

Evolution of Melanocytic Nevi under Vemurafenib, Followed by Combination Therapy with Dabrafenib and Trametinib for Metastatic Melanoma

Calin Giurcaneanu^{1,2}, Cornelia Nitipir^{1,3}, Liliana Gabriela Popa², Ana Maria Forsea^{1,2}, Ioana Popescu², Roxana Silvia Bumbacea^{1,2}

¹Carol Davila University of Medicine and Pharmacy, Bucharest, Romania; ²Department of Dermatology, Elias Emergency University Hospital, Bucharest, Romania; ³Department of Oncology, Elias Emergency University Hospital, Bucharest, Romania
The first two authors contributed equally.

Corresponding author:

Liliana Gabriela Popa, MD
Department of Dermatology
Elias Emergency University Hospital
No. 17, Marasti Bvd.
District 1
Bucharest,
Romania
lilidiaconu@yahoo.com

Received: August 10, 2014

Accepted: May 15, 2015

Acknowledgments:

The research was conducted in the Departments of Dermatology and Oncology of Elias Emergency University Hospital, Bucharest, Romania.

ABSTRACT Treatment of advanced melanoma with selective BRAF and MEK inhibitors is associated with a series of mucocutaneous side effects, among which morphological changes in preexisting nevi and the development of new melanocytic lesions, both benign and malignant.

Objective was to describe the changes observed in melanocytic nevi under vemurafenib therapy, followed by combination therapy with dabrafenib and trametinib for metastatic melanoma.

The melanocytic lesions of a 51-year-old Caucasian male patient diagnosed with stage IV melanoma were monitored both clinically and dermoscopically throughout vemurafenib, followed by combined treatment with dabrafenib and trametinib.

The 65 monitored nevi presented different behaviors under vemurafenib treatment: 18 reticular nevi, 9 reticular-homogenous nevi, 3 reticular-globular nevi, and 2 globular nevi showed a diffuse decrease in pigmentation. Ten reticular nevi remained unchanged, while the rest of the nevi, independent of the dermoscopic pattern, presented a gradual increase in pigmentation. On the other hand, under dabrafenib and trametinib treatment 57 of these nevi showed gradual decrease in pigmentation and central involution, while 7 reticular nevi and 1 globular nevi remained unchanged; none of the monitored nevi increased in pigmentation nor presented new globules following this combination therapy.

Systematic total body skin examination is mandatory in patients receiving BRAF inhibitors. The divergent course of melanocytic nevi during vemurafenib vs. dabrafenib and trametinib therapy remains to be elucidated by further research.

KEY WORDS: melanoma; pigmented nevus; dermoscopy; vemurafenib

INTRODUCTION

Despite global efforts to prevent melanoma through education campaigns and melanoma screening programs, its incidence has constantly risen during the last few decades (1-3). It accounts for less than 2% of skin cancers, but is responsible for approximately 75% of deaths from skin cancer (1).

Melanoma is a curable disease when detected early. However, with regard to advanced metastatic melanoma we are faced with few therapeutic options and a very high mortality rate. Inclusion of patients with stage IV melanoma in clinical trials is preferred due to the low response rate to standard chemother-

apeutic agents such as dacarbazine (as monotherapy or combined with carmustine and cisplatin) and to immunotherapeutic agents such as interferon alpha-2b and high dose interleukin 2. All these treatments failed to improve overall survival in stage IV melanoma, although the latter was associated with durable complete responses in a minority of patients.

Recently, 4 innovative therapeutic agents resulted in improved rates of overall and progression-free survival in patients with advanced melanoma in phase III clinical trials (4,5).

Ipilimumab, a fully human monoclonal antibody against the cytotoxic T lymphocyte associated antigen 4 (CTLA 4) proved beneficial both as single therapy in patients with pretreated metastatic melanoma and in combination with dacarbazine in patients with previously untreated metastatic melanoma (6). It was approved by the US Food and Drug Administration (FDA) for the treatment of unresectable metastatic melanoma in March 2011 and by the European Medicines Agency (EMA) as the second line treatment for metastatic melanoma in November 2012 (7,8).

Vemurafenib, a BRAF serine-threonine kinase inhibitor, was approved by the FDA in August 2011 and by the EMA in February 2012 for the treatment of unresectable or metastatic melanoma harboring the activating BRAF V600E mutation. This is the most frequent protein kinase mutation encountered in melanoma, resulting from the substitution of valine (V) by glutamic acid (E) at codon 600 on the BRAF protein (9). Compared to the wild type, BRAF V600E has a significantly intensified kinase activity associated with uncontrolled cell growth and prolonged cell survival (10-12). Approximately 50% of melanomas and an even higher percentage of melanocytic nevi exhibit activating BRAF mutations (11,12). Vemurafenib does not inhibit melanoma cells without this mutation and can even stimulate wild type BRAF, promoting tumor growth (13,14). Clinical trials have shown that melanoma regresses at least to some degree in up to 90% of patients treated with vemurafenib (15-17). The phase III trial that compared the effects of vemurafenib 960 mg orally twice daily and dacarbazine 1000 mg/m² of body surface area administered intravenously every 3 weeks in 675 previously untreated patients with metastatic melanoma positive for BRAF V600E mutation demonstrated significant improvement in median overall survival (13.6 months vs. 9.7 months, hazard ratio=0.7) and progression-free survival (5.3 vs. 1.6 months; hazard ratio=0.26, p<0.001) in patients treated with vemurafenib (15). The overall survival at 6 months was 84% in patients treated with vemurafenib compared to 64% in those who received dacarbazine. Vemurafenib was associated with a 63%

relative reduction in the risk of death. Response to vemurafenib occurred rapidly, after a median period of 1.45 months (15). Unfortunately, the majority of patients develop resistance to vemurafenib, the median duration of response being 5.5-7.5 months (18).

More recently, in May 2013, a new BRAF protein kinase inhibitor dabrafenib and MEK inhibitor trametinib were both approved by the FDA as single agents in the treatment of BRAF V600E positive advanced melanoma. Unfortunately, patients treated with these agents as monotherapy developed resistance within 6-7 months (19). Soon afterwards, as data from clinical trials showed that combining dabrafenib with trametinib overcomes this resistance, the combination of the two drugs was granted accelerated approval by the FDA in January 2014 for the treatment of unresectable or metastatic melanoma demonstrating the BRAF V600E mutation or the rarer BRAF V600K mutation, as determined by the FDA approved test (19,20). BRAF V600K mutation results in the substitution of valine at codon 600 to lysine. Combination therapy with dabrafenib 150 mg daily and trametinib 2 mg daily was compared to dabrafenib monotherapy in a phase I/II trial (20). The response rate and median progression-free survival for combination therapy were superior to those for monotherapy with dabrafenib (76% vs. 54%; 9.4 vs. 5.8 months, respectively) (20). Two phase III trials that compare combination therapy with dabrafenib and trametinib to dabrafenib monotherapy and vemurafenib monotherapy, respectively, are currently ongoing (21,22).

A series of mucocutaneous side effects have been reported with selective BRAF inhibitor therapy, which include benign and malignant skin tumors, such as keratoacanthoma, and invasive squamous cell carcinomas, warty dyskeratomas, and verrucous keratoses (23-28). Moreover, some of the patients receiving vemurafenib presented with morphological changes in preexisting nevi, as well as development of new melanocytic lesions, both benign and malignant (29-37). However, few reports on the changes of melanocytic nevi under dabrafenib and trametinib treatment have been published.

CASE REPORT

We present the case of a 51-year-old Caucasian male patient, Fitzpatrick skin type III, diagnosed with bilateral axillary lymph nodes metastases of melanoma with occult primary tumor in June 2013. Cerebral, thoracic, abdominal, and pelvic computed tomography examination performed in July 2013 revealed the presence of left axillary lymph nodes, left lateral tho-



Table 1. Dermoscopic changes in nevi monitored during vemurafenib, followed by dabrafenib and trametinib therapy

Baseline number of nevi (%)	Nevi changes during treatment with vemurafenib	Nevi changes during treatment with dabrafenib and trametinib
Reticular 40 (62%)	18 presented diffuse decrease in pigmentation 5 presented new central globules	Further decrease in pigmentation 5 presented central involution 2 eccentric involution
	12 presented diffuse increase in pigmentation 3 presented new central globules	Diffuse decrease in pigmentation 3 presented central involution and disappearance of central globules
	10 remained unchanged	7 remained unchanged 3 presented diffuse decrease in pigmentation
Reticular-homogenous 15 (23%)	9 presented diffuse decrease in pigmentation	Further decrease in pigmentation 4 presented central involution
	6 presented diffuse increase in pigmentation	Diffuse decrease in pigmentation 5 presented central involution
Reticular-globular 8 (12%)	3 presented diffuse decrease in pigmentation	Further decrease in pigmentation and central involution
	5 presented diffuse increase in pigmentation	Diffuse decrease in pigmentation 3 presented central involution
Globular 2 (3%)	Diffuse decrease in pigmentation	1 further decreased in pigmentation 1 remained unchanged

racic wall, and bilateral pulmonary metastases. The patient tested positive for BRAF V600E mutation. He was referred to our Department in August 2013.

The patient presented with an altered general state, fatigability, and markedly decreased effort tolerance. Clinical examination revealed the presence of a firm, violaceous tumorous mass on an erythematous background in the left axillary area (Figure 1). Firm nodules of approximately 3 cm in diameter were palpable in the right malar and right parasternal regions.

We noted more than 100 melanocytic nevi on the patient's trunk and limbs (Figure 2), of which 65 were examined by the aid of digital dermoscopy. The dermoscopic pattern of the examined nevi was as follows: 40 (62%) reticular, 15 (23%) reticular-homogenous, 8 (12%) reticular-globular, and 2 (3%) globular.

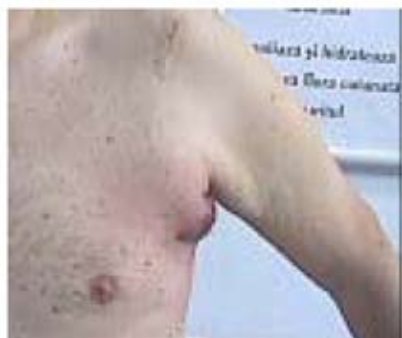

Figure 1. Tumorous mass on an erythematous background in the left axillary area.

The ophthalmologic examination did not reveal pathologic findings. No primary tumor was identified.

Laboratory analyses yielded leukocytosis ($11.5 \times 10^3/\mu\text{L}$) with neutrophilia ($8.52 \times 1010^3/\mu\text{L}$), associated with a mild biological inflammatory syndrome (erythrocyte sedimentation rate (ESR)=36 mm/h, Fibrinogen=454 mg/dL and positive C reactive protein (CRP)) and an elevated lactate dehydrogenase (LDH) level of 648 U/L (normal value <220 U/l). S100 serum level was increased at 2.28 $\mu\text{g/L}$ (normal values <0.15 $\mu\text{g/L}$ determined by chemiluminiscence), while carcinoembrionic antigen serum level was 1.52 ng/mL

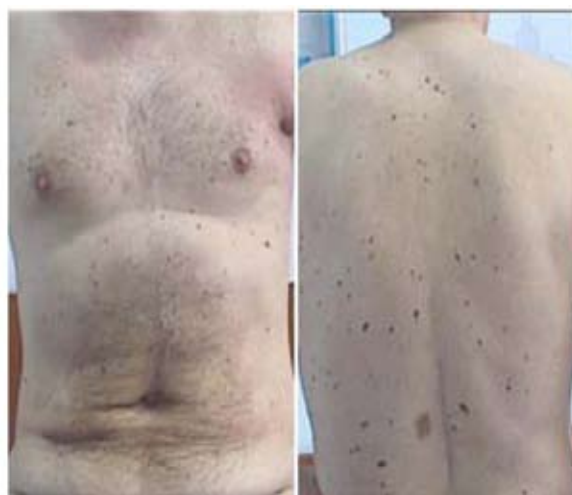

Figure 2. Numerous nevi on the patient's torso.

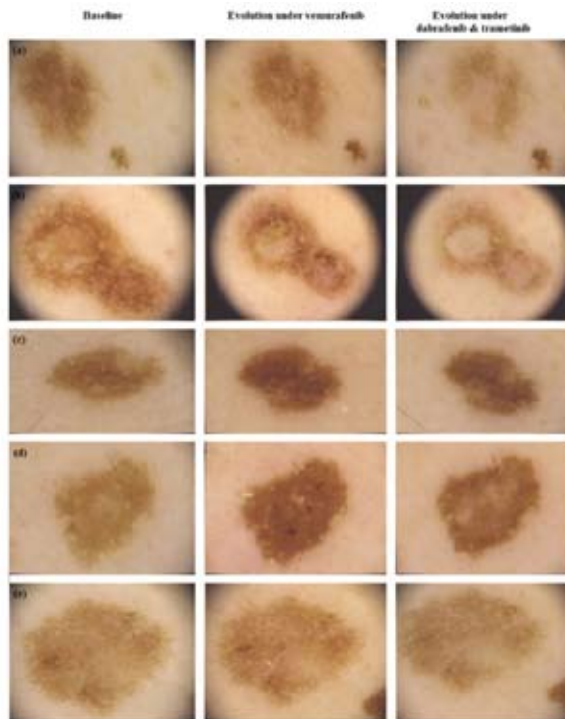


Figure 3. Evolution of reticular nevi: (a), (b) diffuse decrease in pigmentation during vemurafenib treatment, followed by further decrease in pigmentation during dabrafenib and trametinib therapy; (c), (d) diffuse increase in pigmentation during vemurafenib treatment, followed by diffuse decrease in pigmentation during dabrafenib and trametinib therapy; (e) stable nevus during vemurafenib treatment, followed by diffuse decrease in pigmentation during dabrafenib and trametinib therapy.

(normal values <5 ng/mL in non-smokers and <10 ng/mL in smokers, determined by chemiluminescent microparticle immunoassay (CMIA), Architect AB-BOTT).

As the patient refused dacarbazine treatment, the oncologist initiated treatment with vemurafenib 960 mg orally q 12 hr.

After one month of vemurafenib treatment, the patient returned to our Department for follow-up skin examination. The patient's general state and effort tolerance were very much improved, and the left axillary tumorous mass, the right malar and right parasternal nodules were no longer present on inspection and palpation. Multiple new reticular nevi and seborrheic keratoses had occurred. Results of routine laboratory exams were within normal limits, as was S100 serum level (0.08 µg/L). Computed tomography examination was repeated in December 2013 and showed the resolution of all secondary tumors (left axillary lymph

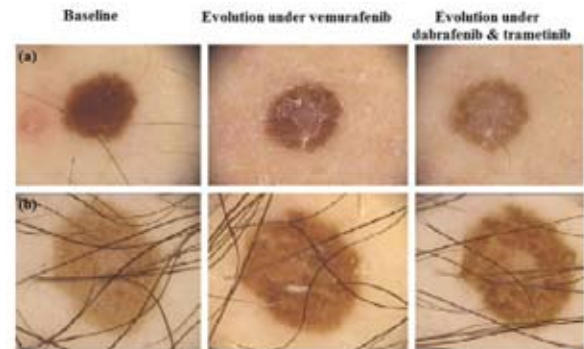

Figure 4. Evolution of reticular-homogenous nevi: (a) diffuse decrease in pigmentation and central involution during vemurafenib treatment, followed by further decrease in pigmentation during dabrafenib and trametinib therapy; (b) diffuse increase in pigmentation during vemurafenib treatment, followed by diffuse decrease in pigmentation, and central involution during dabrafenib and trametinib therapy.

nodes, left lateral thoracic wall, and bilateral pulmonary metastases).

Due to financial restraints, vemurafenib administration was ceased in December 2013. The patient was included in an ongoing clinical trial and initiated combination therapy with dabrafenib 150 mg/day and trametinib 2 mg/day, which he currently receives.

The patient's melanocytic lesions were monitored both clinically and dermoscopically throughout vemurafenib and dabrafenib and trametinib treatment. The changes observed are detailed in Table 1 and illustrated in Figures 3, 4, 5, 6.

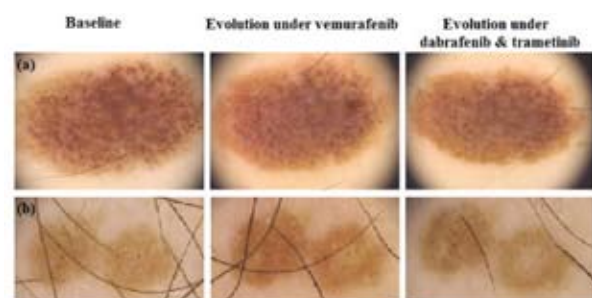


Figure 5. Evolution of reticular-globular nevi: (a) diffuse decrease in pigmentation during vemurafenib treatment, followed by further decrease in pigmentation during dabrafenib and trametinib therapy; (b) diffuse increase in pigmentation during vemurafenib treatment, followed by diffuse decrease in pigmentation, and central involution during dabrafenib and trametinib therapy.

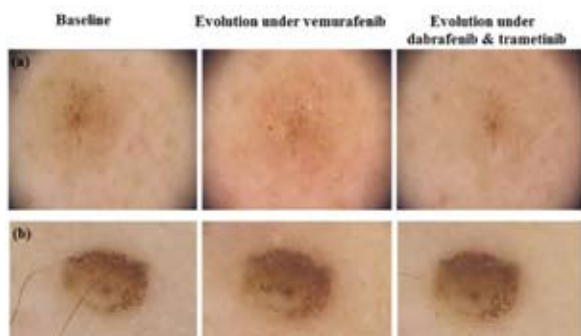

Figure 6. Evolution of globular nevi: (a) diffuse decrease in pigmentation during vemurafenib treatment, followed by further decrease in pigmentation during dabrafenib and trametinib therapy; (b) diffuse decrease in pigmentation during vemurafenib treatment, and stable nevus during dabrafenib and trametinib therapy.

DISCUSSION

The RAS-RAF-MEK-ERK mitogen-activated protein kinase (MAPK) pathway is involved in the transduction of mitogenic signals from the cell membrane to the nucleus, influencing cellular differentiation and proliferation (38). Hyperactivation of the cascade as a result of various mutations occurring at different levels leads to uncontrolled cell growth, prevention of apoptosis, and promotes cancer development (10,39,40). Among such activating mutations, BRAF mutations are frequent and have been linked to the development of a wide range of malignancies, especially melanoma and thyroid cancer (16,28).

Mutant BRAF is present in approximately 50% of melanomas and in an even higher proportion of melanocytic nevi (11,12,41). 75-90% of BRAF mutations in melanoma are missense mutations resulting from the substitution of valine (V) to glutamic acid (E) at codon 600, referred to as BRAF V600E (10,15). BRAF V600E possesses a much amplified kinase activity compared to wild-type BRAF and activates downstream mitogen-activated protein/extracellular signal-regulated kinase (MEK), regardless of RAS status.

BRAF V600E has become the target of a series of new antimelanoma agents, including vemurafenib and dabrafenib, with efficacy that greatly exceeds that of classic chemotherapeutic drugs as discussed above.

However, these therapies are accompanied by a series of adverse effects such as arthralgia, rash, fatigue, nausea, and diarrhea that impose dose reductions in 38% of cases (15). Various cutaneous side effects like pruritus, alopecia, hyperkeratosis, and the development of keratoacanthoma and squamous cell carcinoma,

usually well differentiated, occur frequently in patients receiving BRAF kinase inhibitors (15).

Other phenomena associated with the administration of these drugs are morphological changes in pre-existing nevi, i.e. changes in size, shape and color, both regression or darkening of nevi having been reported (28,30,31), as well as the appearance of new benign and malignant melanocytic lesions. These changes have been noticed 2 to 42 weeks after starting vemurafenib therapy (29). New primary melanomas occurring either in rapidly changing preexisting nevi or *de novo* have been observed in these patients (29,33,34,36,42).

We observed different behaviors of our patient's nevi under vemurafenib treatment. Of the 65 nevi monitored, 18 reticular nevi, 9 reticular-homogenous nevi, 3 reticular-globular nevi, and 2 globular nevi showed a diffuse decrease in pigmentation. 10 reticular nevi remained unchanged, while the rest of the nevi, independently of the dermoscopic pattern, presented gradual increase in pigmentation.

Haenssle *et al.* were the first to report, in 2012, involution of pre-existing compound nevi without clear dermoscopic signs of immunological regression in a 56-year-old woman with BRAF V600E positive metastatic melanoma treated with vemurafenib (28). Thereafter, several authors described similar changes in pigmented lesions during vemurafenib treatment (27,34), and it was hypothesized that such involuting nevi also harbored BRAF V600E mutation and were therefore targeted by vemurafenib (28).

On the other hand, in the same patient, Haenssle *et al.* observed a totally different behavior of preexisting flat, reticular pattern nevi under vemurafenib (28). These increased in pigmentation, and cytologic dysplasia was found in one melanocytic lesion that was excised. Such changes in flat nevi were also described, among others, by Chu *et al.* (30), Germani *et al.* (31), and Debarbieux *et al.* (33). Genetic typing of nevi that developed atypical features during vemurafenib treatment revealed non-mutated wild-type BRAF.

The occurrence of new primary melanomas has also been reported in patients receiving vemurafenib. Dalle *et al.* reported 5 new primary melanomas in 4 of the 5 patients treated (27,34). Similarly, Zimmer *et al.* found 12 new primary melanomas in 11 patients under vemurafenib (29). The majority of new primary melanomas developed in nevi predating treatment with selective BRAF blockers and all proved to be wild-type BRAF (29,33,34,36,42). It is tempting to speculate that these melanomas were biologically present, but clinically unapparent before vemurafenib initiation, and were revealed by this treatment.

Transactivation of wild-type BRAF or a paradoxical activation of the MAP kinase pathway are the suspected mechanisms underlying the atypical evolution of reticular nevi and the development of new melanomas in these individuals (28,29,34). *In vitro* studies have shown that BRAF inhibitors induce a paradoxical MEK activation (13) and a paradoxical increase in ERK phosphorylation in wild-type BRAF melanocytes (43). The increased signaling through the MAP kinase pathway might be related to CRAF dependent mechanisms (13). Upregulation of other signaling pathways such as PI3K/AKT could also be involved in this process.

At the moment there are very few reports on the evolution of melanocytic lesions under more recent therapies, such as dabrafenib and trametinib combination therapy. Mattei *et al.* described a single changing nevus in a 65-year-old metastatic melanoma male patient (32). McClenahan *et al.* have very recently published a report of the BRAFV600E mutation status of involuting and stable nevi in a metastatic melanoma patient participating in dabrafenib with or without trametinib clinical trial. Once again, involuting nevi proved to be BRAFV600E, while the stable ones were wild type BRAF (44).

Clinical trials showed that dabrafenib and trametinib treatment has less cutaneous side-effects, including keratinocyte proliferation, probably due to a higher affinity to the mutant BRAF and less cross-reactivity to CRAF (19). Moreover, the combination therapy is accompanied by an even lower risk of skin toxicity than monotherapy. This can be explained by the inhibition of paradoxical MAP kinase activation associated with BRAF inhibitors (45).

This is in accordance with our findings, with 57 (88%) of our patient's nevi showing gradual decrease in pigmentation and central involution under dabrafenib and trametinib treatment regardless of their evolution under vemurafenib treatment. 7 reticular nevi and 1 globular nevus remained unchanged. None of the monitored nevi increased in pigmentation nor presented new globules following this combination therapy.

CONCLUSIONS

Systematic total body skin examination, with close monitoring of any new or changing pigmented lesion is mandatory in patients receiving BRAF inhibitors. The rapid changes of nevi observed under such treatments and the increased risk of primary new melanomas in these patients necessitate monthly follow-up visits.

The divergent courses of melanocytic nevi during vemurafenib vs. dabrafenib and trametinib therapy is a matter of great interest that remains to be elucidated by further research.

References

1. American Cancer Society. Cancer Facts & Figures 2014. URL: <http://www.cancer.org/acs/groups/content/@research/documents/webcontent/acspc-042151.pdf> Accessed on June 2, 2014.
2. Linos E, Swetter SM, Cockburn MG, Colditz GA, Clarke CA. Increasing burden of melanoma in the United States. *J Invest Derm* 2009;129:1666-74.
3. Ahmedin J, Siegel R, Xu J, Ward E. Cancer Statistics, 2010. *CA Cancer J Clin* 2010;60:288-96.
4. Robert C, Thomas L, Bondarenko I, O'Day S, Weber J, Garbe C, *et al.* Ipilimumab plus dacarbazine for previously untreated metastatic melanoma. *N Engl J Med* 2011;364:2517-26.
5. Raymond AK, Beasley GM, Broadwater G, Augustine CK, Padussis JC, Turley R, *et al.* Current trends in regional therapy for melanoma: Lessons learned from 225 regional chemotherapy treatments between 1995 and 2010 at a single institution. *J Am Coll Surg* 2011;213:306-16.
6. Wolchok J. How recent advances in immunotherapy are changing the standard of care for patients with metastatic melanoma. *Ann Oncol* 2012;23(Suppl 8):viii15-21.
7. FDA news release. URL: <http://www.fda.gov/newsevents/newsroom/pressannouncements/ucm1193237.htm> Accessed on November 29, 2014.
8. Hanaizi Z, van Zwieten-Boot B, Calvo G, Sancho Lopez A, van Dartel M, Camarero J, *et al.* The European Medicines Agency review of ipilimumab (Yervoy) for the treatment of advanced (unresectable or metastatic) melanoma in adults who have received prior therapy: Summary of the scientific assessment of the Committee for Medicinal Products for Human Use. *Eur J Cancer* 2012;48:237-42.
9. Takata M, Saida T. Genetic alterations in melanocytic tumors. *J Dermatol Sci* 2006;43:1-10.
10. Flaherty KT. BRAF inhibitors and melanoma. *Cancer J* 2011;17:505-11.
11. Curtin JA, Fridlyand J, Kageshita T, Patel HN, Busam KJ, Kutzner H, *et al.* Distinct sets of genetic alterations in melanoma. *N Engl J Med* 2005;353:2135-47.
12. Davies H, Bignell GR, Cox C, Stephens P, Edkins S,

- Clegg S, *et al.* Mutations of the BRAF gene in human cancer. *Nature* 2002;417:949-54.
13. Hatzivassiliou G, Song K, Yen I, Brandhuber BJ, Anderson DJ, Alvarado R, *et al.* RAF inhibitors prime wild-type RAF to activate the MAPK pathway and enhance growth. *Nature* 2010;464:431-5.
 14. Halaban R, Zhang W, Bacchicocchi A, Cheng E, Parisi F, Ariyan S, *et al.* PLX4032, a selective BRAF(V600E) kinase inhibitor, activates the ERK pathway and enhances cell migration and proliferation of BRAF(WT) melanoma cells. *Pigment Cell Melanoma Res* 2010;23:190-200.
 15. Chapman PB, Hauschild A, Robert C, Haanen JB, Ascierto P, Larkin J, *et al.* Improved survival with vemurafenib in melanoma with BRAF V600E mutation. *N Engl J Med* 2011;364:2507-16.
 16. Flaherty KT, Puzanov I, Kim KB, Ribas A, McArthur GA, Sosman JA, *et al.* Inhibition of mutated, activated BRAF in metastatic melanoma. *N Engl J Med* 2010;363:809-19.
 17. Ribas AK, Kim KB, Schuchter L, Gonzalez R, Pavlick AC, Weber JS, *et al.* BRIM-2: an open-label, multicenter phase II study of vemurafenib (PLX4032, RG7204) in previously treated patients with BRAF-V600E mutation-positive metastatic melanoma [abstract]. *J Clin Oncol* 2011;29(Suppl):8509.
 18. Batus M, Waheed S, Ruby C, Petersen L, Bines SD, Kaufan HL. Optimal management of metastatic melanoma: Current strategies and future directions. *Am J Clin Dermatol* 2013;14:179-94.
 19. Johnson DB, Sosman JA. Update on the targeted therapy of melanoma. *Current Treatment Options in Oncology* 2013;14:280-92.
 20. Flaherty KT, Infante JR, Daud A, Gonzalez R, Kefford RF, Sosman J, *et al.* Combined BRAF and MEK inhibition in melanoma with BRAF V600 mutations. *N Engl J Med* 2012;367:1694-703.
 21. A Study Comparing Trametinib and Dabrafenib Combination Therapy to Dabrafenib Monotherapy in Subjects with BRAF-mutant Melanoma. In: *ClinicalTrials.gov*. URL: <http://clinicaltrials.gov/show/NCT01584648> Accessed on November 29, 2014.
 22. Dabrafenib Plus Trametinib vs. Vemurafenib Alone in Unresectable or Metastatic BRAF V600E/K Cutaneous Melanoma (COMBI-v). In: *ClinicalTrials.gov*. URL: <http://clinicaltrials.gov/show/NCT01597908> Accessed on November 29, 2014.
 23. Oberholzer PA, Kee D, Dziunycz P, Sucker A, Kamukom N, Jones R, *et al.* RAS mutations are associated with the development of cutaneous squamous cell tumors in patients treated with RAF inhibitors. *J Clin Oncol* 2012;30:316-21.
 24. Huang V, Hepper D, Anadkat M, Cornelius L. Cutaneous toxic effects associated with vemurafenib and inhibition of the BRAF pathway. *Arch Dermatol* 2012;148:628-33.
 25. Zimmer L, Vaubel JV, Livingstone E, Schadendorf D. Side effects of systemic oncological therapies in dermatology. *J Dtsch Dermatol Ges* 2012;10:475-86.
 26. Sinha R, Edmonds K, Newton-Bishop JA, Gore ME, Larkin J, Fearfield L. Cutaneous adverse events associated with vemurafenib in patients with metastatic melanoma: practical advice on diagnosis, prevention and management of the main treatment-related skin toxicities. *Br J Dermatol* 2012;167:987-94.
 27. Dalle S, Poulalhon N, Debarbieux S, Thomas L. Second primary melanomas under vemurafenib [letter]. *Br J Dermatol* 2013;168:887-8.
 28. Haenssle HA, Kraus SL, Brehmer F, Kretschmer L, Volker B, Asper H, *et al.* Dynamic changes in nevi of a patient with melanoma treated with vemurafenib. Importance of sequential dermatoscopy. *Arch Dermatol* 2012;148:1183-5.
 29. Zimmer L, Hillen U, Livingstone E, Lacouture ME, Busam K, Carvajal RD, *et al.* Atypical melanocytic proliferations and new primary melanomas in patients with advanced melanoma undergoing selective BRAF inhibition. *J Clin Oncol* 2012;30:2375-83.
 30. Chu EY, Wanat KA, Miller CJ, Amaravadi RK, Fecher LA, Brose MS, *et al.* Diverse cutaneous side effects associated with BRAF inhibitor therapy: a clinicopathologic study. *J Am Acad Dermatol* 2012;67:1265-7.
 31. Gerami P, Sorrell J, Martini M. Dermatoscopic evolution of dysplastic nevi showing high-grade dysplasia in a metastatic melanoma patient on vemurafenib [letter]. *J Am Acad Dermatol* 2012;67:e275-6.
 32. Mattei PL, Alora-Palli MB, Kraft S, Lawrence DP, Flaherty KT, Kimball AB. Cutaneous effects of BRAF inhibitor therapy: a case series. *Ann Oncol* 2013;24:530-7.
 33. Debarbieux S, Dalle S, Depaepe L, Poulalhon N, Balme B, Thomas L. Second primary melanomas treated with BRAF blockers: study by reflectance confocal microscopy. *Br J Dermatol* 2013;168:1230-5.
 34. Dalle S, Poulalhon N, Thomas L. Vemurafenib in melanoma with BRAF V600E mutation [letter]. *N Engl J Med* 2011;365:1448-9.

35. Chapman PB, Hauschild A, McArthur GA. Vemurafenib in melanoma with BRAF V600E mutation. The authors reply [letter]. *N Engl J Med* 2011;365:1450.
36. Ma L, Dominguez AR, Collins GR, Kia KF, Cockerell CJ. Hidradenitis suppurativa, eruptive melanocytic nevi, and keratosis pilaris-like eruption in a patient treated with vemurafenib. *Arch Dermatol* 2012;148:1428-9.
37. Fearfield L, Newton-Bishop JA, Sinha R, Edmonds K, Gore ME, Larkin J. Second primary melanomas under vemurafenib—reply from the authors. *Br J Dermatol* 2013;168:888-9.
38. Wellbrock C, Hurlstone A. BRAF as therapeutic target in melanoma. *Biochem Pharmacol* 2010;80:561-7.
39. Jordan EJ, Kelly CM. Vemurafenib for the treatment of melanoma. *Expert Opin Pharmacother* 2012;13:2533-43.
40. Ravnán MC, Matalka MS. Vemurafenib in patients with BRAF V600E mutation-positive advanced melanoma. *Clin Ther* 2012;34:1474-86.
41. Pollock PM, Harper UL, Hansen KS, Yudt LM, Stark M, Robbins CM, *et al.* High frequency of BRAF mutations in nevi. *Nat Genet* 2003;33:19-20.
42. Schmitt L, Schumann T, Inhoff O, Loser C, Rebel M, Dippel E. Eruptive nevi mimicking wartlike lesions under selective BRAF inhibition in a 37-year-old female melanoma patient. *Case Rep Dermatol* 2013;5:69-72.
43. Arnault JP, Mateus C, Escudier B, Tomasic G, Wechsler J, Hollvile E, *et al.* Skin tumors induced by sorafenib; paradoxical RAS-RAF pathway activation and oncogenic mutations of HRAS, TP53, and TGFBR1. *Clin Cancer Res* 2012;18:263-72.
44. McClenahan P, Lin LL, Tan JM, Flewell-Smith R, Schaider H, Jagirdar K, *et al.* BRAFV600E mutation status of involuting and Stable Nevi in dabrafenib therapy with or without trametinib. *JAMA Dermatol* 2014. doi: 10.1001/jamadermatol.2014.436. [Epub ahead of print]
45. Su F, Viros A, Milagre C, Trunzer K, Bollag G, Spleiss O, *et al.* RAS mutations in cutaneous squamous-cell carcinomas in patients treated with BRAF inhibitors. *N Engl J Med* 2012;366:207-15.

