

Prikaz slučaja / Case report

Cor triatriatum sinister u trudnice

A case of cor triatriatum sinister during pregnancy

Stanko Biočić, Josip Vincelj, Mario Udovičić*

Klinička bolnica Dubrava, Zagreb, Hrvatska
University Hospital Dubrava, Zagreb, Croatia

SAŽETAK: Cor triatriatum sinister rijetka je prirođena srčana greška, koja obično biva otkrivena u djetinjstvu. Donosimo prikaz slučaja mlade bolesnice kojoj je cor triatriatum sinister otkriven u odrasloj dobi te njegovo praćenje tijekom trudnoće i uspješno konzervativno liječenje sve do poroda. Obzirom na sličnu patofiziologiju odlučili smo se bolesnicu pratiti kao umjereno tešku asimptomatsku mitralnu stenozu. Kliničko praćenje i redoviti ehokardiografski pregledi zauzimaju pri tome centralno mjesto. Prema našem saznanju, ovaj slučaj pacijentice predstavlja prvi slučaj majčinskoga cor triatriatum sinister u trudnoći u Hrvatskoj.

KLJUČNE RIJEČI: cor triatriatum sinister, trudnoća, ehokardiografija.

SUMMARY: Cor triatriatum sinister is a rare congenital cardiac malformation, usually diagnosed in childhood. We describe a case of maternal cor triatriatum diagnosed in adult age and its successful conservative management throughout pregnancy until postpartum. Due to hemodynamic similarities, we decided to treat the cor triatriatum sinister like a moderate asymptomatic functional mitral stenosis in this case. Clinical controls, regular echocardiographic controls have a central place in the follow up of gravida with congenital cardiac anomalies. To the best of our knowledge, this case is the first case of maternal cor triatriatum sinister in Croatia.

KEYWORDS: cor triatriatum sinister, pregnancy, echocardiography.

CITATION: *Cardiol Croat.* 2014;9(1-2):71-74.

Uvod

Cor triatriatum sinister rijetka je prirođena srčana greška, koja obično biva otkrivena u djetinjstvu. Dijagnoza i praćenje cor triatriatum sinister u potpunosti je moguće s minimalno invazivnim metodama, kao što su transtorakalna i transezofagusna 2D te 3D ehokardiografija. Ove metode su stupovi praćenja ove rijetke prirođene srčane greške, čija rijetkost može doprinijeti njezinom neprepoznavanju, no kada je ispravno prepoznata i liječena, ishod je izvrstan¹.

Donosimo prikaz slučaja mlade bolesnice kojoj je cor triatriatum sinister otkriven u odrasloj dobi te njegovo praćenje tijekom trudnoće i uspješno konzervativno liječenje sve do poroda.

Prikaz slučaja

Trudnica u dobi od 30 godina s nedavno otkrivenim asimptomatskim cor triatriatum sinister upućena je u ustanovu radi kardiološke reevaluacije. Od djetinjstva je znala za šum na srcu, no sve do nedavno nije bila kardiološki obrađena. Napore je dobro tolerirala.

U statusu je na srcu dominirao holosistolčki šum s punctum maximum nad apeksom te fiksno rascjepljenim drugim srčanim tonom bez naglašenog P2. Laboratorijski nalazi bili su neupadljiv, kao i zapis 12-kanalnog EKG. Transtorakalnom i transezofagusnom 2D te 3D ehokardiografijom prikazana je fibromuskularna membrana lijevog atrija, koja ga dijeli na dvije komore, od kojih proksimalna prima plućne vene. Ko-

Introduction

Cor triatriatum sinister is a rare congenital cardiac malformation, usually diagnosed in childhood. Diagnosis and follow up of cor triatriatum sinister is entirely possible by minimally invasive methods such as transthoracic and transesophageal 2D and 3D echocardiography. These methods are the mainstay of the follow up of this rare cardiac anomaly, whose rarity can contribute to its misdiagnosis, but when correctly diagnosed and managed, it has an excellent outcome¹.

We describe a case of maternal cor triatriatum diagnosed in an adult age and its successful conservative management throughout pregnancy until postpartum.

Case report

A 30-year-old gravida with an asymptomatic, recently diagnosed, cor triatriatum sinister was referred to our institution for cardiac re-evaluation. She has had a history of heart murmur since childhood, but she has never been properly evaluated because she tolerated effort well.

On physical examination she had regular pulse and normal blood pressure. Cardiac auscultation revealed fixed splitting of the 2nd heart sound without accentuation of P2 and a pansystolic murmur at the apex. Blood test results as well as ECG recording were both unremarkable. Transthoracic and transesophageal 2D and 3D echocardiogram documented a fibromuscular membrane across the left atrium, dividing it into two compartments, with the proximal one receiving the

more komuniciraju preko otvora površine 1,41 cm². Kontinuiranim je doplerom u dijastoli izmjeren srednji intraatrijski gradijent od 6 mmHg. Svi drugi ehokardiografski nalazi bili su uredni. Nije bilo ni indirektnih znakova povišenog plućnog tlaka kao niti eventualanih drugih pridruženih srčanih anomalija (Slike 1-4).

pulmonary venous flow. The two chambers communicated via an orifice with an area of 1.41 cm². The continuous wave Doppler across the membrane showed a diastolic intraatrial mean gradient of 6 mmHg. All other echocardiographic findings were also normal, without any indirect signs of elevated pulmonary pressures. There were no other associated cardiac anomalies (Figures 1-4).

Figure 1. Transesophageal echocardiography presenting left atrium with intraatrial membrane (M).

Legend: LA1 and LA2 compartments of left atrium, LAA left atrial appendage, MV mitral valve, LV left ventricle.

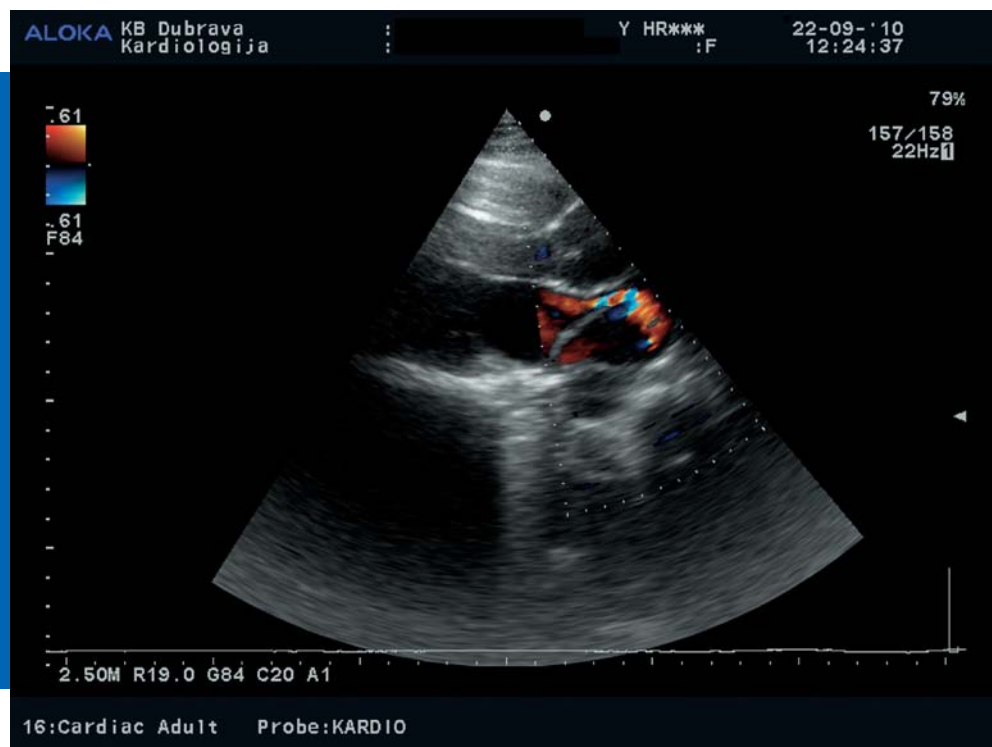
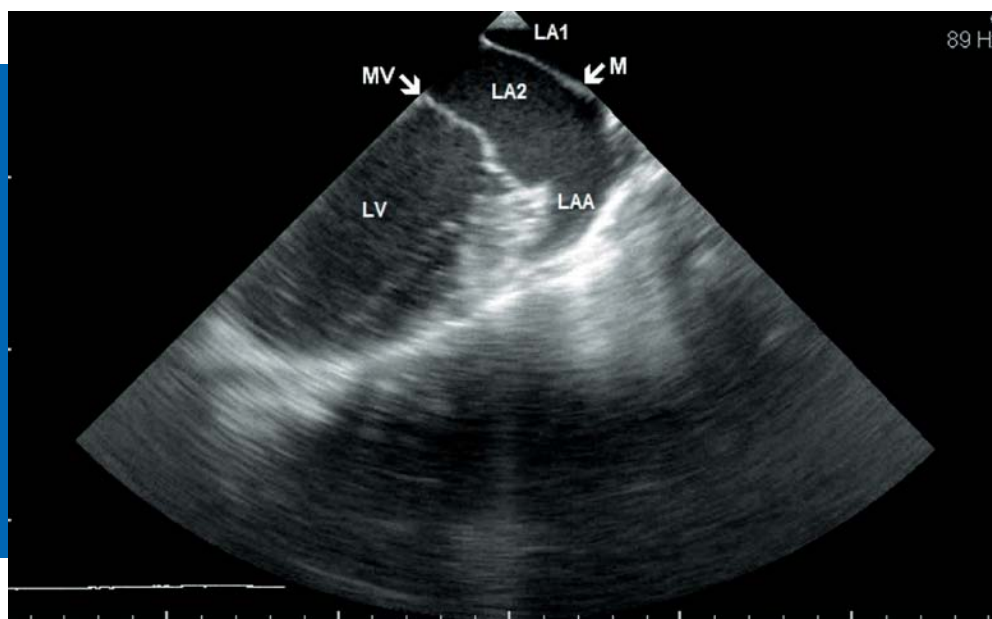


Figure 2. Transthoracic echocardiography showing left atrial membrane.

Obzirom da nije bilo simptoma ili znakova srčanog popuštanja, u suradnji s ginekologom, odlučili smo se za konzervativni pristup. Bolesnici je u terapiju uveden beta-blokator u niskoj dozi te preporučeno mirovanje i redukcija unosa tekućine. Trudnoća je uz redovite kontrole protekla bez problema, bolesnica cijelo vrijeme nije imala nikakve simptome ili tegobe. Redovite rutinske transtorakalne ultrazvučne kontrole srca bile su uredne, kao i vrijednosti NT-proBNP u seru-

Since there were no persisting symptoms or signs of heart failure, in cooperation with a gynecologist, we decided to continue the conservative approach. The patient was put on a low dosage of beta blocker, while prescribing bedrest and reduction of water intake. Close surveillance throughout the pregnancy was maintained, which was uneventful. Routine transthoracic echocardiography repeatedly showed normal findings without development of pulmonary hypertension

Figure 3. Continuous wave Doppler recording across the membrane.

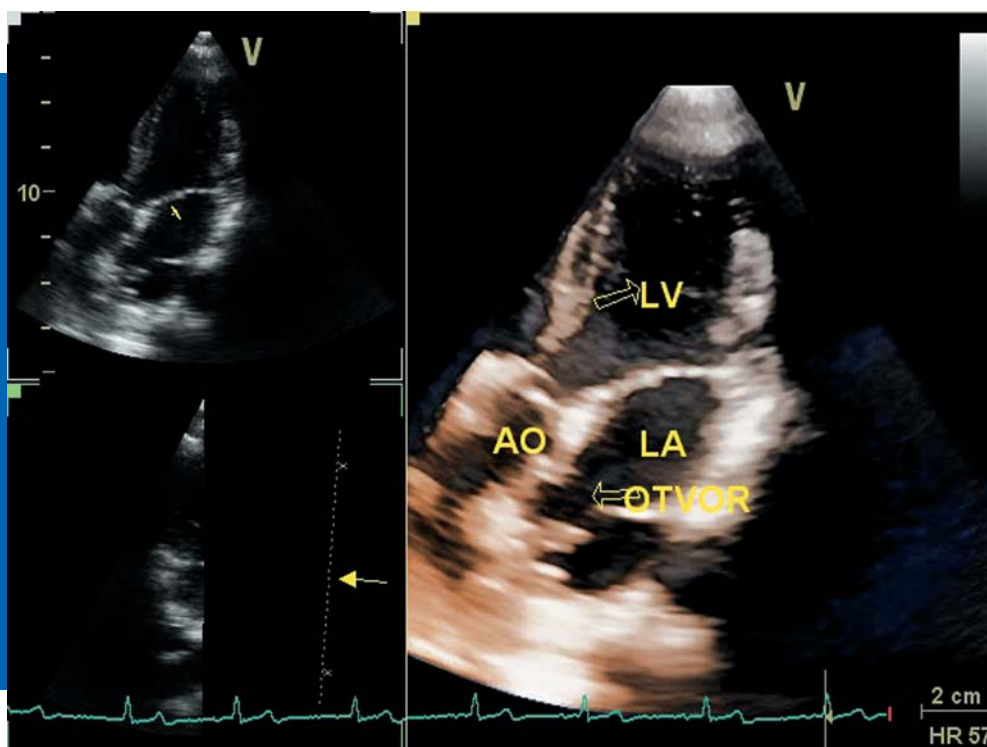
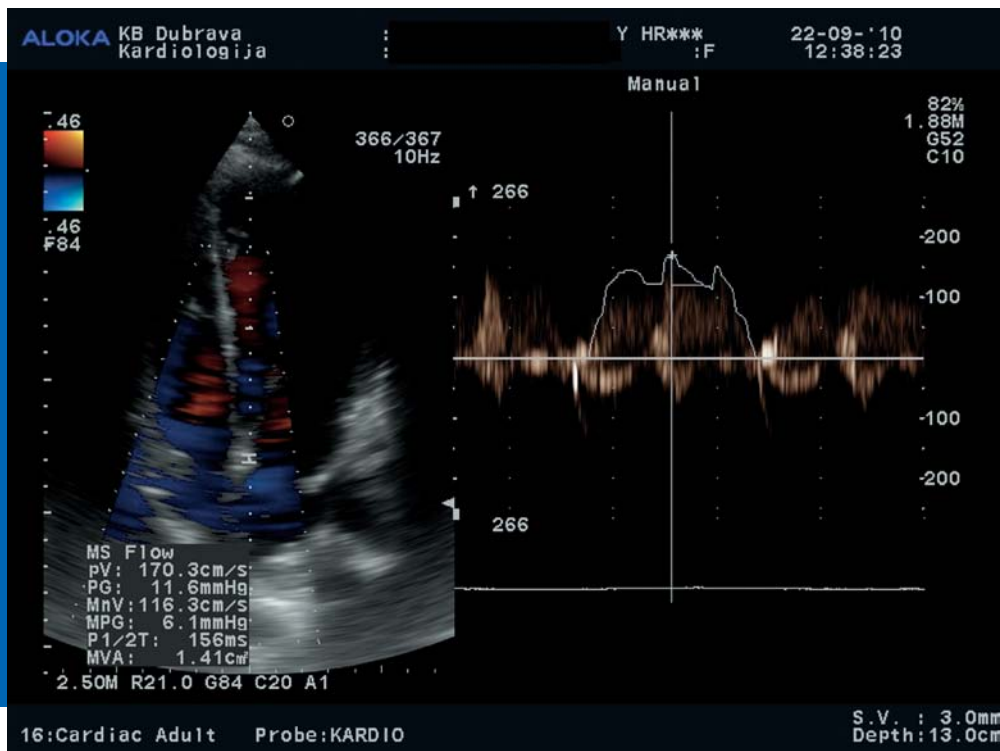


Figure 4. 3D trans-thoracic echocardiography showing left atrial membrane (otvor: orifice).

mu. U 38. tjednu trudnoće pacijentica je vaginalnim putem rodila zdravu djevojčicu.

Rasprava

Cor triatriatum sinister rijetka je srčana greška, prvi put opisana 1868. godine² s incidencijom od 0,1% među srčanim greškama i omjerom incidencije u muškaraca naspram žena 1,5:1.³ Cor triatriatum sinister biva najčešće otkriven u djetinjstvu, no u nekim slučajevima dijagnoza se postavlja u odrasloj dobi^{4,5}, tada najčešće slučajno⁶. Klinička slika i patofizi-

and NT-proBNP levels remained normal. A healthy baby girl was successfully delivered by a normal vaginal birth at 38 weeks' gestation, without any complications.

Discussion

Cor triatriatum sinister is a rare congenital cardiac abnormality first described by Church in 1868² with an estimated incidence of 0.1% of all congenital heart diseases with a ratio of men to women 1.5:1.³ Cor triatriatum is most commonly diagnosed in infancy or childhood, but in some cases it is not

ziološke osobine odgovaraju mitralnoj stenozu. Zbog opstruktivne prirode intraatrijske membrane dolazi do stvaranja tlačnog gradijenta s posljedičnim porastom plućnog venskog i arterijskog tlaka te su najčešći simptomi i znakovi zaduha i hemoptiza. Kao i mitralna stenozu, cor triatriatum sinister može predstavljati veliki izazov u vođenju trudnoće i poroda⁷.

Tijekom trudnoće, dolazi do hormonalno uvjetovanog porasta mase eritrocita, srčane frekvencije⁸ što je povezano s 40% porastom volumena krvi te srčanog minutnog volumena⁹.

U ovom slučaju, obzirom na sličnu patofiziologiju odlučili smo se bolesnicu pratiti kao umjereno tešku asimptomatsku mitralnu stenozu. Bolesnica je rutinski kontrolirana jednom mjesečno, kada smo radili i ultrazvučne kontrole, kojima su u prvom redu kontrolirani tlakovi u plućnoj cirkulaciji i gradijent nad orificijem membrane. Cijelo vrijeme je bila bez simptoma, bez znakova srčanog popuštanja, uz uredne razine NT-proBNP. S jedne strane povećan afterload lijeve klijetke, a s druge limitiran preload predstavljaju klinički izazov. U takvoj situaciji izrazito je važno spriječiti tahikardiju i fibrilaciju atrijske, kako bi se održao adekvatan preload. U isto vrijeme postoji prijetnja nastupa plućne kongestije i edema, naročito tijekom poroda. Potrebno je stoga izbjegavati povećanje cirkulirajućeg volumena primjenom intravenskih infuzija. U terapiju smo uveli beta-blokator radi produljenja dijas-toličkog punjenja, no obzirom na relativno nizak sustavni arterijski tlak nismo se odlučili na uvođenje diuretika, već samo kontrolu unosa tekućine. U literaturi se kod maternalne mitralne stenozu preporuča porod carskim rezom, no u ovom slučaju ginekolog se u dogovoru s trudnicom odlučio za vaginalni porod koji je protekao uredno.

Zaključak

Uz kliničko praćenje redoviti ehokardiografski pregledi zauzimaju centralno mjesto kod praćenja trudnica s prirodnim srčanim greškama. Prema našem saznanju, slučaj ove bolesnice predstavlja prvi slučaj majčinskoga cor triatriatum sinister u trudnoći u Hrvatskoj.

Received: 3rd Jan 2014; Updated 7th Jan 2014; Accepted 15th Jan 2014

*Address for correspondence: Klinička bolnica Dubrava, Avenija Gojka Šuška 6, HR-10000 Zagreb, Croatia.

Phone: +385-1-2902-542

E-mail: mario.udovic@gmail.com

Literature

1. Nassar PN, Hamdan RH. Cor triatriatum sinistrum: classification and imaging modalities. *Eur J Cardiovasc Med.* 2011;1(3):84-7.
2. Church WS. Congenital malformation of the heart: abnormal septum in the left auricle. *Trans Pathol Soc Lond.* 1868;19:188-90.
3. Su CS, Tsai IC, Lin WW, Lee T, Ting CT, Liang KW. Usefulness of multidetector-row computed tomography in evaluating adult cor triatriatum. *Tex Heart Inst J.* 2008;35:349-51.
4. Chen Q, Guhathakurta S, Vadalapali G, et al. Cor triatriatum in adults: three new cases and a brief review. *Tex Heart Inst J.* 1999;26(3):206-10.
5. Hamdan R, Mirochnik N, Celermajer D, Nassar P, Iserin L. Cor triatriatum sinister diagnosed in adult life with three dimensional transesophageal echocardiography. *BMC Cardiovasc Disord.* 2010;10:54.
6. Tanaka F, Itoh M, Esaki H, Isobe J, Inoue R. Asymptomatic cor triatriatum incidentally revealed by computed tomography. *Chest.* 1991;100(1):272-4.
7. Mathew PJ, Subramaniam R, Rawat RS, Kulkarni A. A case of cor triatriatum with pregnancy: an anaesthetic challenge. *J Postgrad Med.* 2004;50:79-80.
8. Siu SC, Colman JM. Heart disease and pregnancy. *Heart.* 2001;85:710-5.
9. Robson SC, Hunter S, Boys RJ, Dunlop W. Serial study of factors influencing changes in cardiac output during human pregnancy. *Am J Physiol.* 1989;256(4 Pt 2):H1060-5.

diagnosed until later^{4,5} and then mostly incidentally⁶. The clinical features mimic those of mitral stenosis. Pathophysiologically the obstructive nature of the membrane leads to the creation of a pressure gradient with an associated rise in pulmonary arterial and venous pressures and the most common symptoms present in adults are dyspnea, hemoptysis, and orthopnea. Like mitral stenosis, cor triatriatum may represent a great challenge in management of pregnancy and delivery⁷.

During the course of pregnancy, hormonally mediated changes result in an increase in red blood cell mass and heart rate⁸, and are thus associated with a 40% increase in blood volume and cardiac output⁹.

In this case, due to hemodynamic similarities, we decided to treat the cor triatriatum sinister like a moderate asymptomatic functional mitral stenosis. The patient routinely underwent controls once a month, when an echocardiogram was performed with measurements of pulmonary pressures and the gradient across the membrane orifice. She remained asymptomatic all the time, without any signs of heart failure and with normal NT-proBNP levels.

In this setting the left ventricle has increased afterload and limited preload due to cor triatriatum — a combination that tends to worsen the cardiac output. Prevention of tachycardia and atrial dysrhythmias is vital to ensure adequate left ventricular preloading along with avoiding sudden decrease in systemic vascular resistance, while the pulmonary capillary bed is extremely prone to pulmonary edema, especially during delivery. It is also important to avoid any increase in the central blood volume by extraneous administration of fluids. We decided to introduce a beta-blocker in order to extend the diastolic filling, but due to a relatively low systemic blood pressure, we also decided to refrain from giving a diuretic; instead we focused on water intake control. Literature also prefers cesarean section to vaginal delivery in such circumstances, but the gynecologist in charge chose the latter approach in agreement with the gravida, which took a normal course.

Conclusion

Along with clinical controls, regular echocardiographic controls have a central place in the follow up of gravida with congenital cardiac anomalies. To the best of our knowledge, this case is the first case of maternal cor triatriatum sinister in Croatia.