

## Drugačija reparacija mitralnoga zalistka u aktivnom endokarditisu i dugoročno praćenje pomoću transezofagealne ehokardiografije

### “Hinge” Mitral Valve Repair for Active Valve Endocarditis and Long-term Follow-up Transesophageal Echocardiography Study

Gokhan Arslan<sup>1\*</sup>,  
Ibrahim Alp<sup>2</sup>,  
Murat Ugur<sup>2</sup>,  
Alper Ucak<sup>2</sup>,  
Ahmet Turan Yilmaz<sup>2</sup>

<sup>1</sup>Vojna medicinska akademija Gulhane, Ankara, Turska  
[Gulhane Military Medical Academy, Ankara, Turkey](#)

<sup>2</sup>Vojna medicinska akademija Gulhane, Haydarpasa bolnica za obuku, Istanbul, Turska  
[Gulhane Military Medical Academy, Haydarpasa Training Hospital, Istanbul, Turkey](#)

RECEIVED:  
July 13, 2014  
UPDATED:  
July 23, 2014  
ACCEPTED:  
July 24, 2014



#### SAŽETAK:

**CILJEVI:** Liječenje mitralnog zalistka u endokarditisu zalistka izazovna je tema, a rekonstrukcija je poželjnija u odnosu na zamjenu, no često zahtijeva opsežan debridman vegetacije, inficiranoga tkiva i složenu rekonstrukciju tijekom aktivne faze.

**METODE:** Donosimo prikaz uspješne rekonstrukcije mitralnoga zalistka u pacijenta s aktivnim endokarditisom.

**REZULTATI:** Postoperativna ehokardiografija nije pokazala regurgitaciju na novoformiranom mitralnom zalistku.

**ZAKLJUČAK:** Reparacija mitralnoga zalistka perikardijanom zakrpom prvi je izbor liječenja aktivnog endokarditisa, koja je tehnički zahtjevna, no ima zadovoljavajuće rezultate. Rekonstrukcija mitralnog zalistka ovom metodom ne samo da podržava otvaranje područja mitralnih komisura, već i potpomaže ponovno uspostavljanje fiziološkoga kretanja mitralnoga zalistka.

#### SUMMARY:

**AIMS:** Mitral valve treatment in valve endocarditis is currently a challenging issue. Repair is preferred to replacement but it often requires extensive debridement of vegetation and infected tissue as well as complex reconstruction in the active phase.

**METHODS:** We report on a successful repair of the mitral valve, as described in the case of active endocarditis.

**RESULTS:** Postoperative echocardiography demonstrated no regurgitation at the newly formed mitral valve.

**CONCLUSION:** First preference is pericardial repair, a technically difficult procedure but with satisfactory results in mitral repair for active endocarditis. Reconstruction of the mitral commissure with this technique not only supports the opening of the commissural area but also helps regain the physiological motion of the mitral valve.

**KLJUČNE RIJEČI:** mitralni zalistak, endokarditis, kirurško liječenje.

**KEYWORDS:** mitral valve, endocarditis, surgical repair.

**CITATION:** *Cardiol Croat.* 2014;9(7-8):306-309.

**\*ADDRESS FOR CORRESPONDENCE:** Department of Cardiovascular Surgery, Gulhane Military Medical Academy, 06018 Etilik, Ankara, Turkey. / Phone: +90 312 304 52 14 / Fax: +90 312 304 27 00 / E-mail: [dr.gokhanarslan@gmail.com](mailto:dr.gokhanarslan@gmail.com)

**ORCID:** Gokhan Arslan, <http://orcid.org/0000-0001-6123-0457> • Ibrahim Alp, <http://orcid.org/0000-0002-3275-868X> • Murat Ugur, <http://orcid.org/0000-0002-1714-7813> • Alper Ucak, <http://orcid.org/0000-0003-1601-0740> • Ahmet Turan Yilmaz, <http://orcid.org/0000-0002-0338-0710>

#### Ciljevi

Akutni infekcijski endokarditis mitralnoga zalistka (MV) i dalje je složen problem. O postupcima alternativnoga liječenja još se uvijek raspravlja, a reparacija MV je prihvaćena kao poželjan način liječenja mitralne regurgitacije, osobito za slučajeve akutnog infekcijskog endokarditisa koji

#### Aims

Acute infective endocarditis of the mitral valve (MV) is still an intricate issue. Alternative treatment procedures are debatable, and MV repair is accepted as the procedure of choice for mitral regurgitation, especially in cases of acute infective endocarditis complicated by abscess for-

je kompliciran formiranjem apscesa, smetnjama u provodljivosti, novonastalim regurgitacijama zalistaka i bakterijemijom<sup>1</sup>. Prekomjerno oštećenje tkiva i prekomjerna resekcija može spriječiti jednostavno konvencionalno liječenje. Predstavljamo uspješno liječenje MV-a u slučaju aktivnog endokarditisa.

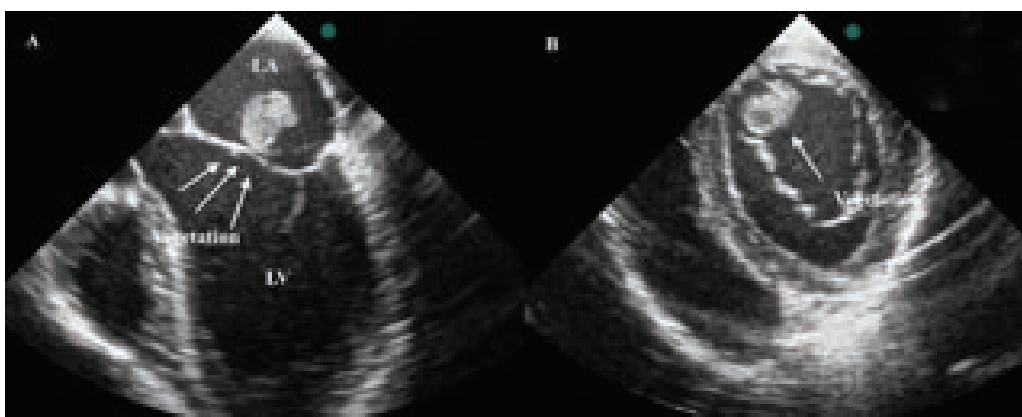
## Metode

23-godišnji pacijent bez prethodnih anamnestičkih podataka o sustavnoj ili lokalnoj infekciji upućen je iz kardiološke klinike s kontinuiranim febrilitetom i tresavicom. Fizikalni je pregled utvrdio sistolički šum 2-3/6. Ehokardiografija je pokazala veliku, mobilnu masu promjera do 24x15 mm na atrijalnoj površini posteriornoga listića mitralnog zalistka, u području posteromedialnoga dijela zalistka koji se nožicom proteže u atrijalni septum (**slika 1**). Postojala je mala mitralna regurgitacija. Višestruke hemokulture dokazale su prisutnost bakterije *Staphylococcus aureus*. Pacijentu je propisana terapija antibioticima, no i nakon prikladne terapije antibioticima pokazivao je znakove infekcije i veliku vegetaciju (>10 mm) te je upućen na operativno liječenje mitralnog zalistka<sup>2</sup>. Pacijent je podvrgnut općoj anesteziji. Pomoću transezofagealne ehokardiografije procijenjena je funkcija zalistka te je nakon toga obavljena medijalna sternotomija. Uspostavljen je izvantjelesni krvotok s bikavalnom venskom drenažom i uzlaznom aortom. Održana je umjerena sustavna hipotermija. Autologni je perikard odstranjen te umočen u otopinu glutaraldehida. Nakon stezanja aorte poprečnom obujmicom, primijenjena je retrogradna kardioplegija hladnom krvi te ostvaren srčani zastoj. Korišten je lijevi atrijalni rez za pristup mitralnom zalistku. Odstranjena je velika vegetacija na posteriornom i djelomično na anteriornom listiću mitralnoga zalistka, u području posteromedijalnoga dijela zalistka koji se nožicom proteže u atrijski septum (**slika 2**). Vegetacija nije utjecala na mitralni prsten. Dio perikardijalnoga sloja izrezan je da simulira odstranjeni segment zalistka te je pomoću kontinuiranih 4-0 prolipropilenskih šavova prišiven na rub listića, mitralni prsten i endokard lijeve pretklijetke. Dodatni su šavovi stavljeni da bi se pojačala rekonstruirana veza i zakrpao niz šavova na mitralnom prstenu koji je prilagođen da bi se omogućilo kretanje mitralnoga zalistka kao kutnoga zgloba (**slika 2B**). Zatvaranje atriotomije, odstranjivanje zraka i dekanulacija obavljena su standardnom metodom.

tion, conduction disturbances, new valvular regurgitation, and bacteremia<sup>1</sup>. Excessive tissue damage and extensive resection, on the other hand, may prevent simple conventional repair. We present a successful repaired MV as described in the case of active endocarditis.

## Methods

A 23-year-old patient with no previous history of systemic or local infection was referred with continuous fever and chills from a cardiology clinic. Physical examination revealed a 2–3/6 systolic murmur. Echocardiography demonstrated a large, mobile mass up to 24x15 mm in diameter on the atrial surface of posterior leaflet of the mitral valve, in the region of the posteromedial part of the valve extending into the atrial septum with a pedicle (**Figure 1**). The patient had mild mitral regurgitation. Multiple blood cultures demonstrated *Staphylococcus aureus*. Antibiotic therapy was started, but an operation to repair of the mitral valve was decided on because of the persistent signs of infection despite appropriate antibiotic coverage and large (>10 mm) vegetation<sup>2</sup>. The patient was placed under general anesthesia. Transesophageal echocardiography was performed to evaluate valvular function, followed by a median sternotomy. Cardiopulmonary bypass was established with bicaval venous drainage and an ascending aorta. Moderate systemic hypothermia was managed. Autologous pericardium was harvested and soaked in glutaraldehyde solution. After aortic cross-clamping, retrograde cold blood cardioplegia was applied and cardiac arrest was obtained. A left atrial incision was used to approach the mitral valve. Large vegetation on the posterior and partially anterior leaflet of mitral valve, in the region of the posteromedial part of the valve extending into atrial septum with a pedicle, was excised (**Figure 2**). The vegetation did not affect the mitral annulus. A piece of pericardial patch was cut to stimulate the excised valve segment and was sutured in place using continuous 4-0 polypropylene sutures to the rim of the leaflets, the mitral annulus, and the left atrium endocardium. An additional suture was placed to reinforce the reconstructed commissure, and patched suture line of the mitral annulus was adapted to permit movement of the mitral valve as a hinge (**Figure 2B**). Atriotomy closure, deairing, and decannulation were done in the standard way.



**FIGURE 1.**

**Four-chamber (A) and short-axis (B) views of transesophageal echocardiography showing large vegetation (white arrows) on the mitral valve (MV).**

LA = left atrium;  
LV = left ventricle.

FIGURE 2.

Illustration of vegetation sited in the posteromedial commissure of the mitral valve (A); debridement of the infected parts of leaflets and vegetation; the defect was repaired with a piece of pericardial patch sutured in place to the rim of the leaflets, the mitral annulus, and the left atrium endocardium. An additional suture was placed to strengthen the commissure and patched suture line of the mitral annulus was adapted to permit movement of the mitral valve as a hinge (B).

author of the illustration: Dr Ibrahim Alp.

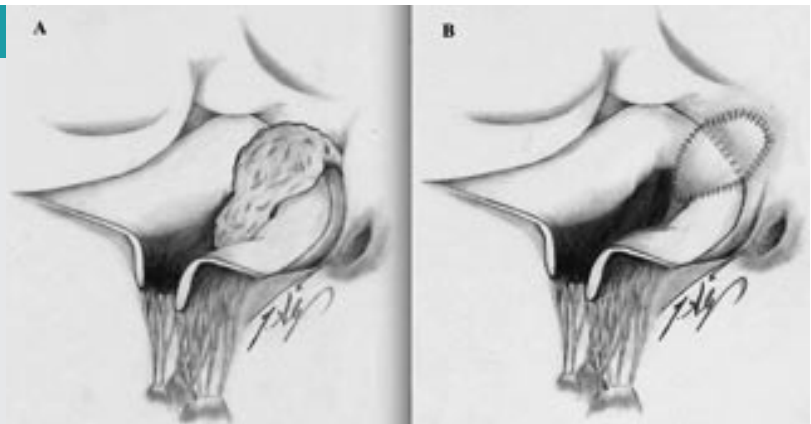


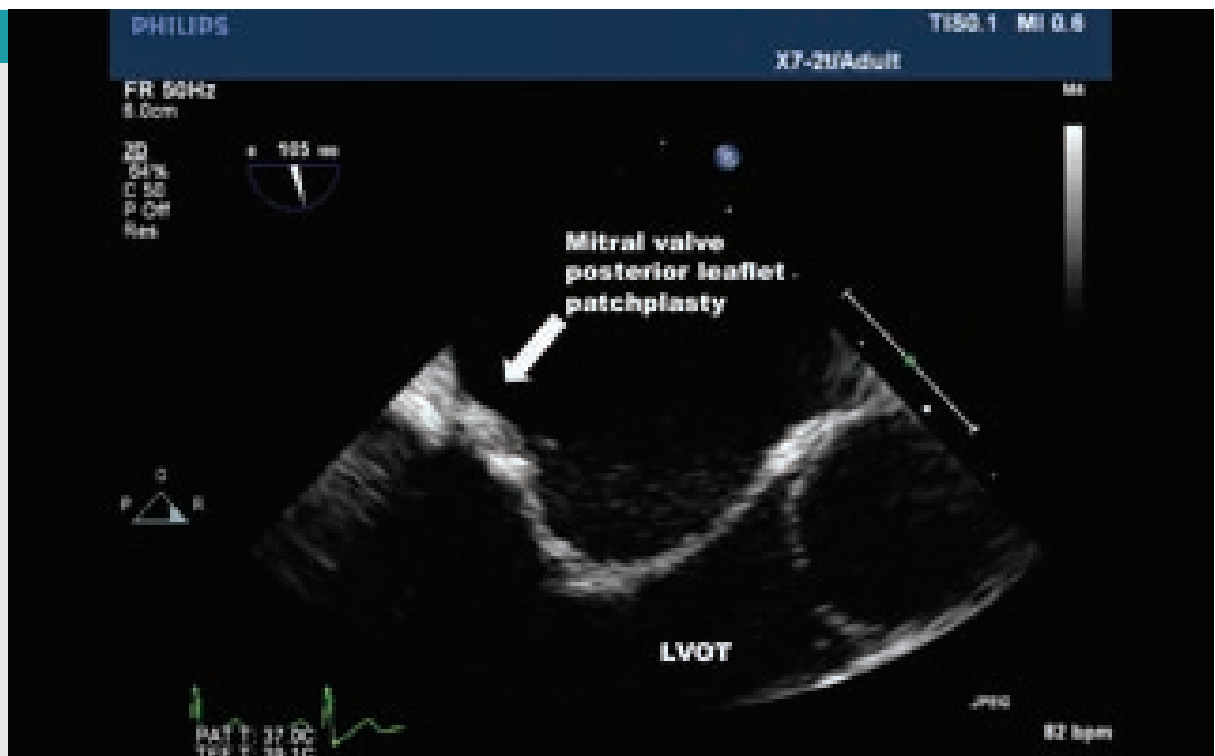
FIGURE 3.

Postoperative views of transesophageal echocardiography, mitral leaflet tethering in the parasternal long-axis (A) and short-axis (B) 2D views in midsystole (white arrows).

MV = mitral valve;  
LA = left atrium;  
LV = left ventricle.

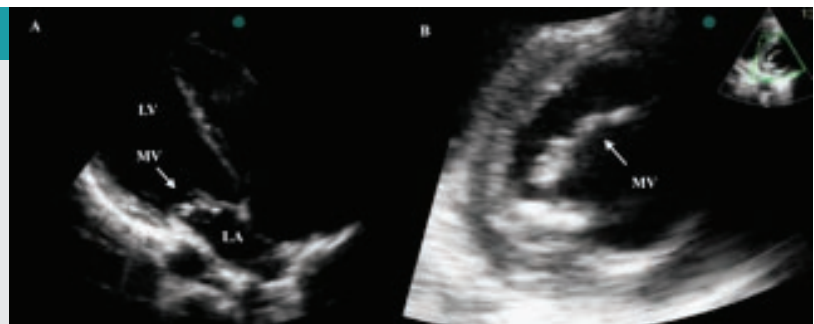

FIGURE 4.



24-month follow-up view of transesophageal echocardiography, mitral valve posterior leaflet, and patchplasty 2D view in midsystole (white arrow).

LVOT = left ventricular outflow tract.

## Rezultati

Postoperativna ehokardiografija pokazala je da na novostvo-  
renom mitralnom zalistku ne dolazi do regurgitacije (**slika 3**).  
Tijekom postoperativnog tretmana nije bilo nikakvih proble-  
ma te je pacijent pušten iz bolnice 14. dan nakon operacije.  
Tijekom pregleda 24 mjeseca nakon operacije nisu uočeni  
simptomi (**Video 1** – samo na mrežnoj stranici časopisa [http://  
youtu.be/6WhVsjP\\_DLM](http://youtu.be/6WhVsjP_DLM); **slika 4**). Nije uočen ni povratak regurgi-  
tacije niti ponovna infekcija mitralnoga zalistka nakon ope-  
racije.

## Zaključak

Liječenje mitralnog zalistka u endokarditisu zalistka je iza-  
zovna tema. Zabilježeno je nekoliko serija i različitih meto-  
da rekonstrukcije MV u infektivnom endokarditisu, a svi su  
pokazali povoljne rane i kasne rezultate te tako potkrjepljuju  
hipotezu da je rekonstrukcija mitralnoga zalistka pogodna  
za te pacijente<sup>3,4</sup>. U nekim slučajevima, opsežan debridman  
zahtijeva kompleksnu rekonstrukciju MV i aparata MV. Potre-  
bno je biti oprezan u liniji šavova velikih područja nakon op-  
sežne resekcije listića s aktivnom upalom, jer može doći do  
postoperativne dehiscencije šavova<sup>5</sup>. Opisani su operativni  
zahvati očuvanja mitralnog zalistka pomoću anularne pli-  
kacije i zakrpa za anularne upale s ograničenim oštećenjem  
listića<sup>6</sup>.

Kod metode koju smo opisali lakše je rekonstruirati mitral-  
no ušće; metoda može biti indicirana za pacijente kojima je  
potrebna resekcija samo na području ušća koje uključuje late-  
ralne polukružne rubove te prednje i stražnje mitralne listiće,  
kao što je opisano u ovog pacijenta.

U zaključku, smatramo da je prvi izbor perikardijalna re-  
konstrukcija, koja je tehnički zahtjevan postupak sa zado-  
voljavajućim rezultatima u rekostrukciji mitralnoga zalistka  
kod aktivnog endokarditisa. Rekonstrukcija mitralne komi-  
sure tom metodom ne samo da podržava otvaranje komisu-  
ralnoga područja već i pomaže pri ponovnom uspostavljanju  
fiziološke pokretljivosti mitralnoga zalistka.

## Results

Postoperative echocardiography demonstrated no regurgita-  
tion at the newly formed mitral valve (**Figure 3**). The patient  
had an uneventful postoperative course and was discharged  
from the hospital on postoperative day 14. He was symptom  
free at his 24-month follow-up (**Movie 1** – journal webpage  
only [http://youtu.be/6WhVsjP\\_DLM](http://youtu.be/6WhVsjP_DLM); **Figure 4**). There was no relapse  
of regurgitation or reinfection of the mitral valve after opera-  
tion.

## Conclusion

Mitral valve treatment in valve endocarditis is currently a  
challenging issue. A few case series and different techniques  
of MV repair for infective endocarditis have been reported,  
and all have shown favorable early and late outcomes, sup-  
porting the view that mitral valve repair is suitable in these  
patients<sup>3,4</sup>. In some cases, extensive debridement requires  
complex reconstruction of the MV and MV apparatus. Severe  
caution is required regarding the suture lines of large patches  
after extensive resection of leaflets that may have active in-  
flammation, because postoperative suture dehiscence could  
ensue<sup>5</sup>. Mitral valve conserving surgery by annular plication  
and patching for annular inflammations with limited leaflet  
damages has been reported as well<sup>6</sup>.

In this technique, repairing the mitral commissure is easier  
and can be indicated for patients who require resection within  
the only commissural area involving lateral scallops of both  
anterior and posterior leaflets, as in our case.

In conclusion, we believe that first preference should be  
pericardial repair, a technically difficult procedure but with  
satisfactory results in mitral repair for active endocarditis.  
Reconstruction of the mitral commissure with this tech-  
nique not only supports the opening of the commissural area  
but also helps regain the physiological motion of the mitral  
valve.

### SUPPLEMENTARY DATA (web only)

**MOVIE 1.** 24-month follow up movie of transesophageal echocardiography. Color Doppler image shows that there is no leakage and a well-functioning mitral valve. [http://youtu.be/6WhVsjP\\_DLM](http://youtu.be/6WhVsjP_DLM)

### LITERATURE

1. Feringa Harm HH, Shaw Leslee J, Poldermans D, et al. Mitral valve repair and replacement in endocarditis: a systematic review of literature. *Ann Thorac Surg.* 2007;83:564-71.
2. Hill E, Herijgers P, Herregods M, et al. Evolving trends in infective endocarditis. *Clin Microbiol Infect Dis.* 2006;12:5-12.
3. Dreyfus G, Serraf A, Jebara VA, et al. Valve repair in acute endocarditis. *Ann Thorac Surg.* 1990; 49:706-13.
4. Hendren WG, Morris AS, Rosenkranz ER, et al. Mitral valve repair for bacterial endocarditis. *J Thorac Cardiovasc Surg.* 1992;103:124-9.
5. Tadashi Omoto, Takeo Tedoriya, Masaya Oi, et al. Significance of mitral valve repair for active-phase infective endocarditis. *Asian Cardiovasc Thorac Ann.* 2011;19:149-53.
6. David TE, Feindel CM, Armstrong S, Sun Z. Reconstruction of the mitral annulus. A ten-year experience. *J Thorac Cardiovasc Surg.* 1995;110:1323-32.