

Torakalni endovaskularni postupak postavljanja aortnog stent-grafta u Kliničkom bolničkom centru Zagreb: deset godina od prve intervencije, problemi i rezultati

Thoracic EndoVascular Aortic Repair in the University Hospital Centre Zagreb: Ten Years since the First Intervention, Problems and Results

Maja Strozzi*

Medicinski fakultet Sveučilišta u Zagrebu, Klinički bolnički centar Zagreb, Zagreb, Hrvatska

University of Zagreb School of Medicine, University Hospital Centre Zagreb, Zagreb, Croatia

RECEIVED:
June 1, 2015

UPDATED:
June 11, 2015

ACCEPTED:
June 13, 2015



SAŽETAK: Torakalni endovaskularni postupak postavljanja aortnog stent-grafta (TEVAR) razvijen je isprva za postupke okluzije degenerativnih aneurizmi descendentne aorte, a uskoro se proširio na cijeli spektar patologije ovog aortnog segmenta, uključujući disekcije i traumatske rupture. Kirurško rješavanje ove patologije ima iznimno visok mortalitet i morbiditet te je TEVAR znatno poboljšao liječenje ovakvih bolesnika. U Kliničkom bolničkom centru (KBC) Zagreb upravo se zbog toga započelo s postupkom u okviru Klinike za bolesti srca i krvnih žila, i unatoč poteškoćama, metodom su liječeni najrizičniji bolesnici s aneurizmom, disekcijom tipa B i traumatskom rupturom descendentne aorte. Dugoročni su rezultati liječenja 24 bolesnika prihvatljivi, uz mortalitet od 8,3 % te uobičajene komplikacije (propuštanje tipa I. i II. u 12,5 %; infekcija u 4,1 %; proksimalno proširenje disekcije 4,1 %) koje su riješene dodatnom intervencijom ili operacijom. U budućnosti očekujemo mnogo brži razvoj metode u KBC-u Zagreb, ali i u Hrvatskoj općenito, nakon što je Hrvatski zavod za zdravstveno osiguranje riješio financiranje uređaja.

SUMMARY: Thoracic EndoVascular Aortic Repair (TEVAR) was initially developed for occlusion procedures in treatment of diseases of the descending aorta, but its use was soon expanded to a whole spectrum of pathologies of this aortic segment, including dissection and traumatic ruptures. Surgical treatment of degenerative aneurysms of the descending aorta has a very high mortality and morbidity, so TEVAR leads to significantly improved outcomes for these patients. This is the reason the University Hospital Centre (UHC) Zagreb introduced the use of this procedure in the Department of Cardiovascular Diseases. Despite difficulties, TEVAR was used to treat the most at-risk patients with aneurysms, type B dissection, and traumatic rupture of the descending aorta. Long-term results of the treatment of 24 patients were acceptable, with a mortality of 8.3% and common complications (type I and II endoleaks in 12.5%; infection in 4.1%; proximal dissection propagation in 4.1%) which were resolved with an additional intervention or surgical procedure. In the future we expect much more rapid development of this method in UHC Zagreb and in Croatia in general once the Croatian Health Insurance Fund has arranged financing for the device.

KLJUČNE RIJEČI: torakalna aorta, endovaskularni postupak, stent-graft, aneurizma, disekcija, vaskularni pristup.

KEYWORDS: thoracic aorta, endovascular procedure, stent grafting, aneurysm, dissection, vascular approach.

CITATION: *Cardiol Croat.* 2015;10(5-6):141–147. | DOI: <http://dx.doi.org/10.15836/ccar.2015.141>

*ADDRESS FOR CORRESPONDENCE: Maja Strozzi, Klinički bolnički centar Zagreb, Kišpatičeva 12, HR-10000 Zagreb, Croatia. / Phone: +385-1-2367-508 / E-mail: maja.strozzi@gmail.com

ORCID: Maja Strozzi, <http://orcid.org/0000-0003-4596-8261>

UVOD

Prošlo je više od 20 godina od prve objave upotrebe stent-grafta u liječenju aneurizme torakalne aorte u pacijenta s vrlo visokim rizikom za operacijski zahvat¹. Taj se zahvat, poznat pod imenom TEVAR (engl. *Thoracic EndoVascular Aortic Repair*), ubrzo pokazao efikasnim i sigurnim, a u usporedbi s kirurškim postupkom imao je manji

INTRODUCTION

More than 20 years have passed since the first report of using stent grafting to treat an aneurysm in the thoracic aorta in a patient with high surgical risk¹. This procedure, known as TEVAR (*Thoracic EndoVascular Aortic Repair*) was soon shown to be efficient and safe, with lower morbidity and mortality rates than surgical intervention.

mortalitet i morbiditet. Danas imamo na raspolaganju komercijalno dostupne torakalne stent-graftove, a nakon objave prvih studija dokazana je prednost ove tehnike u odnosu prema kirurgiji: mortalitet 2,1% prema 11,7%, ishemija leđne moždine 3% prema 14%, uz višestruko manje pojave respiratorne i renalne insuficijencije². Ubrzo nakon intervencija kod aneurizme, stent-graft se počeo implantirati i u slučajevima disekcije aorte tipa B³. U usporedbi s konzervativnim liječenjem ova je metoda poboljšala preživljenje u petogodišnjem praćenju (6,9% prema 19,3%)⁴. Kao i svaka nova metoda bila je povezana s određenim novim komplikacijama, perioperativno najčešće vezanima za vaskularni pristup, a dugoročno zbog pojave nepotpuna isključenja aneurizme ili disekcije, čiji rezultat može biti i njihova progresija. Stoga su nakon TEVAR postupka preporučene dugoročne kontrole. Broj je takvih postupaka u ovih dvadesetak godina dramatično rastao, a zbog sve bolje tehnike implantacije i unapređenja uređaja, danas je, kad god je to moguće, praktično zamijenio kirurški pristup u bolestima descendente aorte⁵.

INDIKACIJE I KONTRAINDIKACIJE

Idealan pacijent za torakalni stent-graft imao bi sljedeće karakteristike:

- aneurizmu, a ne disekciju
- mogućnost postavljanja stent-grafta distalno od lijeve potključne arterije, po mogućnosti da je ne pokriva
- mogućnost postavljanja proksimalno od celijačnog trunkusa
- dobar vaskularni pristup
- prisutnost adekvatnog proksimalnog i distalnog „vrata“ za postavljanje u „zdravo“ tkivo
- odsutnost tromba i minimalna prisutnost kalcija.

Postupak se u većini slučajeva provodi na manje idealnim pacijentima te su time određeni i uspjeh i komplikacije.

TEVAR koji je inicijalno razvijen za liječenje degenerativnih aneurizmi, a zatim i disekcija descendente aorte, našao je indicaciju i u cijelom spektru patologije aorte, osobito u području ekstenzivne traumatske ozljede, gdje se metoda pokazala mnogo manje invazivnom i rizičnom^{6,7}.

Iako je katkad primijenjena i u bolesnika s mikotičnim aneurizmama te u bolesnika sa sustavnim bolestima veziva (Marfanov sindrom), ovakvi pacijenti nisu bili uključeni u randomizirane studije te je općenito prihvaćeno da su nepovoljni za TEVAR postupak zbog očekivanih komplikacija⁸. Također za taj postupak nisu pogodni bolesnici s perifernom vaskularnom bolesti ili neadekvatnim vaskularnim pristupom, kao i aneurizme čija bi ekskluzija okludirala značajne (cerebralne) arterije.

TEHNIKA

Intervencija se planira nakon analize MSCT aortografije koja je ključna dijagnostička metoda za indiciranje i praćenje ovakvih bolesnika. Određuje se promjer femoralne arterije (najčešći vaskularni pristup) te provode točna mjerenja proksimalnog i distalnog „vrata“, prema čemu se određuju dimenzije uređaja.

Today, thoracic stent grafts are commercially available, and studies have shown the superiority of this technique compared with surgery: mortality 2.1% compared with 11.7%, spinal cord ischemia 3% vs. 14%, and several times less common respiratory and renal insufficiency². Soon after being introduced as an aneurysm treatment, stent grafts started being used in cases of aortic dissection type B³. In comparison with conservative treatments, this method had better five-year survival rates (6.9% vs. 19.3%)⁴. As any new method, there were new complications associated with it. Perioperatively, they were mostly associated with the vascular approach, and in the long term because of incomplete exclusion of the aneurysm or dissection, which can result in disease progression. Consequently, long-term follow-up is recommended after TEVAR procedures. The number of these procedures being performed worldwide has grown dramatically over the last twenty years, and has now practically replaced, whenever possible, the surgical approach for diseases of the descending aorta due to constant improvements to the implantation technique and the device itself⁵.

INDICATIONS AND CONTRAINDICATIONS

The ideal patient for thoracic stent grafting would have the following characteristics:

- An aneurysm, not a dissection,
- The possibility of implanting the stent graft distally from the left subclavian artery, without covering it if possible,
- The possibility of implanting proximally from the celiac trunk,
- Good vascular access,
- The presence of an adequate proximal and distal “neck” for implantation in “healthy” tissue, and
- No thrombi and minimal presence of calcium.

The procedure is usually performed on patients less ideally suited to it, affecting the chances of success and complications.

TEVAR, initially developed to treat degenerative and later dissection of the descending aorta as well, is now indicated for a wide spectrum of aortic pathologies, especially in extensive traumatic injuries where this method has shown itself to be much less invasive and risky^{6,7}.

Although it is sometimes also used in patients with mycotic aneurysms and in patients with systemic connective tissue disease (Marfan syndrome), these patients were not included in randomized studies, and it is widely accepted that TEVAR is not appropriate in such cases due to expected complications⁸. Patients with peripheral vascular diseases or inadequate vascular approach are not suited to the procedure, nor are cases in which aneurysm exclusion would occlude important (cerebral) arteries.

TECHNIQUE

The intervention is planned using multislice computed tomography (MSCT) angiography, which is a key diagnostic tool for diagnosis and monitoring of these patients. The radius of the femoral artery needs to be determined (usually the vascu-

Procedura se najčešće izvodi u općoj anesteziji u radiološkoj sali za angiografiju. Standardnim perkutanom postupkom uvede se kateter u ascendentnu aortu za angiografsko praćenje, a zatim se ili perkutanom postupkom uz kasniju upotrebu posebnih vaskularnih „zatvarača“, ili nakon kirurške preparacije odabranoga vaskularnog pristupa, uvodi stent-graft, premontiran na sistem za otpuštanje preko vrlo tvrde žice vodilice, pažljivo pozicionira i otpusti (**slika 1**). U nekim slučajevima, osobito kod okluzija aneurizmi, može se nakon otpuštanja grafta učiniti balonska dilatacija radi bolje apozicije. Ovaj postupak treba izbjegavati kod disekcije.

KOMPLIKACIJE

Već spomenute komplikacije najčešće uključuju oštećenje periferne vaskulature zbog velikih dimenzija uređaja (14%), neurološke komplikacije, kao što su ishemijski moždani udar (4%), parapareza/paraplegija (3%), a moguć je i smrtni ishod (2%)⁸.

Problem je i nepotpuno isključenje aneurizme, odnosno „propuštanje“ (engl. *endoleak*), koji se, s obzirom na ishodište, dijele na 4 tipa:

- *tip I.* označuje situaciju propuštanja na proksimalnom ili distalnom kraju grafta (**slika 2**)
- *tip II.* pojavljuje se u slučaju povratnoga krvarenja iz manjih krvnih žila, pokrivenih graftom
- *tip III.* pojavljuje se u slučaju postavljanja više od jednog grafta, na mjestu njihova preklapanja
- *tip IV.* je rijedak i nastaje zbog poroznosti grafta.

lar approach), and exact measurements of the proximal and distal “neck” are conducted, which determine the dimensions of the device.

The procedure is usually conducted under general anesthesia in a radiology angiography theater. A standard percutaneous procedure is used to introduce a catheter into the ascending aorta for angiographic monitoring, and a stent graft is then introduced either using a percutaneous procedure with later use of a vascular occlusion device, or, or after surgical preparation of the chosen vascular approach. The stent graft pre-attached to a release system, is then introduced over a very hard leading wire, carefully positioned, and released (**Figure 1**). In some cases, especially for occluded aneurysms, the release of the graft can be followed with a balloon dilatation to achieve better apposition. This should be avoided in cases of dissection.

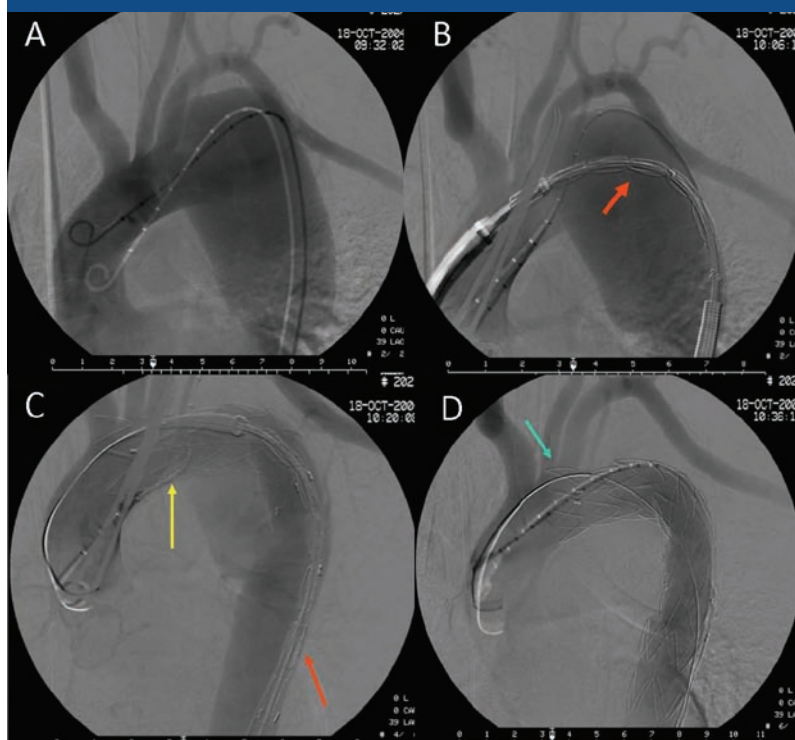
COMPLICATIONS

The abovementioned complications most commonly include damage to the peripheral vasculature due to the large dimensions of the device (14%), neurological complication such as ischemic stroke (4%), paraparesis/paraplegia (3%), and even death (2%)⁸.

Incomplete exclusion of the aneurysm, i.e. endoleaks, can be a problem as well and are divided into 4 types depending on the point of origin:

- *Type I* denotes leaks at the proximal or distal end of the graft (**Figure 2**),

FIGURE 1.

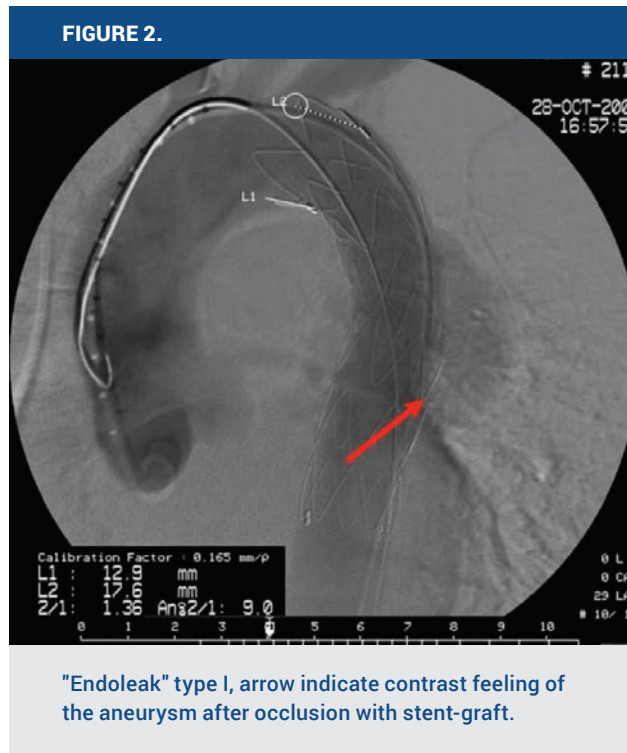

A) Angiographic presentation of descending aortic aneurysm.

B) Stent-graft positioning before deployment (red arrow).

C) Partially deployed stent-graft (yellow arrow – proximal stent-graft end, red arrow – aneurysm steel feeling with contrast in the distal, non-expanded end of the stent-graft).

D) Complete aneurysm occlusion, left subclavian and partially left carotid artery covered with the uncovered part of the stent (green arrow).



Propuštanje se može pojaviti rano ili kasnije tijekom praćenja. Utječe na daljnje širenje aneurizme i zato ga je potrebno riješiti endovaskularnim postupkom, ako je moguće, ili operacijom⁹.

POČETAK PROGRAMA TEVAR U KLINIČKOM BOLNIČKOM CENTRU ZAGREB

TEVAR je u svijetu najčešće u djelokrugu rada vaskularnih kirurga, intervencijskih radiologa, ali i kardiologa. U Kliničkom bolničkom centru (KBC) Zagreb s metodom smo započeli upravo u okviru Klinike za bolesti srca i krvnih žila, i to zbog sljedećih razloga: ovakvi se pacijenti obraćaju upravo nama, od nas se očekuje rješenje za njihovo kompleksno zdravstveno stanje, njihov je kirurški mortalitet visok, a kao intervencionalisti velikog volumena imali smo raspoložive resurse i vještinu, osobito zato što takve bolesnike nitko drugi nije htio riješiti.

Prvu smo intervenciju izveli 18. listopada 2004. godine uz pomoć proktora (prof. dr. Josip Mašković) u mladog bolesnika s postraumatskom aneurizmom descendente aorte.

Tijekom sljedećih 10 godina susretali smo se s nizom problema. Izdvojila bih poteškoće s organizacijom tima, iako je uvijek postojala dobra volja kolega drugih struka (uz osoblje Laboratorija za intervencijsku kardiologiju, nužan je anesteziološki i kirurški tim), nepostojećim budžetom za takve postupke te su se oni mogli izvoditi samo povremeno na račun budžeta za koronarne intervencije. U prvim godinama imali smo potpuno neadekvatan prostor i aparaturu za takvu vrstu postupaka. Kao kardiolozi imali smo poteškoća s analizom MSCT nalaza. Manjak interesa za održavanje i unapređenje metode pokazale su sve uprave KBC-a Zagreb u tom razdoblju,

- *Type II* appears in cases of retrograde hemorrhage from small blood vessels covered by the graft,
- *Type III* appears when several grafts are implanted, at the point of their overlap,
- *Type IV* is rare and is caused by porousness of the graft.

Leaks can appear early or later during the follow-up. They affect further progression of the aneurysm and should therefore be resolved with an endovascular procedure, if possible, or with a surgical intervention⁹.

STARTING THE TEVAR PROGRAM IN THE UNIVERSITY HOSPITAL CENTRE ZAGREB

Internationally, TEVAR procedures are generally performed by vascular surgeons and interventional radiologists, but cardiologists as well. In the University Hospital Centre (UHC) Zagreb we started using this method in the Department of Cardiovascular Diseases, for the following reasons: patients suitable for the procedure are referred to us, and we are expected to treat their complex health issues; their surgical mortality is high, and as interventionists dealing with a high volume of patients we had the resources and skills required, especially since no one else wanted to treat these patients.

The first intervention was performed on October 18, 2004, with the help of the proctor (Prof Josip Mašković, MD) on a young patient with posttraumatic aneurysm of the descending aorta.

We faced a number of problems over the next 10 years. Notably, we had difficulties organizing the team, despite the willingness of colleagues from other fields (in addition to the personnel of the Laboratory for Interventional Cardiology, a team of anesthesiologists and surgeons are needed as well) and a non-existent budget for such procedures, which meant that we could perform the procedures only intermittently using the budget for coronary interventions. During the first years, our premises and equipment were completely inadequate for this type of procedures. As cardiologists, we struggled with MSCT image analysis. A lack of interest from all administration groups of the UHC Zagreb for support and improvement in the method was evident in that period, likely due to the procedure not being subsidized by the Croatian Health Insurance Fund. During this period, we tried to draw attention to the fact that the high price of the graft at 55 000 HRK is insignificant compared with the prices of surgery that are several times larger, even for the most optimistic outcomes with no complications, which are very rare with these types of surgeries.

RESULTS

Over a period of ten years, 26 stent grafts were implanted into the thoracic aorta of 24 patients in the Zagreb Clinical Hospital Center. The most common indication for the procedure was dissection type B (11 patients), and the other cases included 5 patients with posttraumatic aneurysm, 3 patients with atherosclerotic aneurysm in the thoracic aorta, and 5 patients with acute traumatic dissection at the usual site. Considering the low number of procedures over a large amount of time, and as a result of inadequate resources, the learning curve

vjerojatno zbog nemogućnosti naplate skupog postupka od Hrvatskog zavoda za zdravstveno osiguranje (HZZO). U tom smo razdoblju pokušali upozoriti na to da je ta visoka cijena grafta od 55.000,00 kn neznatna u usporedbi s troškovima koje donosi kirurgija, i koji su višestruko viši, čak i u najoptimističnijem scenariju, bez komplikacija, što je u ovoj vrsti operacija iznimno rijetko.

REZULTATI

U deset godina u KBC-u Zagreb implantirano je 26 stent-graftova u torakalnu aortu u 24 bolesnika. Najčešća je indikacija bila disekcija tipa B (11 bolesnika), a od ostalih indikacija ugrađena je u 5 pacijenata s posttraumatskom aneurizmom, u 3 pacijenta s aterosklerotskom aneurizmom torakalne aorte te u 5 pacijenata s akutnom traumatskom disekcijom na tipičnom mjestu. S obzirom na mali broj provedenih postupaka u dugom razdoblju, što je bio rezultat nedostatka sredstava, krivulja učenja bila je vrlo duga, no unatoč tomu rezultati su bili dobri uz uobičajenu učestalost i vrstu komplikacija.

Perioperativne komplikacije. U jednog bolesnika postupak nije uspio zbog problema pri uvođenju grafta zbog jako izraženih kalcifikata u području abdominalne aorte i perifernih arterija. Kod jednog bolesnika imali smo komplikaciju nakon perkutanog zatvaranja vaskularnog pristupa, što je riješeno kirurški. To je bila i jedina vaskularna komplikacija koju smo imali. Najveća je komplikacija bila migracija grafta tijekom provođenja postupka, što je riješeno dodatnim uređajem.

Rane komplikacije. U jednog je bolesnika došlo do retrogradne disekcije u ascendentnu aortu. Pacijent je bio bez značajnih tegoba, a nalaz je utvrđen na prvom kontrolnom MSCT-u 48 sati nakon uspješne intervencije. Pacijent je uspješno transportiran i operiran u inozemstvu (odbijen je od kardiokirurškog tima naše bolnice zbog manjka iskustva u takvim postupcima). Ni u jednog se bolesnika nije prezentirala parapareza ili paraplegija, kao ni cerebrovaskularni incident!

Kasne komplikacije i dugoročni rezultati. U jednog bolesnika razvila se infekcija grafta, zbog čega je uspješno operiran u inozemstvu (ekstrakcija grafta i ugradnja homografta). Tijekom praćenja dva su bolesnika umrla, jedan godinu dana nakon postupka, u vrijeme uvođenja u anesteziju prije planiranoga kardiokirurškog zahvata, nepovezanog s TEVAR-om. U tom se slučaju ne može isključiti ruptura aorte (opisana na obdukciji nakon ekscesivne masaže u tijeku reanimacije). Drugi je pacijent umro četiri godine nakon procedure od zloćudne bolesti (**slika 3**).

PROPUŠTANJE

U jednog smo bolesnika imali periintervencijsko propuštanje tipa I. te postavili dodatni stent-graft. Kod jedne bolesnice na kraju postupka zaostao je vrlo veliki „leak“ tipa II., koji je riješen u drugom postupku postavljanjem zatvarača (Amplazer „occluder“) u lijevu potključnu arteriju (**slika 4**). Najveći smo problem imali kod bolesnice koja je nakon intervencije zbog akutne disekcije tipa B, imala minimalno propuštanje tipa II., koje smo pokušali riješiti postavljanjem spirala, no poslije je propuštanje napredovalo i razvila se velika aneurizma. Posri-

was very long; despite these problems the results were good, with expected frequency and type of complications.

Perioperative complications. The procedure was not successful in one of the patients due to problems in the introduction of the graft due to significant calcification in the area of the abdominal aorta and the peripheral arteries. A patient experienced a complication after percutaneous closure of the vascular approach, which was surgically resolved. This was the only vascular complication we experienced. The most significant complication was a migration of the graft during the procedure, which was resolved with an additional device.

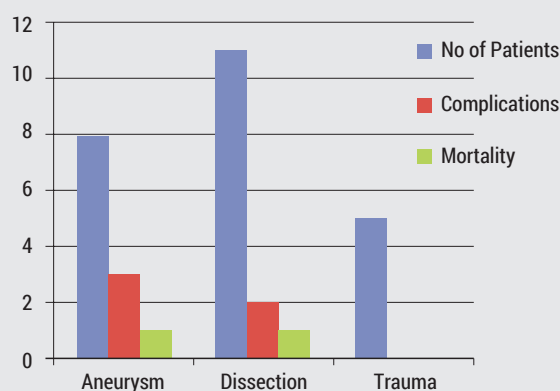
Early complications. One patient experienced retrograde dissection in the ascending aorta. The patient experienced no significant issues, and the diagnosis was made during the first MSCT follow-up within 48 hours of the successful procedure. The patient was successfully transported and underwent surgery abroad (the cardiosurgical team in our hospital refused the referral due to the lack of experience in such procedures). None of our patients presented with paraparesis, paraplegia, or cerebral incidents.

Late complications and long-term results. One patient developed graft infection, which was successfully resolved by a surgical procedure abroad (graft extraction and homograft implantation). Two patients died during follow-up, one a year after the procedure during anesthesia before an unrelated cardiosurgical procedure. It is impossible to rule out an aortic rupture as the cause (described in the autopsy, possible as the result of excessive pressure during reanimation). The other patient died four years after the procedure as a result of a malignant disease (**Figure 3**).

LEAKS

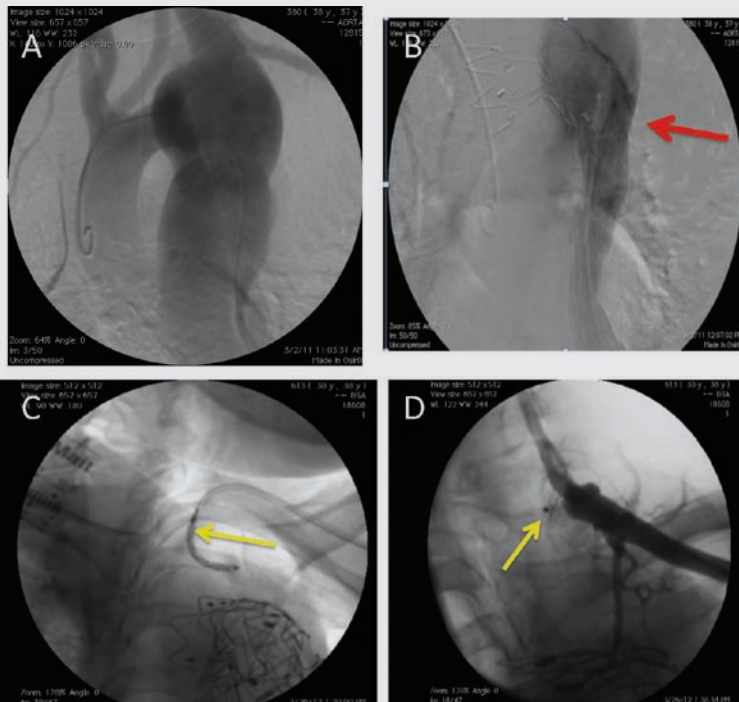
One patient experienced a type I periinterventional leak, which was resolved with an additional stent graft. In a single female patient, a very large type II leak remained after the procedure,

FIGURE 3.



Number of patients according to indication, early and late complication and mortality.

FIGURE 4.



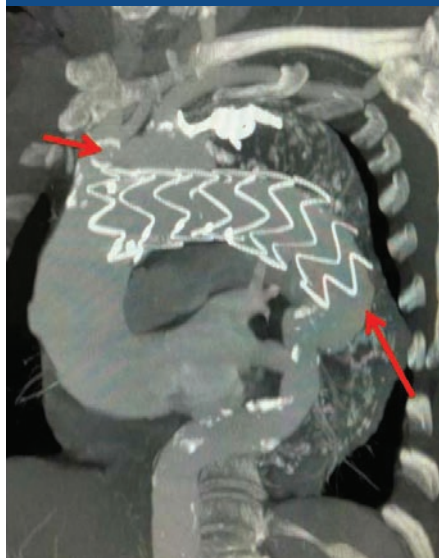
- A)** Thoracic aorta aneurysm including left subclavian artery.
B) After stent-graft deployment, continued contrast feeling of the aneurysm from the dilated subclavian artery (Type II «endoleak»).
C) and **D)** Before and after occlusion of subclavian artery with the «occluder» (amplazer device pointed with yellow arrow).

jedi je bila kombinacija tipa I. i II. i jedina moguća metoda liječenja jest kompleksan hibridni zahvat koji uključuje veliki kirurški zahvat proksimalnog dijela aneurizme te dodatni endovaskularni postupak distalno (slika 5).

TEVAR U TRAUMATSKOJ DISEKCIJI

Tijekom posljednje četiri godine TEVAR postupak proveden je u pet politraumatiziranih bolesnika (31 – 55 godina). U svim slučajevima riječ je bila o prometnim nesrećama, a ruptura aorte nađena je tijekom obrade na kompjutoriziranoj tomografiji. Svi su postupci bili uspješni i očekivano su prošli bez ranih i kasnih komplikacija (slika 6). U ovoj, za život izrazito opasnoj situaciji, nakon uspješnoga TEVAR postupka, preživljenje u prvom redu ovisi o ishodu drugih ozljeda. U našem slučaju svi su se bolesnici oporavili.

FIGURE 5.



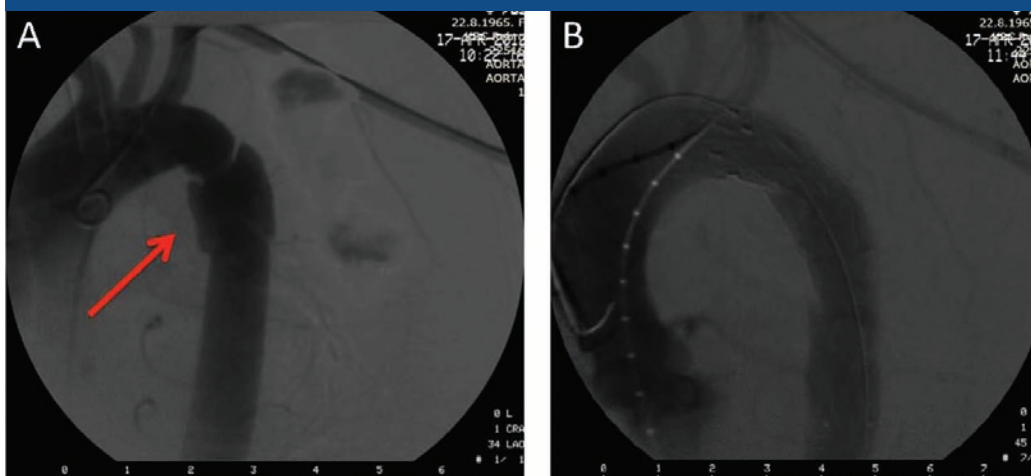
MSCT aortography of a patient with progression of aneurysm 9 years after procedure, caused by «endoleaks» type I and II.

which was resolved with an Amplazer occluder in the left subclavian artery (Figure 4). The most significant problem appeared in a single female patient after intervention for acute dissection type B. We tried to resolve a minor leak after the procedure using a coil, but the leak increased, and a large aneurysm developed. The leak was a combination of type I and II, and the only treatment solution was a complex hybrid procedure including a large surgical intervention in the proximal part of the aneurysm and an additional distal endovascular procedure (Figure 5).

TEVAR IN TRAUMATIC DISECTION

During the past four years, TEVAR procedures have been conducted in five polytraumatized patients (ages 31-55). In all cases the causes of the traumas were traffic accidents, and ruptures in the aorta were found during computerized tomography imaging. All the procedures were successful, with no early or late complications, as expected (Figure 6). In these life-threatening cases, survival after a successful TEVAR procedure depends primarily on the other injuries. All the patients recovered in our cases.

FIGURE 6.



A) Aortography presenting traumatic transection of aorta on typical location.

B) After stent-graft deployment.

ZAKLJUČAK

Povod je za ovaj kratki prikaz rezultata TEVAR programa u KBC-u Zagreb dvojak.

Prvi je činjenica da je prošlo 10 godina otkako smo postupak započeli raditi, relativno rano s obzirom na pojavu metode u svijetu, i da smo, unatoč mnogim teškoćama i nedostatku podrške, program održali, iako na minimumu. U međuvremenu je u sredinama u kojima je timu pružena podrška onih koji raspolažu sredstvima broj TEVAR procedura mnogo brže rastao.

Drugi je razlog optimistična činjenica da je metodu nedavno konačno prepoznao HZZO kao etabliranu proceduru za rješavanje bolesti descendentne aorte, s mnogo manje rizika od vrlo kompleksne i skuplje kirurgije te da je sve više u nekoliko ustanova u Hrvatskoj rutinski izvode kardiolozi, radiolozi ili vaskularni kirurzi.

CONCLUSION

The motivation for this short overview of the results of the TEVAR program in UHC Zagreb was twofold:

The first is the fact that it has been 10 years since we started performing the procedure, which is fairly early compared with the emergence of this method worldwide, coupled with the fact that, despite many difficulties and a lack of support, we managed to keep the program running, albeit at a minimal level. In the meantime, the number of TEVAR procedures has grown much faster in areas where the teams have been supported by those with the resources to do so.

The second reason is the encouraging fact that this method has finally been recognized by the Croatian Health Insurance Fund as an established procedure for the treatment of diseases of the descending aorta, with much less risk involved than the very complex and more costly surgical procedures, and that TEVAR is now being routinely performed in several institutions in Croatia by cardiologists, radiologists, or vascular surgeons.

LITERATURE

- Dake MD, Miller DC, Semba CP, Mitchell RS, Walker PJ, Liddell RP. Transluminal placement of endovascular stent-grafts for the treatment of descending thoracic aortic aneurysms. *N Engl J Med.* 1994;331(26):1729-34. DOI: <http://dx.doi.org/10.1056/NEJM199412293312601>
- Bavaria JE, Appoo JJ, Makaroun MS, Verter J, Yu ZF, Mitchell RS; Gore TAG Investigators. Endovascular stent grafting versus open surgical repair of descending thoracic aortic aneurysms in low-risk patients: a multicenter comparative trial. *J Thorac Cardiovasc Surg.* 2007;133(2):369-77. DOI: <http://dx.doi.org/10.1016/j.jtcvs.2006.07.040>
- Dake MD, Kato N, Mitchell RS, Semba CP, Razavi MK, Shimono T, et al. Endovascular stent-graft placement for the treatment of acute aortic dissection. *N Engl J Med.* 1999;340(20):1546-52. DOI: <http://dx.doi.org/10.1056/NEJM199905203402004>
- Nienaber CA, Kische S, Rousseau H, Eggebrecht H, Rehders TC, Kundt G, et al; INSTEAD-XL trial. Endovascular repair of type B aortic dissection: long-term results of the randomized investigation of stent grafts in aortic dissection trial. *Circ Cardiovasc Interv.* 2013;6(4):407-16. DOI: <http://dx.doi.org/10.1161/CIRCINTERVENTIONS.113.000463>
- Trimarchi S, Nienaber CA, Rampoldi V, Myrmet T, Suzuki T, Bossone E, et al; IRAD Investigators. Role and results of surgery in acute type B aortic dissection: insights from the International Registry of Acute Aortic Dissection (IRAD). *Circulation.* 2006;114(1 Suppl):1357-64. DOI: <http://dx.doi.org/10.1161/CIRCULATIONAHA.105.000620>
- Kolbeck KJ, Kaufman JA. Endovascular stent grafts in urgent blunt and penetrating thoracic aortic trauma. *Semin Intervent Radiol.* 2011;28(1):98-106. DOI: <http://dx.doi.org/10.1055/s-0031-1273944>
- Fernandez V, Mestres G, Maeso J, Dominguez JM, Aloy MC, Matas M. Endovascular treatment of traumatic thoracic aortic injuries: short- and medium-term Follow-up. *Ann Vasc Surg.* 2010;24(2):160-6. DOI: <http://dx.doi.org/10.1016/j.avsg.2009.05.013>
- Svensson LG, Kouchoukos NT, Miller DC, Bavaria JE, Coselli JS, Curi MA, et al; Society of Thoracic Surgeons Endovascular Surgery Task Force. Expert consensus document on the treatment of descending thoracic aortic disease using endovascular stent-grafts. *Ann Thorac Surg.* 2008;85(1 Suppl):S1-41. DOI: <http://dx.doi.org/10.1016/j.athoracsur.2007.10.099>
- Alsac JM, Khantalina I, Julia P, Achouh P, Farahmand P, Capdevila C, et al. The significance of endoleaks in thoracic endovascular aneurysm repair. *Ann Vasc Surg.* 2011;25(3):345-51. DOI: <http://dx.doi.org/10.1016/j.avsg.2010.08.002>