

PERIOCLAR PILOMATRIXOMA: CASE REPORT

Ana Bišćan Tvrđi¹, Biljana Kuzmanović Elabjer², Daliborka Miletić², Mladen Bušić², Damir Bosnar² and Zvonko Petrović³

¹Medikol Polyclinic; ²Clinical Department of Ophthalmology, ³Clinical Department of Pathology and Cytology, Sveti Duh University Hospital, Zagreb, Croatia

SUMMARY – The aim is to present a case of pilomatrixoma in the periocular area in a 10-year-old female through retrospective review of medical records of a single patient. A 10-year-old female developed a lesion under her right eyebrow over a period of one year. The rest of the ophthalmic history was unremarkable. On examination, oval, well-defined, subcutaneous tumor measuring 7x4 mm was found under the right eyebrow. It gave bluish tint under the firmly adherent overlying skin of normal color and texture. Rocky hard and non-tender, it was mobile over the underlying tissues. Total excision biopsy was performed under general anesthesia. Histopathologic analysis confirmed the diagnosis of pilomatrixoma. Pilomatrixoma is a rare tumor with head, neck and periocular area being the commonest sites. It is often clinically misdiagnosed and/or missed on differential diagnosis. Although a benign tumor, malignant transformation into pilomatrix carcinoma has been described. Thus, total surgical excision of the mass is recommended.

Key words: *Pilomatrixoma – surgery; Periocular area; Skin neoplasms – pathology; Case reports*

Introduction

Pilomatrixoma is a rare, benign, cutaneous tumor arising from pluripotential precursors of hair matrix cells. Lids and eyebrows are common sites of its appearance¹. Malignant transformation into pilomatrix carcinoma has been described². We present a case of pilomatrixoma of the eyebrow in a 10-year-old female.

Case Report

A 10-year-old female presented with a painless mass under the right eyebrow, slowly growing for one year. Her medical history was otherwise unremarkable. On examination, oval, well-defined, subcutaneous tumor measuring 7x4 mm was found under the right eyebrow. It gave bluish tint under the firmly

adherent overlying skin of normal color and texture. Rocky hard and non-tender, it was mobile over the underlying tissues (Fig. 1). Total excision biopsy was performed under general anesthesia. Macroscopically, the well circumscribed, multilobular yellow-grey tumor had a diameter of 7 mm. Histopathologic analysis revealed numerous islands of epithelial cells composed mostly of eosinophilic shadow cells, which are pathognomonic of pilomatrixoma. Calcification was also present (Fig. 2).

Discussion

Pilomatrixoma (also called pilomatricoma or Malherbe calcifying epithelioma)¹⁻⁶ is a rare, benign, cutaneous tumor arising from pluripotential precursors of hair matrix cells. Although the lesion can appear at any age⁶, it is most common in the first two decades of life³ affecting females more than males⁵. It can appear on any part of the body, the commonest being head and neck^{1,2,4,6}, followed by upper extremities, trunk and lower extremities. In periocular area, it

Correspondence to: *Ana Bišćan Tvrđi, MD*, Medikol Polyclinic, Voćarska 106, HR-10000 Zagreb, Croatia
E-mail: anabiscan@yahoo.com

Received August 6, 2013, accepted June 16, 2014

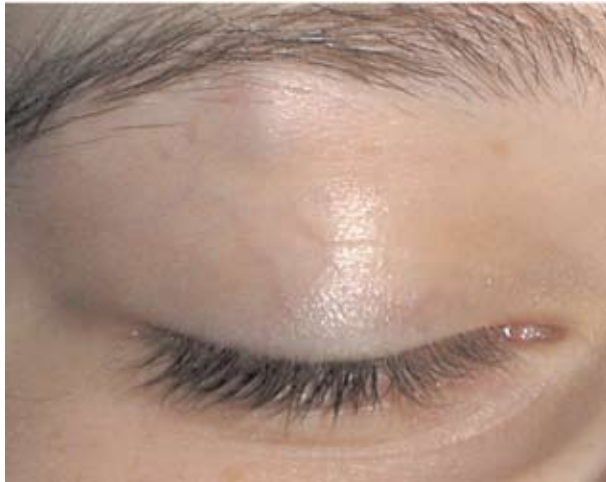

Fig. 1. Oval, well circumscribed, subcutaneous mass measuring approximately 7x4 mm under medial upper orbital margin, under the right eyebrow.

usually arises from the lids and eyebrows^{1,6}. It presents as a painless, slowly enlarging, firm to hard, well-circumscribed, subcutaneous mass⁴⁻⁶, with average size of 10 mm or less⁶ that slides freely over the underlying tissues^{2,4}. The overlying skin is usually intact with reddish to blue discoloration due to dilated blood vessels^{3,5}.

Pilomatrixoma is mostly solitary. Multiple tumors are in rare instances associated with myotonic muscular dystrophy, Gardner syndrome, Turner syndrome and sarcoidosis²⁻⁴. Frequently misdiagnosed, it is mistakenly believed to be an epidermoid cyst, dermoid cyst, foreign body reaction, calcification in lymph nodes, chalazion, sebaceous adenoma, adenocarcinoma and pyogenic granuloma^{1,3,4,6}.

Although a benign tumor, pilomatrixoma may undergo malignant transformation into pilomatrix carcinoma. Its tendency to recurrence as well as distant metastases have been reported. Thus, pilomatrixoma total surgical excision^{1,2,4} is mandatory.

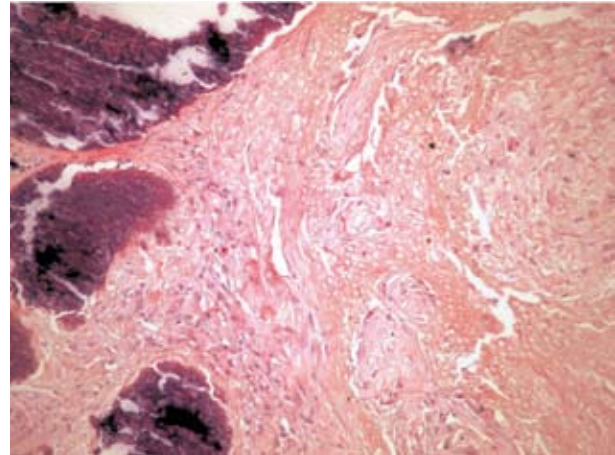


Fig. 2. Histopathologic examination showing numerous islands of epithelial cells degeneratively changed with calcification and shadow cells as a pathognomonic sign for pilomatrixoma.

References

1. IZQUIERDO-RODRÍGUEZ C, MENCÍA-GUTIÉRREZ-DÍAZ E, SUÁREZ-GAUTHIER A. An unusual presentation of a pilomatrixoma in the eyelid. *Arch Soc Esp Oftalmol* 2006;81:483-6.
2. DANIELSON-COHEN A, LIN JS, HUGHES CA, ANHY, MADDALOZZO J. Head and neck pilomatrixoma in children. *Arch Otolaryngol Head Neck Surg* 2001;127:1481-3.
3. SOM MP, SHUGAR MAJ, SILVERS RA. CT of pilomatrixoma in the cheek. *AJNR Am J Neuroradiol* 1998;19:1219-20.
4. KUMAR S. Rapidly growing pilomatrixoma on eyebrow. *Indian J Ophthalmol* 2008;56(1):83-4.
5. ROSA N, LANZA M, CENNAMO G, ACCARDO M. Pilomatrixoma of the eyelid. *J Dermatol Case Rep* 2008;2(2):21-3.
6. ALI JM, HONAVAR GS, NAIK NM, VEMUGANTI KG. Malherbe's calcifying epithelioma (pilomatrixoma): an uncommon periocular tumor. *Int J Trichol* 2011;3(1):31-3.

Sažetak

PILOMATRIKSOM PERIOKULARNOG PODRUČJA: PRIKAZ SLUČAJA

A. Bišćan Tvrđi, B. Kuzmanović Elabjer, D. Miletić, M. Bušić, D. Bosnar i Z. Petrović

Prikazuje se slučaj pilomatriksoma periokularnog područja u desetogodišnje djevojčice kroz retrospektivnu analizu povijesti bolesti jednog bolesnika. Desetogodišnja djevojčica dolazi zbog tvorbe ispod desne obrve koja raste godinu dana. Kliničkim pregledom se nađe ovalni, dobro ograničeni, potkožni tumor, pomičan po podlozi, veličine 7x4 mm. Plavičasto prosijava ispod nepromijenjene kože. Učinjena je ekscizijska biopsija tumora. Histopatološka analiza potvrdila je kliničku dijagnozu pilomatriksoma. Pilomatriksom je rijedak kožni tumor koji se najčešće javlja u području glave i vrata te u periokularnom području. Često je izostavljen u diferencijalnoj dijagnozi. Iako je benignan, tumor se može maligno promijeniti, stoga se preporuča potpuna kirurška ekscizija.

Ključne riječi: *Pilomatriksom – kirurgija; Periokularno područje; Kožni tumori – patologija; Prikazi slučaja*