

Alzheimer and Lewy Body Pathology or Creutzfeldt-Jakob Disease

Ana Krvavica¹, Miro Morović², Anamarija Mrđen³, Damir Mišlov³, Klaudia Duka-Glavor³, Krešimir Ivanac³ and Ellen Gelpi⁴

¹ General Hospital Zadar, Department of Pathology and Forensic Medicine, Zadar, Croatia

² University in Rijeka, General Hospital Zadar, Department of Infective Diseases, Zadar, Croatia

³ General Hospital Zadar, Department of Neurology, Zadar, Croatia

⁴ Medical University of Vienna, Austrian Reference Centre for Human Prion Diseases, Institute of Neurology, Vienna, Austria

ABSTRACT

The objective of this work is to describe the neuropathological findings of a patient clinically presenting with rapidly progressive nonspecific neurological symptoms suggestive of Creutzfeldt-Jakob disease. Methods used were clinical description with laboratory analyses, repeated electroencephalogram, cerebral computed tomography, magnetic resonance imaging studies and details on neuropathological work-up. Neuropathological examination excluded Creutzfeldt-Jakob disease. By contrast other neurodegenerative changes combining Alzheimer-type pathology and Lewy body pathology were detected as the most likely substrate of neurological symptoms. Dementia with Lewy bodies should be included in the differential diagnosis in individuals presenting with rapidly progressive dementia.

Key words: dementia, Lewy body, Alzheimer disease, Parkinson disease, Creutzfeldt-Jakob disease

Introduction

Dementia with Lewy bodies (DLB) and Parkinson disease dementia (PDD) are after Alzheimer's disease (AD) the most frequent neurodegenerative disorders. There is increasing evidence that up to 80% of people with PD will develop dementia towards the end of their life. While the neurobiology of movement disorder has been studied in detail in PD, much less is known about mechanisms underlying the cognitive and behavioral symptoms associated with DLB and PDD. To date, the best correlate of cognitive impairment appears to be the presence of cortical Lewy bodies; however new emphasis has been placed on small aggregates of synuclein¹ and cortical and striatal beta-amyloid deposits. Clinically it is important to recognize DLB with characteristic and often rapidly progressive symptoms: mental impairment progressing to dementia, early and prominent visuospatial difficulties, fluctuation in cognitive function, well-formed visual hallucinations, and spontaneous motor features of parkinsonism². Brainstem or cortical alpha-synuclein immunoreactive Lewy bodies are the only features considered essential for a pathologic diagnosis of dementia with Lewy bodies, although Lewy-related neurites, Alzheimer

pathology, and spongiosis of upper cortical layers may also be seen. No standard criteria exist for the neuropathologic diagnosis of Parkinson disease dementia, as the specificity and sensitivity of the characteristic findings have not been established clearly. Individuals presenting with primary dementia may exhibit neuropathologic features indistinguishable from those of advanced Parkinson disease (e.g., Braak's stage 5–6 of PD-related pathology). Neuropathological diagnostic criteria for Alzheimer disease are based on tau-related pathology: neurofibrillary tangles or neuritic plaques. According to NIA-Reagan criteria, a good correlation between Braak's neurofibrillary stage and CERAD plaque score with dementia was found, with relatively good agreement between these criteria and existing neuropathological methods for diagnosing AD^{3–5}. Sporadic Creutzfeldt-Jakob disease is a rare fatal neurodegenerative disease characterized by spongiform degeneration of grey matter and accumulation of pathologic prion protein primarily in the central nervous system. Its most classical form shows a quite typical clinical picture with initial subtle changes in memory and behavior followed by a rapidly progres-

sive dementia, often with pronounced startle myoclonus, visual impairment, pyramidal and extrapyramidal or cerebellar signs. Microscopically the characteristic spongiform change is seen in the cerebral and cerebellar cortex and other regions of gray matter, such as caudate, putamen and thalamic nuclei, and consists of variable microvacuolation of the neuropil. In advanced disease stages there is severe neuronal loss and marked reactive astrogliosis and microglial activation. Alternative diagnoses in suspected cases include Alzheimer's disease, Lewy body diseases⁶, vascular encephalopathy, metabolic encephalopathies and viral or limbic encephalitis. Postmortem investigation of brain tissue is mandatory to confirm the diagnosis of a prion disease.

Clinical Findings

A 60 year old male patient presented various neurological symptoms about two months prior the hospitalization. Patient's family observed mild cognitive disturbances, ataxia, and visuospatial alterations. Routine laboratory analyses showed no specific findings, but CSF analysis revealed high level of total proteins. 14-3-3 protein and tau- protein analysis in CSF was not performed. Repeated electroencephalograms (EEG) revealed diffuse attenuation of brain activity with intermittent hypersynchronous delta-waves and repetitive complexes such as sharp point-wave in its slow variant of 2–3s duration. In the preterminal phase, he developed febrile status with »startle« myoclonus. Cerebral computed tomography (MSCT) showed irregular broadening of periventricular white matter with hypodensity. Magnetic resonance imaging studies (MRI) showed hyperintensities in the cortico subcortical boundary and in white matter (in T2 and FLAIR sequences). He died 19 days after hospitalization of interstitial pneumonia. The final clinical diagnosis was rapidly progressive encephalopathy, most likely due to prion disease, fulfilling WHO surveillance criteria for probable CJD: dementia+ataxia+myoclonus+visuospatial alteration and suggestive EEG.

Autopsy Findings

General macroscopic findings included atherosclerosis, predominantly aorta abdominalis, myocardial fibrosis and renal sclerosis, interstitial pneumonia with compensatory emphysema as the ultimate cause of death. The brain was diffusely edematous with a total weight of 1550g. On serial frontal sections, moderate ventricular enlargement was observed. Right putamen was not well demarcated from capsula interna and pallidum; also beneath the basis of the temporal and occipital lobes dura was yellow discolored, as a consequence of chronic, almost resorbed subdural haemathoma. Due to the clinical suspicion of a prion disease, formalin-fixed and paraffin-embedded brain tissue was sent to the Austrian Reference Center for Human Prion Diseases (ORPE), at the Institute of Neurology, Medical University in Vienna, for neuropathological evaluation. Selected brain areas were

basal ganglia including caudate, putamen and pallidum, pons, medulla oblongata and dura mater.

Neuropathological Findings

Histology showed no characteristic features of a spongiform encephalopathy: there was no spongiform change, no marked neuronal loss and no significant gliosis. In addition immunohistochemistry using two different antibodies 12F10 and 3F4 did not reveal pathological prion protein deposits. So the clinical suspicion of Creutzfeldt-Jakob disease could not be confirmed. Nevertheless there were other neurodegenerative changes combining Alzheimer-type pathology and Lewy body pathology. In the temporal and cingular cortex a moderate density of neuritic plaques was observed in the Bielschowsky silver stain. These plaques were composed of beta-amyloid peptide. Furthermore silver stain and AT8 immunohistochemistry labeled in addition to the neuritic component of neuritic plaques, several tangles and pretangles in the temporal cortex and nucleus basalis Meynert (Figure 1), and single tangles in locus coeruleus and substantia nigra. There was a marked vascular thickening and remodelling the wall of the leptomeningeal vessels with some intermingled lymphocytes and macrophages in the area of the almost resorbed subdural haemorrhage. Moreover, Lewy bodies were already visible in the HE stain in the locus coeruleus. These were strongly immunolabelled with antibodies directed against alpha-synuclein. In addition to the locus coeruleus, numerous

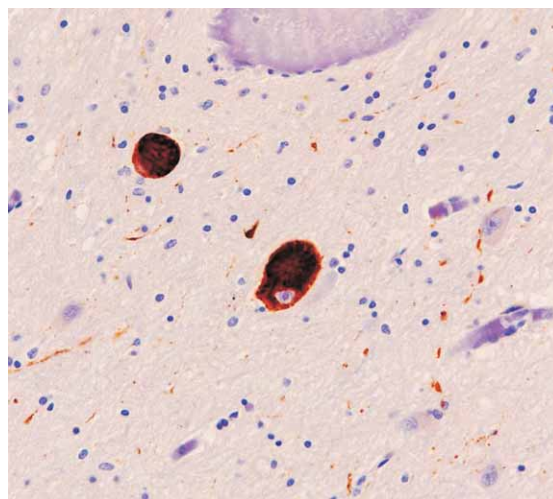


Fig. 1. Some hyperphosphorylated tau-immunoreactive tangles in cholinergic neurons of *n. basalis Meynert* associated with delicate neuropil threads (AT8 ×200).

classical Lewy bodies and some Lewy neurites were detected in the substantia nigra (Figure 2), dorsal nucleus of the vagus, intermediate reticular zone, raphe, and nucleus basalis Meynert. There was also a moderate amount of cortical Lewy bodies in the temporal and cingular cortices.

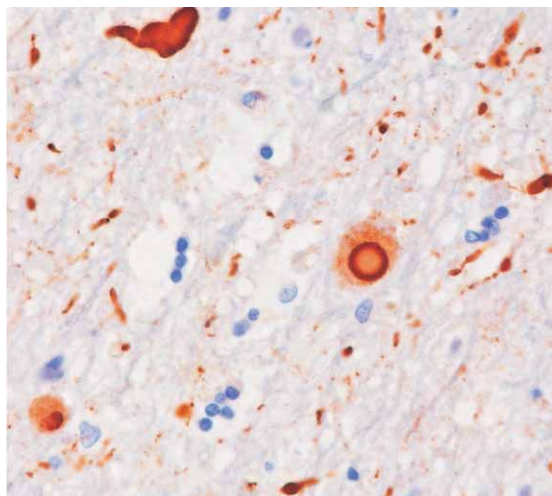


Fig. 2. Abundant alpha-synuclein immunoreactive Lewy-bodies and Lewy neurites are detected in dorsal nucleus of vagus and intermediate reticular zone of medulla oblongata substantia nigra ($\times 400$) and n. basalis of Meynert.

Summary

The moderate density of neuritic plaques together with the age of the patient and the reported dementia would allow the classification into definite Alzheimer's disease according to CERAD criteria. The extent and distribution of neurofibrillary pathology would correspond at least to stage III according to Braak and Braak classification. According to NIA/Reagan Institute criteria there would be an intermediate likelihood, that dementia had been due to Alzheimer's disease lesions. The extent and distribution of the concomitant alpha-synucleinopathy of the Lewy body type would correspond at least to a stage 4 of the Parkinson-associated pathology according to Braak et al; or at least to a limbic stage of diffuse Lewy body disease (DLB) according to the Newcastle criteria. Taking into account both the extent of Lewy body related pathology and Alzheimer type pathology according to the DLB consortium (2005) there would be an intermediate likelihood that the pathologic findings could be associated with the clinical syndrome.

REFERENCES

1. FRANCIS PT, *J Neurol*, 256 Suppl 3 (2009) 280. — 2. MC KEITH IG, *Journal of Alzheimer's Disease*, 9 Suppl 3 (2006) 417. — 3. LIPPA CF, DUDA JE, GROSSMAN M, HURTIG HI, AARSLAND D, BOEVE BF, BROOKS DJ, DICKSON DW, DUBOIS B, EMRE M, FAHN S, FARMER JM, GALASKO D, CALVIN JE, GOETZ CG, GROWDON JH, GWINN-HARDY KA, HARDY J, HEUTINK P, IWATSUBO T, KOSAKA K, LEE VM, LEVERENZ JB, MASLIAH E, MCKEITH IG, NUSSBAUM RL, OLANOW CV, RAVINA BM, SINGLETON AB, TANNER CM, TROJANOWSKI JQ, WSZOLEK ZK, *Neurology*, 68 Suppl 11 (2007) 812. — 4. MURAYAMA S, SAITO Y, *Neuropathology*, 24 Suppl 3 (2004) 254. — 5. SHULZ-SCHAEFFER WJ, *Acta Neuropathol*, 120 Suppl 2 (2010) 131. — 6. MOLLENHAUER B, FORTSL J, DEUSCHL G, STORCH A, OERTEL W, TRENKWALDER C, DROBNA E, JARIUS C, LANG S, WALDHOR T, BEMHEIMER H, BUDKA H, *Dtsch Arztebl Int*, 107 Suppl 39 (2010) 684.

Discussion

We present a patient with Alzheimer and Lewy body-related pathology who presented with rapidly progressive dementia, and complex neurological symptoms with EEG changes that raised the suspicion of CJD. Indeed, the patient fulfilled clinical surveillance criteria for probable CJD. Nevertheless, this was based solely on EEG results, but 14-3-3 protein analysis was not performed and MRI, a sensitive method recently included in diagnostic criteria^{7,8}, showed no cortical or basal ganglia hyperintensities that are observed in most sCJD subtypes. Similar clinical presentations between CJD and some forms of DLB have been previously reported (Tschampa, du Plessis, Gaig). Tschampa et al.⁹ analyzed symptoms and signs of 31 patients with clinical suspicion of CJD but post-mortem confirmation of AD or DLB. Clinical suspicion of CJD was raised in DLB cases because of rapidly progressive clinical course with or without focal neurological signs (70% had myoclonus and limb rigidity) and/or suggestive EEG (8%). Fifty percent of DLB patients fulfilled WHO criteria of »possible« and one case of »probable« sporadic CJD. Recently, Gaig et al.¹⁰ presented a retrospective clinico-pathological study of a subgroup of DLB patients with rapidly progressive clinical course (6 cases among 47 subjects with a clinical picture of DLB). Three of them fulfilled clinical WHO criteria of »possible« sporadic CJD due to the presence of myoclonus and parkinsonism, but had negative 14-3-3 protein in CSF and non-typical EEG. The authors could not find any distinct neuropathological feature of this rapidly progressive DLB subgroup, nor alpha-synuclein gene mutations or multiplications.

Due to the lack of a definite in vivo diagnostic test for most of the currently known neurodegenerative proteinopathies, available methods to delineate the clinical diagnosis should be combined whenever possible. Therefore the development of techniques with high sensitivity and specificity is urgent in terms of therapeutic challenge. Rapidly progressive diffuse Lewy-body disease with or without Alzheimer-type pathology should be included in the differential diagnosis of CJD, especially when useful tests such as 14-3-3 protein in CSF or MRI are negative.

- 7. WHO, Manual for Surveillance of human transmissible spongiform encephalopathies including variant Creutzfeldt-Jakob disease, WHO, Geneva, 2003. — 8. ZERR I, KALLENBERG K, SUMMERS DM, ROMERO C, TARATUTO A, HEINEMANN U, BREITHAUP T M, VARGES D, MEISSNER B, LADOGANA A, SCHUUR M, HAIK S, COLINS SJ, JANSEN GH, STOKIN GB, PIMENTEL J, HEWER E, COLLIE D, SMITH P, ROBERTS H, BRANDEL JP, VAN DUJN C, POCCHIARI M, BEGUE C, CRAS P, WILL RG, SANCHES-JUAN P, *Brain*, 132 (2009) 2659. — 9. TSCHAMPA HJ, NEUMANN M, ZERR I, HENKEL K, SCHROTER A, SCHULZ-SCHAEFFER WJ, STEINHOFF BJ, KRETZSCHMAR HA, POSER S, *J Neurol Neurosurg Psychiatry*, 71 (2001) 33. — 10. GAIG C, VALLDEORIOLA F, GELPI E, EZQUERRA M, LLUFRIU S, BUONGIORNO M, REY MJ, MARTI MJ, GRAUS F, TOLOSA E, *Mov Disord*, 26 (2011) 1316.

A. Krvavica

General Hospital Zadar, Bože Peričića 5, 23000 Zadar, Croatia
e-mail: ana.krvavica@zd.t-com.hr

ALZHEIMER I LEWY BODY DEMENCIJA ILI CREUTZFELD-JACOBOVA BOLEST

SAŽETAK

Naša namjera je bila opisati neuropatološke promjene kod bolesnika koji se klinički manifestirao slikom brzo progresivne demencije ispunjavajući kriterije za vjerojatnu Creutzfeldt-Jacobovu bolest (CJD). Neuropatološki pregled je isključio Creutzfeldt-Jacobovu bolest. Imunohistološkim metodama su dokazane neuropatološke promjene kombiniranog tipa Alzheimerove i Lewyjeve demencije kao najvjerojatniji uzročnici kliničkih simptoma. Preklapanje u kliničkim simptomima i patološkim promjenama bolesnika sa brzo progredirajućom demencijom može izazvati dijagnostičke probleme, te se uz Creutzfeldt-Jacobovu bolest trebaju diferencijalno dijagnostički uključiti Alzheimerova i difuzna Lewyjeva bolest.