

# The Radiological Estimation of Vertebral Body Volumes on the Thoracic and Lumbal Spine

Mirza Bišćević<sup>1</sup>, Šejla Bišćević<sup>2</sup>, Farid Ljuca<sup>3</sup>, Azmi Hamzaoglu<sup>4</sup>, Ferid Krupić<sup>5</sup>, Barbara UR Smrke<sup>6</sup> and Dragica Smrke<sup>7</sup>

<sup>1</sup> University of Sarajevo, University Clinical Center Sarajevo, Department of Orthopedics and Traumatology, Sarajevo, Bosnia and Herzegovina,

<sup>2</sup> University of Sarajevo, University Clinical Center Sarajevo, Sarajevo, Bosnia and Herzegovina,

<sup>3</sup> University of Tuzla, Medical Faculty, Tuzla, Bosnia and Herzegovina,

<sup>4</sup> Istanbul Spine Center, Florence Nightingale Hospital, Istanbul, Turkey

<sup>5</sup> Sahlgrenska Academy at University of Gothenburg, Department of Orthopedics, Gothenburg, Sweden

<sup>6</sup> University of Ljubljana, University Clinical Center Ljubljana, Department of Neurosurgery, Ljubljana, Slovenia

<sup>7</sup> University of Ljubljana, University Clinical Center Ljubljana, Department of Traumatology, Ljubljana, Slovenia

## ABSTRACT

*The aim of this work is to radiologically estimate the width, height and depth of bodies of thoracic and lumbal vertebrae. Charts of one hundred and seventeen patients with implanted internal fixateur on the thoracic and lumbal spine, between 01.01.2008. and 31.3.2010. at the Department of Orthopedics and Traumatology – Clinical Centre Sarajevo, were retrieved, and only 14 patients, with totally 46 vertebrae have met including criteria (clearly visible measured structures on X-ray and CT scans, and data about implants dimensions). Digitalized anteroposterior and laterolateral X-ray, and transversal and sagittal CT scans were basic inputs for measurement of height, width and depth of the vertebral body – CH, CW, CD. The correction of enlargement on X-ray pictures was performed according to known dimensions of implants and the length scale on CT scans. Enlargement of those parameters, from T1 to L5 spine level was from 60 to 100%, except the stagnation in the mid-thoracic region, and decreasing of corporal depth on the L5 vertebra (CD/L5), in comparison to the fourth vertebra (CD/L4). The clinical importance of this work is in estimation and comparison of dimensions of vertebral bodies measured on X-ray and CT scans, as the basic inputs during surgical procedures of vertebroplasty and anterior spondilodesis.*

**Key words:** spine, vertebra, body, volume, dimensions, vertebroplasty

## Introduction

The main function of the spine is its weight-bearing function. The spine column is consisted of 24 mobile and 9 immobile segments – vertebrae. Generally, thoracic and lumbal vertebrae have common anatomical characteristics. The anterior, massive cylindrical part, the vertebral body or corpus has an oval shape on the trans-section. The vertebral body is a structure which carries about 80% of body weight, the rest 20% of body weight is carried by the posterior parts of the vertebra. When a vertebral body is weakened by some pathological process, it cannot withstand to the usual gravitational pressures in everyday activities. Most common pathological spine fractures are compressive fractures of thoracolumbal

vertebrae of geriatric patients. Considering the fact that the geriatric population often has numerous comorbidities, weakened bone quality, and that instrumented spondylodeses have increased surgical risk, minimally invasive procedures are treatments of the choice for the described fractures. Principle of the minimally invasive treatment of compressive spine fractures is to inject bone cement percutaneously into the collapsed vertebral body through transpedicular placed canals, under the X-ray control (Figure 1). After this ambulatory procedure, a patient has prompt lack of pain, full mobility; risks of surgery are lower than one promile<sup>1</sup>.

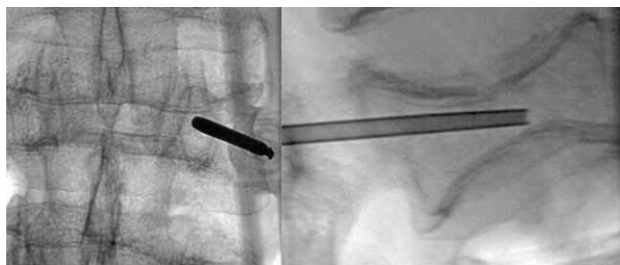


Fig. 1. Percutaneous instillation of bone cement into the collapsed vertebral body – vertebroplasty.

During percutaneous augmentation procedures, and anterior spine instrumentation, the vertebral body width, height and depth (CW, CH, CD), and consecutively volume of the vertebral body are particularly important parameters, like on Figures 2 and 3.

Variations in vertebral body volume are important for estimation of optimal volume of bone cement during performing vertebroplasty procedures – usually, three to six milliliters of bone cement is needed. Pre and posttraumatic volume of vertebral body are the referent values to avoid leak of cement to a minimum<sup>2,3</sup>. Average volumes of vertebral corpa are presented in Table 1.

TABLE 1  
ESTIMATIONS OF VERTEBRAL BODY VOLUMES IN MILLILITERS

	Theoretic volume (mL)	Filling volume (mL)	50% compressed primary volume (mL)
C5	7.2	3.6	1.8
T9	15.3	7.65	3.8
L3	22.4	11.2	5.6

For a spinal surgeon, shape, dimensions and internal structure are the most important morphometric characteristics of one vertebra, and X-ray and CT scanning are methods for their estimations.

The aim of this work is to measure the depth, width and height of thoracic and lumbar vertebral bodies on X-ray and CT scans, and compare them with referral values.

### Patients and Methods

Charts of one hundred and seventeen patients with implanted internal fixateur on the thoracic and lumbar spine between 01.01.2008. – 31.3.2010. at the Department of Orthopedics and Traumatology, of the Clinical

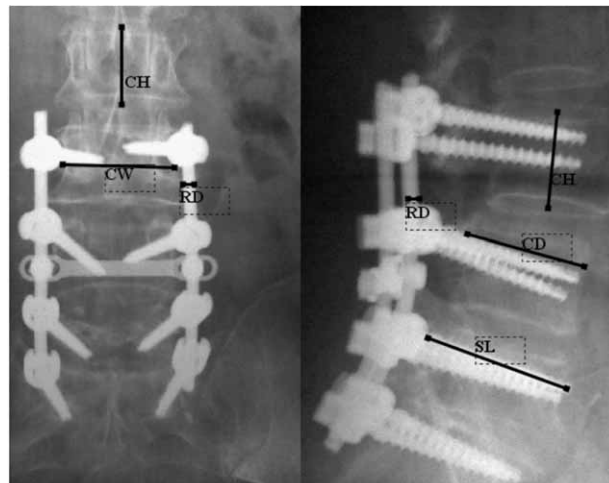


Fig. 2. Vertebral body depth, width and height – CD, CW, CH, rod diameter – RD, and screw length SL on the X-ray scans after posterior fixation of lumbar spine.

centre of Sarajevo were retrieved. Only 14 patients, with 46 vertebrae and 89 pedicles have had complete documentation (clearly visible measured structures on X-ray and CT scans) – Table 2. The most common indications for posterior stabilization were vertebral fractures, tumor, scoliosis, degenerative disease, spondylodiscitis.

Including criteria were CT scan performed after surgery (mostly because of the postoperative pain due to progression of the disease, repeated trauma, estimating of bone consolidation, new neurological symptoms), and a history chart that contains X-ray and CT scans with clearly visible all measured parameters and transpedicular screws on their whole length on X-ray and CT scans, and data about the type and dimensions of implanted screws. The last including criteria were crucial because we have made corrections of distortion of dimensions according to known dimensions of implants. CT scans have had length scales for additional recheck. This study is ethically acceptable because each postoperative CT scan with its negative effect of irradiation is performed due to a medical indication, not due to this study.

Digitalized anteroposterior and laterolateral X-ray, and transversal and sagittal CT scans were basic inputs for measurement of vertebral body height, depth and width – CH, CD, CW. The CorelDRAW 9 software was used for visual measurement of CH, CD and CW parameters, analogous to Figures 2 and 3.

Each parameter has got a suffix (r, x, ct), according to its origin (r – for data from referent literature<sup>4</sup>, x – for data measured on X-ray scans, ct – for data measured on CT scans). Correction of values measured on X-ray scans

TABLE 2  
NUMBER OF ANALYZED VERTEBRAS FROM T1 TO L5 LEVEL (N=46/89)

	T1	T2	T3	T4	T5	T6	T7	T8	T9	T10	T11	T12	L1	L2	L3	L4	L5
Vertebrae	2	2	1	1	1	1	1	1	1	2	3	3	6	8	5	5	3

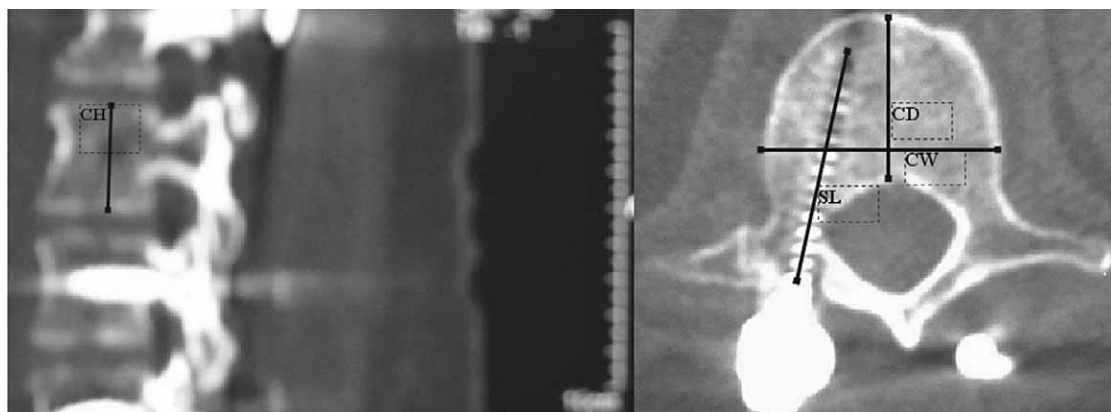

Fig. 3. Transversal and sagittal CT scans with vertebral body dimensions – CW, CH, CD and clearly visible transpedicular screws.

was in average about 20% (ratio between actual length of implants and its length measured on X-ray scans)<sup>2,5,6</sup>. Due to a low number of analyzed vertebrae – Table 2, comparative statistics were not applicable.

### Results

The average results for corporal depth, width and height, with referent values are presented in millimeters after correction of length distortion (Table 3). The graphical presentation is on the Figure 4.

### Discussion

Macroscopically, the inside of vertebral corpa has a sponge structure, similarly to toast-bred. Majority of vertebral body volume is consisted of venous vessels, as a part of Baxter’s plexus. That plexus is an intra and extra osseous by-pass system without valvulas. It connects the drainage system of lower and upper vena cava, what is the reason for relatively common metastasis of urogenital and colon carcinoma into vertebral bodies<sup>1</sup>. The osseous trabeculas are relatively rare, especially on elderly patients.

Data about depth, width, and height of vertebral bodies are necessary in clinical practice during anterior spine instrumentation (transcorporeal screw length and cage dimensions). The estimation of vertebral body volumes helps us in vertebraplasties to reduce the risk of cement leak on minimum.

This article has shown that dimensions of thoracic and lumbar vertebral bodies differ significantly. The common characteristic of all measured parameters is their almost linear increment from upper to lower levels of the spine (T1 to L5 vertebra). In average, that increment was from 60 to 100% (table 3.). Analogue on the Fig. 3, the trendlines of all parameters measured on X-ray and CT scans follow increment of corresponding referent line from T1 to L5. Only in the midthoracic spine, that increment is less pronounced. However, corporal depth of the fifth lumbar vertebra (CD/L5) was lower in comparison to the fourth lumbar vertebra (CD/L4).

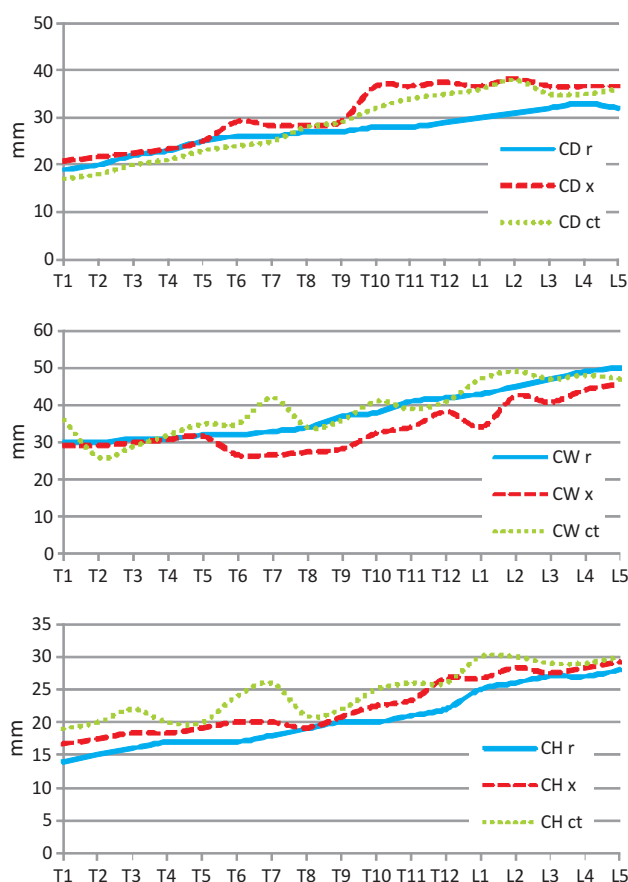


Fig. 4. Increasing of corporal depth (CD), width (CW), and height (CH) from T1 to L5 level, referral data (r), and measured on X-ray (x) and CT scans (ct).

General linear increment of measured parameters from upper to lower levels is related to vertical human posture and consecutive gradual increment of the weight bearing from T1 to L5 level. Mentioned exception is mostly evident at the region of the midthoracic spine. That can be explained by the fact that a part of axial weight bearing is transmitted on the rib-sternum construction (mechanical by-pass).

**TABLE 3**  
CORPORAL DEPTH (CD), HEIGHT (CH) AND WIDTH (CW) – REFERRAL VALUES, AND VALUES AT X-RAY AND CT SCANS (r, x, ct)  
IN MILLIMETERS

	T1	T2	T3	T4	T5	T6	T7	T8	T9	T10	T11	T12	L1	L2	L3	L4	L5
CD r	19	20	22	23	25	26	26	27	27	28	28	29	30	31	32	33	32
CD x	21	22	22	23	25	29	28	28	29	37	37	37	37	38	37	37	37
CD ct	17	18	20	21	23	24	25	28	29	32	34	35	36	38	35	35	36
CW r	30	30	31	31	32	32	33	34	37	38	41	42	43	45	47	49	50
CW x	29	29	30	31	32	27	27	27	28	32	34	38	34	42	41	44	46
CW ct	36	26	29	32	35	35	42	34	36	41	39	41	47	49	47	48	47
CH r	14	15	16	17	17	17	18	19	20	20	21	22	25	26	27	27	28
CH x	17	17	18	18	19	20	20	19	21	22	23	27	27	28	27	28	29
CH ct	19	20	22	20	20	24	26	21	22	25	26	26	30	30	29	29	30

In studies similar to our study, the interpretation of standard X-ray scans can be complicated on many ways<sup>7,8</sup>. The CT studies of the lumbal spine have revealed superiority of CT scans over the X-ray scans in the demonstration of artificial vertebral cortex damage<sup>9–15</sup>. Differences between referral data and parameters measured in our study are not observed, which confirms validity of our method for the correction of X-ray scanning distortion<sup>16–18</sup>. Oscillation of each parameter on X-ray and CT scans can be a consequence of individual variability and relatively low number of analyzed vertebrae. As a matter of fact, there is no other way for radiological estimation of corporal dimensions except the described two.

Limitation of this study is a relative low number of analyzed vertebrae and low reproducibility. The biggest problem during the study was the absence of high resolu-

tions on CT scans. That was the reason for excluding a great number of charts (103 of 117).

The individual, physiological and pathological variations of each parameter point on the necessity for analyzing of more vertebrae. Otherwise, a clinician must be aware that each patient has their absolute dimensions, and that great variations are possible. Those dimensions must be compatible with a local intra-operative status. Ignoring any dissonant measure can lead to serious consequences.

Data in this study has to be on mind as starting values for recalculation due to each noted variation visible on scans. In spite of that, this study has pointed that, if we respect the mentioned limitations of X-ray and CT scanning methods, those two methods are reliable in the clinical practice.

## REFERENCES

1. BIŠĆEVIĆ M, HAMZAĞLU A, LJUCA F, GAVRANKAPETANOVIĆ I, NADAREVIĆ A, REJEC-SMRKE B, SMRKE D, *Med Arh*, 63 (2009) 234. — 2. BIŠĆEVIĆ M, BIŠĆEVIĆ Š, LJUCA F, REJEC-SMRKE B, KAPUR E, TEZER M, SMRKE D, *Coll Antropol*, 36 (2012) 1313. — 3. BENZEL EC, *Spine surgery* (Elsevier Churchill Livingstone, London, 2005). — 4. CANALE ST, *Operative orthopedics* (Mosby, St. Louis; London, 2008). — 5. SMRKE D, BIŠĆEVIĆ M, *Coll Antropol*, 31 (2007) 661. — 6. BIŠĆEVIĆ M, HEBIBOVIĆ M, SMRKE D, *Coll Antropol*, 29 (2005) 315. — 7. WEINSTEIN JN, SPARTT KF, SPENGLER D, *Spine* 5 (1991) 576. — 8. TOHTZ SW, ROGALLA P, TAUPITZ M, PERKA C, WINKLER T, PUTIZER M, *Spine*, 10 (2010) 285. — 9. FAYAZZI AH, HUGATE RR, PENNYPACKER J, GELB DE, LUDWIG SC, *J Spinal Disord Tech*, 17 (2004) 367. — 10. CASTRO WH, HALM H, JEROSCH J, *Spine*, 21 (1996) 1320. — 11. BASTAIN L, KNOP C, LANGE U, BLAUTH M, *Orthopade*, 28 (1999) 693. — 12. KRAG MH, WEAVER DL, BEYNNON BD, *Spine*, 13 (1988) 27. — 13. MISENHIMER GR, PEEK RD, WILTSE LL, *Spine*, 14 (1989) 367. — 14. YOO JU, GAHANYEM A, PETERSILGE C, *Spine*, 22 (1997) 2668. — 15. CINOTTI G, GUMINA S, RIPANI M, *Spine*, 24 (1999) 114. — 16. SUK SI, LEE CK, CHUNG SS, *Spine*, 19 (1994) 419. — 17. LJENQVIST UR, LINK TM, HALM HF, *Spine*, 25 (2000) 1247. — 18. PANJABI MM, TAKATA K, GOEL V, *Spine*, 16 (1991) 888.

### D. Smrke

University of Ljubljana, University Clinical Center Ljubljana, Department of Traumatology, Zaloška 4,  
1000 Ljubljana, Slovenia  
e-mail: dragica.smrke@kclj.si

## RADIOLOŠKO ODREĐIVANJE OBUJMA GRUDNIH I SLABINSKIH KRALJEŽAKA

### SAŽETAK

Cilj ovog rada je radiološki izmjeriti širinu, dubinu i visinu trupova grudnih i slabinskih kralježaka. Sakupljeni su podaci o 117 pacijenta kojima je implantiran unutarnji fiksator na grudnu ili slabinsku kralježnicu, i to u periodu 01.01.2008. – 31.3.2010. na Klinici za ortopediju i traumatologiju u Sarajevu. Uključujuće kriterije (jasno vidljive mjerene strukture na RTG i CT snimcima, podaci o dimenzijama implantata) je ispunilo 14 pacijenata, s ukupno 46 instrumentiranih kralježaka. Digitalizirane anteroposteriorne i laterolateralne RTG snimke te transferzalni i sagitalni CT scan-ovi bili su osnova za mjerenje visine, dubine i širine trupa kralješka – CH, CD, CW. Na osnovu poznatih dimenzija vijaka i dužinske skale na CT scanovima vršila se je korekcija uvećanja na RTG snimcima. Povećanje svih mjerenih parametara, idući od T1 do L5 kralješka iznosilo je 60 do 100%, osim stagniranja porasta u srednjem grudnom području, i smanjenju dubine trupa L4 (CD/L4) u odnosu na L5 kralježak (CD/L5). Klinički značaj ovog rada je u određivanju i usporedbi dimenzija trupova kralježaka mjerenih RTG i CT metodom, kao osnovnih parametara pri izvođenju operativnih procedura vertebroplastike i prednje spondilodeze.