

## Subcutaneous Panniculitis-like T-cell Lymphoma in Type 1 Neurofibromatosis: a Case Report

Adam Reich<sup>1</sup>, Aleksandra Butrym<sup>2,3</sup>, Grzegorz Mazur<sup>4</sup>, Sławomir Tubek<sup>5</sup>, Grażyna Wąsik<sup>6</sup>, Bartosz Brzezicha<sup>7</sup>, Zdzisław Woźniak<sup>8</sup>

<sup>1</sup>Department of Dermatology, Venereology, and Allergology, Wrocław Medical University; <sup>2</sup>Department of Haematology, Blood Neoplasms, and Bone Marrow Transplantation, Wrocław Medical University; <sup>3</sup>Department of Physiology, Wrocław Medical University; <sup>4</sup>Department and Clinic of Internal and Occupational Diseases and Hypertension, Wrocław Medical University, Wrocław, <sup>5</sup>Department of Internal Disease, Voivodship Hospital; <sup>6</sup>Department of Dermatology, Voivodship Hospital, Opole, <sup>7</sup>Chair of Clinical immunology, Poznan University of Medical Sciences, Poznan, <sup>8</sup>Department of Pathology, Wrocław Medical University, Wrocław, Poland

### Corresponding author:

Adam Reich, MD, PhD  
Department of Dermatology, Venereology,  
and Allergology  
Wrocław Medical University  
Ul. Chałubińskiego 1, 50-368 Wrocław, Poland  
[adi\\_medicalis@go2.pl](mailto:adi_medicalis@go2.pl)

Received: October 14, 2012

Accepted: May 5, 2014

**SUMMARY** Neurofibromatosis 1 (NF-1) is an autosomal dominant genodermatosis with an increased risk of developing mesenchymal malignancies.

A 28-year-old woman with NF-1 was admitted to our Department for deep ulcers on the right thigh. The ulcerations had appeared about two years earlier, and were initially diagnosed as pyoderma gangrenosum. The patient received immunosuppressive therapy but only marginal improvement was observed. Several months later, the disease progressed, so a skin biopsy was taken, establishing cytophagic histiocytic panniculitis. The patient was admitted to our Department for further therapy. After re-evaluation of histological slides, while taking into account the clinical presentation and previously established histological diagnosis, subcutaneous panniculitis-like T cell lymphoma (SPTL) was diagnosed. Chemotherapy (combination of fludarabine and cyclophosphamide) was started, resulting in almost complete remission of malignant lesions.

To the best of our knowledge, this is the first report of the development of SPTL in NF-1.

**KEY WORDS:** cutaneous lymphoma, genodermatosis, neurofibromatosis 1, paraneoplastic syndrome, NF-1

### INTRODUCTION

Neurofibromatosis type 1 (NF-1, Recklinghausen's disease – OMIM 162200) is an autosomal dominant inherited genodermatosis caused by mutations in

the NF-1 gene on chromosome 17q11.2 that encodes neurofibromin (1). According to the National Institutes of Health (2), NF-1 is diagnosed based on clini-

cal presentation if the patient fulfils at least two of the following seven criteria: presenting with six or more café au lait spots (with a diameter of >0.5 cm in children or >1.5 cm in adults), axillary or groin freckling, two or more Lisch nodules, two or more neurofibromas or one plexiform neurofibroma, optic pathway glioma, bone dysplasia, and having a first-degree family relative with NF-1. Patients with NF-1 may also demonstrate a broad spectrum of other clinical features, including learning problems, renal artery stenosis, arterial hypertension, pruritus, and many others. In addition, they show increased risk of developing some malignancies, mainly malignant peripheral nerve sheath tumors or leukemia (1,3). In this paper, we report on a patient with NF-1 with a subcutaneous panniculitis-like T-cell lymphoma (SPTL). To the best of our knowledge, this is the first description of the coexistence of this unique and rare lymphoma with NF-1.

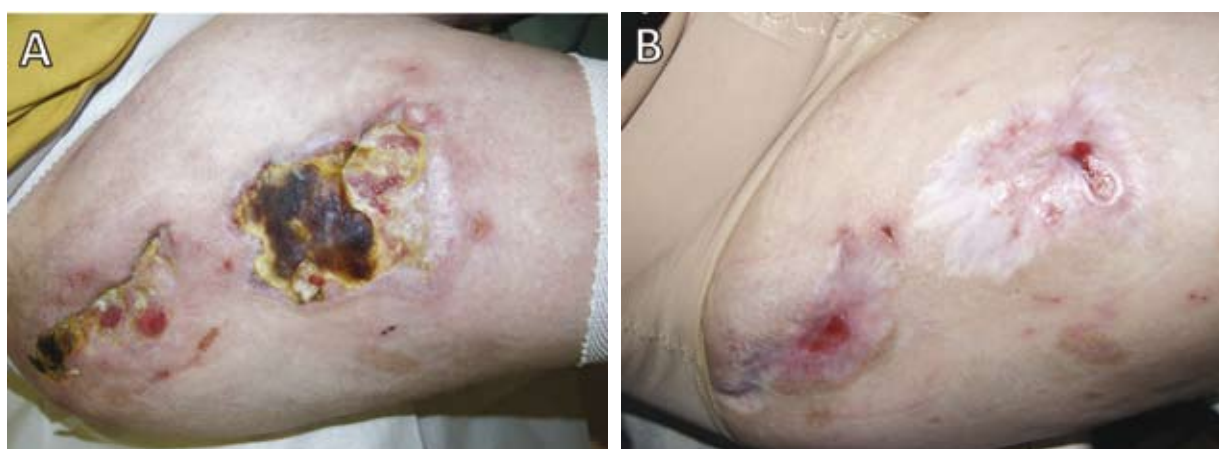
### CASE REPORT

A 28-year-old woman with NF-1, diagnosed based on numerous café-au-lait macules, multiple neurofibromas, Lisch nodules, and positive family history of NF-1 (the patient's father and brother were diagnosed with NF-1), was admitted to our Department because of deep ulcers on the right thigh (Figure 1A). The first ulcerations had appeared about two years prior to admission, and were initially diagnosed as pyoderma gangrenosum based on clinical presentation. At that time, the patient received immunosuppressive therapy (alternating systemic corticosteroids, cyclosporine A, and sulphasalazine), which at first resulted in a partial healing of the ulcers. However, several months later, the disease begun to progress despite continuous immunosuppression, so a skin biopsy was taken

from the edge of one ulcer. The histology revealed cytophagic histiocytic panniculitis. The patient was transferred to our Department for further diagnostics and therapy.

On admission, two deep ulcers covered with necrotic tissue were noted (Figure 1A), in addition to the typical features of NF-1. The patient also complained of severe pain, preventing her from sleeping and requiring a combined analgesic therapy (combination of buprenorphine 1.6 mg/day, ketoprofen 100 mg/day, and carbamazepine 400 mg/day). Taking into account the clinical presentation and previously established histological diagnosis, after re-evaluation of previous histological slides and new skin biopsy, the diagnosis of SPTL was finally established (Figures 2 and 3). Laboratory examinations revealed a slightly elevated erythrocyte sedimentation rate (30 mm/h), an increased level of C-reactive protein (11.2 mg/L, normal value <7.0 mg/L) and fibrinogen (5.71 g/L, normal value 2.0-4.5 g/L), low serum iron (6.7 µmol/L, normal value 8.9-30.3 µmol/L), and decreased immunoglobulin G (IgG) serum level (6.96 g/L, normal value 8.0-17.0 g/L). Other routine laboratory tests, also including blood smear, were within the normal range or negative. Sonography of the abdomen revealed hepato- (16.8 cm) and splenomegaly (13.2×6.3 cm). Lymph nodes were not enlarged (both clinically and according to the sonography test). Trepanobiopsy did not reveal any malignant cells infiltrating the bone marrow. In addition, no clinical symptoms of hemophagocytic syndrome were observed.

Chemotherapy (FC – a combination of fludarabine 25 mg/m<sup>2</sup> and cyclophosphamide 250 mg/m<sup>2</sup> on days 1-3, 28-day cycles) was started, resulting in partial remission after two cycles. Patient completed 6 FC cy-

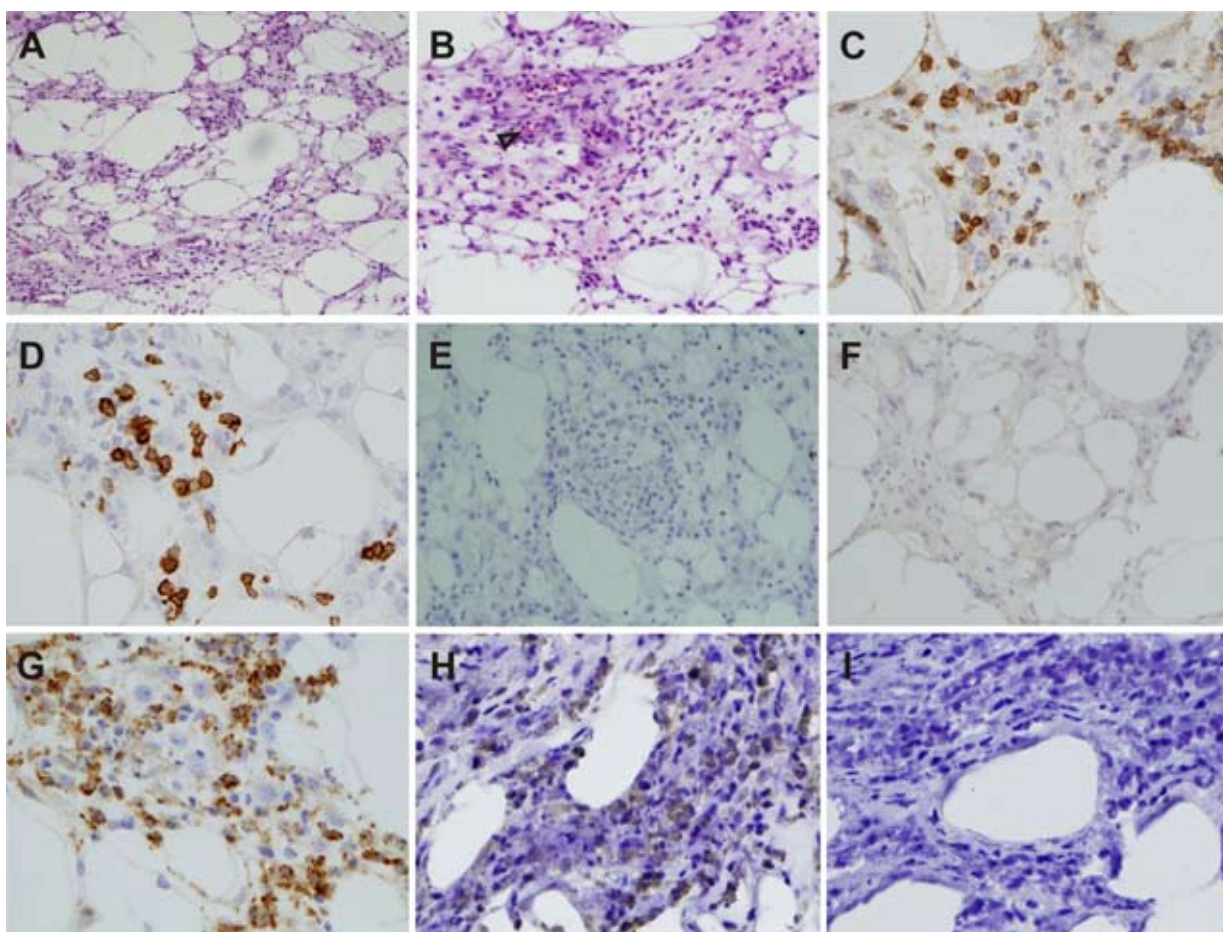


**Figure 1**

- A) Two deep ulcers covered with necrotic tissue on the right thigh.
- B) Current status of the patient with almost completely healed lesions.

cles with almost complete remission being achieved. Then, due to disease progression, two cycles of gemcitabine – GVP (1 g/m<sup>2</sup>, days 1 and 8), vinorelbine (30 mg/m<sup>2</sup>, days 1 and 8), and prednisone (100 mg/day, days 1–8) were administered, but due to significant prolonged myelotoxicity (grade 4 neutropenia and thrombocytopenia) this regimen was stopped. Cur-

rently the patient remains under observation, receiving only wound dressings. For the last 8 months, slow wound healing has been noted, without any symptoms of tumor progression (Figure 1B). Topically gelling foam dressing (Versiva<sup>®</sup> XC™) was applied during the entire treatment period.



### Figure 2

An overview of tumor histology (H&E, original magnification: x40).

A) Histological features of panniculitis (H&E, original magnification: x100)

B) Larger magnification of histological slide with atypical large lymphocytes and hemophagocytosis (arrowhead) (original magnification: x200)

C) Positive staining for CD3 (original magnification: x400)

D) Positive staining for CD8 (original magnification: x400)

E) Negative staining for CD30 (original magnification: x200)

F) Negative staining for CD56 (original magnification: x200)

G) Positive staining for CD68 (original magnification: x400)

H) Positive staining for TIA-1 (original magnification: x400)

I) Negative staining for granzyme B (original magnification: x400)



## DISCUSSION

SPTL, first described in 1991 by Gonzales *et al.* (4), is a rare lymphoma showing features imitating panniculitis, and is frequently associated with hemophagocytic syndrome (5). According to European Organization for Research and Treatment of Cancer – World Health Organization (EORTC-WHO) classification, only SPTL showing  $\alpha/\beta$  T-cell phenotype (SPTL-AB) is nowadays considered true SPTL, while SPTL showing  $\gamma/\delta$  T-cell phenotype (SPTL-GD) belongs to the provisional group of cutaneous  $\gamma/\delta$  T-cell lymphomas (5). The most typical clinical presentations of SPTL-AB are nodular skin lesions or deeply seated plaques, whereas ulcers are less commonly observed. About 20% of patients with SPTL-AB have concomitant autoimmune disorder (5). To the best of our knowledge, this is the first description of a patient with NF-1 developing SPTL. However, patients with NF-1 were reported to have developed many other lymphomas and hematologic malignancies (6-9).

The long-term course of the disease strongly suggests that our patient suffers from SPTL-AB, as SPTL-GD usually presents with more aggressive behavior and a much poorer outcome of treatment. SPTL can also be easily misdiagnosed, both clinically and histologically, as benign panniculitis, including lupus panniculitis, which may delay correct diagnosis for a long time. SPTL-AB sometimes responds to immunosuppressive treatment with prednisone and cyclosporine, particularly during the initial phase of the disease (10,11), as also observed in our patient. However, not all patients achieve remission on immunosuppression, the response is usually short, and the disease progresses over time (12). Regarding other therapies, the CHOP regimen is the most popular one (5,12,13). However, we used another treatment scheme for our patient, namely a combination of fludarabine and cyclophosphamide. That treatment modality was used with success by our group in the past to treat another case of primary cutaneous T-cell lymphoma (14). Interestingly, other authors also reported promising results of fludarabine-based regimens in patients with SPTL lymphoma (15-18). However, this was the first time our combination of chemotherapeutics (FC) was used to treat SPTL.

## CONCLUSION

Our case report provides new data on SPTL, since, to the best of our knowledge, this is the first case of SPTL in a patient with NF-1. Furthermore, an almost complete remission was achieved using a combination of fludarabine and cyclophosphamide, a treatment regimen that was used for the first time for this type of lymphoma.

## References

1. Williams VC, Lucas J, Babcock MA, Gutmann DH, Korf B, Maria BL. Neurofibromatosis type 1 revisited. *Pediatrics* 2009;123:124-33.
2. Neurofibromatosis. NIH Consensus Statement Online 1987;6:1-19.
3. Mazur G, Wróbel T, Butrym A, Duszyńska W, Reksa D, Szepietowski J, *et al.* Adult acute lymphoblastic leukaemia in the course of neurofibromatosis type I – case report. *Pol J Environ Stud* 2006;15:82-5.
4. Gonzalez CL, Medeiros LJ, Braziiel RM, Jaffe ES. T-cell lymphoma involving subcutaneous tissue: a clinicopathologic entity commonly associated with hemophagocytic syndrome. *Am J Surg Pathol* 1991;15:17-27.
5. Willemze R, Jansen PM, Cerroni L, Berti E, Santucci M, Assaf C, *et al.* Subcutaneous panniculitis-like T-cell lymphoma: definition, classification, and prognostic factors: an EORTC Cutaneous Lymphoma Group Study of 83 cases. *Blood* 2008;111:838-45.
6. Kim SJ, Seo JH, Lee SW, Han E, Lee ES, Cha SH, *et al.* A case of non-Hodgkin's lymphoma in a patient with neurofibromatosis type 1. *Korean J Intern Med* 2003;18:202-5.
7. Zein G, Yu E, Tawansy K, Berta A, Foster CS. Neurofibromatosis type 1 associated with central nervous system lymphoma. *Ophthalmic Genet* 2004;25:49-51.
8. Dohi O, Hatori M, Ichinohasama R, Hosaka M, Hashimoto S, Kokubun S. Diffuse large B-cell lymphoma arising in a patient with neurofibromatosis type I and in a patient with neurofibromatosis type II. *Tohoku J Exp Med* 2006;208:169-76.
9. Krüger S, Kinzel M, Walldorf C, Gottschling S, Bier A, Tinschert S, *et al.* Homozygous PMS2 germline mutations in two families with early-onset haematological malignancy, brain tumours, HNPCC-associated tumours, and signs of neurofibromatosis type 1. *Eur J Hum Genet* 2008;16:62-72.
10. Tsukamoto Y, Katsunobu Y, Omura Y, Maeda I, Hirai M, Teshima H, *et al.* Subcutaneous panniculitis-like T-cell lymphoma: successful initial treatment with prednisolone and cyclosporin A. *Intern Med* 2006;45:21-4.
11. Rojnuckarin P, Nakorn TN, Assanasen T, Wannakrairot P, Intragumtornchai T. Cyclosporin in subcutaneous panniculitis-like T-cell lymphoma. *Leuk Lymphoma* 2007;48:560-3.
12. Go RS, Wester SM. Immunophenotypic and molecular features, clinical outcomes, treatments, and prognostic factors associated with subcutaneous panniculitis-like T-cell lymphoma: a systematic analysis of 156 patients reported in the literature. *Cancer* 2004;101:1404-13.
13. Lee DW, Yang JH, Lee SM, Won CH, Chang S, Lee MW. Subcutaneous panniculitis-like T-cell lymphoma: a clinical and pathologic study of 14 Korean patients. *Ann Dermatol* 2011;23:329-37.
14. Mazur G, Maj J, Wróbel T, Hryniewicz-Gwóźdź A, Niezgoda E, Kuliczkowski K. Treatment of cutaneous T-cell

- lymphomas with purine analogues (fludarabine and 2-chlorodeoxyadenosine). *J BUON* 2003;8:247-51.
15. Au WY, Ng WM, Choy C, Kwong YL. Aggressive subcutaneous panniculitis-like T-cell lymphoma: complete remission with fludarabine, mitoxantrone and dexamethasone. *Br J Dermatol* 2000;143:408-10.
  16. Go RS, Gazelka H, Hogan JD, Wester SM. Subcutaneous panniculitis-like T-cell lymphoma: complete remission with fludarabine. *Ann Hematol* 2003;82:247-50.
  17. Wells J, Kosky CA, Scolyer RA, Lee S, Bye PT, Young GA, *et al.* Unusual case of subcutaneous panniculitis-like T-cell lymphoma. *Australas J Dermatol* 2004;45:114-8.
  18. Chim CS, Loong F, Ng WK, Kwong YL. Use of fludarabine-containing chemotherapeutic regimen results in durable complete remission of subcutaneous panniculitis-like T-cell lymphoma. *Am J Clin Dermatol* 2008;9:396-8.

