



Brinzolamide-induced retinopathy in neonatal rats: an alternative animal model of retinal neovascularization

Y. A. DYOMIN¹
P. V. BILETSKA²
I. D. GAPUNIN³

¹ Kharkiv Medical Academy
of Postgraduate Education,

² Institute for Problems of Cryobiology
and Cryomedicine of the National Academy
of Sciences of Ukraine, Cryomorphology department

³ Specialized Clinic of Ukrainian Ministry of Health

Correspondence:

Polina Biletska
Institute for Problems of Cryobiology
and Cryomedicine of the National Academy
of Sciences of Ukraine
Cryomorphology department
61001, Derzhavinska str. 2, 363. Kharkiv. Ukraine.
E-mail: doctor_ps@mail.ru

Abstract

Background and Purpose: Neovascular retinal pathology is still uncertain. Thus, there is great need to investigate new modeling, diagnostic and treatment technologies. Brinzolamide induces a metabolic acidosis via an alternative biochemical mechanism (bicarbonate loss). In the present study the influence of brinzolamide-induced acidosis on preretinal neovascularization in neonatal rat was investigated.

Materials and Methods. In our study we used newborn Wistar rats raised in two litters. Newborn rats ($n=17$) were randomized to either intraperitoneal brinzolamide in dose 200 mg/kg ($n=9$) or saline ($n=8$), twice daily from days 2 to 7. After 5 days of recovery all rats were euthanized. Six paraffin-embedded sections prepared in a standard manner and stained with hematoxylin and eosin. To investigate the damage, we evaluated the number of cells in the ganglion cell layer (GCL) and the thicknesses of the inner plexiform layer (IPL), inner nuclear layer (INL), outer plexiform layer (OPL), and outer nuclear layer (ONL). The cells in GCL and the thicknesses of the IPL, INL, and ONL at a distance between 375 and 625 μm from the optic disc were measured.

Results: Preretinal neovascularization was found in 71% retinas, from brinzolamide-injected rats. Cataract formation was detected in 100% eyes after brinzolamide injections. All retinas from saline group were negative for neither neovascularization nor cataract. Brinzolamide rat model retinas showed decrease in the thicknesses of the retinal layers.

Conclusion: In the present study, we report that brinzolamide (a drug causing metabolic acidosis primarily by bicarbonate loss) is associated with preretinal neovascularization in the neonatal rat. So this method can be suitable model for other neovascular pathologies of the eye.

INTRODUCTION

Many blinding retinal diseases, including diabetic retinopathy, age related macular degeneration, retinopathy after central retinal vein occlusion, and branch retinal vein occlusion and retinopathy of prematurity, involve the development of abnormal vasculature (1, 2, 3, 4). Numerous clinical and experimental observations have indicated that ischemia with following hypoxia and acidosis of nervous tissue is the main cause for retinal neovascularization. Stimulation of angiogenesis

is performed by various angiogenic proteins, including several growth factors, whereas the VEGF family has been demonstrated to be a major contributor to angiogenesis (1, 3, 5). At least five retinal cell types have the ability to produce VEGF. These include the retinal pigmented epithelium, astrocytes, Muller cells, endothelial and ganglion cells. However, they differ widely in their responses to hypoxia; *in vitro* studies show that Muller cells and astrocytes generally produce the greatest amounts of VEGF in hypoxic and acidosis conditions (4, 5, 6). Animal models of oxygen-induced retinopathy have become major models for pathological angiogenesis resulting from ischemia. Studies suggest, excess CO₂ inhalation, NH₄Cl gavage and intraperitoneal acetazolamide in the neonatal rat produce an acidosis-induced retinopathy which serves as a model for neovascular retinopathy (7, 8, 9). Carbonhydrase inhibitors (CAI) induce a metabolic acidosis via an alternative biochemical mechanism (bicarbonate loss versus hydrogen ion load) (9, 10). The only solution of CAI, released in Ukraine is brinzolamide. In the present study the influence of brinzolamide-induced acidosis on preretinal neovascularization in neonatal rat was investigated.

MATERIALS AND METHODS

In our study we used newborn Wistar rats raised in two litters. Animals were treated according to European Convention for the Protection of Vertebrate Animals used for Experimental and Other Scientific Purposes (Strasbourg, 18.III.1986). The rats were kept under controlled lighting conditions (12:12-h light/dark). Newborn rats (n=17) were randomized to either intraperitoneal brinzolamide in dose 200 mg/kg (n=9) or saline (n=8), twice daily from days 2 to 7. After 5 days of recovery direct ophthalmoscopy was performed. All brinzolamide-injected animals had dense lenticular opacification. Saline-injected rats were negative for cataract formation. The opaque region was always restricted to the center of the lens. It was impossible to recognize retinal changes under ophthalmoscopy in brinzolamide group. At the same day all rats were euthanized. Each eye was enucleated and kept immersed for at least 21 day at 4°C in a fixative solution containing 4% paraformaldehyde. Six paraffin-embedded sections (thickness, 5 µm) cut through the optic disc of each eye were prepared in a standard manner and stained with hematoxylin and eosin. Light microscope images were photographed using a digital camera. To investigate the damage in each retinal layer after intraperitoneal brinzolamide or saline injections, we evaluated the number of cells in the ganglion cell layer (GCL) and the thicknesses of the inner plexiform layer (IPL), inner nuclear layer (INL), outer plexiform layer (OPL), and outer nuclear layer (ONL). The cells in GCL and the thicknesses of the IPL, INL, and ONL at a distance between 375 and 625 µm from the optic disc were measured on the photographs in a masked fashion by a single observer.

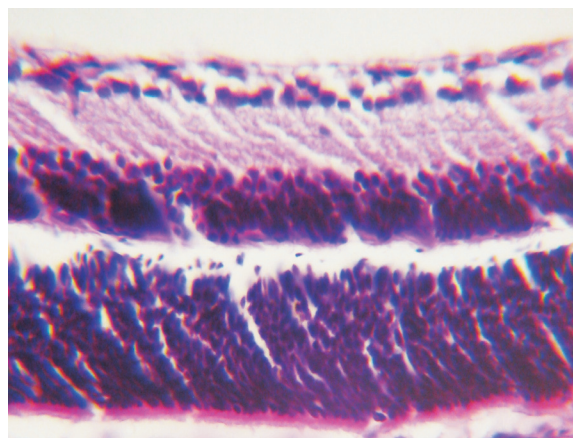


Figure 1. Normal rat retina. Hematoxylin-eosin staining. ×100

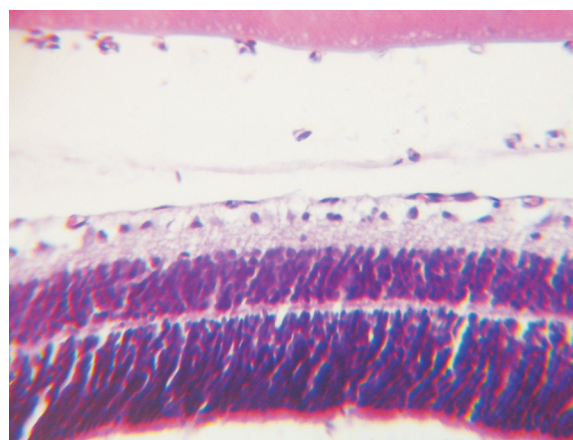


Figure 2. Neovascular tufts above ILM, in the vitreous cavity, near by lens posterior capsule. Hematoxylin-eosin staining. ×100

RESULTS

All retinas from saline group were negative for neovascularization (Fig. 1).

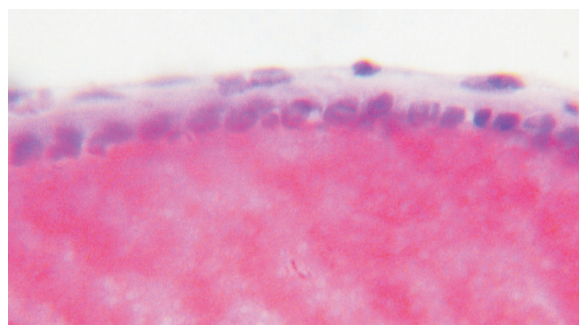
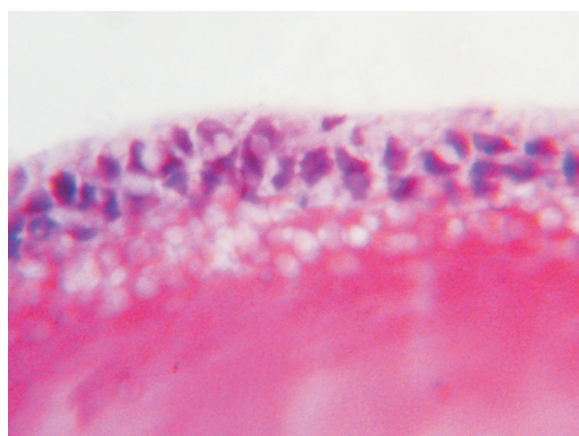
Preretinal neovascularization was found in 71% retinas, from brinzolamide-injected rats. Newly formed capillaries were found above the internal limiting membrane (ILM) in a mid- and far retinal periphery, protruded in the vitreous cavity. The capillary wall consists of single endothelial cell layer and its basement membrane. Erythrocytes were found in the capillary lumen (Fig. 2).

Brinzolamide rat model retinas showed decrease in the thicknesses of the IPL, OPL, INL and ONL compared to those in normal rat retinas. There were no significant differences in the number of cells in the GCL between the brinzolamide model and normal rats' retinas. However the depth of the GCL varied significantly between experimental groups (Tab.1).

Bilateral cataract formation in all brinzolamide-injected rats was the side effect, so ophthalmoscopy was not

TABLE 1Morphometric changes in experimental rats retinas (μm).

	Saline		Brinzolamide	
	Mean	\pm SD	Mean	\pm SD
Central zone	204	2,16	163,77*	1,8
Periph. zone	154,06	1,61	122,5*	1,33
IPL	42	2,19	39,66*	2,49
OPL	18	1,63	14,77*	1,8
INL	40,94	1,77	28*	1,53
ONL	55	1,89	35*	2,05
GCL	23,06	1,76	19*	2,05

* - significantly different from saline ($p < 0,05$)**Figure 3.** Swelling of the lens capsule; hematoxylin-eosin staining $\times 1000$, immersion.**Figure 4.** Proliferation of epithelial cells; hematoxylin-eosin staining $\times 1000$, immersion.

performed. We founded swelling of the lens capsule (Fig.3), proliferation of epithelial cells (Fig.4), vacuolization of the hyaline layer, disorder or collapse of the lens.

Hence, brinzolamide induces excessive loss of bicarbonate via the kidneys. It leads to metabolic acidosis and results tissue hypoxia. Neural cells in hypoxic conditions start to produce angiogenic factors, among them VEGF. Angiogenic factors turn on neovascularization cascade.

DISCUSSION

There is well known oxygen-induced neovascular retinopathy animal model. Oxygen using needs special precautions and consumes labor-intensive manipulations.

Metabolic acidosis involves a decreased serum HCO_3^- concentration along with a decrease in pH. In metabolic acidosis, the body compensates for the decrease in pH by increasing the respiratory rate in an effort to decrease PCO_2 and H_2CO_3 levels. Metabolic acidosis can be caused by one or more of the following four mechanisms: increased production of fixed metabolic acids or ingestion of fixed acids such as salicylic acid, inability of the kidneys to excrete the fixed acids produced by normal metabolic processes, excessive loss of bicarbonate via the kidneys or gastrointestinal tract, or an increased serum Cl concentration (13). Indeed other studies suggest, excess CO_2 inhalation, NH_4Cl gavage and intraperitoneal acetazolamide in the neonatal rat produce an acidosis-induced neovascular retinopathy (6, 8, 10).

CO_2 application requires expensive laboratory equipment with hermetic gas contour. NH_4Cl gavage is related to technical problems: putting feeding intestinal tube into neonatal rat's stomach.

We can't apply acetazolamide injections, because this medicine didn't release in Ukraine. So we decided to create available, simple, cheap, safe and less labor-consuming experimental model of neovascular retinopathy. In our study we used brinzolamide, carboanhydrase inhibitor. We needed just sterile syringe 28G, sterile 0,1% brinzolamide solution, preoperative injection site preparation with betadine. Intraperitoneal injection is technically simple procedure.

Preretinal neovascularisation occurred in 71% rats received high dose brinzolamide compared to 59% in acetazolamide study. Pathology retinal findings from experimental animals were similar to those in acetazolamide study (10).

Brinzolamide and acetazolamide have the same fairly well protein-bound (60%), but brinzolamide's whole half-life is very long (111 days in human) compared to hours in acetazolamide. We suppose that this is key point of brinzolamide use in neovascular retinopathy modeling (11, 12).

Besides, cataract formation was observed in all animals, received brinzolamide. We assume that high dose (200 mg/kg) brinzolamide, causing prolonged acidosis, leads to metabolic cataract formation.

In conclusion, in the present study we report that brinzolamide (a drug causing metabolic acidosis primarily by bicarbonate loss) is associated with preretinal neovascularization in the neonatal rat. Retinal neovascularization was found above the internal limiting membrane in mid- and far periphery. So this method can be suitable model for other neovascular pathologies of the eye such as diabetic retinopathy, age related macular degeneration, retinopathy after central retinal vein occlusion, and branch retinal vein occlusion and retinopathy of prematurity. The side effect of intraperitoneal brinzolamide injections was cataract formation. This animal model is much safer than oxygen-induced one, because no explosive gas is used.

REFERENCES

1. CAMPOCHIARO P A 2003 Ocular neovascularization: a valuable model system. *Oncogene* 22: 6537–6548
2. GARIANO R F, GARDNER T W 2005 Retinal angiogenesis in development and disease. *Nature* 438: 960–966
3. GARIANO R F 2003 Cellular mechanisms in retinal vascular development. *Prog Retin Eye Res* 22: 295–306
4. SCHLINGEMANN R O, WITMER A N 2009 Treatment of retinal diseases with VEGF antagonists. *Prog Brain Res* 175: 253–267
5. WITMER A N, VRENSSEN G F J M, VAN NOORDEN C J F, SCHLINGEMANN R O 2003 Vascular endothelial growth factors and angiogenesis in eye disease. *Prog Retin Eye Res* 22: 1–29
6. HOLMES J M, ZHANG S, LESKE D A, LANIER W L 1999 Metabolic acidosis-induced retinopathy in the neonatal rat. *Invest Ophthalmol Vis Sci* 40: 804–809
7. GERHARDT H, GOLDING M, FRUTTIGER M 2003 VEGF guides angiogenic sprouting utilizing endothelial tip cell filopodia. *J Cell Biol* 161: 1163–1177
8. HOLMES J M, ZHANG S, LESKE D A, LANIER W 1998 Carbon dioxide-induced retinopathy in the neonatal rat. *Curr Eye Res* 17: 608–616
9. PATAN S 2000 Vasculogenesis and angiogenesis as mechanisms of vascular network formation, growth and remodeling. *J Neurooncol* 50: 1–15
10. ZHANG S, HOLMES J M, LESKE D A, LANIER W 2001 Pre-retinal neovascularization associated with acetazolamide-induced systemic acidosis in the neonatal rat. *Invest Ophthalmol Vis Sci* 40: 1066–1071
11. Alcon Inc. 2003 Azopt (brinzolamide) ophthalmic suspension 1% prescribing information. Fort Worth, TX.
12. W A WATSON, J C GARRELTS, P D ZINN, J C GARRIOTT, T L MCLEMORE, W A CLEMENTI 1984 Chronic acetazolamide intoxication. *Journal of toxicology. Clinical toxicology* 22(6): 549–63
13. SHAPIRO J I, KAEHNY W D 2003 Pathogenesis and management of metabolic acidosis and alkalosis. In: Schrier R W (ed.) Renal and electrolyte disorders. Lippincott Williams & Wilkins, Philadelphia, p 115–153