

HOMICIDE AND SUBSEQUENT CATATONIA ASSOCIATED WITH A LARGE ARACHNOID CYST: CASE REPORT

Branimir Margetić, Tija Žarković Palijan and Dražen Kovačević

Department of Forensic Psychiatry, Dr. Ivan Barbot Neuropsychiatric Hospital, Popovača, Croatia

SUMMARY – The existence of a focal brain lesion that might be the crucial cause for the development of diverse psychiatric phenomena and certain characteristics of personality is often a controversial issue. The patient was a 29-year-old male when he killed his father with a single knock with the blunt side of an axe. Subsequently to the act, the patient developed a 10-month-long catatonic stupor during which he experienced intensive fear, delusions, and affective symptoms. He was an emotionally blunted person with no medical record and without prior history of aggressive behavior. Magnetic resonance image revealed a large, right-sided arachnoid cyst that was associated with right temporal and frontal lobe hypoplasia and bilateral changes of perfusion in peri-insular regions. The treatment with clozapine and diazepam showed to be therapeutic. This could be the second case of homicide committed by a person with arachnoid cyst and without past history of aggression, and the second description of an adult patient with cyst who developed catatonic stupor. This is the first description of long-lasting organic catatonic stupor treated with clozapine and diazepam. Relevant literature is reviewed and some controversial issues are discussed.

Key words: *Arachnoid cysts; Homicide; Catatonia; Stupor; Clozapine; Case report*

Introduction

Arachnoid cysts are rare space-occupying lesions containing cerebrospinal fluid (CSF) that can occur in any area of the central nervous system, but are more frequent in the sylvian fissure. Although benign and often accidentally diagnosed¹, arachnoid cysts can be related to a wide spectrum of symptoms including focal neurological symptoms, headache, seizures, dizziness, nausea, and so on. Psychiatric conditions, assumed to be related to cysts, have been rather rarely described, although there are descriptions of patients with psychotic and affective features, catatonic symptoms and aggressive behavior^{2,3}.

Among very few case reports of aggressive behavior, there are only two reports of homicide committed by persons with arachnoid cysts^{4,5}, and in one of these cases homicide was committed by a person without prior history of violent behavior⁴. There are also a few case reports of patients with arachnoid cyst who developed catatonic features⁶⁻⁸, but only one of these reports is related to an adult patient⁸.

Our aims are to report the first case of a patient with a large arachnoid cyst who committed homicide and also developed catatonic stupor, affective and psychotic symptoms subsequently to the act, to discuss some controversial aspects related to the possible association between the existence of the cyst and psychiatric phenomenology, and to emphasize similarities and differences with previous cases.

Because of great differences in legal systems worldwide, controversial aspects that are related to the characteristics of the Croatian legal system are not a subject of this article.

Correspondence to: *Tija Žarković Palijan, MD, PhD*, Dr. Ivan Barbot Neuropsychiatric Hospital, Jelengradska 1, HR-44317, Popovača, Croatia
E-mail: tija-zarkovic.palijan@sk.t-com.hr

Received October 15, 2012, accepted November 20, 2013

The patient gave his informed consent for publication of this case study.

Case Report

S. D., unemployed worker, with no prior history of violent behavior or psychiatric medical history, was aged 29 when he abruptly killed his father after a short argument in a forest nearby their house, in February 2008.

He admitted the homicide and described it as impulsive and unintentional act provoked by his father. In the following months, while being in custody, he developed a condition described as “apathy and refusing to give adequate answers”. These were the reasons for his forensic evaluation that begun in May 2008 and was followed by hospitalization at forensic department.

During and after admission, he was in catatonic stupor and most of the time he was lying in bed absolutely immobile. *Cereza flexibilitas* and short-lasting sporadic stereotyped movements of the left hand were also noted. He would speak only a few words daily, mostly yes or no, showing no signs of affective reactions. Echophenomena were not present. He would swallow food and liquids automatically, showing no intention to take them spontaneously. He was afebrile, without rigidity, with a normal and stable blood pressure (115/75-125/85 mm Hg) and heart rate of 70-86 bpm.

Contact with his mother revealed that the patient might be described as an emotionally blunted person with lack of interest for normal social contacts (e.g., had no friends, never had a girlfriend). She told that her son had not been going to a doctor for the last few years, but also described an episode that had lasted a few months and had taken place about a year prior to the homicide, after he had lost his job. During that episode, the patient used to sit motionless, mute, and unresponsive for hours. His mother told us that the patient looked “strange, distant and fearful”. According to his mother, he also often complained of headaches that had been intensive in days prior to the homicide, but nothing unusual happened on the day when the act was committed. She denied that her son was prone to impulsive reactions; quite contrary, but described her late husband as an impulsive and aggressive per-

son who had been beating her and the patient many times, although his aggression towards the patient was rather psychical in recent years (dominantly humiliating). She also declared that her late husband had two brothers who had committed suicide years before, but she was not able to say whether they had been treated for any psychiatric condition or not.

The treatment with intramuscular diazepam 30 mg/daily was initiated immediately after admission. During the next days, in parallel with physical and neurological examination that could not reveal any certain pathology, the usual tests were conducted and showed some irregular values. Electroencephalography revealed unspecific changes in the median temporoparietal zones bilaterally. Chest x-ray revealed the existence of pulmonary emphysema. Initial creatine phosphokinase level was 485 U/L (normal <177) and normalized five days later to 141 U/L (when treated with oral medications). Triiodothyronine (T3) level was slightly decreased, 1.04 nmol/L (normal 1.3-3.1 nmol/L), while the levels of thyroxine (T4) and thyrotropin (TSH) were within the normal limits.

As no improvement of the condition was noted in the first three days of treatment with diazepam, olanzapine 5 mg/day was added. Ten days later, the patient developed bilateral leg edema assumed to be a side effect of olanzapine treatment. Thus, olanzapine was discontinued and treatment with clozapine was initiated at a dose of 50 mg/day and was increased to 225 mg/day over the next three weeks.

As there was no improvement of the long-lasting stupor, which could not be explained by slightly decreased T3 (while the levels of T4 and TSH were normal), brain imaging was needed. Magnetic resonance imaging (MRI) of the brain (June, 2008) revealed the presence of a large arachnoid cyst (type 3, most severe according to Galassi classification)⁹ at the level of the right sylvian fissure with a marked mass effect, recognized as the existence of the right temporal and frontal lobe hypoplasia. MRI also showed diffuse zones of hyperintensity in the white matter, most prominent bilaterally in peri-insular regions, assumed to be the consequences of chronic perfusion changes (Figs. 1 and 2). The patient did not show signs of increased intracranial pressure or focal neurologic deficits, even though there was a mass effect. Although surgical cyst reduction is assumed to be a quite safe procedure that

might result in complete remission of psychiatric symptoms¹⁰ because the risk of operating was higher than the potential benefits, the neurosurgical team proposed conservative management.

In September 2008, the court decided that the patient was not competent to stand trial and that he had to be hospitalized at department of forensic psychiatry.

In the next period, until December 2008, only slow improvement was noticed. The patient started to move more while lying in bed, but no improvement of verbal communication was noticed in that period. After December 2008, he started to walk spontaneously. In February 2009, he began speaking more than just a few words daily. In April 2009, he started speaking slowly, his short sentences had normal structure, and his answers were adequate. Although his conversation skills significantly improved, he was not showing spontaneity, and he seldom asked for anything.

However, we were finally able to get more detail from the patient. He described himself as “constricted since adolescence”, telling that he had no interests for communicating with, or meeting people for many years, but that he had had a lot of friends during his childhood.

The homicide took place in a forest while he and his father were working. The patient was working with an axe and his father with a chain saw. He said that his father had started to yell at him, probably because he was not working according to his expectations, and remembered that his father had made a few steps toward him with the chain saw turned on in his hands. When his father approached to a distance of 2-3 steps, he hit his father once on the head with the blunt side of his axe. After the act, he left the axe on the ground, went home, told his mother that he had probably killed his father, and then called the police.

He told us that he had had no intention to kill. He “felt fear in a split second” and the act was like a “reflex”. He could not tell us whether his father had intended to attack him with the saw or not, but could remember that subsequently to the act, he felt no remorse or fear and that he was without any intensive feelings. Accordingly, he declared that he had had intensive fear only in a “split second”.

His recent view on the act was that he had made a mistake. Not because he killed his father, the person who had been humiliating and mistreating the rest of the family for years, but because he was separated

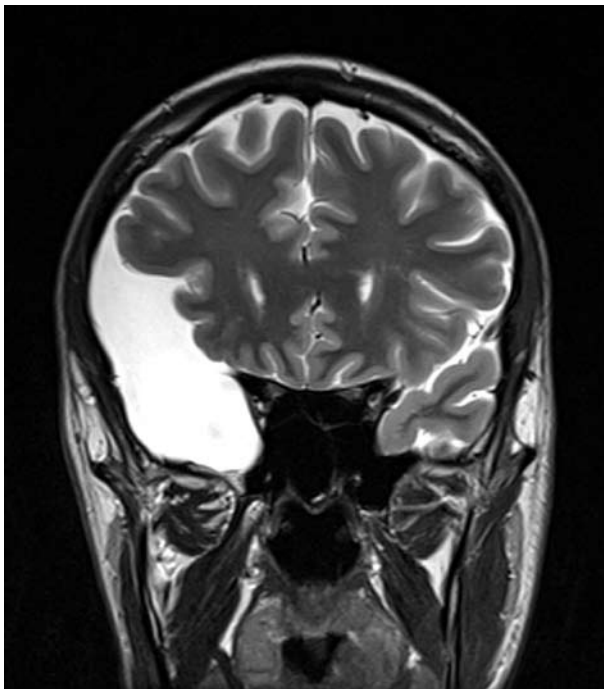


Fig. 1. T3-weighted magnetic resonance image (coronal plane) showing a large oval mass.

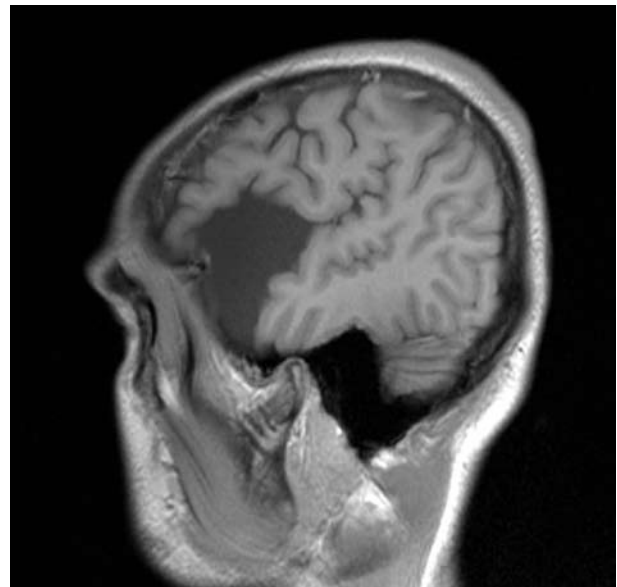


Fig. 2. T3-weighted magnetic resonance image (sagittal plane) showing an ovoid-cystic lesion in the middle cranial fossa. The mass effect on the right temporal and frontal lobe (with hypoplasia) determined by the arachnoid cyst is visible.

from his mother and two sisters. There was not and there is currently no remorse related to the act.

The patient also described his late father as an aggressive and impulsive person. He believed that the reason that he had not been attacked by his father during prior years was that he had “never been opposing”, but “used to walk away when he had humiliated me with no reason”. He declared that in such situations, he had not been overwhelmed by emotions, but he “had always tried to avoid serious conflict”.

He remembered that he had stopped talking during custody. He felt alone, helpless, worthless, without future, could not think anything else but that he would be in prison for many years. He assumed that his position was even worse after hospitalization at department of forensic psychiatry. He was terrified, aghast, sad and certain that somebody (staff or other patients) would attack him. He declared that, although he was immobile, he was aware of what was happening in his surrounding.

He also explained how he had felt during his (most probably) first catatonic episode (after losing the job). He was not angry, sad, or fearful, but felt empty and humiliated. At the time, he thought that he had no future, and that “all was a dirty game of his boss who was jealous because he was an excellent worker”. In fact, the patient described that during both of his catatonic episodes he also had delusions and affective symptoms.

Accordingly, apart from the fact that the patient's condition was initially diagnosed as organic personality disorder and organic catatonic disorder (*per* ICD-10), it was finally possible to get information on the existence of psychotic and affective symptoms during catatonia.

Further improvement was noted after April 2009. The patient became more spontaneous, his affective reactions could be noted, his speech became faster.

Psychological testing was carried out in June 2009. On the WB-2, his verbal IQ was 94, nonverbal IQ was 66, and full scale IQ was 80. The 28-point discrepancy between verbal and non-verbal scores was significant and suggestive of impaired function of the right brain hemisphere. Graphomotor coordination (Benton test) abilities were significantly impaired. The tests of language function including comprehension, word finding, expressive speech, reading and writ-

ing were within the normal limits. Memory function (Wechsler Memory Scale and Rey Complex Figure) was impaired and suggestive of organic lesions. Personality testing with the MMPI and the Rorschach test revealed significant existence of cognitive and emotional empowerment, confusion, impairments in testing of reality, tendency to confabulation and dissimulation, decreased threshold for impulsive reactions, and increased risk of aggressive behavior.

The overall impression based on psychological testing suggested the existence of organic lesions of the right brain hemisphere in an emotionally blunted, anxious, suspicious, projective person that also showed an increased risk of impulsive aggression.

Speaking of interests, during 2010, the patient was saying that his interests in contacts with other persons were much improved in comparison with the years prior to hospitalization, although he remained to be distant and practically without expression of emotions.

Since hospitalization, the patient has not been showing any signs of aggression or impulsive reactions.

To exclude “spontaneous” disappearance or change in the cyst volume as the possible reason for recovery, brain MRI was obtained again in December 2010, but revealed the findings that corresponded to those previously described.

An interesting finding was normalization of T3 levels (1.51 in April 2009 and 2.16 in May 2010).

Discussion

A basic question related to the possibility of a causal relationship between “focal” brain dysfunction and development of different psychiatric presentations in many cases remains to be the same: whether the existence of a lesion was the crucial cause for the development of diverse psychiatric phenomena and certain characteristics of personality¹¹. Surgical intervention may resolve this question only in selected cases¹².

Homicide

Data on the incidence of arachnoid cysts are rather confusing. While it has been estimated that arachnoid cysts are rare and account for approximately 1% of all nontraumatic intracranial space-occupying le-

sions¹³, in one large study MRIs were conducted in 2,536 healthy young male applicants for flying duties in the German Air Force, and in this study the frequency of arachnoid cysts was 1.7%¹. This latter finding suggests not only that in most cases the diagnosis is accidental, but also that violent acts committed by persons with the cysts may be more common than described. Thus, it is rather intriguing that the literature on violence associated with cysts is so rarely present. As mentioned above, there are only a few descriptions of violent behavior of persons with arachnoid cysts, but only one description related to a homicide committed by a person without prior psychiatric history or violent behavior⁴.

In the first case, the homicide was associated with a large left-sided cyst, and positron emission tomography showed left frontal and temporal hypometabolism. In our case, MRI showed a large right-sided cyst with right temporal and frontal lobe hypoplasia. Both patients had been showing long-lasting inability to express emotions, and in both cases the act was not followed by subsequent subjective experience of intensive emotions. Yet, the most striking similarity is that in both cases the patients had no past history of violent behaviors and such behaviors were not noted subsequently to the acts. This is especially perplexing in our case.

Early studies on homicidal aggression often emphasized the importance of psychodynamic factors, such as the possibility in which the child who killed a parent acted upon an unconscious parental wish¹⁴. Our patient had been raised with aggressive father who had problems with impulse control. Moreover, the fact that two father's brothers had committed suicide is in accordance with the findings on familial aggregation of suicidal behavior that is independent of psychopathology, but is associated with aggressive behavior¹⁵. Accordingly, because of the possible genetic factors and environmental influences¹⁶, one may well assume that our patient was at an increased risk of being an aggressive and/or impulsive person. However, he demonstrated such behavior only once. Here, a speculative postulation might be that the long-lasting cyst influenced the patient's personality, made him apathetic, as sometimes focal brain lesions do¹⁷. In this case, apathy might be not just the absence or lack of feelings, emotions or interests, but also lead to the

lack of motivation for social interaction including aggressive behavior, as a kind of social interaction.

The authors of the first report suggest that the patient's "violent behavior represents stimulus-bound aggression, triggered by a novel physical threat and unchecked by learned social restraints owing to the presence of ventral prefrontal dysfunction"⁴. Although speculative, the explanation seems acceptable for our case. The close approach of the patient's father with a chain saw turned on in his hands was something the patient did not expect. He felt fear in a "split second" and acted in the next moment without premeditation. The fact that the act was done without premeditation may suggest that dysfunction of prefrontal cortex and the lack of its inhibitory role was important in this case. However, we may go further with our speculations.

Although many different structures are involved in behavior associated with strong emotions, the coordination between amygdala and prefrontal cortex (PFC) is probably crucial¹⁸. The findings related to the role of amygdala in the regulation of aggression support the conclusion that these structures provide rapid, largely unconscious processing of information on social circumstances and threats. This information should be normally integrated in higher-order centers (PFC) for further elaboration and prediction of the consequences of actions¹⁹. Being exposed to connote threat would activate the amygdala, but information about the social context would also be derived from PFC. It has been suggested that PFC normally inhibits the amygdala and suppresses negative emotions¹⁸, and that deficits in normal PFC activity are related to increased vulnerability to impulsive aggression¹⁹. Moreover, the amygdala are involved in conditioned, unconditioned responses to stimuli, in extinction-related processes, and living in certain environment should have some influence on cellular plasticity and neurotransmitter function in the brain structures involved in the regulation of behavior associated to emotions²⁰.

One may emphasize that the patient lived in aggressive environment, that he was frightened of his aggressive father, and that in such environment he "learned" to choose "flight" without intensive fear instead of fight and fear. During years of being aggressively maltreated, he learned to make optimal decision, i.e. "flight", whenever he could. In a new situation and

in the moment when he felt fear, an aggressive reaction was instant. The problem is the fact that normal persons show important varieties in their skills in suppressing negative emotions¹⁷, and the main unresolved question remains to be: what would the reaction of a normal person (without cyst) with similar past experiences and in similar situation be?

Moreover, it is known that focal brain lesions may provoke aggression, but persons with brain lesions often show dramatic and long-lasting discrepancy between provocation and response, where minor provocations may induce life-threatening aggressive outbursts²¹. The patient showed aggressive reaction only once, that reaction was only one kick, and finally the provocation should not be characterized as a minor one.

There is a body of literature based on animal studies that implicates the relation between decreased impulsivity and certain brain lesions. Moreover, stereotactic amygdalotomy, sometimes assumed to be a valid surgical treatment option for selected cases of medically refractory aggression²², is basically a “therapeutic brain injury”. It means that certain changes in brain morphology and/or neurotransmitter functions may provoke or inhibit certain behaviors, including aggression. Accordingly, an interesting question is: would it be possible that arachnoid cyst was in this case associated with a decreased frequency of violent behavior, but also with an increased risk of consciously uncontrolled impulsive acts?

Finally, in our case, the patient described the act as impulsive. If the perpetrator is not a psychopathic person, this type of aggression is often associated with subsequent feelings of guilt or remorse²³. Yet, it was different. Our patient, similarly as the patient described in the first case, was showing a long-lasting inability to express emotions, including feelings of guilt or remorse related to the act. Such inability may be the consequence of brain lesion, especially of prefrontal cortex²⁴.

Catatonia, delusions and affective features

As mentioned above, psychiatric syndromes associated with arachnoid cysts are relatively rarely described in the literature. It seems that most often patients developed schizophrenia-like psychosis, but there are only three previously described cases of patients with arachnoid cysts who also developed catatonia⁶⁻⁸.

In our case, it is most probable that the patient had developed two catatonic episodes. The first episode was subsequently to losing his job, and the second subsequently to the homicide. In other words, after he had been faced with stress. Although the view of catatonia as a motor disorder remains dominant, there is also the thesis that “catatonia may primarily be a fear reaction, closely related to the animal defense strategy tonic immobility”, and “evolutionary-based fragments of primitive defenses against predators that now misfire under conditions of exaggerated stress”²⁵. Furthermore, structural imaging studies suggest cortical and subcortical dysfunction in catatonia. Some of these studies emphasize prefrontal and parietal dysfunction²⁶, but there is also a report on a patient whose MRI scan showed a right temporal medial lesion with amygdala atrophy²⁷. Thus, it is possible that the cyst in certain circumstances, such as other brain lesions, may represent an additional factor for the development of catatonia.

It has been well described that patients during catatonia may experience extremely intense “uncontrollable and overwhelming” emotions that lead to total blockade²⁸. Although the existence of fear during the first catatonic episode is questionable, the patient described his extremely intensive terror that was present during the second catatonic episode. Here, it is interesting to note that the patient was ‘totally blocked’ and no signs of intensive emotions were recorded. Moreover, something else was similar in both episodes. Aside from more or less intensive fear, the patient had delusions (his boss’ jealousy, other patients’ attacks, has no future) and affective symptoms.

Finally, it is interesting to note that previous cases show similarities with this case. In all of these cases, the conditions were associated with stressful life events and all these patients most probably also developed affective symptoms⁶⁻⁸, while psychotic symptoms were present in at least two of previous cases⁶⁻⁸. However, chronic catatonia has not been previously described.

Treatment

It has been reported that lorazepam, a benzodiazepine, is promptly therapeutically effective in 60%-80% of all acute catatonic patients²⁸ and that responders reported significantly more anxiety, intense

feelings, and “blockade of movements by emotions” than nonresponders did²⁹. Yet, data on pharmacological treatment of chronic organic catatonia are much less available and are predominantly based on case reports. As examples, there is a description of awaking from years-long catatonia after usage of a single dose of diazepam³⁰ and a report on a mentally retarded patient who had been in a catatonic state for 5 years and who recovered gradually during 5 months of continuous treatment with lorazepam. The authors of the latter report conclude that patients with chronic episode “may respond to a longer course or higher doses of the medication”³¹. While there are descriptions of patients with major mental disorders whose catatonia responded to treatment with olanzapine^{32,33}, or clozapine^{34,35}, the literature revealed only one report of therapeutic effect of clozapine in a patient with recurrent organic catatonic symptoms associated with traumatic brain injury of frontal cortex³⁶.

Olanzapine was the first-used antipsychotic and discontinued shortly after initiation. The reason was development of bilateral leg edema. Although this side effect of olanzapine has been reported previously^{37,38}, it is interesting to note that in our case leg edema developed in the practically immobile patient while lying in bed. After a short initial period, the patient was treated with clozapine and diazepam, and recovered gradually from catatonia over approximately 10 months.

However, the response to this treatment was questionable. Importantly, due to the information from the patient and his mother, the patient most probably had one previous catatonic episode that had resolved spontaneously, without any medication. Accordingly, this could have been a spontaneous recovery too.

On the other hand, although the dose of clozapine was rather low, similar doses have sometimes been shown to be therapeutic in schizophrenic patients with recurrent catatonia³⁴ and for behavioral disturbances in patients with various neurologic conditions, including focal brain lesions³⁹. Moreover, clozapine is an antipsychotic that also possesses anxiolytic and antidepressive properties⁴⁰. Thus, clozapine was able to ameliorate intensive fear and the intensity of depressive and psychotic symptoms. If we assume that catatonia in this case was a kind of response to stress,

then we may suggest that clozapine was also able to ameliorate symptoms that ‘were not visible’, but were fundamental for the development of catatonia.

It is certainly worth noting that the patient was mentioning a change in his relations with environment. He was telling that his interests for contacts with other people were greatly improved in comparison with the period prior to the act. Focal brain lesions are sometimes associated with apathy, and some authors assume that this condition and negative symptoms of schizophrenia might share a similar pathophysiology, involving damage to the frontal-subcortical circuits of the brain⁴¹. Accordingly, aside from the possible therapeutic effect on catatonic, depressive and psychotic symptoms, it is possible that the use of clozapine improved the patients’ social interactions. Therapeutic effects of clozapine on different symptoms in a number of neurologic disorders (including focal lesions) have been described³⁹, but an improvement of motivation for social interactions and increased interests for environment in a patient with focal brain lesion has not yet been described. Our patient, although remaining emotionally distant, clearly emphasized that his interests in social interactions improved in comparison with the period prior to the act and hospitalization. The finding clearly suggests that further research on the possible therapeutic effect of clozapine and other atypical antipsychotics on apathy in patients with focal brain lesions are needed.

Although thyroid dysfunction was not the suspected cause of the stupor, and the importance of the finding is not clear, the decreased levels of T3 are worth noting. Literature data on the plasma thyroid hormone values in patients with major psychiatric disorders are rather inconsistent, but decreased levels of T3 have been reported in patients with different disorders such as major depression⁴² or schizophrenia⁴³. Yet, we were not able to detect a single case of decreased T3 in a patient with catatonic stupor. It has been suggested that chronic elevation of cortisol in patients with psychotic depression may lead to thyroid dysfunction⁴⁴, and animal studies have shown that stress by acute immobilization may decrease T3 levels in rats. As a possible mechanism, reduction in T4 5'-deiodinase activity associated with increased corticosterone levels⁴⁵ is suggested.

References

1. WEBER F, KNOPF H. Incidental findings in magnetic resonance imaging of the brains of healthy young men. *J Neurol Sci* 2006;240:81-4.
2. WESTER K. Intracranial arachnoid cysts – do they impair mental functions? *J Neurol* 2008;255:1113-20.
3. VIDRIH B, KARLOVIĆ D, BOŠNJAK PAŠIĆ M. Arachnoid cyst as the cause of bipolar Affective disorder: case report. *Acta Clin Croat* 2012; 51:655-659
4. RELKIN N, PLUM F, MATTIS S, EIDELBERG D, TRANEL D. Impulsive homicide associated with an arachnoid cyst and unilateral frontotemporal cerebral dysfunction. *Semin Clin Neuropsychiatry* 1996;1:172-83.
5. PARADIS CM, HORN L, LAZAR RM, SCHWARTZ DW. Brain dysfunction and violent behavior in a man with a congenital subarachnoid cyst. *Hosp Community Psychiatry* 1994;45:714-6.
6. WOLAŃCZYK T, KOMENDER J, BRZOZOWSKA A. Catatonic syndrome preceded by symptoms of anorexia nervosa in a 14-year-old boy with arachnoid cyst. *Eur Child Adolesc Psychiatry* 1997;6:166-9.
7. WACHTEL LE, BARANANO K, RETI IM. Electroconvulsive therapy for catatonia in a boy with hydrocephalus and an arachnoid cyst. *Pediatr Neurol* 2010;43:73-5.
8. LIČINA M, VITOROVIĆ S, VELIKONJA I. Frontotemporal arachnoid cyst connected to relapsing stupor. *J Neuropsychiatry Clin Neurosci* 2004;16:120.
9. BELTRAMELLO A, MAZZA C. Spontaneous disappearance of a large middle fossa arachnoid cyst. *Surg Neurol* 1985;24:181-3.
10. SAJKO T, HEĆIMOVIĆ H, BORIĆ M, SESAR N, ROTIM K. Complete resolution of medically refractory temporal lobe epilepsy after arachnoid cyst fenestration. *Acta Clin Croat* 2011;50:589-93.
11. AHARONI E, FUNK C, SINNOTT-ARMSTRONG W, GAZZANIGA M. Can neurological evidence help courts assess criminal responsibility? Lessons from law and neuroscience. *Ann N Y Acad Sci* 2008;1124:145-60.
12. KOHN R, LILLY RB, SOKOL MS, MALLOY PF. Psychiatric presentations of intracranial cysts. *J Neuropsychiatry Clin Neurosci* 1989;1:60-6.
13. WALKER MT, PARTOVI S. Arachnoid cysts. In: AMINOFF MJ, DAROFF RB, editors. *Encyclopedia of the neurological sciences*. Vol. 1. Amsterdam, Boston: Elsevier Science, 2003;253-4.
14. LEWIS DO, MOY E, JACKSON LD, AARONSON R, RESTIFO N, SERRA S, SIMOS A. Biopsychosocial characteristics of children who later murder: a prospective study. *Am J Psychiatry* 1985;142:1161-7.
15. KIM CD, SEGUIN M, THERRIEN N, RIOPEL G, CHAWKY N, LESAGE AD, TURECKI G. Familial aggregation of suicidal behavior: a family study of male suicide completers from the general population. *Am J Psychiatry* 2005;162:1017-9.
16. MILES DR, CAREY G. Genetic and environmental architecture of human aggression. *J Pers Soc Psychol* 1997;72: 207-17.
17. RAO V, SPIRO JR, SCHRETLEN DJ, CASCELLA NG. Apathy syndrome after traumatic brain injury compared with deficits in schizophrenia. *Psychosomatics* 2007;48:217-22.
18. DAVIDSON RJ, PUTNAM KM, LARSON CL. Dysfunction in the neural circuitry of emotion regulation – a possible prelude to violence. *Science* 2000;289:591-4.
19. VICTOROFF J. Human aggression. In: SADOCK BJ, SADOCK VA, RUIZ P, editors. *Kaplan & Sadock's Comprehensive textbook of psychiatry*, 9th edn. Vol. 2. Philadelphia: Lippincott Williams & Wilkins, 2009;2672-703.
20. DOLAN RJ. The human amygdala and orbital prefrontal cortex in behavioural regulation. *Philos Trans R Soc Lond B Biol Sci* 2007;362:787-99.
21. HALLER J, KRUK MR. Normal and abnormal aggression: human disorders and novel laboratory models. *Neurosci Biobehav Rev* 2006;30:292-303.
22. MPAKOPOULOU M, GATOS H, BROTIAS A, PATERAKIS KN, FOUNTAS KN. Stereotactic amygdalotomy in the management of severe aggressive behavioral disorders. *Neurosurg Focus* 2008;25:E6.
23. QUANBECK C. Forensic psychiatric aspects of inpatient violence. *Psychiatr Clin North Am* 2006;29:743-60.
24. LEVY R, DUBOIS B. Apathy and the functional anatomy of the prefrontal cortex-basal ganglia circuits. *Cerebral Cortex* 2006;16:916-28.
25. MOSKOWITZ AK. "Scared stiff": catatonia as an evolutionary-based fear response. *Psychol Rev* 2004;111:984-1002.
26. NORTHOFF G, STEINKE R, NAGEL D, CZERWENKA C, GROSSER O, DANOS P, GENZ A, KRAUSE R, BÖKER H, OTTO HJ, BOGERTS B. Right lower prefronto-parietal cortical dysfunction in akinetic catatonia: a combined study of neuropsychology and regional cerebral blood flow. *Psychol Med* 2000;30:583-96.
27. NETO B. Catatonia with left temporal lesion on MRI: crossing borders. *Eur Psychiatry* 2009;24(Suppl 1):S727.
28. NORTHOFF G. What catatonia can tell us about "top-down modulation": a neuropsychiatric hypothesis. *Behav Brain Sci* 2002;25:555-77.
29. NORTHOFF G, KRILL W, WENKE J, GILLE B, RUSS M, ECKERT J, PESTER U, BOGERTS B, PFLUG B. Major differences in subjective experience of akinetic states in catatonic and parkinsonian patients. *Cogn Neuropsychiatry* 1998;3:161-78.
30. ALISKY JM. Minimally-responsive head injury survivors may have chronic catatonia reversed years after an accident. *Singapore Med J* 2009;50:1117-8.

31. GAIND GS, ROSEBUSH PI, MAZUREK MF. Lorazepam treatment of acute and chronic catatonia in two mentally retarded brothers. *J Clin Psychiatry* 1994;55:20-3.
32. GUZMAN CS, MYUNG VH, WANG YP. Treatment of periodic catatonia with atypical antipsychotic, olanzapine. *Psychiatry Clin Neurosci* 2008;62:482.
33. CEYLAN MF, KUL M, KULTUR SE, KILINCASLAN A. Major depression with catatonic features in a child remitted with olanzapine. *J Child Adolesc Psychopharmacol* 2010;20:225-7.
34. HUNG YY, YANG PS, HUANG TL. Clozapine in schizophrenia patients with recurrent catatonia: report of two cases. *Psychiatry Clin Neurosci* 2006;60:256-8.
35. DURSUN SM, HALLAK JE, HADDAD P, LEAHY A, BYRNE A, STRICKLAND PL, ANDERSON IM, ZUARDI AW, DEAKIN JF. Clozapine monotherapy for catatonic schizophrenia: should clozapine be the treatment of choice, with catatonia rather than psychosis as the main therapeutic index? *J Psychopharmacol* 2005;19:432-3.
36. ROMMEL O, TEGENTHOFF M, WIDDIG W, BRÄUNIG P, MALIN JP. Organic catatonia following frontal lobe injury: response to clozapine. *J Neuropsychiatry Clin Neurosci* 1998;10:237-8.
37. YALUĞ I, OSTEN E, TUFAN AE, ALEMDAR M, CERIT C. Bilateral pedal edema associated with olanzapine use in manic episode of bipolar disorder. *Prog Neuropsychopharmacol Biol Psychiatry* 2007;31:1541-2.
38. NAYAK V, CHOGTU B, DEVARAMANE V, BHANDARY PV. Pedal edema with olanzapine. *Indian J Pharmacol* 2009;41:49-50.
39. DUFFY JD, KANT R. Clinical utility of clozapine in 16 patients with neurological disease. *J Neuropsychiatry Clin Neurosci* 1996;8:92-6.
40. MARX CE, VanDOREN MJ, DUNCAN GE, LIEBERMAN JA, MORROW AL. Olanzapine and clozapine increase the GABAergic neuroactive steroid allopregnanolone in rodents. *Neuropsychopharmacology* 2003;28:1-13.
41. Van REEKUM R, STUSS DT, OSTRANDER L. Apathy: why care? *J Neuropsychiatry Clin Neurosci* 2005;17:7-19.
42. STIPČEVIĆ T, PIVAC N, KOZARIĆ-KOVAČIĆ D, MÜCK-ŠELER D. Thyroid activity in patients with major depression. *Coll Antropol* 2008;32:973-6.
43. OTHMAN SS, ABDUL KADIR K, HASSAN J, HONG GK, SINGH BB, RAMAN N. High prevalence of thyroid function test abnormalities in chronic schizophrenia. *Aust N Z J Psychiatry* 1994;28:620-4.
44. DUVAL F, MOKRANI MC, MONREAL-ORTIZ JA, FATTAH S, CHAMPEVAL C, SCHULZ P, MACHER JP. Cortisol hypersecretion in unipolar major depression with melancholic and psychotic features: dopaminergic, noradrenergic and thyroid correlates. *Psychoneuroendocrinology* 2006;31:876-88.
45. BIANCO AC, NUNES MT, HELL NS, MACIEL RM. The role of glucocorticoids in the stress-induced reduction of extrathyroidal 3,5,3'-triiodothyronine generation in rats. *Endocrinology* 1987;120:1033-8.

Sažetak

UBOJSTVO I NAKNADNA KATATONIJA UDRUŽENA S VELIKOM ARAHNOIDNOM CISTOM: PRIKAZ SLUČAJA

B. Margetić, T. Žarković Palijan i D. Kovačević

Razvoj različitih psihijatrijskih sindroma ili promjena značajka osobnosti može biti povezana sa žarišnim ozljedama mozga, ali je ujedno i proturječno pitanje. Bolesnik, inače osoba bez osobitosti u ranijoj medicinskoj dokumentaciji i bez ranijih iskazivanja fizičke agresije, imao je 29 godina kada je ubio oca jednim udarcem sjekire. Nakon djela razvio je dugotrajni, desetomjesečni katatoni stupor tijekom kojeg je doživljavao intenzivni strah, sumanutosti i afektivne simptome. Pretraga glave magnetskom rezonancom otkrila je veliku desnostranu arahnoidnu cistu povezanu s hipoplazijom desnog temporalnog i frontalnog režnja te bilateralnim promjenama u perfuziji periinzularnih regija. Liječenje klozapinom i diazepamom pokazalo se učinkovitim. Ovo je vjerojatno drugi prikaz bolesnika s arahnoidnom cistom koji je razvio ubojstvo, a da prethodno nije pokazivao agresivno ponašanje te drugi prikaz bolesnika s cistom koji je razvio katatoni stupor. Radi se također o prvom opisu uspješnog liječenja dugotrajnog katatonog stupora kombinacijom klozapina i diazepam. Slučaj je poslužio za prikaz relevantne literature i raspravu o proturječnim pitanjima.

Ključne riječi: *Arahnoidne ciste; Ubojstvo; Katatonija; Stupor; Klozapin; Prikaz slučaja*