

VETERINARSKI ARHIV 84 (3), 319-329, 2014

Syndactyly and concurrent multiple pad agenesis in all four limbs with secondary deep digital flexor contracture in a puppy - a case report

Carlos A. Rodríguez-Alarcón, Diana M. Beristain-Ruiz*, Mateo F. Itzá, and Ramón Rivera-Barreno

Veterinary Science Department, Autonomous University of Juárez, Anillo Envolverte y Estocolmo S/N, ZonaPRONAF, Ciudad Juárez, Chihuahua, México

RODRÍGUEZ-ALARCÓN, C. A., D. M. BERISTAIN-RUIZ, M. F. ITZÁ, R. RIVERA-BARRENO: Syndactyly and concurrent multiple pad agenesis in all four limbs with secondary deep digital flexor contracture in a puppy. Vet. arhiv 84, 319-329, 2014.

ABSTRACT

A 2-month-old, 7 kg, male Belgian shepherd Malinois was presented for evaluation of simple and complete syndactyly and metacarpal/tarsal pad agenesis in all four limbs, as well as deep digital flexor tendon contracture in the left thoracic and right pelvic limbs. A deep digital flexor tenotomy (digits 2 to 5) was initially performed at the level of the proximal and middle phalanges in the left thoracic limb. Pelvic limb surgery was not performed because the puppy showed less severe signology in this limb and to evaluate the consequences of the thoracic limb surgery. The patient responded partially, and was then treated with a subsequent bilateral tenotomy made more proximal to the previously described, at the level of the lateral lumbrical muscles in the left thoracic and right pelvic limbs. At 7-month post-operative examination, the patient had minimal lameness, especially regarding concurrent syndactyly and pad agenesis of all extremities that was not treated.

Key words: syndactyly, tenotomy, deep digital flexor, tendon contracture, pads agenesis.

Introduction

Syndactyly refers to the partial or complete fusion of two or more contiguous digits. This condition involves the bony and/or soft tissue union of digits, with varying degrees of involvement. Syndactyly is classified as “simple” if the union between contiguous digits consists only of skin and fibrous tissue. On the other hand, if it also includes unification of bones, this condition is called “complex”. In addition, when adjacent

*Corresponding author:

Diana M. Beristain-Ruiz, DVM, Ph.D, titular professor, Veterinary Science Department, Autonomous University of Juárez, Anillo Envolverte y Estocolmo S/N, ZonaPRONAF, CP 32310, Ciudad Juárez, Chihuahua, México, Phone: +52 656 6881 800 ext. 1766; E-mail: diana.beristain@uacj.mx

ISSN 0372-5480
Printed in Croatia

digits (phalanges 1-3) are attached throughout their entire length with soft tissue and/or osseous abnormality syndactyly is called “complete”, and is called “incomplete” when they are only partially connected. Complex syndactyly is additionally classified in another two types: 1) complicated syndactyly, that is associated with other anomalies, and 2) uncomplicated syndactyly, which is not associated with concomitant pathologies (TOWLE et al., 2007b).

This condition has been identified by veterinarians, zoologists, physicians, and naturalists in individuals and populations in a range of species (MADGWICK et al., 2011). Excluding humans and cattle research, this anomaly remain relatively poorly understood in other mammals (LEMUS et al., 2003; TOWLE et al., 2007a; CHEW et al., 2012). Syndactyly is uncommon in dogs, and little is known about its presentation, and the breeds, gender, or genetic predispositions. However, in a report of canine syndactyly, genetic etiology was demonstrated in one case of Australian Shepherd Dogs. These dogs also had multiple defects, including: cleft palate, polydactyly, shortened tibia-fibula, brachygnathism, and lethal scoliosis (SPONENBERG and BOWLING, 1985; FREEMAN et al., 1988).

The aim of this article is to present a case report of a rare combination of congenital pathologies found in a dog. The article also includes a description of the surgical management of the deep digital tendon contractures found in the dog's left thoracic and right pelvic limbs.

Case presentation

A two-month-old, 7 kg, male Belgian Malinois was referred for evaluation of progressive lameness of the left thoracic limb and right pelvic limb. The animal was the only puppy in the last litter, and puppies from the other litters from the same parents (maternal and paternal) had not had other congenital abnormalities detected on routine physical examination.

The lameness was initially noticed in the left forelimb and right hind limb when the puppy began to walk. He also had mild intermittent, self-limiting discomfort in this limb. By one month of age the puppy was grade III-IV/V lame and by the evening it was grade V (non-weight bearing) in the left forelimb and right hind limb. Physical and neurological examination was unremarkable, with the exception of the orthopaedic abnormalities. Digits 2-5 of all four limbs did not have any interdigital space and there was webbing in the entire spacing. There was complete agenesis of the metacarpal and metatarsal pads of all four limbs. The remaining digital, tarsal, and carpal pads were all normal (Fig. 1). The left forelimb and right hind limb had severe and moderate hyperflexion of the digits 2-5 (Fig. 2B) with nail shortening, respectively (Fig. 1B, 2B, and 2C). Secondary to these deformities, the patient walked on the dorsal aspect of the extremity. These abnormalities could not be manually corrected.

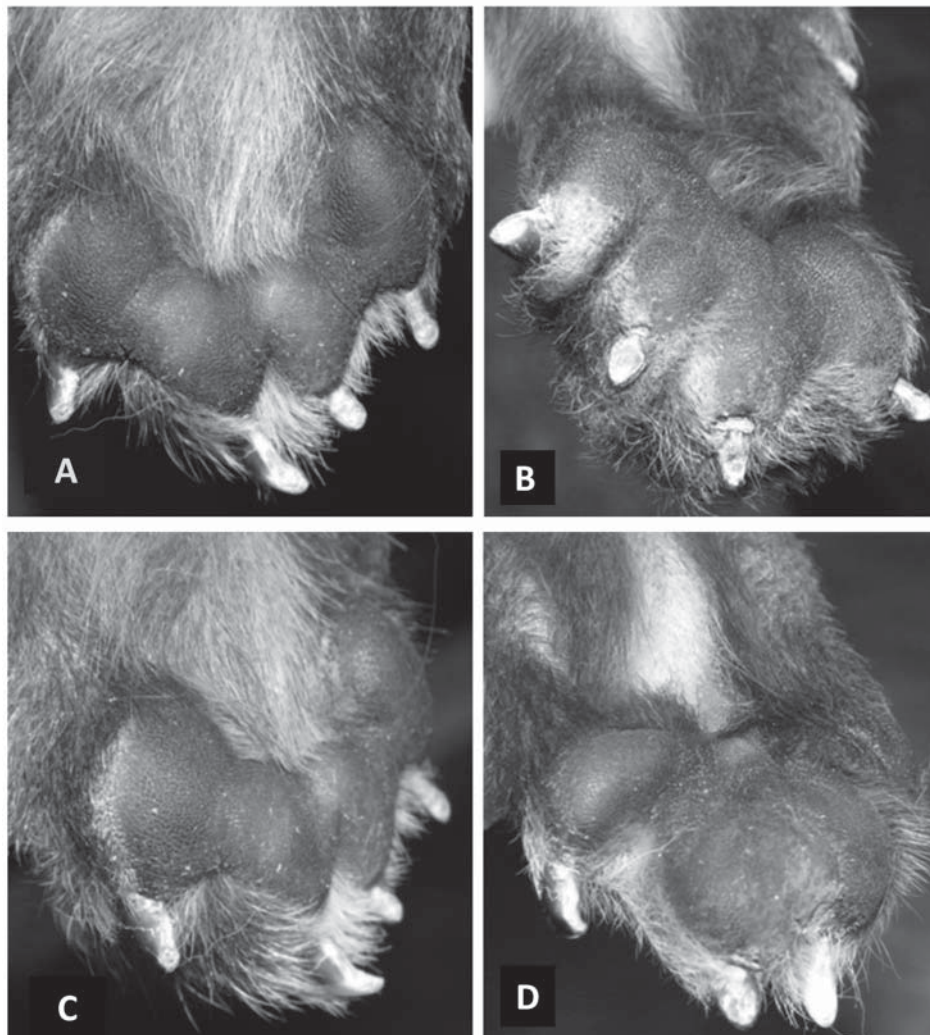


Fig. 1. Photograph of a palmar and plantar view of all paws at presentation. A) Right thoracic, B) Left thoracic, C) Right pelvic and D) Left pelvic. Note complete fusion in all digital pads. Abnormal positioning and wear pattern are most affected in the left thoracic limb (B).

Two orthogonal radiographs were taken of the left forelimb and right hind limb including the mid-antebrachium to phalange 3 and from the mild tibia/fibula to phalange 3 to further characterize the syndactyly deformity and to rule out other congenital orthopaedic anomalies. Radiographs confirmed digit 2-5 hyperflexion and showed no bony abnormalities (Fig. 3). Based upon physical examination and radiographic findings, simple complete syndactyly in all limbs with secondary digit 2-5 deep digital flexor contracture in the left forelimb and right hind limb was diagnosed.

In this case, the results from pre-surgical blood and urine analysis were unremarkable.

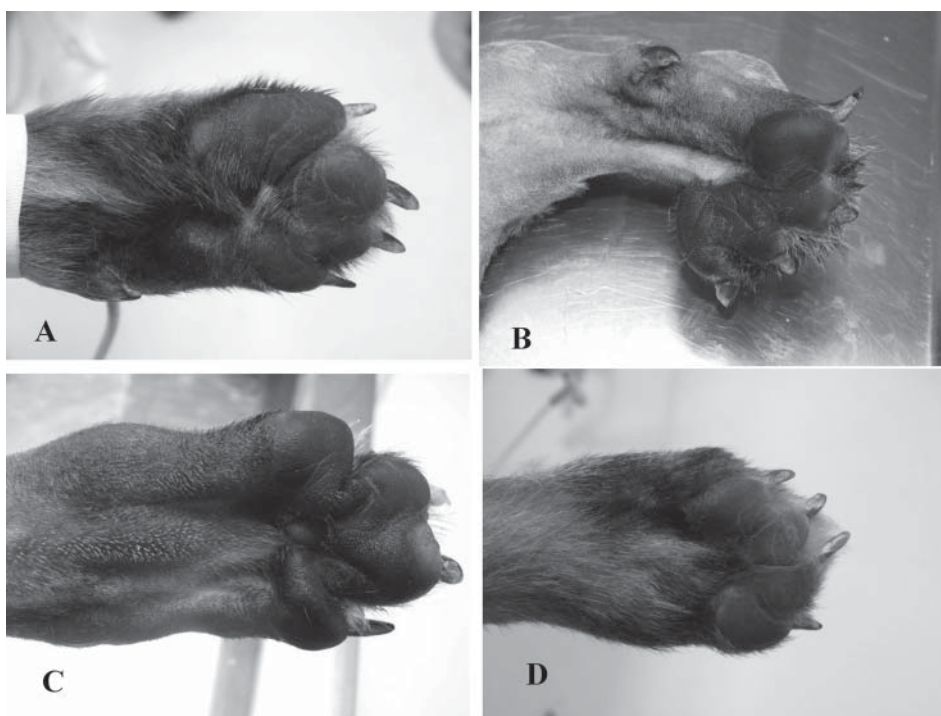


Fig. 2. Photograph of a palmar and plantar view of all paws immediately before the first surgery. A) Right thoracic, B) Left thoracic, C) Right pelvic and D) Left pelvic. Note complete fusion of all digital pads, abnormal positioning and wear pattern of the nails of digits of the left thoracic paw (B) and right pelvic paw (C). Additionally, note metacarpal and metatarsal pad agenesis of all extremities.

Meloxicam (Mobicox®), at 0.2 mg/kg per oral (PO) initially, was administered followed by 0.1 mg/kg PO q 24 h. To alleviate the severe lameness, surgery on all digits of the left thoracic limb was performed. The patient was premedicated with acepromazine (Promace®, Pfizer; 0.01 mg/kg IM) and tramadol (Tradol®, Grünenthal; 1 mg/kg IM). Subsequent to induction with propofol (Diprivan®, AztraZeneca; 6 mg/kg IV), the animal was intubated and anaesthesia was maintained on 1.5-2% isoflurane (Forane®, Abbott) and oxygen. A palmar approach between the proximal and middle phalanges was made. The deep digital flexor tendon of digits 2-5 was identified and transected. Fibrosis was found associated with each phalanx, which was resected with a Metzenbaum scissor.

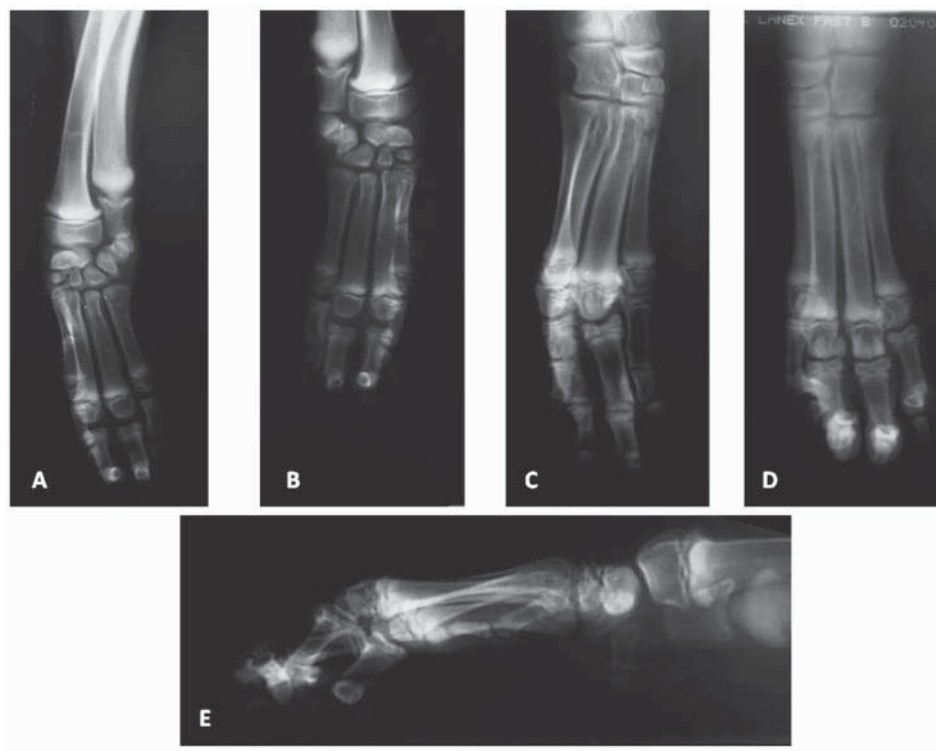

Fig. 3. Radiographic view of all limbs of the affected puppy. A) Palmodorsal view of the right thoracic limb and B) left thoracic limb. C) Plantodorsal view of the right pelvic limb, and D) left pelvic limb. Note that none of the four limbs presents fused digits E) Mediolateral view of the affected puppy in a weight bearing position at presentation. Hyperflexion proximal and distal interphalangeal joints of all digits.

Recovery from anesthesia occurred without incident. Tramadol (1 mg/kg IM once) was administered for post-surgical pain management, and a modified Robert-Jones bandage was placed to prevent post-operative swelling. Meloxicam (0.1 mg/kg PO q 24 h) was continued for seven days.

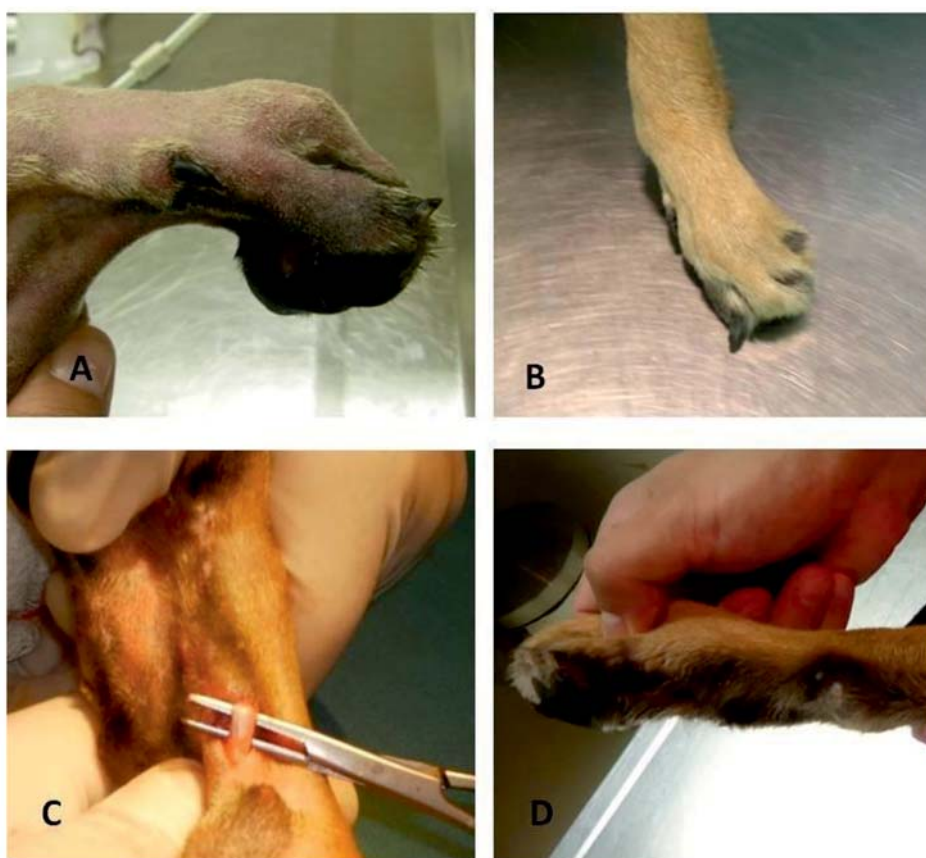

Fig. 4. Photograph of left thoracic paw at presentation. A) mediolateral view before the first surgery. Note the hyperflexion of digits instead of paw and the excessive tension of the tendon. B) craniocaudal view after first surgery. Note the lateral deviation of the fifth digit. C) View of the second tenotomy, the procedure was performed right at the insertion of the tendon over the metacarpus. D) Lateromedial view after the second surgery, note the normal position of the paw, without hyperflexion or hyperextension.

The patient did not show deep digital flexor contracture and was able to bear weight on both thoracic limbs on the day after surgery. The animal was discharged 2 days after surgery with a modified Robert-Jones bandage for 4 days and instructions for rest from exercise. The dog's owner returned 7 days post-surgery. The bandage and sutures were removed, and the incisions healed without any complications. Lameness of the thoracic limb had improved from grade 5 to 3 during the first two months post-surgery, physical examination revealed a lateral deviation from the third to the fifth digit (Fig. 4B). Manipulation of the phalanges of the second digit demonstrated hyperflexion of the proximal interphalangeal joints.

A second tenotomy was recommended in this surgery, and the procedure was performed more proximally, just distally to the flexor manica (Fig. 4C). During the same anaesthesia, we performed a deep digital flexor tenotomy in the right pelvic limb at the level where the flexor tendon passes over the metatarsus. Immediately after tendon surgery, both limbs had normal grade flexion and extension of digits.

Six months after the second surgery, the animal returned for re-evaluation. The lameness of both limbs had improved significantly, showing only grade 1 lameness in both limbs. Orthopaedic examination showed no hyperflexion or hyperextension of either set of limbs (Fig. 4D).

Discussion

In this paper, we have presented one case of simple complete syndactyly in the four limbs of a Belgian Malinois puppy. We have found only two reports of dogs with syndactyly in four limbs (BAUM, 1889; RENOY and BALLIGAND, 1991). Also, to the author's knowledge, this is the first report of agenesis of the metacarpal and metatarsal pads affecting both the thoracic and pelvic limbs.

In children, surgery to repair syndactyly is usually performed between 12 and 18 months of age. This time is important because it is necessary to avoid scar contracture by operating too early and deviation of the joints by operating too late. However, if syndactyly is complex or the fingers are significantly irregular in size, correction is done at 6 months of age or even earlier. Follow-up surgeries for syndactyly are generally not imperative. However, if severe contractures develop, a second graft or release will be necessary. The necessity of a second surgery is in the range of 10% (CHOPRA et al., 2013).

In dogs, this syndrome is probably more common than would be assumed from the reported cases, since this malformation is not always associated with clinical signs in dogs (JEZYK, 1985). However, surgery is indicated in patients with severe lameness, as described in a Golden Retriever with simple syndactyly. This dog had intermittent non-weight-bearing lameness, involving the affected forepaw after vigorous exercise. The

lameness possibly resulted from stretching of the thin skin on the dorsum of the paw as the digits attempted to extend during weight bearing. In this animal, surgical separation of digits 3 and 4 was performed (RICHARDSON et al., 1994). In the patient in the present report, the deep flexor tendon contracture caused the lameness.

The first report of a deep digital flexor tendon contracture associated with syndactyly was described in the pelvic limb of a five-month-old, female Basset hound (TOWLE et al., 2007b). However, this pathology has never been described in the thoracic limbs, as found in this Belgian Malinois puppy.

In dogs, the deep digital flexor muscle of the thoracic limb has three heads of origin of dissimilar size, which arise from the humerus, radius, and ulna. The function of the deep digital flexor muscle of the thoracic limb is flexion of the carpal and metacarpophalangeal joints and the proximal and distal inter-phalangeal joints of the digits. In the pelvic limb, the deep digital flexor muscle consists of a lateral head and a medial head that fuse simultaneously to form a common deep digital flexor tendon, which branches off to the plantar surface of the base of each third phalange. The function of this tendon in the pelvic limb is to flex the digits and extend the tarsus (EVANS and DE LAHUNTA, 2010). To flex the digits and extend the tarsus)

The first surgery performed in the Belgian Malinois puppy was performed as described by TOWLE et al. (2007b), but we transected the deep digital flexor tendon of all of the toes

of the affected thoracic limb. They hypothesized that simple incomplete syndactyly causes the diminished growth of the distal segment of the flexor tendons of the third and fourth digits, with normal-length development of the metatarsals and the phalanges. Eventually, this could result in peri-tendinous and peri-articular fibrosis and additional accentuation of the malformation and contracture. However our patient had shown contracture since birth, therefore we think that this is a congenital condition. They also believed that the origin of the contracture should have been distal to the branching of the common tendon into tendons going to the digits, because only two toes were affected. In our case, all digits were affected in both sets of limbs involved, and the contracture occurred more proximally. Similarly, during surgery, we also found periarticular fibrosis. In Towle's surgery, surgeons also performed amputation of the third and portion of the second phalanx. The tenotomy of the digital flexor tendon in our puppy resulted in the apparent significant resolution of the hyperextension of the digits. Considering this, we did not perform the amputation of the digits.

Although our patient exhibited a slight improvement in lameness two weeks after the first surgery, during the physical examination the puppy showed a lateral deviation of the digits (3-5) of the forelimb that had undergone surgery. In addition, the deep digital flexor tendon was still very rigid during palpation. During a thorough examination, we found

that contracture occurred proximal to the branching of the common flexor tendon. Also, we observed that the tendon was not centrally located on the palmar surface of the bone, as normally occurs. It deviated laterally, passing onto the accessory carpal bone.

Taking this into consideration, we performed a second tenotomy at the site where the tendon passed over the accessory carpal bone at the level of the lateral lumbrical muscles (BUDRAS et al., 2007; EVANS and DE LAHUNTA, 2010).

The second surgery in this report represented successful treatment of the lameness caused by contracture of the deep digital flexor tendons in left thoracic and the right pelvic limbs in a dog with simple complete syndactylism in all fourth limbs.

Three months after the second surgery, the patient exhibited grade 1 lameness of the left thoracic and right pelvic limbs. Also there was resolution of the hyperflexion of the digits that were previously affected.

During literature review, the authors did not find any report of paw pad agenesis in dogs. However, there are few reports mentioning that retinoic acid induced aplasia of the fibular tarsal pad and supernumerary interdigital pads on hindlimbs in mice (MORI et al., 2000). Footpads are characterized by thickened dermis and only some terrestrial mammals have this. During those animals' development, bone morphogenetic protein (BMP) is expressed in the mesenchyme where the footpads will form (WU et al., 2004). Research has shown that suppression of BMP mediated interactions in K14 noggin mice reduced footpads (PLIKUS et al., 2004); additionally there is a report demonstrating that retinoic acid might also be able to antagonize Fgf8 survival activity and, in this way, promote cell death. BMP is a subfamily of the Tgf β grow factor (HERNANDEZ-MARTINEZ et al., 2009). The bitch or puppy presented in this report, never received retinoic acid.

Otherwise, one report described a kitten showing some anatomical forelimb malformation. The cat had aphalangia, a shortened limb that ended, at the level of the carpus, and on the palmar surface only presented two footpads (MACRI et al., 2012).

Conclusion

According to the research found in the literature, this is the third reported case of a dog with syndactyly in its four limbs. We have presented a case in which, for the first time, describes deep digital flexor tendon contracture in two limbs in the same dog. This animal was treated successfully with a tenotomy performed proximal to the location as previously described by TOWLE et al. (2007b) and without the need for amputation of the distal phalanges involved. Finally, the dog walked nearly normally after the surgery, especially considering that the animal had metacarpal and metatarsal pad agenesis of all extremities. This is the first description of agenesis of the metacarpal and metatarsal pads of all extremities in a dog.

References

- BAUM, H. (1889): A case of syndactyly in the dog. (in German) *Deutsche Zeitschr. Tiermed.* 15, 81-90.
- BUDRAS, K. D., P. H. MCCARTHY, W. WOLFGANG, F. RICHTER, A. HOROWITZ, R. BERG (2007): *Anatomy of the Dog*. 5th ed., Schluetersche, London.
- CHEW, K. Y., H. YU, A. J. PASK, G. SHAW, M. B. RENFREE (2012) : HOXA13 and HOXD13 expression during development of the syndactylous digits in the marsupial *Macropus eugenii*. *BMC Dev. Biol.* 12, 2.
- CHOPRA, K., K. K. TADISINA, K. R. PATEL, D. P SINGH. (2013). Syndactyly Repair. *Eplasty* 13, ic51.
- EVANS, H.E., A. DE LAHUNTA (2010): *Guide to the dissection of the dog*. 7th ed., Saunders Elsevier, Edinburgh, London, New York, Oxford, Philadelphia, St. Louis, Sydney, Toronto.
- FREEMAN, L. E., D. P. SPONENBERG, D. G. SCHABDACH (1988): Morphologic characterization of a heritable syndrome of cleft lip/palate, polydactyly, and tibial/ fibular dysgenesis in Australian shepherd dogs. *Anat. Histol. Embryol.* 17, 81.
- HERNANDEZ-MARTINEZ, R., S. CASTRO-OBREGON, L. COVARRUBIAS (2009): Progressive interdigital cell death: regulation by the antagonistic interaction between fibroblast growth factor 8 and retinoic acid. *Development* 136, 3669-3678.
- JEZYK, P. F. (1985): Constitutional Disorders of the Skeleton in Dogs and Cats. In: *Textbook of Small Animal Orthopaedics*. (Newton, C. D., D. M. Nunamaker, Eds.), Lippincott, Philadelphia, pp. 637-654.
- LEMUS, F. C., M. R. ALONSO, M. ALONSO-SPILSBURY (2003): Morphologic characteristics in mexican native pigs. *Arch. Zootec.* 52, 105-108.
- MACRÌ, F., G. LANTERI, G. RAPISARDA, G. MARINO F. (2012): Unilateral forelimb partial aphyalangia in a kitten. *J. Feline Med. Surg.* 14, 272-275.
- MADGWICK, R., V. FOREST, F. BEGLANE (2011): Syndactyly in pigs: a review of previous research and the presentation of eight archaeological specimens. *Int. J. Osteoarchaeol.* 23, 395-409.
- MORI, N., M. H. TSUGANE, K. YAMASHITA, Y. IKUTA, M. YASUDA (2000): Pathogenesis of retinoic acid-induced abnormal pad patterns on mouse volar skin. *Teratology* 62, 181-188.
- PLIKUS, M. V., W. P. WANG, J. LIU, X. WANG, T. X. JIANG, C. M. CHOUNG (2004): Morphoregulation of ectodermal organs: integument pathology and phenotypic variations in K14-Noggin engineered mice through modulation of bone morphogenic protein pathway. *Am. J. Pathol.* 164, 1099-1114.
- RENOY, B. P., M. BALLIGAND (1991) : A case syndactyly in dogs. (in French) *Ann. Vet. Med.* 135, 43-44.
- RICHARDSON, E. F., P. D. WEY, L. A. HOFFMAN (1994): Surgical management of syndactyly in a dog. *J. Am. Vet. Med. Assoc.* 205, 1149-1151.

C. A. Rodríguez-Alarcón et al.: Syndactyly and concurrent multiple pads agenesis with secondary deep digital flexor contracture

SPONENBERG, D. P., A. T. BOWLING (1985): Heritable syndrome of skeletal defects in a family of Australian shepherd dogs. *J. Hered.* 76, 393-394.

TOWLE, H., W. E. BLEVINS, L. R. TUER, G. BREUR (2007a): Syndactyly in a litter of cats. *J. Small Anim. Pract.* 48, 292-296.

TOWLE, H., K. FRIEDLANDER, R. KO, R. APER, G. BREUR (2007b): Surgical treatment of simple syndactylism with secondary deep digital flexor tendon contracture in a Basset Hound. *Vet. Comp. Orthop. Traumatol.* 3, 219-223.

WU, P., L. HOU, M. PLIKUS, M. HUGES, J. SCHEHNET, S. SUKSAWEANG, R. B. WIDELITZ, T. X. JIAN, C. M. CHUONG (2004): Evo-Devo of amniote integuments and appendages. *Int. J. Dev. Biol.* 48, 249-270.

Received: 14 March 2013

Accepted: 19 December 2013

RODRÍGUEZ-ALARCÓN, C. A., D. M. BERISTAIN-RUIZ, M. F. ITZÁ, R. RIVERA-BARRENO: Sraštenost prstiju uz istodobnu višestruku nerazvijenost mekušića na sve četiri noge sa sekundarnom kontrakturom duboke fleksorne tetive u šteneta. *Vet. arhiv* 84, 319-329, 2014.

SAŽETAK

U radu je iznesen opis i procjena stanja u dvomjesečnog, 7 kg teškog šteneta, belgijskog Malinois ovcara, s jednostavnom i potpunom sraštenošću prstiju, nerazvijenim metakarpalnim/metatarzalnim mekušića na sve 4 noge te s kontrakturama duboke digitalne fleksorne tetive na lijevoj prednjoj i desnoj stražnjoj nozi. U slučaju prve lijeve noge obavljeno je presjecanje duboke digitalne fleksorne tetive (2. do 5. prsta) na razini gornje i srednje falange. Operacija stražnje noge nije obavljena jer je štene na tom ekstremitetu pokazivalo manje izražene simptome, a željelo se prvo i procijeniti učinke zahvata na prednjoj nozi. Stanje pacijenta djelomično se poboljšalo, stoga je naknadno provedeno bilateralno presjecanje tetiva na mjestu iznad prethodne operacije, na razini lateralnih lumbrikalnih mišića prednje lijeve i stražnje desne noge. Postoperativnom kontrolom nakon 7 mjeseci, kod pacijenta je utvrđena minimalna šepavost, posebice vezana za neliječenu popratnu sraštenost prstiju i nerazvijenost mekušića na svim ekstremitetima.

Ključne riječi: sraštenost prstiju, presjecanje tetive, duboka digitalna fleksorna tetiva, kontraktura tetive, nerazvijenost mekušića
