


Contents lists available at [ScienceDirect](http://www.sciencedirect.com)

eNeurologicalSci

journal homepage: <http://ees.elsevier.com/ensci/>

Benefit of ELISpot in early diagnosis of tuberculous meningoencephalitis: Case report and literature review



Josefine Blume ^a, Josef Köstler ^b, Robert Weissert ^{a,*}

^a Department of Neurology, University of Regensburg, Universitaetsstrasse 84, 93053 Regensburg, Germany

^b Institute of Microbiology and Hygiene, University of Regensburg, Franz-Josef-Strauss-Allee 11, 93053 Regensburg, Germany

ARTICLE INFO

Article history:

Received 29 June 2015

Received in revised form 12 October 2015

Accepted 15 October 2015

Available online 09 November 2015

Keywords:

Tuberculosis
Central nervous system
Meningoencephalitis
Diagnostics
ELISpot
Cerebro spinal fluid

ABSTRACT

Tuberculous meningitis and meningoencephalitis are rare and dangerous complications of infections with mycobacteria-complex. Usually these are complications of systemic florid infection with *Mycobacterium (M.) tuberculosis*. They are most often seen in immune compromised patients. The confirmation of diagnosis can be elaborate and delayed due to long-term culture requirements for *M. tuberculosis*. We present a female patient, without history of immunosuppression, who was diagnosed with tuberculous meningoencephalitis using ELISpot to detect immune reactivity against mycobacterial antigens with lymphocytes from cerebrospinal fluid (CSF). ELISpot with CSF derived lymphocytes seems to be an appropriate method to diagnose tuberculous meningitis and meningoencephalitis and to make therapeutic decisions easier and earlier in atypical cases of infection with *M. tuberculosis*.

© 2015 The Authors. Published by Elsevier B.V. This is an open access article under the CC BY-NC-ND license (<http://creativecommons.org/licenses/by-nc-nd/4.0/>).

1. Introduction

Tuberculous meningitis and meningoencephalitis are rare and dangerous complications of infections with mycobacteria-complex and confirmation of these diagnoses can be elaborated and often protracted [1]. Evidence-based therapy with a long-term combination of four tuberculostatic agents is accompanied by the risk of side effects affecting multiple organ systems. Therefore, the initiation and continuation of therapy should be substantiated by as many clinical and laboratory findings as possible.

2. Materials and methods

2.1. ELISpot assays for peripheral blood and CSF

Venous blood was collected in lithium-heparin tubes and processed regarding the instructions of the commercial T-SPOT.TB test (Oxford Immunotec). Peripheral blood mononuclear cells (PBMCs) from the cerebro spinal fluid (CSF) were prepared according to Kösters et al. 2008 [2]. In short, native CSF was centrifuged at 465 g at room temperature for 15 min. After cell resuspension in AIM-V medium (life technologies) the centrifugation step was repeated. Finally, cells were resuspended and counted in an automated cell counter (Vicell, BD) regarding cell count and viability. Further ELISpot analyses were done

following the instruction manual of the T-SPOT.TB test. In brief 250,000 PBMCs from human blood or 54,000 PBMCs from CSF were stimulated with *Mycobacterium (M.) tuberculosis* specific antigens, ESAT-6 and CFP-10, or PHA as positive control and medium as negative control. Antigen specific T cells released interferon- γ (IFN- γ) after contact with the antigen presenting cell. The released IFN- γ binds to the precoated anti-IFN- γ antibody on the plate, and after incubation with a second anti-IFN- γ antibody with a color reaction, the spots were visible on the plate.

The test is validated for blood with a sensitivity of 95.6% and a specificity of 97.1%. Up to now, tests for other body fluids, like CSF, are not validated. Rather, they are done similar to tests with blood. In our case we had only 54,000 PBMCs from CSF compared to 250,000 PBMCs for ELISpot. This means that we used around 5 times less PBMCs albeit we used the test interpretation for 250,000 PBMCs.

The test could be validated (blood) or interpreted (CSF) if the negative control showed less than ten spots and the positive control showed more than 20 spots or spots too numerous to count (TNTC). The test result was positive in the case of more than 5 spots in the ESAT-6 or/and CFP-10 stimulation and negative with 5 or less spots in the ESAT-6 and CFP-10 stimulation.

2.2. Literature search

Literature was searched via the database PubMed of the US National Library of Medicine National Institutes of Health using the search terms 'ELISpot', 'enzyme-linked immunospot', 'tuberculosis', 'tuberculous',

* Corresponding author.

E-mail address: robert.weissert@ukr.de (R. Weissert).

'meningitis', 'meningoencephalitis', 'encephalitis', 'cerebrospinal fluid' and 'extrapulmonary' in various combinations by using the Boolean operator AND.

3. Case report

A 58 year old female patient, until that point healthy, presented to our Department of Neurology via TEMPiS, a tele medical network for the region of South-East-Bavaria. She had suffered from a slight headache for ten days before she was found confused and aphasic by her husband. In the referring hospital she recovered quickly, and the initial diagnosis was complex-focal epileptic seizure. In a cerebral computer tomography (CT), a hypodense area in the left temporal lobe was seen. After cerebral magnetic resonance imaging (MRI), a low-grade glioma or lymphoma was suspected (Fig. 1A). The lumbar puncture revealed pleocytosis of 312/ μ l leukocytes with a mixed cytology consisting of 20% granulocytes, 30% lymphocytes, 40% monocytes and 10% macrophages. Lactate in CSF was increased to 4.0 mmol/l (range 1.2 to 2.1) and the protein content was heightened to 1242 mg/l (range 150 to 450). Subsequently, the patient was transferred to our hospital with a headache, meningism and an elevated body temperature of 38 °C. The patient did not have neurological deficits. She was treated with antibiotics and aciclovir for a suspected meningoencephalitis. Because of the unclear etiology of the lesion, lumbar puncture was performed three times excluding the presence of atypical, malignant cells. The polymerase chain reactions (PCR) and antibody indices for *Streptococcus pneumoniae*, *Haemophilus influenzae*, *Neisseria meningitidis*, *Streptococcus agalactiae*, *Leptospira*, *Brucella*, Tick-borne encephalitis virus, Enterovirus, Varicella virus, Herpes virus type I and type II, *Aspergillus spp.*, *Cryptococcus spp.* and *Bacteroides spp.* did not result in positive findings. CSF consistently showed high lactate

(3,2 mmol/l) and increasing mixed lympho-granulocytic pleocytosis (314/ μ l) which led us to the suspicion of tuberculosis. The patient reported that she was treated in hospital due to a pyelonephritis four months ago. Furthermore, her father had suffered from lung tuberculosis. A routine X-ray of her lung post-specific lymph nodes had been found from when she was aged 20 years. Based on that history and the negative findings in screening for differential diagnoses, we started anti-tuberculous treatment with isoniazide, rifampicin, pyrazinamide and levofloxacin. ELISpot from blood was positive for tuberculosis, but was not interpretable due to tuberculosis of the lung in the past. PCR for detection of *M. tuberculosis* was done and direct microscopy was performed from sputum, urine, serum and CSF, both with negative results (each three to six times). After 12 days of therapy, the cell counts in CSF increased again. In another cerebral MRI, new small contrast medium enhancing lesions located left temporomesial, right frontolateral, and temporobasal were found. Most likely, these were tuberculomas. At this point the diagnosis was still uncertain due to inconclusive findings and the untypical clinical manifestation. Therefore we decided to perform an ELISpot from CSF. Fortunately we had a clear positive result despite the relatively small amount of leukocytes in CSF. We used the standard ELISpot available for detection of reactivity of T lymphocytes against *M. tuberculosis* specific antigens, ESAT-6 and CFP-10 (Fig. 1C). Results were 58/250,000 spots per cells for tuberculous protein CFP10 and 6/250,000 spots per cells for tuberculous protein ESAT-6 with a positive control of 23/250,000 in CSF in relation to 8/250,000 for ESAT-6 and 21/250,000 for CFP-10 with a positive control of TNTC in blood. We stated this finding as an indirect proof that lymphocytes in CNS had contact to antigens of mycobacteria-complex and continued the specific therapy against *M. tuberculosis*. On day 40 of treatment, the first direct cultural detection of *M. tuberculosis*, and thus the diagnosis, were consolidated. During the course of events there had not been any sign of basal meningitis, either clinically or by MRI. The patient recovered within three weeks of initiation of treatment and was released without symptoms from our hospital (Fig. 1B). After six and nine months, CSF still showed a slight pleocytosis (13/ μ l) but normalized lactate and protein content under continuous therapy for 12 months. There have not been any complications of therapy for the time of treatment.

4. Discussion

As demonstrated by our case and the below summarized literature, there is evidence for the effectiveness of ELISpot, for the detection of immune reactivity against mycobacterial antigens with lymphocytes from CSF in reducing the diagnostic delay caused by long incubation of cultures for diagnosis of CNS infection by *M. tuberculosis*. It supports decision making for therapy initiation and continuation in immune competent, as well as immune deficient patients, and could thereby even lead to a better outcome, especially preventing the threatening deterioration often seen in tuberculous meningitis or meningoencephalitis.

In all reviewed studies, the diagnosis of confirmed CNS tuberculosis (TBC) was based on the result of cultures for *M. tuberculosis*. In contrast, diagnoses of highly probable, probable, or possible CNS TBC were diagnosed using a risk estimation consisting of age, length of history, white-blood-cell count, CSF white blood cell count, and glucose as well as CSF neutrophil proportion as first described in 2002 by Thwaites et al. [3]. In 2005, this approach was evaluated in HIV negative patients with bacterial and tuberculous meningitis revealing a sensitivity of 91.7% and specificity of 79.7% in diagnosis in microbiologically proven cases, respectively [4]. The decision for an empirical treatment was not influenced by ELISpot results in the reported studies, but made by clinical features as well as imaging by CT or MRI and CSF findings. The results of ELISpot were sometimes concealed by the attending physician to avoid a bias. Nowadays, ELISpot with PBMC is an established diagnostic adjunct in extrapulmonary tuberculosis. This is especially the case for CNS TBC in immunocompetent patients [5]. As tuberculosis-specific T cells tend to compartmentalize to the side of infection, a more sensitive

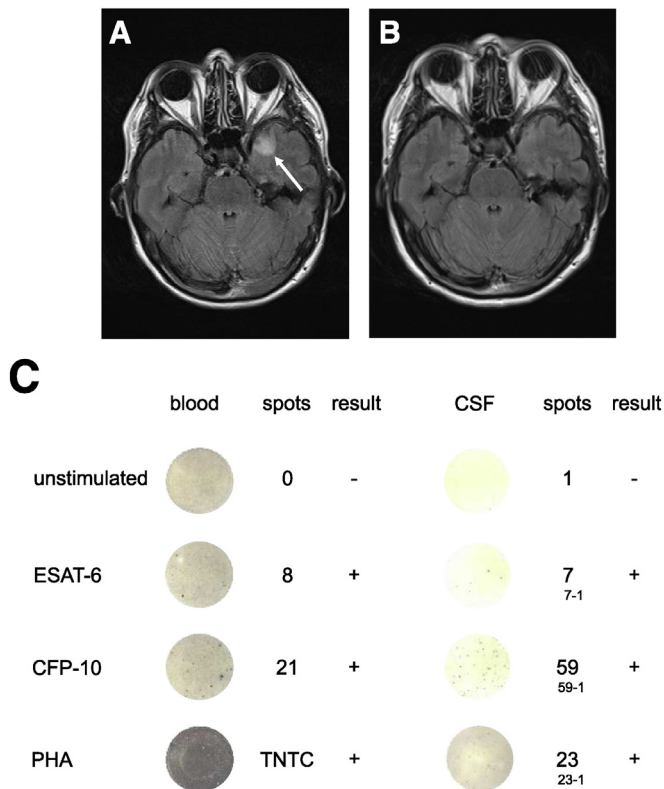


Fig. 1. Cerebral MRI at onset of neurological symptoms (A) and after two weeks of therapy with anti-mycobacterial agents (B) in axial fluid-attenuated inversion recovery (FLAIR) images. (C) ELISpot for detection of immune reactivity against mycobacterial antigens with lymphocytes from blood and CSF of a patient with tuberculous meningoencephalitis. Number of spots indicating T lymphocytes that have secreted IFN- γ in response to the mycobacterial antigens, ESAT-6 or/and CFP-10, as well as to the mitogen phytohemagglutinin (PHA) from blood and CSF are shown. TNTC indicates too numerous to count.

reaction of CSF ELISpot is conceivable, particularly in the early stage of CNS TBC compared to the above mentioned parameters. In 2008, Köster et al. first reported a patient with suspected TBC in whom ELISpot was used not only with lymphocytes from blood but also from CSF [2]. The authors reported that they were able to detect CNS infection by *M. tuberculosis* four weeks ahead of cultural detection. In the same year, the first prospective case series of ten patients with TBC with CNS infection revealed a sensitivity of 90% and specificity of 100% [6]. Another prospective analysis of 37 cases who were suspected to have CNS TBC revealed a sensitivity and specificity of 75% for ELISpot with CSF derived lymphocytes compared to 91% and 63% for blood derived lymphocytes, however only seven patients were classified as confirmed TBC by culture [7]. The combined sensitivity of ELISpot from CSF and blood to diagnose CNS TBC was shown to be 94% with a negative likelihood ratio of 0.14 in 2010 by Kim et al. [8]. The specificity could be increased up to 100% when patients had a ratio of lymphocytes from CSF to lymphocytes from blood of 2 or higher. CSF ELISpot had a higher diagnostic value than clinical prediction for CNS infection with TBC in immune compromised patients in regions with endemic HIV infections. Even in these patients in whom deficient T cell reactivity is assumed, a sensitivity of 58% and specificity of 94% were reached by this approach [9]. Park et al. showed in a study of 16 patients with TBC that the results of serial analysis of ELISpot with lymphocytes from blood are overall variable within an individual's immune response. Therefore the authors conclude that this approach is ineffective in predicting clinical response to therapy. In contrast, presence of TBC specific T cells as demonstrated by ELISpot in CSF in the first six weeks of therapy is a predictor of therapy failure [10].

Based on our case and the review of the literature, ELISpot from lymphocytes from CSF for detection of mycobacterial antigens seems to be a very good method to diagnose CNS TBC and to bridge time until results from bacterial cultures are available. The additive information obtained by ELISpot from lymphocytes of CSF can be used to start with early antimycobacterial treatment.

5. Conclusion

ELISpot with lymphocytes from CSF for detection of immune reactivity against mycobacterial antigens should be an essential part of the routine diagnostic pathway in cases with meningitis or meningoencephalitis possibly caused by *M. tuberculosis*.

Author contributions

J. Blume: study concept and design, analysis and interpretation of data, and drafting of manuscript.

J. Köstler: analysis and interpretation of data, and drafting of manuscript.

R. Weissert: study concept and design, analysis and interpretation of data, drafting/revising of manuscript, and study supervision.

Disclosure

None for any author.

Acknowledgments

We thank Kelly La France for linguistic advice.

References

- [1] G.E. Thwaites, R. van Toorn, J. Schoeman, Tuberculous meningitis: more questions, still too few answers, *Lancet Neurol.* 12 (2013) 999–1010.
- [2] K. Kusters, R. Nau, A. Bossink, et al., Rapid diagnosis of CNS tuberculosis by a T-cell interferon-gamma release assay on cerebrospinal fluid mononuclear cells, *Infection* 36 (2008) 597–600.
- [3] G.E. Thwaites, T.T. Chau, K. Stepniewska, et al., Diagnosis of adult tuberculous meningitis by use of clinical and laboratory features, *Lancet* 360 (2002) 1287–1292.
- [4] M. Sunbul, A. Atilla, S. Esen, et al., Thwaites' diagnostic scoring and the prediction of tuberculous meningitis, *Med. Princ. Pract.* 14 (2005) 151–154.
- [5] C.H. Liao, C.H. Chou, C.C. Lai, et al., Diagnostic performance of an enzyme-linked immunosorbent assay for interferon-gamma in extrapulmonary tuberculosis varies between different sites of disease, *J. Infect.* 59 (2009) 402–408.
- [6] M.M. Thomas, T.S. Hinks, S. Raghuraman, et al., Rapid diagnosis of *Mycobacterium tuberculosis* meningitis by enumeration of cerebrospinal fluid antigen-specific T-cells, *Int. J. Tuberc. Lung Dis.* 12 (2008) 651–657.
- [7] S.H. Kim, K. Chu, S.J. Choi, et al., Diagnosis of central nervous system tuberculosis by T-cell-based assays on peripheral blood and cerebrospinal fluid mononuclear cells, *Clin. Vaccine Immunol.* 15 (2008) 1356–1362.
- [8] S.H. Kim, O.H. Cho, S.J. Park, et al., Rapid diagnosis of tuberculous meningitis by T cell-based assays on peripheral blood and cerebrospinal fluid mononuclear cells, *Clin. Infect. Dis.* 50 (2010) 1349–1358.
- [9] V.B. Patel, R. Singh, C. Connolly, et al., Cerebrospinal T-cell responses aid in the diagnosis of tuberculous meningitis in a human immunodeficiency virus- and tuberculosis-endemic population, *Am. J. Respir. Crit. Care Med.* 182 (2010) 569–577.
- [10] K.H. Park, M.S. Lee, S.O. Lee, et al., Kinetics of T-cell-based assays on cerebrospinal fluid and peripheral blood mononuclear cells in patients with tuberculous meningitis, *Korean J. Intern. Med.* 29 (2014) 793–799.