

Review Article

Surgical resection of sporadic and hereditary hemangioblastoma: Our 10-year experience and a literature review

Elisabeth Bründl, Petra Schödel, Odo-Winfried Ullrich, Alexander Brawanski, Karl-Michael Schebesch

Department of Neurosurgery, University Medical Center Regensburg, Germany

E-mail: *Elisabeth Bründl - elisabeth.bruendl@ukr.de; Petra Schödel - petra.schoedel@ukr.de; Odo-Winfried Ullrich - winfried.ullrich@ukr.de; Alexander Brawanski - alexander.brawanski@ukr.de; Karl-Michael Schebesch - karl-michael.schebesch@ukr.de

*Corresponding author

Received: 20 May 14 Accepted: 30 July 14 Published: 22 September 14

This article may be cited as:

Bründl E, Schödel P, Ullrich O, Brawanski A, Schebesch K. Surgical resection of sporadic and hereditary hemangioblastoma: Our 10-year experience and a literature review. *Surg Neurol Int* 2014;5:138.

Available FREE in open access from: <http://www.surgicalneurologyint.com/text.asp?2014/5/1/138/141469>

Copyright: © 2014 Bründl E. This is an open-access article distributed under the terms of the Creative Commons Attribution License, which permits unrestricted use, distribution, and reproduction in any medium, provided the original author and source are credited.

Abstract

Background: Hemangioblastomas (HBLs) are benign neoplasms that contribute to 1-2.5% of intracranial tumors and 7-12% of posterior fossa lesions in adult patients. HBLs either evolve hereditarily in association with von Hippel–Lindau disease (vHL) or, more prevalently, as solitary sporadic tumors. Only few authors have reported on the clinical presentation and the neurological outcome of HBL.

Methods: We retrospectively analyzed the clinical, radiological, surgical, and histopathologic records of 24 consecutive patients (11 men, 13 women; mean age 51.3 years) with HBL of the posterior cranial fossa, who had been treated at our center between 2001 and 2012. We reviewed the current literature, and discussed our findings in the context of previous publications on HBL. The study protocol was approved by the local ethics committee (14-101-0070).

Results: Mean time to diagnosis was 14 weeks. The extent of resection (EOR) was total in 20 and near total in 4 patients. Four patients required revision within 24 h because of relevant postoperative bleeding. One patient died within 14 days. One patient required permanent shunting. At discharge, 75% of patients [$n = 18$, modified Rankin scale (mRS) 0-1] showed no or at least resolved symptoms. Mean follow-up was 21 months. Two recurrences were detected during follow-up.

Conclusions: In comparison to other benign entities of the posterior fossa, time to diagnosis was significantly shorter for HBL. This finding indicates the rather aggressive biological behavior of these excessively vascularized tumors. In our series, however, the rate of complete resection was high, and morbidity and mortality rates were within the reported range.

Key Words: CNS hemangioblastoma, neurological outcome, posterior cranial fossa, von Hippel–Lindau disease

Access this article online

Website:

www.surgicalneurologyint.com

DOI:

10.4103/2152-7806.141469

Quick Response Code:



INTRODUCTION

Hemangioblastomas (HBLs) represent benign capillary-rich neoplasms of the central nervous system (CNS) that are

derived from a blood vessel lineage. HBLs account for 1-2.5% of intracranial tumors and 7-12% of posterior fossa lesions in adult patients.^[21,32,33] Morphologically, HBLs present heterogeneously, mainly as cystic, solid-cystic,

or solid lesions that consist of a small, abundantly vascularized, mural nidus surrounded by a variably lipidized stromal cell component of unknown histogenesis.^[2,4,7,13,30,38] HBLs predominantly evolve as solitary sporadic lesions, but may also grow hereditarily in association with von Hippel–Lindau (vHL) disease.^[4,8,21,24,30,42] vHL is a clinically heterogeneous syndrome of varying severity that is characterized by a predisposition to develop various benign and malignant tumors, for example, retinal angiomas, endolymphatic sac tumors, renal cell carcinomas (RCC), pancreatic tumors, and pheochromocytomas. However, solely cystic lesions may also develop, for example, of the epididymis or the mandible.^[4,6,8,21,24,30,42] Hence, patients with vHL require interdisciplinary treatment by neurosurgeons or surgeons, geneticists, and internists. Approximately 25% of CNS HBLs arise in the setting of vHL.^[11,22] HBLs are potentially curable, and the outcome is favorable provided that the solid component of the tumor can be resected.^[8,44,46,49]

Consulting our database, we wanted to retrospectively analyze the clinical presentation, neuroradiological findings, surgical aspects, and neurological outcome of patients with HBL of the posterior cranial fossa, both with and without vHL, who had undergone surgery at our center over the past 10 years.

METHODS

Between 2001 and 2012, 24 consecutive patients with HBL in the posterior cranial fossa underwent suboccipital craniotomy and consecutive microsurgical resection in our department. We retrospectively reviewed the patients' clinical, neuroradiological, surgical, and histopathologic records. We excluded three patients with tumor recurrence because they had undergone initial surgery before 2001. All patients were treated according to our standardized postoperative treatment regimen: (1). all patients were transferred to the intensive care unit for postoperative monitoring for at least 24 h; (2). corticosteroids were routinely administered to avoid brain edema; and (3). post-surgical computed tomography (CT) or magnetic resonance imaging (MRI) was obtained within 24 h.

The nature and duration of symptoms, the manifestations of vHL, and associated positive family history were evaluated by analyzing the patients' charts. vHL was diagnosed on a solely clinical basis according to previous updated criteria.^[8,23,30] Fundoscopy and abdominal echography or CT scans were carried out to screen for vHL.

Cerebral MRI and CT scans were analyzed with regard to tumor localization, tumor size (maximum diameter), and the number of lesions as well as their signal density in the T1 sequence after intravenous gadolinium injection. Further factors to be analyzed were surrounding tumor

edema, hemorrhage, abnormally large vessels within or adjacent to the tumor, morphology (pure cyst, cyst with a mural nidus, mixed solid and cystic components, syrinx formation), and the presence or absence of hydrocephalus. Tumor location was defined by the predominant anatomical area of the solid part of the lesion. Preoperative hydrocephalus was diagnosed if external ventricular drainage (EVD) placement was required. Moreover, we assessed the surgical approach, the adhesive neurovascular structures, the duration of the surgical procedure, and the extent of resection (EOR; total or near total), as well as the complications and recurrence rates. The EOR was assessed by early control CT ($n = 14$) or MRI ($n = 10$) scans. During follow-up, all patients underwent MRI to screen for residual or recurrent tumors, defined as residual or new areas of contrast enhancement along the borders of the resection cavity. Postoperative complications were treated within 24 h after surgery (early complications) and between 24 h and up to 10 days postoperatively (late complications). Patient outcome was assessed immediately after surgery, at discharge, and, if available, at follow-up according to the modified Rankin scale (mRS) and the Glasgow Outcome Scale (GOS). Outcomes of mRS values of 0-1 or GOS values of 5-4 were considered good, mRS values of 2-3 or GOS value of 3 as fair, and mRS values of 4-5 or GOS values of 2-1 as poor. The overall follow-up interval ranged from 2 to 99 months with a mean follow-up time of 21 months. Two patients dropped out during follow-up.

We reviewed the current literature and discussed our findings in the context of previous publications on HBL.

The study protocol was approved by the local ethics committee (14-101-0070).

RESULTS

Patient profiles

During the study period, 27 patients had undergone 37 surgical procedures for CNS HBL. Three patients with tumor recurrence who had received initial surgery before 2001 were excluded. Of the 24 patients included in our study, 13 (54%) were women and 11 (46%) were men. The mean age was 51.3 years (ranging from 27 to 81 years) [see Figure 1]. Twenty-two HBLs had been localized within the cerebellar hemispheres, and two were in the craniocervical junction area, of which one partially extended into the medulla oblongata.

Clinical features

The major presenting symptoms were headache, vertigo or ataxia, and nausea. The other symptoms were neck pain, emesis, dysarthria, and cranial nerve deficits [Table 1]. The mean time to diagnosis was 14 weeks (ranging from 1 day to 57 weeks) in the entire cohort, 7 weeks in the hereditary subgroup, and 15 weeks in the sporadic HBL subgroup [Figure 2].

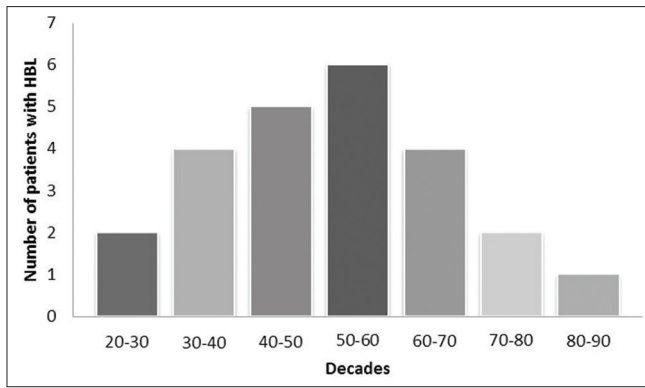


Figure 1: Age distribution by decades of patients with hemangioblastoma in the posterior cranial fossa

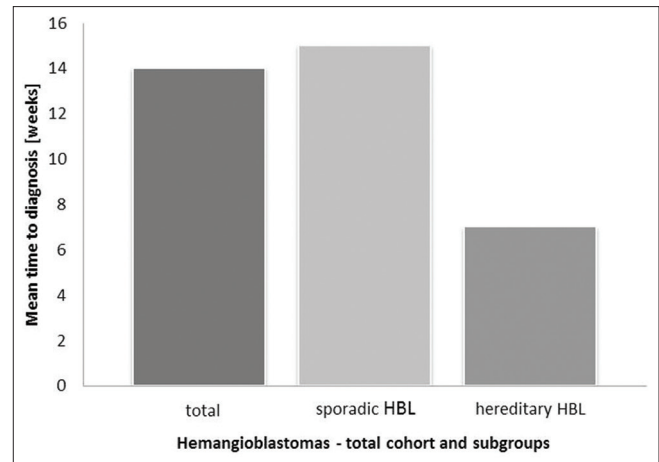


Figure 2: Mean time to diagnosis in the entire cohort (n = 24, ranging from 1 day to 57 weeks) in the subgroup with sporadic hemangioblastoma (HBL) (n = 21) and in the subgroup with hereditary HBL [von Hippel-Lindau disease (vHL), n = 3, ranging from 4 to 12 weeks]. Analyses showed a considerably shorter mean time from the onset of symptoms to diagnosis in patients with vHL disease-associated HBL

Table 1: Preoperative clinical features of hemangioblastoma in the posterior cranial fossa (n=24 patients)

Clinical features and symptoms	N
Age (years)	
21-30	2
31-40	4
41-50	5
51-60	6
61-70	4
>70	3
Sex	
Female	13
Male	11
Duration of symptoms (weeks)	
0-1	2
2-8	8
9-15	5
16-32	4
>32	5
Presenting symptoms	
Headache	22
Vertigo	15
Ataxia	15
Nausea	10
Emesis	7
Neck pain	7
Recurring syncopes	5
Dysarthria	3
Sensomotoric deficits or unilateral symptoms	3
Diplopia or anisocoria	3
Depressive mood	1
Dysgraphia	1

Neuroimaging

On MRI scans (n = 12), eight lesions appeared to be cystic, showing a characteristic mural nodular component with strong homogenous enhancement after gadolinium injection. Two lesions were purely solid, two were both solid and cystic, and none of the lesions was purely cystic

[Figure 3]. The mean tumor size was 36.8 mm (ranging from 15.0 to 63.7 mm). Perifocal edema was found in 10 patients. All patients except one had only one solitary CNS HBL. There were no signs of any intratumoral hemorrhage. Among the five MRIs of the spinal cord available, no syrinx formation could be detected.

Surgery

Three patients required an EVD placement preoperatively because of occlusive hydrocephalus and one patient intraoperatively because of prolonged bleeding into the fourth ventricle. All operations were done via the retrosigmoid suboccipital approach, four operations included a laminectomy of the atlas, and one of those an additional laminectomy of the axis. The mean duration of the surgical procedure was 218 min (ranging from 75 to 900 min). Strong intraoperative bleeding due to abundant tumor vascularization was reported for five patients, and two of them required a blood transfusion. Cortical adherences were reported for three patients. The EOR was total in 20 patients and near total in 4 patients. Three of them were operated on again after the postoperative control MRI scan had shown a residual nodule. In one patient, complete removal could not be achieved because of a highly vascularized nidus. The histopathologic findings confirmed the diagnosis of HBL in all patients.

Postoperative course and long-term outcome

Within 24 h postoperatively, 14 patients did not show any neurological deficits. Some patients had transient cranial nerve paresis (n = 3) (e.g. diplopia), hemiparesis (n = 1), ataxia (n = 1), or nausea and emesis (n = 1). Within the first 24 h after surgery, four patients underwent immediate surgical revision with hematoma evacuation because of relevant bleeding, and

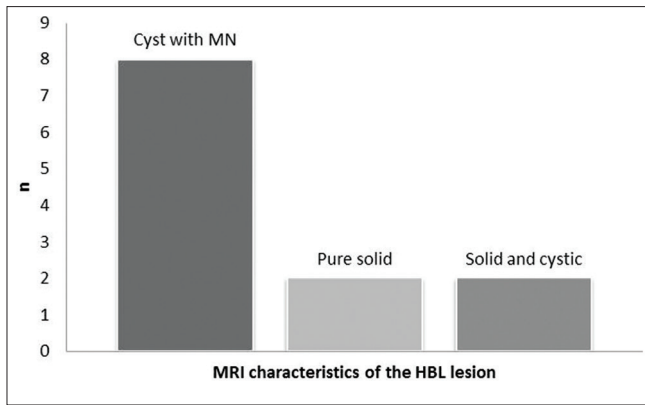


Figure 3: Characteristics of available preoperative MRI of 12 out of 24 patients with hemangioblastoma. MN: Mural nodule

three of them additionally required an EVD placement. Only one of these four patients underwent permanent ventriculoperitoneal shunting 1 month later. Within the first 10 postoperative days, we found cerebrospinal fluid (CSF) infections ($n = 3$, 13%), infratentorial ischemia ($n = 2$, 8%), pneumonia ($n = 2$, 8%), psycho-syndrome ($n = 1$, 4%), and a Mallory–Weiss lesion ($n = 1$, 4%). Perioperative mortality was 4% ($n = 1$) as one patient died due to postoperative bleeding.

At discharge, 75% ($n = 18$, mRS 0–1) of the patients showed no or at least resolved symptoms. The remaining patients (mRS 2–3 in $n = 1$ and mRS 4–5 in $n = 4$) had persistent ataxia ($n = 3$, 13%) and newly developed diplopia ($n = 1$, 4%) and hemiparesis ($n = 1$; 4%). According to the GOS grading, outcome at discharge was good in 18 patients (GOS 5–4), fair in 4 patients (GOS 3), and poor in 2 patients (GOS 2–1).

The overall follow-up period ranged from 2 to 99 months with a mean follow-up time of 21 months. Differentiating between patients with vHL-associated HBL and sporadic HBL, we found a mean follow-up time of 75 months for vHL and 19 months for sporadic HBL. Two tumor recurrences were detected during follow-up. One patient underwent re-operation 32 months after initial surgery. The other patient (vHL subgroup) had regular MRI controls because of two small contrast-enhanced nodules in the resection cavity that were stable and asymptomatic within the 57 months of follow-up (“watch and wait”). At follow-up, outcome was good in 14 (according to mRS) and 15 patients (according to GOS), fair in 2 (mRS) and 4 (GOS) patients, and poor in 5 (mRS) and 2 (GOS) patients.

DISCUSSION

HBLs are benign CNS lesions, classified as grade I according to the World Health Organization (WHO), with a highly vascularized solid tumor component. The posterior inferior cerebellar arteries and their drainage into the transverse, sigmoid, and rectus sinuses may

occasionally require preoperative embolization.^[31,48] Sometimes, preoperative embolization may significantly reduce the tumor blood supply and thus avoid profuse intraoperative bleeding. In this way, surgery in sensitive areas may be facilitated.^[37,39,41] In our cohort, five patients underwent preoperative cerebral digital subtraction angiography. Embolization prior to surgery was not conducted in any of the patients. Besides, none of our patients received any adjuvant therapy after surgery. The effectiveness of both radiotherapy and chemotherapy in HBL has been questioned.^[5,25,28] Both techniques are solely used for residual or recurrent tumors after microsurgery. Neurosurgical resection represents the treatment of choice, providing long-term tumor control.^[1,14,20,26,36]

Commonly, HBLs develop within the cerebellar hemispheres, whereas HBLs in the cerebellopontine angle, brain stem, ventricles, or supratentorially are rather rare.^[10,19,36,47] About 20% of CNS HBLs develop within the spinal cord, contributing to 2–4% of spinal tumors.^[21,34,45] Accordingly, 92% of the infratentorial HBLs in our patients were localized in the cerebellum and none originated from the brain stem. In comparison to sporadic HBLs, vHL is more often associated with the brain stem, spinal cord, and the spinal nerve roots.^[4,30]

As depicted in Figure 1, our series comprised 13 (54%) women and 11 (46%) men, with a mean age of 51.3 years (ranging from 27 to 81 years) at the time of diagnosis. Consistent with our results [Table 1], recent trials^[16,27] have identified headache, cerebellar signs, and nausea as the main presenting symptoms. Even in HBL, non-specific clinical manifestations were reported that were localized in functionally important areas, such as the brain stem and the cerebellopontine angle.^[31,48] Clinical diagnosis of vHL was solely based on the updated criteria described by Conway *et al.*^[8] In the absence of any family history of CNS or retinal HBL, diagnosis of vHL requires the presence of multiple or of at least two HBLs or one HBL and one of the visceral manifestations described above. In the case of a positive family history of CNS or retinal HBL, diagnosis of vHL necessitates the presence of only one HBL or any other manifestation of vHL.^[8,23,30] As previously stated in the literature, many patients with HBL do unfortunately not undergo appropriate screening for vHL.^[6,27] A possibly underrated percentage of 10–40% of primary symptomatic HBL has been reported to be vHL associated.^[6,8,21,27,35]

Despite basically similar histological characteristics, the biological behavior of syndromic HBL may be more aggressive than that of sporadic HBL because of its rapid growth pattern or its multifocal involvement.^[29,32,42] Our results confirm the idea of the more aggressive nature of hereditary HBL because the mean time to diagnosis of 7 weeks of the three patients diagnosed with vHL was significantly shorter than that of the

patients with sporadic HBL who tended to present after 15 weeks [Figure 2]. Compared to a recent analysis of 10 patients with epidermoids of the posterior cranial fossa (unpublished data), we found a significantly longer mean duration from the onset of neurological symptoms to the time of diagnosis of 121 weeks (2.3 years). In contrast to other tumor entities of the posterior cranial fossa, such as histomorphologically inert and non-vascularized epidermoids, HBLs, particularly of the syndromic subtype, seem to be considerably more aggressive. Such behavior may be due to a more rapid, space-occupying expansion of the cyst, causing focal compression of the surrounding tissue. Lesion growth bears the risk of decompensation of the brain stem and bleeding. Despite being rare, bleeding significantly increases morbidity and mortality.^[9,12] Because the majority of symptomatic HBL is associated with cysts,^[42] solid and cystic lesions may differ regarding their clinical manifestation. When reviewing 17 patients with solid HBL, Rachinger and colleagues^[31] emphasized that solid tumors are much more complex to handle than the microsurgical resection of a cystic compartment. This complexity is caused by the frequent localization of solid tumors in eloquent areas and their more complex vascular architecture and blood supply. Rachinger *et al.* yielded good functional results with *en bloc* removal and also discussed the histological features of HBL: The stromal cells, representing the neoplastic component of the tumor, express, among others, a high level of different growth factors and receptors, such as vascular endothelial growth factor (VEGF). Excessive expression of VEGF may result in peritumorous edema. We observed peritumorous edema in two patients with solid HBL that account for approximately one-third of HBLs.^[17] In these tumors, peritumorous edema may mask radiological diagnosis by mimicking metastatic disease.^[18]

In our study population, the radiologically suspected diagnosis of HBL in preoperative MRI was histologically verified in all patients. Advances in MRI techniques, such as dynamic susceptibility contrast perfusion MRI, perfusion MRI, and susceptibility weighted imaging (SWI), facilitate differential diagnosis with other infratentorial lesions, for instance, pilocytic astrocytoma,^[3,15] vestibular schwannoma,^[50] or tumoral hemorrhage. Such technical advances also improve the potential identification of high-velocity blood vessels.^[40] In 8 out of 12 available preoperative MRI analyses [Figure 3], we observed the predominant radiological pattern of a cyst with an intense gadolinium-enhanced mural nodule [Figure 4].^[38] We noted a mean maximum tumor size of 36.8 mm (ranging from 15.0 to 63.7 mm) that was within the previously reported range (5-57 mm^[16] and 10-40 mm^[31]) of HBL in the posterior cranial fossa. Patients with vHL tend to develop new lesions over time, thus requiring frequent surgery.^[8,21] Frequent tumor recurrence and surgical

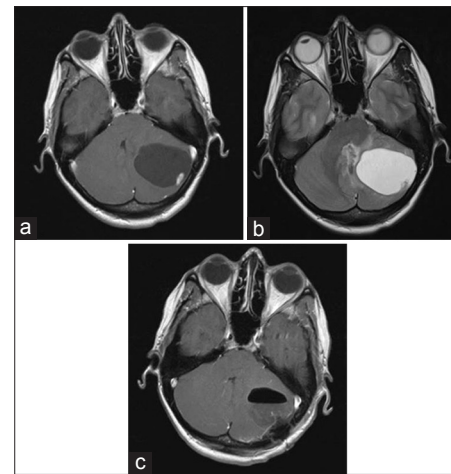


Figure 4: (a) T1-weighted, axial and (b) T2-weighted, axial MRI of a cystic hemangioblastoma localized in the left cerebellar hemisphere, showing the characteristic mural nodule with strong gadolinium enhancement. (c) Postoperative MRI (T1-weighted, axial), confirming total tumor removal and resection of the cystic component after retrosigmoid suboccipital craniotomy. The space-occupying effect and the brain stem compression are alleviated

resection represent the most common causes of morbidity and mortality in patients with vHL disease; in 30-50% of patients, RCC are the cause of death.

Our surgical procedures were conventionally performed in “Concorde” position with the patient’s upper body elevated approximately 15° above the horizontal level and head in neutral position, with the neck flexed. Craniotomy was done via a retrosigmoid suboccipital approach, based on the shape of the venous sinuses, the nidus, and the side and localization of the tumor. In four HBLs with either a space-occupying cerebellar cyst or tumor localization in the craniocervical junction, a laminectomy of C1 (and C2) was required for sufficient exposure of the foramen magnum and the medulla oblongata. Prior to dural incision, an ultrasound-guided localization of the tumor was usually conducted. The strategy of surgical tumor resection differed depending on the morphological characteristics of the HBL. In tumors with an expansive cystic component, the cyst was released before dissecting the mural nidus. In solid tumors, a circumferential dissection with devascularization and *en bloc* removal was favored whenever possible. We achieved complete resection in 83% of our patients ($n = 20$). In one patient with a strongly adhesive and highly vascularized solid HBL extending from the cerebellar vermis to the foramen magnum, complete removal of the tumor was not possible. Because of relevant bleeding on the first postoperative day, the patient underwent immediate surgical revision with hematoma evacuation but died 13 days later because of multi-organ failure. Two patients underwent re-craniotomy after a residual nodule was found in the postoperative

MRI scan. Three tumor recurrences were detected within the follow-up period (mean 21 months). Apart from the above-mentioned difficulties in diagnosing vHL, another limitation in the current literature including the present study is the restricted duration of the follow-up period. Similar follow-up periods have been reported, ranging from 16 days to 132 months,^[27] from 6 to 9 months,^[31] and from 13 to 108 months.^[16] Tumor control was achieved in all patients at the last follow-up. In comparison to the reports by Conway *et al.*^[8] and Padhi *et al.*^[27] reporting a mortality rate of 5% and 8%, respectively, we observed a lower mortality rate of 4%. With regard to surgery-associated morbidity, we noted relevant postoperative bleeding ($n = 4$, 17%), consecutive permanent shunting ($n = 1$, 4%), CSF infections ($n = 3$, 13%), infratentorial ischemia ($n = 2$, 8%), newly developed diplopia ($n = 1$, 4%), and newly developed hemiparesis ($n = 1$, 4%). However, 75% of patients ($n = 18$) were discharged without or at least with resolved symptoms. We found poor outcome at discharge in patients with preexisting encephalomyelitis disseminata ($n = 1$), postoperative cerebellopontine edema ($n = 1$), and postoperative hemorrhage ($n = 2$). In a series of 38 patients with sporadic intracranial HBL, Le Reste *et al.*^[16] reported CSF leaks in 8%, transiently worsened cerebellar syndrome in 3%, peripheral facial palsy in 3%, postoperative external shunts for hydrocephalus in 11%, bulbar syndromes with tetraparesis in 8%, postoperative hematoma of the surgical bed in 3%, and both hemiparesia and lateral homonym hemianopsia in 3% of patients. Rachinger *et al.*^[31] reported a favorable outcome in six patients with solid HBL of the cerebellar hemispheres. Despite improved clinical results because of progress in imaging and microsurgical techniques over the past decades, HBLs within the brain stem still have the most unfavorable prognosis.^[43,48]

Limitations

This is a retrospective observational study with the commonly acknowledged methodological limitations given below.

Preoperative MRI was only available for review for 12 patients of our study population, curtailing preoperative neuroradiological analysis. Furthermore, only in 10 out of 24 patients was an MRI scan assessed as early control imaging, whereas the remaining 14 patients had an early postoperative CT scan, limiting the analysis of residual tumor. However, all patients received MRI for follow-up control.

As previously reported by a number of authors, the exact prevalence of vHL disease may also be misleading in our series because not every patient with HBL was subjected to vHL screening as an in-patient. A precise differentiation

between sporadic HBL and vHL patients is of utmost importance because the complexity of vHL-associated lesions requires interdisciplinary management and prolonged endeavor. Family members of affected patients also have to be counseled and subjected to the full screening protocol, ideally to identify HBL or any other vHL manifestation before the disease could become symptomatic. These issues should be addressed in clinical practice and further prospective research projects.

CONCLUSIONS

In the present study, we correlated our 10-year results with the various findings of previous clinical trials on HBLs. In contrast to other benign tumor entities of the posterior cranial fossa, the biological behavior of excessively vascularized HBLs seems to be rather aggressive as reflected by the short time to diagnosis. We achieved a high rate of complete resection, and morbidity and mortality rates were within the reported range.

vHL disease requires early diagnosis, adequate surgical management, a multimodal therapeutic approach, a lifelong follow-up, and the counseling of patients and their relatives at-risk. These issues are all the more important because of the rather high estimated number of unreported cases due to patients not undergoing the appropriate screening for vHL.

REFERENCES

1. Ahyai A, Woerner U, Markakis E. Surgical treatment of intramedullary tumors (spinal cord and medulla oblongata). Analysis of 16 cases. *Neurosurg Rev* 1990;13:45-52.
2. Baker KB, Moran CJ, Wippold FJ, 2nd, Smirniotopoulos JG, Rodriguez FJ, Meyers SP, et al. MR imaging of spinal hemangioblastoma. *AJR Am J Roentgenol* 2000;174:377-82.
3. Bing F, Kremer S, Lamalle L, Chabardes S, Ashraf A, Pasquier B, et al. Value of perfusion MRI in the study of pilocytic astrocytoma and hemangioblastoma: Preliminary findings. *J Neuroradiol* 2009;36:82-7.
4. Burger PC, Scheithauer BW. Hemangioblastoma. Tumors of the central nervous system, AFIP atlas of tumor pathology; 4th series, Fascicle 7:309-20. Washington DC:ARC Press; 2007.
5. Capitanio JF, Mazza E, Motta M, Mortini P, Reni M. Mechanisms, indications and results of salvage systemic therapy for sporadic and von Hippel-Lindau related hemangioblastomas of the central nervous system. *Crit Rev Oncol Hematol* 2013;86:69-84.
6. Catapano D, Muscarella LA, Guarnieri V, Zelante L, D'Angelo VA, D'Agruma L. Hemangioblastomas of central nervous system: Molecular genetic analysis and clinical management. *Neurosurgery* 2005;56:1215-21.
7. Choyke PL, Glenn GM, Walther MM, Patronas NJ, Linehan WM, Zbar B. von Hippel-Lindau disease: Genetic, clinical, and imaging features. *Radiology* 1995;194:629-42.
8. Conway JE, Chou D, Clatterbuck RE, Brem H, Long DM, Rigamonti D. Hemangioblastomas of the central nervous system in von Hippel-Lindau syndrome and sporadic disease. *Neurosurgery* 2001;48:55-62.
9. de San Pedro JR, Rodriguez FA, Niguez BF, Sanchez JF, Lopez-Guerrero AL, Murcia MF, et al. Massive hemorrhage in hemangioblastomas Literature review. *Neurosurg Rev* 2010;33:11-26.
10. Dow GR, Sim DW, O'Sullivan MG. Excision of large solid haemangioblastomas of the cerebellopontine angle by a skull base approach. *Br J Neurosurg* 2002;16:168-71.

11. Filling-Katz MR, Choyke PL, Oldfield E, Charnas L, Patronas NJ, Glenn GM, et al. Central nervous system involvement in von Hippel-Lindau disease. *Neurology* 1991;41:41-6.
12. Glasker S, Van Velthoven V. Risk of hemorrhage in hemangioblastomas of the central nervous system. *Neurosurgery* 2005;57:71-6.
13. Ho VB, Smirniotopoulos JG, Murphy FM, Rushing EJ. Radiologic-pathologic correlation: Hemangioblastoma. *AJNR Am J Neuroradiol* 1992;13:1343-52.
14. Kohno K, Matsui S, Nishizaki A, Takeda S, Sadamoto K, Sakaki S. Successful total removal of intramedullary hemangioblastoma from the medulla oblongata. *Surg Neurol* 1993;39:25-30.
15. Kumar VA, Knopp EA, Zagzag D. Magnetic resonance dynamic susceptibility-weighted contrast-enhanced perfusion imaging in the diagnosis of posterior fossa hemangioblastomas and pilocytic astrocytomas: Initial results. *J Comput Assist Tomogr* 2010;34:825-9.
16. Le Reste PJ, Henaux PL, Morandi X, Carsin-Nicol B, Brassier G, Riffaud L. Sporadic intracranial haemangioblastomas: Surgical outcome in a single institution series. *Acta Neurochir* 2013;155:1003-9.
17. Lee SR, Sanches J, Mark AS, Dillon WP, Norman D, Newton TH. Posterior fossa hemangioblastomas: MR imaging. *Radiology* 1989;171:463-8.
18. Machein MR, Plate KH. VEGF in brain tumors. *J Neurooncol* 2000;50:109-20.
19. Naik RT, Purohit AK, Dinakar I, Ratnakar KS. Hemangioblastoma of the IV ventricle. *Childs Nerv Syst* 1995;11:499-500.
20. Nakamura N, Sekino H, Taguchi Y, Fuse T. Successful total extirpation of hemangioblastoma originating in the medulla oblongata. *Surg Neurol* 1985;24:87-94.
21. Neumann HP, Eggert HR, Weigel K, Friedburg H, Wiestler OD, Schollmeyer P. Hemangioblastomas of the central nervous system. A 10-year study with special reference to von Hippel-Lindau syndrome. *J Neurosurg* 1989;70:24-30.
22. Neumann HP, Wiestler OD. Von Hippel-Lindau disease: A syndrome providing insights into growth control and tumorigenesis. *Nephrol Dial Transplant* 1994;9:1832-3.
23. Neumann HP. Basic criteria for clinical diagnosis and genetic counseling in von Hippel-Lindau syndrome. *Vasa* 1987;16:220-6.
24. Niemela M, Lemeta S, Summanen P, Bohling T, Sainio M, Kere J, et al. Long-term prognosis of haemangioblastoma of the CNS: Impact of von Hippel-Lindau disease. *Acta Neurochir* 1999;141:1147-56.
25. Niemela M, Lim YJ, Soderman M, Jaaskelainen J, Lindquist C. Gamma knife radiosurgery in 11 hemangioblastomas. *J Neurosurg* 1996;85:591-6.
26. Nishimoto A, Kawakami Y. Surgical removal of hemangioblastoma in the fourth ventricle. *Surg Neurol* 1980;13:423-7.
27. Padhi S, Sarangi R, Challa S, Bussary P, Panigrahi MK, Purohit AK. A 10-year retrospective study of hemangioblastomas of the central nervous system with reference to von Hippel-Lindau (VHL) disease. *J Clin Neurosci* 2011;18:939-44.
28. Pan L, Wang EM, Wang BJ, Zhou LF, Zhang N, Cai PV, et al. Gamma knife radiosurgery for hemangioblastomas. *Stereotact Funct Neurosurg* 1998;70 Suppl 1:179-86.
29. Peyre M, David P, Van Effenterre R, Francois P, Thys M, Emery E, et al. Natural history of supratentorial hemangioblastomas in von Hippel-Lindau disease. *Neurosurgery* 2010;67:577-87.
30. Plate KH, Vortmeyer AO, Zagzag D, Neumann HPH. Von Hippel-Lindau disease and hemangioblastoma. In: Louis DN, Ohgaki H, Weistler OC, editors *World Health Organization classification of tumors of the central nervous system*. 4th ed. Lyon: IARC Press; 2007. p. 215-7.
31. Rachinger J, Buslei R, Prell J, Strauss C. Solid haemangioblastomas of the CNS: A review of 17 consecutive cases. *Neurosurg Rev* 2009;32:37-47.
32. Resche F, Moisan JP, Mantoura J, de Kersaint-Gilly A, Andre MJ, Perrin-Resche I, et al. Haemangioblastoma, haemangioblastomatosis, and von Hippel-Lindau disease. *Adv Tech Stand Neurosurg* 1993;20:197-304.
33. Russel DS, Rubinstein LJ. *Pathology of tumors of the nervous system*. 5th ed. London: Arnold Publishers; 1989.
34. Singounas EG. Haemangioblastomas of the central nervous system. *Acta Neurochir* 1978;44:107-13.
35. Sora S, Ueki K, Saito N, Kawahara N, Shitara N, Kirino T. Incidence of von Hippel-Lindau disease in hemangioblastoma patients: The University of Tokyo Hospital experience from 1954-1998. *Acta Neurochir* 2001;143:893-6.
36. Spetzger U, Bertalanffy H, Huffmann B, Mayfrank L, Reul J, Gilsbach JM. Hemangioblastomas of the spinal cord and the brainstem: Diagnostic and therapeutic features. *Neurosurg Rev* 1996;19:147-51.
37. Standard SC, Ahuja A, Livingston K, Guterman LR, Hopkins LN. Endovascular embolization and surgical excision for the treatment of cerebellar and brain stem hemangioblastomas. *Surg Neurol* 1994;41:405-10.
38. Sundaram C, Rammurti S, Reddy JJ, Prasad SS, Purohit AK. Hemangioblastoma: A study of radiopathologic correlation. *Neurol India* 2003;51:373-5.
39. Takeuchi S, Tanaka R, Fujii Y, Abe H, Ito Y. Surgical treatment of hemangioblastomas with presurgical endovascular embolization. *Neurol Med Chir* 2001;41:246-51.
40. Thomas B, Somasundaram S, Thamburaj K, Kesavadas C, Gupta AK, Bodhey NK, et al. Clinical applications of susceptibility weighted MR imaging of the brain - a pictorial review. *Neuroradiology* 2008;50:105-16.
41. Tognetti F, Galassi E, Servadei F, Gaist G. Haemangioblastomas of the brain stem. *Neurochirurgia* 1986;29:230-4.
42. Wanebo JE, Lonser RR, Glenn GM, Oldfield EH. The natural history of hemangioblastomas of the central nervous system in patients with von Hippel-Lindau disease. *J Neurosurg* 2003;98:82-94.
43. Wang C, Zhang J, Liu A, Sun B. Surgical management of medullary hemangioblastoma. Report of 47 cases. *Surg Neurol* 2001;56:218-26.
44. Weil RJ, Lonser RR, DeVroom HL, Wanebo JE, Oldfield EH. Surgical management of brainstem hemangioblastomas in patients with von Hippel-Lindau disease. *J Neurosurg* 2003;98:95-105.
45. Yasargil MG, Antic J, Laciga R, de Preux J, Fideler RW, Boone SC. The microsurgical removal of intramedullary spinal hemangioblastomas. Report of twelve cases and a review of the literature. *Surg Neurol* 1976;14:1-8.
46. Young S, Richardson AE. Solid haemangioblastomas of the posterior fossa: Radiological features and results of surgery. *J Neurol Neurosurg Psychiatry* 1987;50:155-8.
47. Zhou LF. Intracranial epidermoid tumours: Thirty-seven years of diagnosis and treatment. *Br J Neurosurg* 1990;42:11-6.
48. Zhou LF, Du G, Mao Y, Zhang R. Diagnosis and surgical treatment of brainstem hemangioblastomas. *Surg Neurol* 2005;63:307-15.
49. Zimmermann M, Seifert V, Schreyer F, Stolke D, Dietz H. Hemangioblastoma: Description of a disease picture and report of 41 cases. *Zentralbl Neurochir* 1997;58:1-6.
50. Zimny A, Sasiadek M. Contribution of perfusion-weighted magnetic resonance imaging in the differentiation of meningiomas and other extra-axial tumors: Case reports and literature review. *J Neurooncol* 2011;103:777-83.