

Implant-supported prostheses with temporomandibular joint reproduction after hemimandibular resection: a case report

Fabrizio Carini MD, DDS
 Salvatore Longoni MD, DMD, DDS
 Valeria Pisapia DMD
 Gianbattista Gatti DMD, DDS
 Dario Monai DMD, DDS
 Gianluca Porcaro DMD, DDS

Department of Surgery and Translational Medicine,
 University of Milan-Bicocca, Monza, Italy

Corresponding author:

Gianluca Porcaro
 School of Oral Surgery
 University of Milan-Bicocca,
 via Pergolesi 33
 20900 Monza, Italy
 E-mail: gianluca.porcaro@unimib.it

Summary

Aim of the study. The change in anatomy and physiology resulting from radical mandible surgery is often exacerbated by radiation therapies that make the mucosa atrophic and susceptible to irritation and ulceration rendering the task of creating functional complete dentures for edentulous subjects very challenging to prosthodontists. The aim of this study is to describe an implant supported denture rehabilitation in an edentulous hemimandibulectomized patient with a singular prosthetic design in order to compensate for the lack of a condylar process.

Materials and methods. The subject of the clinical case, had a history of squamous cell carcinoma of the right tonsillar region for which it was subjected to a hemimandibulectomy and was primarily rehabilitated with an over denture mounted onto a bar furnished by a resin condylar eminence in articulation with the glenoid fossa of the upper denture. The need to provide greater stabilization for the upper prosthesis led to a maxillary implant insertion and to the realization of a new joint connection that was constituted inferiorly by a titanium condyle and superiorly by a teflon acetabulum.

Discussion. The prosthetic balance guaranteed by the second rehabilitation greatly affected the biomechanics of mastication leading to a reduction of eccentric interferences, a stabilization of centric occlusion, and a lowering of intensity contraction by masticatory muscles. This difference

is well represented by two and three-dimensional plans obtained from the application of a T-Scan III device.

Conclusions. The rehabilitative solution proposed was effective in resolving the lateral deviation, in relieving masticatory and speech discomfort, as well as restoring an aesthetically acceptable appearance in a hemimandibulectomized and not reconstructed patient.

Key words: hemimandibulectomy, implant-supported prostheses, computerized occlusion analysis, mandibular deviation, condylar prosthesis.

Introduction

The treatment of oral neoplasia often requires radical surgery with or without radiation or chemotherapy approaches to completely eliminate the pathologic condition and to prevent possible relapses (1).

The two most common sites of oral cancer are the lateral border of the tongue and the floor of the mouth with frequent secondary involvement of the mandible (2). Mandibular bone defects usually occur and can be classified, depending upon the extent, into three types (Fig. 1): marginal, segmental, and hemimandibular defects (3). This classification simplifies that provided by Cantor & Curtis in 1971 which contemplated a division of mandibular defects into six classes (4, 5).

Boyde et al. (5) developed the HCL classification scheme where H defects refer to lateral defects of any length up to the midline including the condyle; C defects involve the central segment that is the inter-

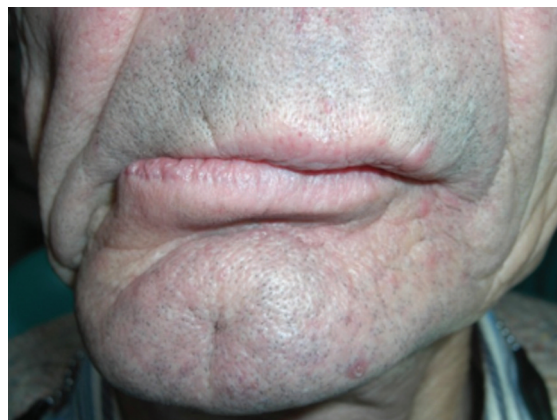

Figure 1. Extra-oral initial situation.

canine area; L defects relate to defects involving the lateral segment excluding the condyle. There are also three lower case letters to describe the soft tissue component. The lower case "o" means no skin or mucosa involved, the lower case "s" refers to defects involving the skin, and "m" relates to mucosa involvement.

The mandible is a major component of the human facial appearance (7) and contributes greatly to the orofacial function; oral competence and mastication are highly dependent on its integrity (1). Loss of continuity of the mandible destroys the balance and symmetry of mandibular function which leads to altered mandibular movements and deviation of the residual fragment towards the resected side (4-7). The degree of the resultant disability is often related to the involved structures and the extent of resection (1-8).

Anterior segment defects that result in the well known "Andy Gump Deformity" challenge the patient's ability to maintain oral intake and can also lead to airway obstructions necessitating a permanent tracheostomy (9). Conversely, posterior mandibular defects in both the dentate and edentulous mandible are better tolerated.

When the resection extends proximally to include the condyle and temporo-mandibular joint (TJM), loss of TJM can result in malocclusion, difficulty with mastication, trismus, and loss of posterior mandibular height (9, 10).

The goals of mandibular reconstruction are to re-establish the form of the lower third of the face and to restore the patient's ability to eat, be intelligible to listeners, and maintain an unencumbered airway that allows proper ventilation. The main techniques of mandibular reconstruction include the use of alloplastic devices, nonvascularized bone grafts, and vascularized free flaps.

When the resection extends proximally to include the condyle and temporo-mandibular joint (TJM), the goal of reconstruction is to maintain its near normal range of motion in order to preserve mandibular excursion (9).

The reconstruction of mandibular continuity is of great importance for facial contour restoration and mandibular function, but it is often inadequate from the masticatory, phonatory, and swallowing point of view. A restoration of these aspects can be obtained only by recreating a proper dental occlusion. Numerous prosthetic methods are employed to minimize deviation and improve masticatory efficiency, including mandibular guide flange prosthesis (11, 12) and palatal based guidance restoration (13, 14).

These approaches are particularly efficient for establishing facial symmetry and achieving maximum intercuspitation in centric relation in condylectomy patients who complain about a loss of balance in the lower third of the face with a mandibular deviation towards the resected side and a cross-bite occlusion on the unresected side.

However, these devices are applicable in partially edentulous patients, since they require dental elements that give anchorage and stability to the pros-

thesis so the flanges are able to carry the role of occlusal guidance. In edentulous patients where resection does not involve only bone structures but provides the sacrifice of tongue, the floor of the mouth, and adjacent soft tissues, the rehabilitative solution is represented by conventional dentures (15) or implant-supported prostheses if allowed by the residual bone amount and cancer prognosis.

The purpose of this study is to describe implant-supported denture rehabilitation on a hemimandibulectomized patient with a singular prosthetic design in order to compensate for the lack of a condylar process.

Clinical case

A 65-year-old male patient was referred to the dentistry section of the San Gerardo Hospital - School of Oral Surgery, University of Milan-Bicocca (Monza) with a chief complaint of difficulty in mastication and speech along with an unaesthetic jaw deviation to the right side (Fig. 1). The patient had a history of squamous cell carcinoma of the right tonsillar region with involvement of the lingual root and the postero-lateral pharyngeal wall for which it was subjected to a hemimandibulectomy, partial glossectomy and latero-cervical emptying.

Cancer surgical resection was followed by reconstruction using pectoralis a myocutaneous flap and radiation therapy (Fig. 2). Clinical and radiographic inspection was followed by extraction of the residual dental roots (Fig. 3).

Implant rehabilitation began four months after tooth extractions and initially provided for the insertion of four implants in the symphysis (Fig. 4).

Six months after surgery through cephalometric values detection and study of the models in an articulator (Fig. 5), prosthetic rehabilitation began, and an overdenture on the lower bar and a total denture on the upper side were realized.

In correspondence with the resection side, the lower denture was implemented with a resin device in order to reproduce the condylar process that is housed in a concavity recreated on the upper prosthesis reproducing the glenoid fossa (Fig. 6).

The analysis of the occlusal contacts was conducted using a computerized analysis system (T-Scan III) (16). The most important result emerging from T-Scan III analysis was the inability of the artificial condyle to mimic all joint movements in a comprehensive manner, creating interference in the initial phase and an imbalance of the upper denture during mastication cycles.

From these results, the need to provide greater stabilization of the upper prosthesis has emerged. Therefore, the second surgery stage with the placement of four implants in the intercanine area took place (Figs. 7, 8).

With the aid of digital and stereolithographic models, a new prosthetic rehabilitation was designed: a titanium condyle was added to the lower denture while a teflon acetabulum, of which several variations were

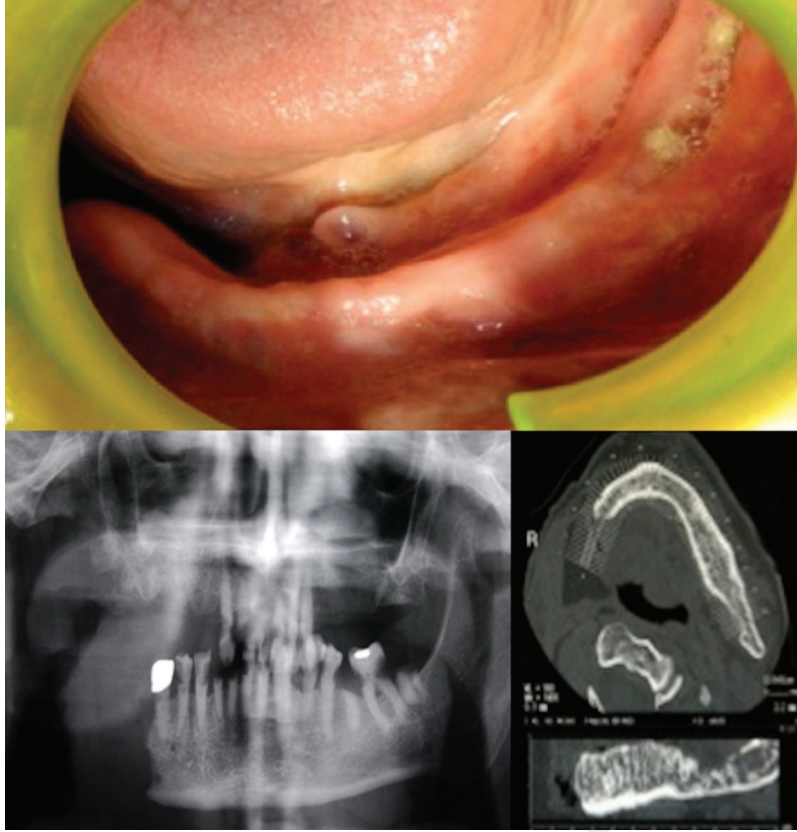


Figure 2. Intra-oral and radiographic initial situation.

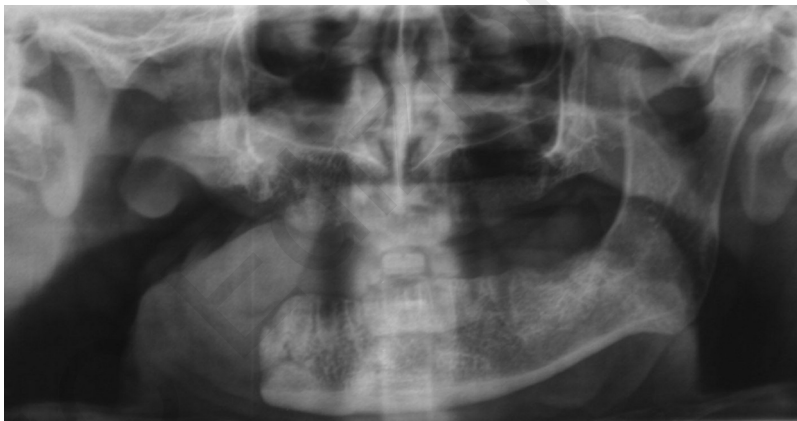

Figure 3. Radiographic situation after dental extractions.

made, was realized to the upper overdenture on bar (Figs. 9, 10).

The comparison of occlusal contacts using T-Scan III revealed a significant difference in both static and dynamic phases of the new prosthetic rehabilitation provided (Figs. 11, 12).

Discussion

The change in anatomy and physiology resulting from radical mandible surgery, is often exacerbated by radia-

tion therapies that make the mucosa atrophic and susceptible to irritation and ulceration and makes the task of creating a functional complete denture for edentulous subjects very challenging to prosthodontists.

The normal integrated neuromuscular control that serves to stabilize the complete denture is compromised, leading to uncoordinated and less precise movements. The absence of masticatory muscle attachment on the surgical side results in a significant rotation of the mandible upon forceful closure, which is of greater intensity in edentulous and non reconstructed patients.

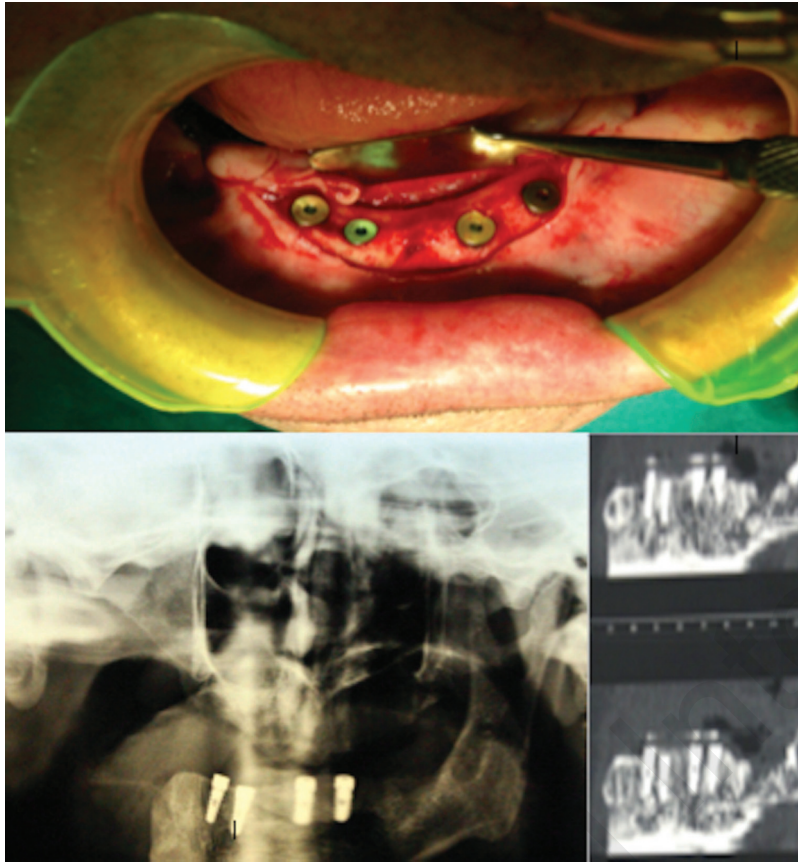


Figure 4. Clinical and radiographic situation after implant insertion in the symphysis.

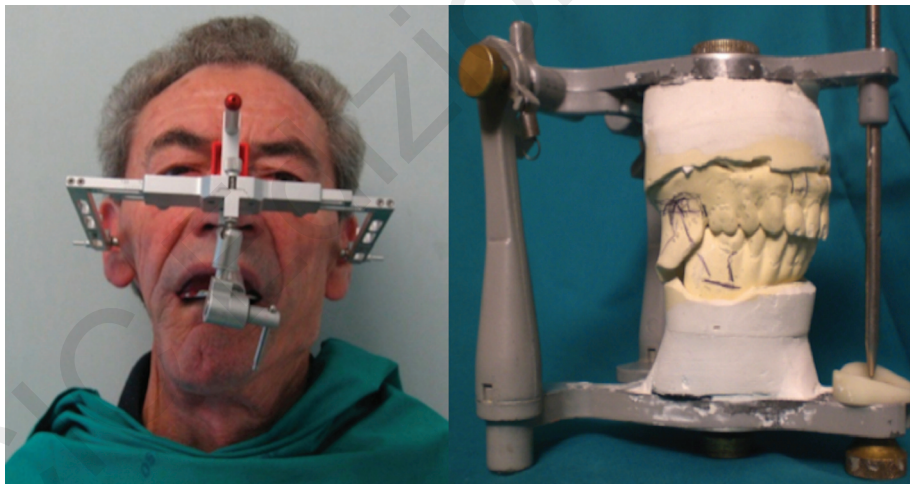


Figure 5. Cephalometric values detection and study of the models in the articulator.

When a patient has been rebuilt, mandibular reconstruction was achieved using alloplastic devices, nonvascularized bone grafts, and vascularized free flaps, as mentioned before.

There are several implantable devices used in mandible reconstruction. The bone plate and screw are the most commonly used implants. These implants are indicated in patients with poor performance status or when the soft tissue defect is more exten-

sive than the bony mandibular defect (9). Nonvascularized bone grafts are used to reconstruct partial mandibular defects from small segmental resections. They are not useful when soft tissue defects are present, which is often the case in patients with squamous cell carcinoma or when patients undergo radiation treatment (17).

Microvascular surgery has revolutionized oral and mandibular reconstruction by ensuring the possibility

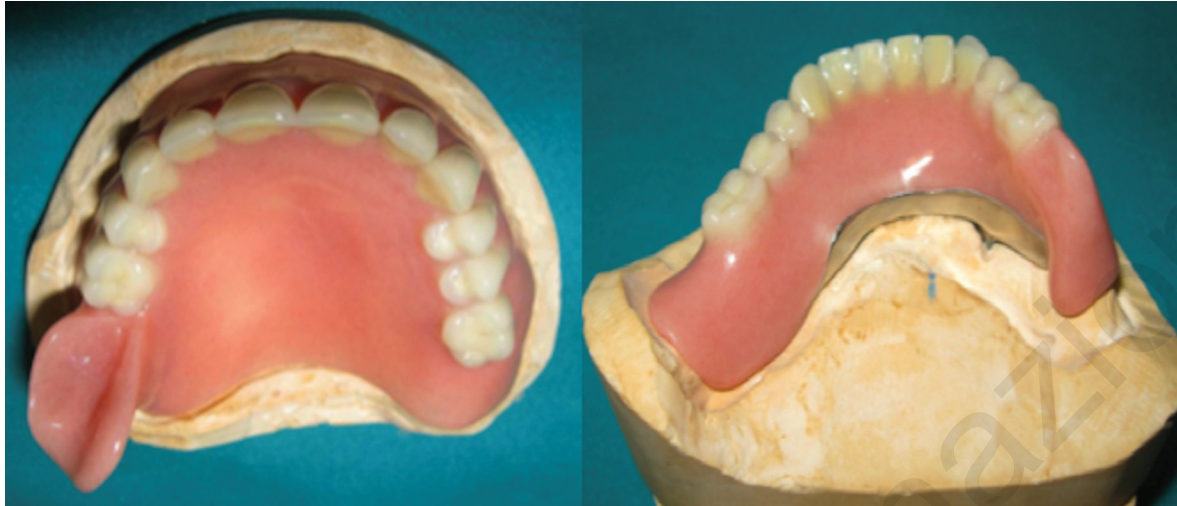

Figure 6. First prosthetic rehabilitation.

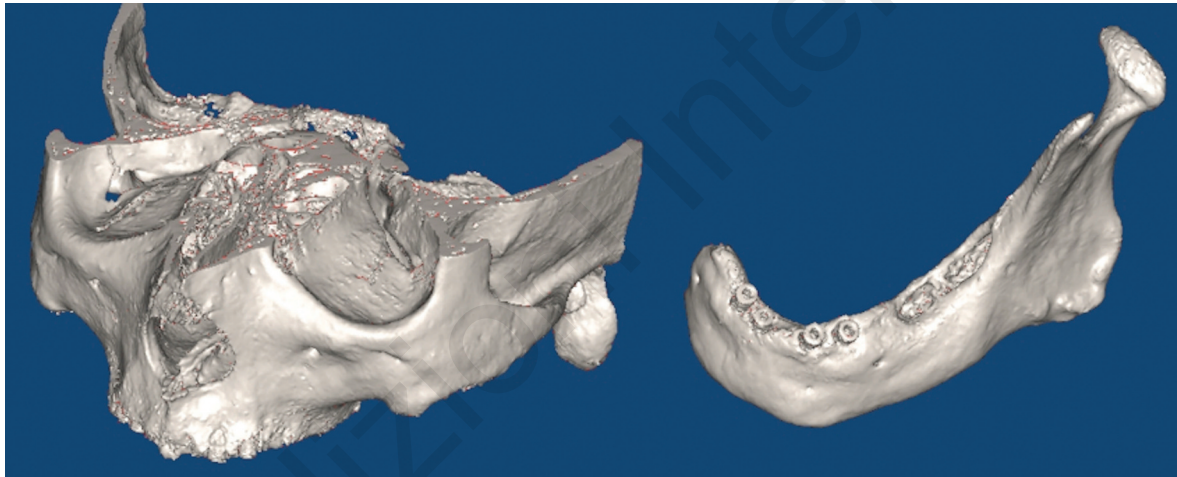


Figure 7. Stereolithography models of the jaws.

of transferring substantial bone with soft tissue to the head and neck. Taylor (18) as well as Sanders and Mayou (18) described the utilization of the iliac bone and overlying skin as a free tissue transfer in 1980. The iliac crest flap offers bone with a height comparable to a native dentate mandible, which improves oral competence by supporting the lower lip, albeit donor site morbidity can be a limiting factor in its utilization (9).

In 1986, Swartz et al (19) introduced the scapular osteocutaneous free flap which is thought to be the most versatile flap for mandible reconstruction, because it can provide up to 14 cm of bone with a well-vascularized skin island and a moderate amount of bulk, despite often being of poor quality.

The fibular free flap, first utilized by Hidalgo (20) in 1989, has become the workhorse of mandible reconstruction. It can be utilized to reconstruct a bony defect as long as 30 cm in length, although the bone does not recreate the alveolar height of a native den-

tate mandible, and the flap is limited in the amount of soft tissue that can be recruited.

The various options of managing a TMJ after hemimandibulectomy, instead, are reconstructions using alloplastic TMJ prosthesis (21), autogenous bone, cartilage, and condylar grafts or vascularized free flaps (22). Alloplastic materials, such as a Christensen implant which is composed of a metal fossa and a metal condyle with an articulating dome of polymethylmethacrylate, would maintain a functional mandibular ramus height, avoid malocclusion, and prevent hypomobility (23). Some risks and potential complications have also been described, such as fracture, displacement, loss of stability, and dystrophic bone formation (24).

The fibula free flap and the iliac crest provide the best functional and aesthetic results which exceed the unpredictable resorption of free bone grafts, especially the osteochondral rib grafts.

The aforementioned functional devices, such as the mandibular guide flange or palatal guide ramps, are

useful for improving masticatory efficiency in partially edentulous patients but they can't be applied in edentulous subjects due to the absence of anchorage pillars. The mandibular guide flange device for hemi-

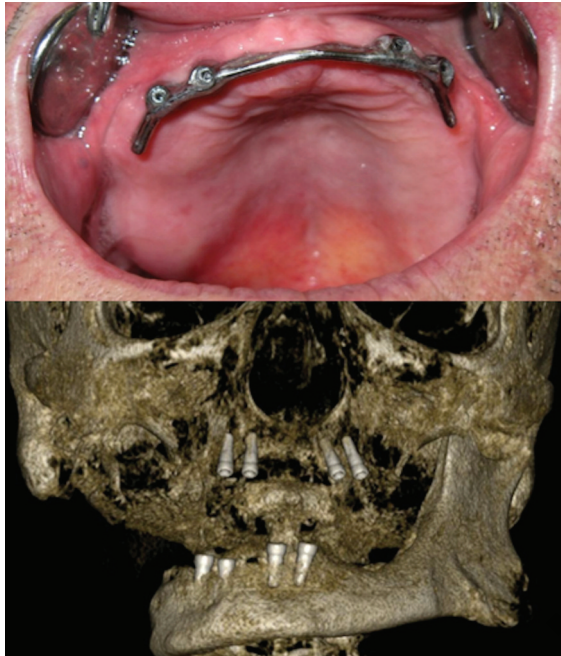


Figure 8. Clinical and radiographic situation after implant insertion in the intercanine area.

mandibulectomized patients presenting good natural teeth on the residual mandible fits generally over those teeth (base-plate) and has a guide plane (flange splint) extending into the maxillary buccal vestibule that rides on the buccal surfaces of several of the maxillary teeth; this is the mechanical system preventing the mandible from turning towards the resected side.

The second technique consists of the fabrication of a conventional denture with a ramp provided on the maxillary side using acrylic resin in antagonism with respect to the resected side and being a few mm higher than the occlusal plane, which serves as a training device for returning the mandible to a functional position.

Where sufficient numbers of abutment teeth are not present, deviation is massive, and implant prosthetic rehabilitation is not achievable, the literature advocates fabricating a twin occlusion. This is a conventional maxillary removable partial prosthesis with two rows of teeth (twinned occlusion) in which the palatal row intercuspidates with the remaining mandibular teeth, and the buccal one supports the cheeks (4).

Alternatively, rehabilitation has been obtained applying the Neutral Zone technique (25), which is a method that acts on the horizontal and vertical forces generated from the tongue and the lips which tend to dislocate the denture. The main limit of these rehabilitations is that they are not always feasible; to create a balanced denture, a minimum bone-mucous support is always required that should hold the denture at its base..

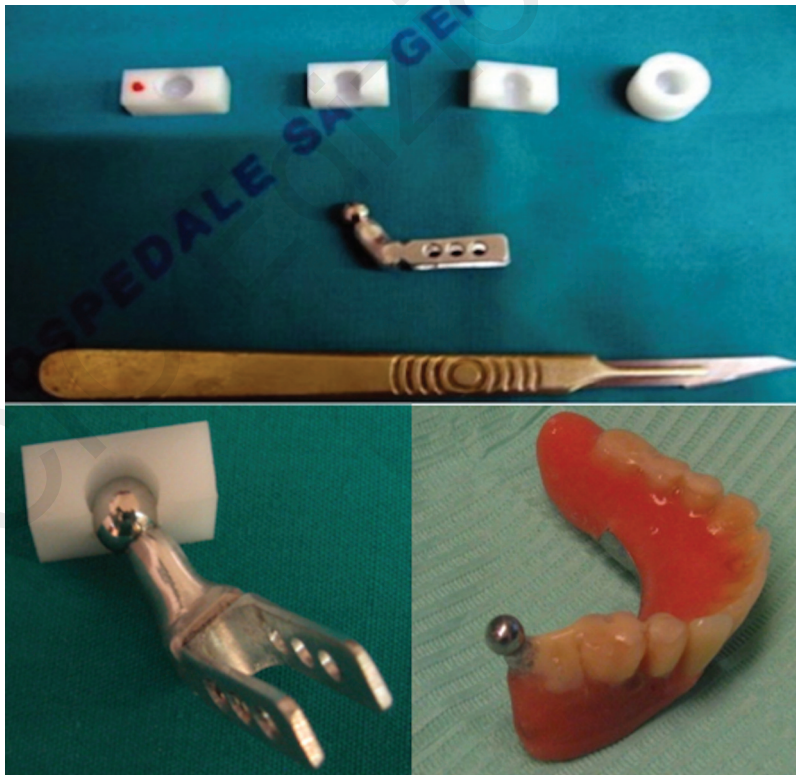


Figure 9. Teflon acetabulum and titanium condyle.

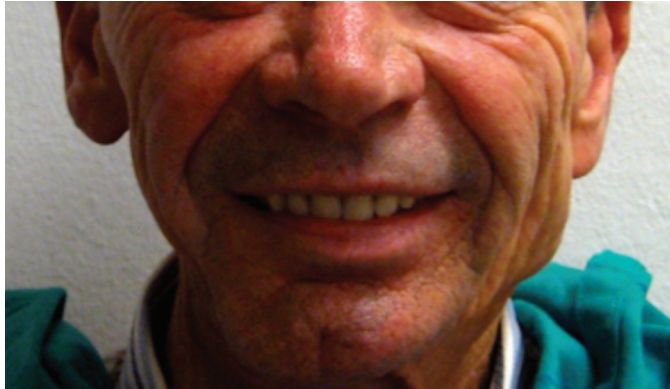

Figure 10. Final clinical situation.

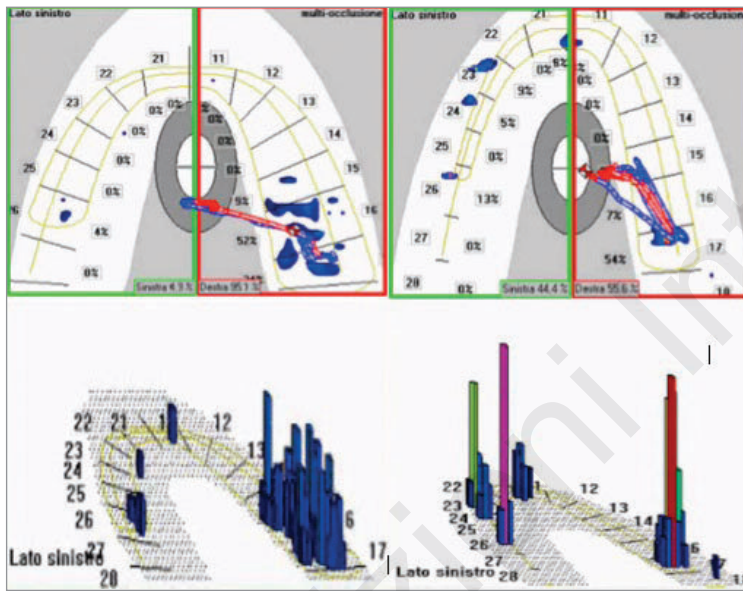


Figure 11. Comparison between T-Scan III 2D and 3D graphs of the first and second prosthetic rehabilitation.

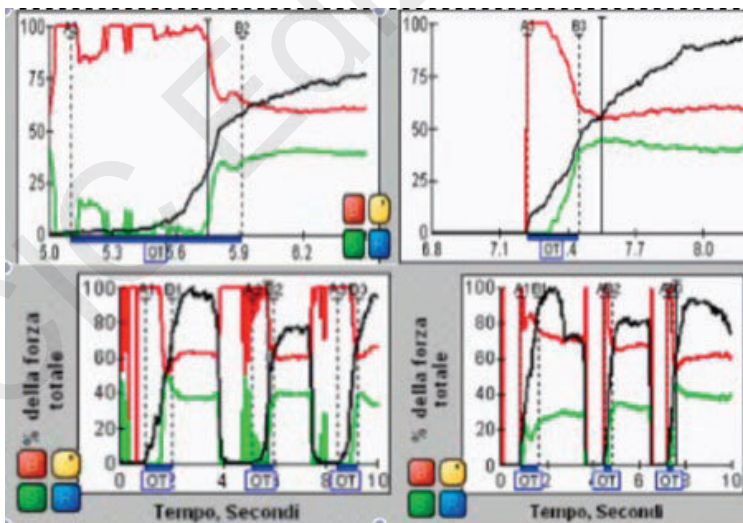


Figure 12. Comparison between T-Scan III force/time graphics of the first and second prosthetic rehabilitation.

The realization of implant-supported prostheses, such as those provided in this case, seems to be the best performing rehabilitative solution by improving both

function and aesthetics. The available evidence from the literature shows that implant-retained overdentures may significantly reduce problems related to

stability and retention of the denture and decrease pressure on the underlying soft tissues (26).

The prosthetic balance guaranteed by endosseous implants greatly affects the biomechanics of mastication leading to a reduction of eccentric interferences, a stabilization of centric occlusion, and a lowering of intensity contraction by masticatory muscles.

This difference is well represented by two and three-dimensional plans obtained from the application of the T-Scan III device.

The undeniable advantage of this computerized registration, compared to the traditional detection achieved with the use of articulating papers, is to allow for evaluating the intensity of the contacts and especially their temporal sequence both in static (maximum intercuspation or centric relation) and dynamic state (lateral and protrusive) (16).

The comparison between the 2D contour graphs with the margins of the contact areas rounded by software shows how the loads distribution was 96.2% and 4.8% for the first rehabilitation and 44.4% and 55.6% for the second rehabilitation respectively for the left and right sides.

The data obtained suggest the presence of a clear occlusal overload towards the resected side with the first prosthesis and its significant decrease with the second rehabilitation. Two-D graphs also show the center of forces (COF) or occlusion center of gravity, which is the sum of the moments of anterior-posterior and medial-lateral occlusal force to which the arch is subjected. With the first rehabilitation, COF, symbolized by a white and red square, is strongly shifted to the right side, while with the second rehabilitation, it falls within the central ellipse which is the area in which 68% of subjects considered "normal" during centric occlusion should be placed statistically.

Three-D histograms highlight the difference between occlusal loads for both right and left fields and for each tooth more than the others (16). The color distribution indicates the different intensity of occlusal loads: red suggests a greater load, while blue a smaller load.

The first graphic obtained was homogenous in terms of load intensity but not in terms of load distribution; all loads were concentrated in the right posterior region.

However, the second 3D histogram shows a more homogeneous distribution of forces with intensity peaks also well distributed.

Force/time graphs, which show as a percentage the variation of the force with respect to time in both static and dynamic states, highlighted an imbalance of 80% and 20% between the left and right side for the first and rehabilitation of 60% and 45% for the second one. Ideally, the red and green line, corresponding to the left and right sectors, should be overlapped; otherwise the resulting imbalance may appear more or less severe.

The best masticatory performance is attributable not only to the secondary stabilization by means of osseointegrated implants in the upper dentures, but also to the new titanium condyle applied to the lower denture and to the corresponding teflon acetabulum with which it is articulated.

Finally, it is important to emphasize that the surgery, as well as the realization of the prostheses, were conducted through a careful analysis of digital and stereolithographic models obtained from CT scans of the facial massif.

This fact shows how the surgical-prosthetic rehabilitation of complex cases like the one described can't overlook a meticulous preoperative study.

Conclusions

The rehabilitative solution proposed was effective in resolving the lateral deviation, relieving masticatory and speech discomfort, as well as restoring an aesthetically acceptable appearance in a hemimandibulectomized and not reconstructed patient.

Both the prosthetic stabilization by osseointegrated implants and the provision of an alloplastic joint model designed to re-establish an acceptable facial contour and an adequate freedom of mandibular excursion contributed to the achievement of the result.

The changes of the prosthetic materials used have shown how a resin joint prosthesis was more susceptible to wear than the titanium-teflon connection, which showed greater resistance to abrasion leading to the maintenance of a correct vertical dimension.

Finally, a surgical and prosthetic project conducted with the aid of data obtained from the T-scan III analysis and of finite element mathematical models has resulted in an effective method in order to create restorations increasingly similar to the stomatognathic apparatus from an anatomo-functional point of view.

References

1. Coelho Goiato M, Barbosa Ribeiro A, Von Dreifus Marinho ML. Surgical and prosthetic rehabilitation of patients with hemimandibular defect. *J Craniofacial Surg.* 2009;20:2163-2167.
2. Curtis DA, Plesh O, Miller AJ, Curtis TA, Sharma A. A comparison of masticatory function in patients with or without reconstruction of the mandible. *Head Neck.* 1997;19:287-296.
3. Kadota C, Sumita YI, Wang Y, Otomaru T, Mukohyama H. Comparison of food mixing ability among mandibulectomy patients. *Journal of Oral Rehabilitation.* 2008;35:408-414.
4. Agarwal S, Praveen G, Agarwal SK, Sharma S. Twin occlusion: a solution to rehabilitate hemimandibulectomy patient - a case report. *J Indian Prosthodont Soc.* 2011;11:254-257.
5. Fonsica RJ, Davis WH. Reconstruction preprosthetic oral and maxillofacial surgery, 2nd edn. WB Saunders Company, Philadelphia. 1986;1063-1067.
6. Shpitzer T, Neligan PC, Gullane PJ, Freeman JE, Boyd BJ, Gur E. Oromandibular reconstruction with the fibular free flap: analysis of 50 consecutive flaps. *Archives of Otolaryngology Head & Neck Surgery.* 1997;123:939-944.
7. Cuesta Gil M, Bucci T, Duarte Ruiz B, Navarro Villa C, Marenzi G, Sammartino G. Implant Mandibular rehabilitation postoncologic segmental resection: a clinical report. *Implant Dent.* 2012;21:104-107.
8. Wong TL, Wat PY, Pow EHN, McMillan AS. Rehabilitation of a mandibulectomy/onlay graft-reconstructed mandible us-

- ing a milled bar and a tooth- and implant supported removable dental prosthesis: a clinical report. *Prosthet Dent.* 2010;104:1-5.
9. Bak M, Jacobson AS, Buchbinder D, Urken ML. Contemporary reconstruction of the mandible. *Oral Oncology.* 2010;46:71-76.
 10. Disa JJ, Cordeiro PG. Mandible reconstruction with microvascular surgery. *Semin Surg Oncol.* 2000;19:226-34.
 11. Sahin N, Hekimoglu C, Aslan Y. The fabrication of cast metal guidance flange prostheses for a patient with segmental mandibulectomy: A clinical report. *J Prosthet Dent.* 2005;93:217-20.
 12. Atreja G. Prosthetic rehabilitation of partially resected edentulous mandible. *Int J of Clinical Case and Investigations.* 2011;3(2):10-14.
 13. Singh SP, Jolly R, Garg R. Prosthetic management following mandibular resection- a clinical report. *Int J of Clinical Dental Science* 2011;2(4):90-3.
 14. Tadi DP, Sandeep C, Babu PJK, Mohan TK. Treatment of unilateral bifid condyle resection using a maxillary guidance ramp: a clinical report. *J of Dr. NTR University of Health Sciences.* 2012;1(2):134-136.
 15. Kori SS. Prosthodontic rehabilitation of a complete edentulous hemimandibulectomized patient. *Int J of Prosthet Dent.* 2011;2(2):16-18.
 16. Baldini A, Berardi A, Nanussi A. Importanza clinica della valutazione computerizzata dell'occlusione. *Dental Cadmos.* 2009;77:47-59.
 17. Walton B, Resto V, Quinn FB, Quinn MS. Mandibular reconstruction: special consideration in TMJ and condyle reconstruction. Grand Rounds presentation, university of Texas Medical Branch. Dept of Otolaryngology. 2010.
 18. Sanders R, Mayou BJ. A new vascularized bone graft transferred by microvascular anastomosis as a free flap. *Br J Surg.* 1979;66:787-8.
 19. Swartz WM, Banis JC, Newton ED, Ramasastry SS, Jones NF, Acland R. The osteocutaneous scapular flap for mandibular and maxillary reconstruction. *Plast Reconstr Surg.* 1986;84:71-9.
 20. Hidalgo DA, Pusic AL. Free-flap mandibular reconstruction: a 10-year follow-up study. *Plast Reconstr Surg.* 2002;110:438-449.
 21. Sidebottom AJ. UK TMJ replacement surgeons, British association of oral and maxillofacial surgeons. Guidelines for the replacement of temporomandibular joints in United Kingdom. *Br J Oral Maxillofac Surg.* 2008;46:146-7.
 22. Tang W, Long J, Feng F, Guo L, Gao C. Condyle replacement after tumor resection: comparison of individual prefabricated titanium implants and costochondral grafts. *Oral Surg Oral Med Oral Pathol Oral Radiol Endod.* 2009;108:147-152.
 23. Guarda-Nardini L, Manfredini D, Ferronato G. Temporomandibular joint total replacement prosthesis: current knowledge and considerations for the future. *Int J Oral Maxillofac Surg.* 2008;37:103-110.
 24. Mercuri LG, Edibam NR, Giobbie-Hurder A. Fourteen-year follow-up of a patient-fitted total temporomandibular joint reconstruction system. *J Oral Maxillofac Surg.* 2007;65:1140-8.
 25. Carini F, Gatti G, Saggese V, Monai D, Porcaro G. Implant-supported denture rehabilitation on a hemimandibulectomized patient: a case report. *Ann Stomatol.* 2012;3:26-31.
 26. Simunovic-Soskic M, Juretic M, Kovac Z, Cerovic R, Uhac I. Implant prosthetic rehabilitation of the patients with mandibular resection following oral malignoma surgery. *Coll Antropol.* 2012;1:301-305.