

RADIOLOGICAL EVALUATION OF THE CRESCO SYSTEM IN COMBINATION WITH OSSEOSPEED IMPLANTS: A PRELIMINARY 3-YEAR REPORT

N. BALDINI, M. DE SANCTIS, M.C. CAGIDIACO, P. BALLERI, F. VIGNOLETTI, C. GORACCI, M. FERRARI

Tuscan School of Dental Medicine, University of Firenze and Siena, Siena, Italy

SUMMARY

Aim. In this preliminary study, the 3-year radiological outcomes of Osseospeed implant-supported fixed complete or partial prostheses made with two different laboratory protocols were compared.

Methods. A convenience sample of 34 patients, who were either partially or completely edentulous in either jaw, were randomly assigned to two groups, of 17 patients each, using either a traditional laboratory protocol (control group) or the Cresco one (test group). The study's objective was an assessment of marginal bone loss around implants, measured on intraoral radiographs at 3-year follow-up.

Results. None of the implants inserted was lost during the study and radiological measurements of marginal bone level changes revealed that the mean marginal bone loss was respectively $0,73\pm 0,33\text{mm}$ for test group and $0,88\pm 1,13\text{mm}$ for control group. The differences between test and control groups were not statistically significant.

Conclusion. This preliminary study did not demonstrate statistically significant differences in marginal bone loss around implant-prostheses prepared with the two different laboratory protocols, over the 3-year observational period.

Key words: Cresco system, implant-supported prostheses, 3-year preliminary report, marginal bone loss.

Introduction

Numerous studies endorse high oral implant survival rates in both partially and completely edentulous patients after 5 years of function, while accompanied by infrequently recorded evidence of occurrence of biomechanical complications (1-5). Some reports also suggest the incidence of mechanical complications implant-supported prostheses may be higher for implant-supported than for teeth-supported prostheses (6, 7).

It is also speculated that a passive fit of prosthetic supra-structures reduces the risk of long term mechanical and biological complications (8), since the induced osseointegrated inter-

face lacks resiliency and is not adversely challenged by a mechanical misfit. The latter may be generated by mechanical distortion that occurs during the cooling phase of the casting procedure as well as a result of shortcomings in laboratory protocol. It appears that ensuring a completely passive implant-supported prosthesis may not be readily achieved, and diverse laboratory protocols, including new computer-reliant technologies have been described to address this technical challenge (9-15). The Cresco system approach relies on a laser-welding procedure between the framework and special "bridge supports" screw-connected to the implant analogues that were previously cut by a computerized milling machine (16-18).

The aim of this preliminary study was to compare radiographically measured marginal bone levels at the end of a 3-year observational follow-up period, of a selected group of patients whose partial and complete implant-supported prosthetic frameworks were made using two different laboratory protocols.

inadequate oral hygiene, presence of untreated periodontitis. In addition, further exclusion criteria were considered during the surgical intervention: lack of primary stability of the implant, dehiscence of the buccal or palatal surfaces of the implant that required a local augmentation procedure.

Materials and methods

A convenience sample of 34 patients (17 males and 17 females) with a mean age 59,6 years (range 38-75) was selected from the patient population group seeking oral implant therapy at the University of Siena. The following inclusion and exclusion criteria were applied.

Inclusion criteria: morphologically suitable edentulous host bone sites (adequate width and height dimension that comprised a minimum equivalent of two adjacent missing teeth in either arch in partially edentulous patients), agreement to participate to regular maintenance visits and agreement to participate in a long term study.

Exclusion criteria: systemic disease presence, history of irradiation therapy, osseous lesions, cigarette smoking (a maximum number of 10 cigarettes for a day was accepted for the study),

Randomization procedure

The patients were randomly assigned to 2 groups of 17 patients each (test and control groups) and are described in Table 1 as per treated sites and type of treatment prescribed.

Once the surgical phase of treatment was concluded, the 34 patients were randomly assigned to 2 groups of 17 patients each, for prosthetic treatment - one employing the Cresco laboratory procedure and the other using traditional laboratory protocol (Table 1 includes jaw sites and prostheses types).

Randomization was made after implant reopening utilizing a sequence of closed envelopes: the envelopes were marked with consecutive numbers and contained the indication for the assignment of the patient to one of the two laboratory protocol test groups (Test and Control).

Table 1 - Distribution of patients.

Patient number	Age	Gender	Treatment group	Type of prosthetic rehabilitation	Location	Number of implants
#1	67	F	Test	Full-arch bridge	Maxilla	6
#2	71	M	Test	2 3-unit bridges	Mandible, posterior	5
#3	47	M	Control	Full-arch bridge	Maxilla	6
#4	72	M	Test	Full-arch bridge	Maxilla	6
#5	48	F	Control	4-unit bridge	Maxilla, posterior	3
#6	61	F	Test	Full-arch bridge	Mandible	5
#7	53	F	Control	2 2-unit bridges	Mandible, posterior	4

Continue →

Cont. Table 1

Patient number	Age	Gender	Treatment group	Type of prosthetic rehabilitation	Location	Number of implants
#8	64	F	Test	4-unit bridge	Mandible, posterior	3
#9	44	M	Control	3-unit bridge	Mandible, posterior	2
#10	72	F	Control	5-unit bridge	Mandible,posterior	3
#11	75	F	Control	4-unit bridge	Mandible, posterior	3
#12	66	M	Test	2 3-unit bridges	Maxilla, posterior	5
#13	66	M	Test	4-unit bridge	Mandible, posterior	3
#14	42	F	Control	3-unit bridge	Mandible, posterior	2
#15	54	M	Test	3-unit bridge	Mandible, posterior	2
#16	38	F	Test	3-unit bridge	Maxilla, posterior	2
#17	50	M	Control	3- 3-unit bridges	Maxilla (2) and mandible, posterior	7
#18	61	M	Test	Full-arch bridge	Maxilla	6
#19	57	F	Control	3-unit bridge	Maxilla, postyerior	2
#20	70	M	Control	Full-arch bridge	Mandible	6
#21	66	F	Test	3-unit bridge	Maxilla, posterior	2
#22	61	M	Control	2 3-unit bridges and a 4-unit bridge	Maxilla and mandible(2), posterior	9
#23	72	M	Test	2 3-unit bridges	Mandible, posterior	5
#24	67	M	Test	5-unit bridge	Maxilla, posterior	4
#25	55	F	Control	Full-arch bridge	Mandible	5
#26	51	F	Control	Full-arch bridge	Mandible	5
#27	67	M	Test	4-unit bridge	Mandible, posterior	3
#28	55	F	Control	Full-arch bridge	Mandible	7
#29	45	M	Control	4-unit bridge	Mandible, anterior	2
#30	76	F	Test	Full-arch bridge	Mandible	6
#31	58	M	Test	5-unit bridge	Mandible, posterior	4
#32	69	M	Control	3-unit bridge	Mandible, posterior	2
#33	63	F	Test	Full-arch bridge	Maxilla	6
#34	46	F	Control	3-unit bridge	Mandible, posterior	2

Surgical procedure

All implants were placed according to the traditional two-stage following the manufacturer's surgical indications. The same surgical procedure was performed for both test and control groups. All the surgical procedures were performed by the same surgical team.

On the day of the primary surgery implants were osseously submerged followed by a 4-6 month healing period. All patients rinsed with a chlorhexidine 0.12% solution for 1 minute prior to administration of local anaesthesia, followed by a crestal incision and the raising of a mucoperiosteal flap. Drilling of the prospective implant site was then performed according to the manufacturer's protocol and screw-type rough Osseospeed surface implants (Astra Tech Implant System®, Mölndal, Sweden) were placed. If no contraindications were present, each patient received an analgesic and an antibiotic (Brufen® 600mg, Abbott, USA; Augmentin® 1gr, GlaxoSmithKline, UK) twice a day for 5 days. Patients were instructed to cool the operation site with a cold pack during the first 6 hours after surgery and to rinse with a chlorhexidine 0.12% solution (Curasept® 0,12%, Curaden Healthcare, Saronno, Italy) twice a day for 10 days. Seven to 10 days after surgery, the sutures were removed. Following a 4-6-month healing period, the surgical site was re-accessed under local anaesthesia, a full-thickness flap raised to expose the implant shoulder and the healing abutments were screwed to the implants. The soft tissue flaps were adapted and sutured.

Prosthetic procedure

All of the patients' prosthetic needs were managed with implant supported fixed prostheses following routine 2-stage implant surgery. All the patients received provisional partial or complete removable dentures during the healing phase of the implants.

After making the final impressions on the abutments, casts were made and then, in the test group the framework was made using the Cresco system while in the control group a traditional lost-wax technique was performed to produce a screw-retained bridge. All steps for the test group prostheses were performed according to the described Cresco protocol (16) (Figs. 1-4), and followed by implant connection obtained with preformed, bendable burn-out acrylic tubes that allowed screw retention of the framework directly to the implant (without abutment). After a one-piece wax framework was prepared, the waxed framework was sent to the Cresco Ti milling centre, together with the master cast. The marginal portion of the cast tubes connecting the framework with the implants was then cut and substituted by means of laser welding

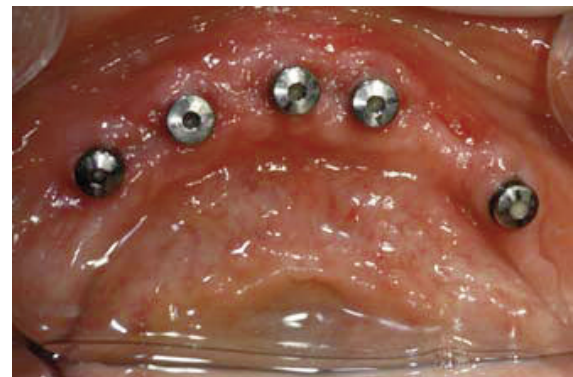

Figure 1
Impression phase.

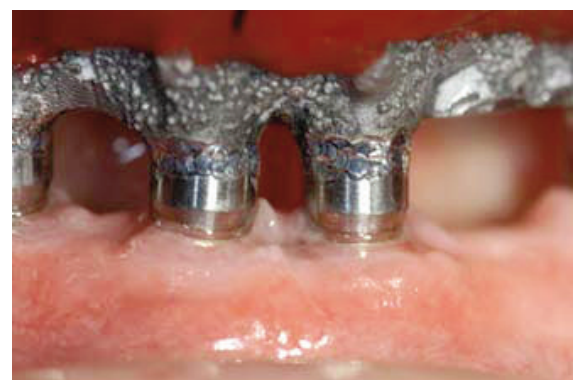

Figure 2
Framework passivated using Cresco system.

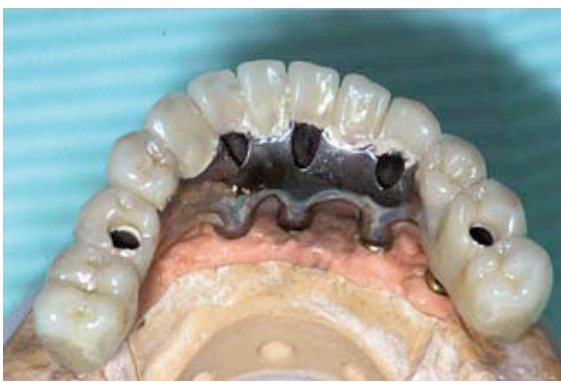

Figure 3
Final restoration.

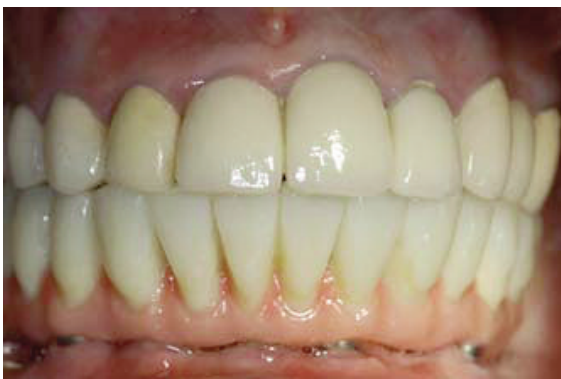

Figure 4
3-year follow-up.

with new preformed titanium cylinders that fit onto the implant replicas. The coupling of the framework to the prefabricated machined cylinders was made with a precise automatic computer driven machine. Patients were recalled for oral hygiene sessions every 3 months after treatment completion.

Radiographic assessment

Standardized peri-apical radiographs were obtained immediately after surgery, at prosthetic connection and after 36 months of follow-up. The standardized X-rays were scanned and digitalized. All radiographs were evaluated by a single examiner, blind to the treatment as de-

scribed by Wennstrom et al. (19, 20) and Bilhan (21, 22). Marginal bone loss was assessed from peri-apical radiographs using software image analysis (Nikon Nis Elements D). The image software was calibrated with the known length of the implant in order to correct any distortion of the radiograph. Marginal bone loss was considered as the primary outcome of interest and measured as the distance between the implant shoulder and the most coronal bone to implant contact at the mesial and distal aspects. The mean value between mesial and distal measurements was considered for each implant.

Implant success was only based on radiological parameters: the absence of a continuous radiolucency around the implant (23), annual vertical bone loss $\leq 2\text{mm}$ in the first year and not $> 0,2\text{mm}$ after the first year of loading (24, 25).

Statistical analysis

The Kolmogorov test was applied to assess for the normal distribution of the subjects and implants. As the bone loss data distribution was not normal, the Mann-Whitney 'U' test was applied to assess the statistical significance of the difference in bone loss between the Cresco group and the control.

Furthermore, a multiple linear regression model was applied to explore the relative contribution of different predictors on bone loss. The predictive variables included type of implant (Cresco implants/screwed implants), dental arch (maxillary/mandibular), and type of prosthetic restoration (partial/full).

In all the analyses the level of significance was set at $\alpha=0.05$.

Results

A total of 143 Astratech implants were inserted: 73 implants in Group 1 (test) and 70 in Group 2 (control). In the test group 3 drop out patients

(patient n°12, 18 and 23, 16 implants) were observed: one due to death and two to loss of follow-up.

The mean marginal bone loss after 3 years was $0,73\pm 0,33\text{mm}$ and $0,88\pm 1,13\text{mm}$ for test and control group, respectively. The differences between test and control groups were not statistically significant (Tab. 2).

The implant survival rate after 3-years was of 100% for both test and control groups whereas the success rate was 100% for test implants and 94.28% for control implants. No statistically significant difference was found between test and control implants ($p=0.1$; Tab. 3).

Focusing on an evaluation of the success of the whole implant-supported prosthesis at 3-year follow up, successful prostheses were found in 78.57% of the test group patients and in 64.70% of control group patients. During the 3-year fol-

low-up a total of 9 complications arose, 3 in Group 1 and 6 in Group 2: these complications were due to either implant or prosthetic reasons, in these cases the implant-supported prostheses were not considered as successful. This difference between the two groups was not statistically significant ($p=0.3$; Tab. 4).

Discussion

This preliminary study measured radiographic marginal bone loss in patients following 3-years of wearing implant-supported fixed partial and complete prostheses made with two types of laboratory protocols: the Cresco system and a traditional one. It presumed that a correlation could be made between different

Table 2 - Marginal bone loss around implants (distance between implant-abutment interface and most coronal bone implant-contact in mm).

Group	N	Median	Interquartile range (25%-75%)	Mean	Standard deviation
Test	57	0.735	0.5-0.96	0.734	0.335
Control	70	0.58	0.4-0.963	0.887	1.131

Table 3 - Implant success.

Implants	Success	3-year marginal bone loss $>2,4\text{mm}$	% Success	Total
Test	57	0	100%	57
Control	66	4	94.28%	70
Total	123	4	96.85%	127

Table 4 - Final restoration success.

Patients	Success	Implant complications	Prosthetic complications	% Success	Total
Test	11	0 (0%)	3 (21.42%)	78.57%	14
Control	11	3 (17.64%)	3 (17.64%)	64.70%	17
Total	22	3 (9.67%)	6 (19.35%)	70.96%	31

framework fabrication techniques and marginal bone behaviour around implants in functional use. The mean recorded marginal bone loss was $0,73\pm 0,33\text{mm}$ and $0,88\pm 1,13\text{mm}$ for test and control group respectively and was similar to that reported for the same implant system used in other reports, albeit in different contexts. Results from the present investigation are consistent with findings from other studies that reported on marginal bone loss around Osseospeed implants: De Bruyn (26) described a mean value for marginal bone loss at 3-year follow up of $0,4\pm 1,5\text{mm}$, Galindo-Moreno (27) reported a mean value of $0,065\pm 1,01\text{mm}$ at 1-year follow up, Bilham (21) reported a mean value of $0,95\pm 0,18\text{mm}$ at 3-year follow-up, Chang (28) found a mean marginal bone loss of $0,45\pm 1,15\text{mm}$ at 5-year follow up.

In the present study, the performances of the implants supporting superstructures made using the Cresco components resulted comparable to those supporting FDPs made by conventional methods using manufacturer's components: this finding is consistent with other retrospective studies on Cresco procedures (29, 30). Nevertheless, a randomized controlled clinical trial on full arch rehabilitations using the Cresco prosthetic system reported marginal mean values of bone loss that were lower than those observed in the present investigation (31). Contrastly, Nordin et al. (32) reported in a 3-year clinical and radiographic examination on the Cresco prosthetic system, mean values slightly higher than the results observed in this study. One possible reason may in part explain this latter observation: it can be related to the fact that several implants (2/3 of the total number) were placed according to the immediate implant placement protocol, whereas in the present investigation only healed alveolar ridges were selected. The correlation between a less passive fit at the abutment-implant interface and marginal bone loss is a very controversial issue. Indeed, *in vitro* studies suggested that biomechanical stress due to incorrect occlusal design (33) or framework misfit (34) of the implant-supported restoration may adversely affect the stability of peri-implant marginal bone, although well-designed human clinical trials are still lack-

ing. Moreover, while some animal studies suggest that peri-implant crestal bone levels around two-piece implants may be associated with the size of the microgap between components (35, 36), clinical human studies failed to confirm these findings (37). Indeed, based on low number of observations in a retrospective study it has been accepted that a certain degree of non-passive fit between the components does not influence bone loss (38). Results from the present investigation seem to support this hypothesis. Furthermore it has to be considered the type of implant: in this investigation Osseospeed AstraTech implants with a conical internal connection were used. According to analyses made by Jansen et al. (39), the conical interface between the abutment and the current implant appeared to vary between 1-2 μm . This suggests that marginal bone behaviour in a long-term time dependent context remains a complex subject for study and that it should include far more determinants for consideration than the employment of different laboratory protocols.

An analysis of the radiographic outcomes of this study, the frequency distribution of marginal bone loss at test and control implants demonstrated that 4 of 127 implants in the control group experienced a severe marginal bone loss $>3\text{mm}$. In detail 2 implants in two patients demonstrated a mean marginal bone loss of 3,02mm and 3,20m, whereas 2 implants in 1 patient demonstrated 6,78mm and 7,05mm. All the four implants belonged to the control group (Fig. 5) and the observed bone loss was in contrast with generally accepted definitions of success criteria (19).

Few prosthetic complications were reported during the 3-year follow-up: in the test group, two patients showed a crown fracture and one patient presented an abutment screw fracture while in control group a crown fracture and two abutment screw fractures were documented.

Two main limitations affect this study and have to be considered in the final evaluation of its outcomes: the first main limitation is the statistical sample: the number of the patients to be involved in the protocol was not determined at the beginning of the study, a convenience sample of con-

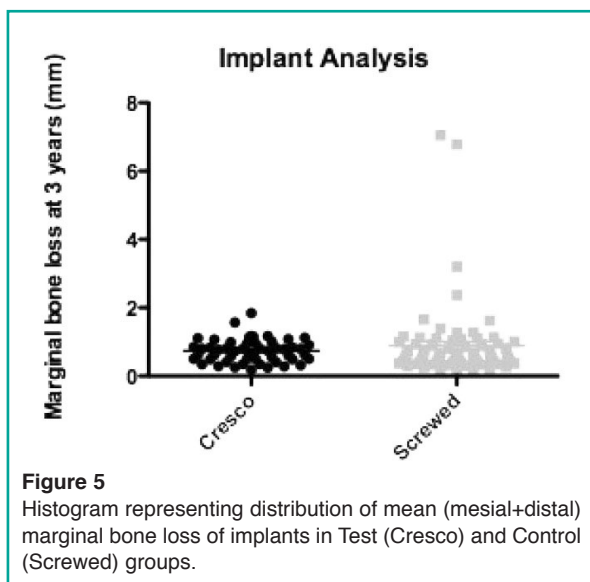


Figure 5
Histogram representing distribution of mean (mesial+distal) marginal bone loss of implants in Test (Cresco) and Control (Screwed) groups.

secutive treatments was selected. The second main limitation is the lack of clinical measurements of the implants. Indeed only a radiographic assessment of marginal bone resorption was performed and thus no definite conclusions regarding the health of peri-implant tissues may be drawn.

Conclusions

Within the limitations of the present study, although a slight tendency towards less marginal bone loss and less prosthetic complications was observed in the test group, this clinical trial failed to demonstrate statistically significant differences in marginal bone loss around implant-supported prostheses performed using Cresco prosthetic system or traditional lab procedures, after 3 years from loading.

References

1. Zurdo J, Romão C, Wennström JL. Survival and complication rates of implant-supported fixed partial dentures with cantilevers: a systematic review. *Clin Oral Implants Res.* 2009 Sep;20 Suppl 4:59-66. Review.
2. Lang NP, Pjetursson BE, Tan K, Bragger U, Egger M,

- Zwahlen M. A systematic review of the survival and complication rates of fixed partial dentures (FPDs) after an observation period of at least 5 years. II. Combined tooth – implant-supported FPDs. *Clinical Oral Implants Research.* 2004;15:643-653.
3. Aglietta M, Siciliano VI, Zwahlen M, Bragger U, Pjetursson BE, Lang NP, Salvi GE. A systematic review of the survival and complication rates of implant supported fixed dental prostheses with cantilever extensions after an observation period of at least 5 years. *Clin Oral Implants Res.* 2009 May;20(5):441-51.
4. Del Fabbro M, Testori T, Francetti L, Taschieri S, Weinstein R. Systematic review of survival rates for immediately loaded dental implants. *Int J Periodontics Restorative Dent.* 2006 Jun;26(3):249-63.
5. Pjetursson BE, Tan K, Lang NP, Bragger U, Egger M, Zwahlen M. A systematic review of the survival and complication rates of fixed partial dentures (FDPs) after an observation period of at least 5 years – I. implant supported FPDs. *Clinical Oral Implants Research.* 2004;15:625- 642.
6. Pjetursson BE, Bragger U, Lang, NP, Zwahlen M. Comparison of survival and complication rates of tooth supported fixed partial dentures and implant supported fixed partial dentures and single crowns. *Clinical Oral Implants Research.* 2007;8 (Suppl. 3):97-113.
7. Pjetursson BE, Lang NP. Prosthetic treatment planning on the basis of scientific evidence. *Journal of Oral Rehabilitation.* 2008;35 (Suppl. 1):72-79.
8. Sahin S, Cehreli MC. The significance of passive framework fit in implant prosthodontics: current status. *Implant Dentistry.* 2001;10: 85-92.
9. White GE. Osseointegrated dental technology. Quintessence Publishing Co Ltd London; 1993. p. 61-94.
10. Monteiro DR, Goiato MC, Gennari Filho H, Pesqueira AA. Passivity in implant-supported prosthesis. *J Craniofac Surg.* 2010 Nov;21(6):2026-9.
11. Di Felice R, Rappelli G, Camaioni E, Cattani M, Meyer J-M, Belser UC. Cementable implant crowns composed of cast superstructure frameworks luted to electroformed primary copings: an in vitro retention study. *Clin Oral Impl Res.* 2007;18:108-113.
12. Jemt T, Bäck T, Petersson A. Precision of CNC-milled titanium frameworks for implant treatment in the edentulous jaw. *Int J Prosthodont.* 1999 May-Jun;12(3):209-15.
13. Wee AG, Aquilino SA, Schneider RL. Strategies to achieve fit in implant prosthodontics: a review of the literature. *Int J Prosthodont.* 1999 Mar-Apr;12(2):167-78.
14. Abduo J, Lyons K, Bennani V, Waddell N, Swain M. Fit of screw-retained fixed implant frameworks fabricated by different methods: a systematic review. *Int J Prosthodont.* 2011 May-Jun;24(3):207-20.
15. Harder S, Kern M. Survival and complications of computer-aided designing and computer-aided manufacturing vs. conventionally fabricated implant- supported reconstructions: a systematic review. *Clin Oral Impl Res.* 2009;20 (Suppl. 4):48-54.

16. Helldén LB, Dérand T. Description and evaluation of a simplified method to achieve passive fit between cast titanium frameworks and implants. *Int J Oral Maxillofac Implants*. 1998 Mar-Apr;13(2):190-6.
17. Helldén L, Ericson G, Elliot A, Fornell J, Holmgren K, Nilner K, Olsson CO. A prospective 5-year multicenter study of the Cresco implantology concept. *Int J Prosthodont*. 2003 Sep-Oct;16(5):554-62.
18. Helldén LB, Ericson G, Olsson CO. The Cresco Bridge and implant concept: presentation of a technology for fabrication of abutment-free, passively fitting superstructures. *Int J Periodontics Restorative Dent*. 2005 Feb;25(1):89-94.
19. Wennström J, Zurdo J, Karlsson S, Ekstubby A, Gröndahl K, Lindhe J. Bone level change at implant-supported fixed partial dentures with and without cantilever extension after 5 years in function. *J Clin Periodontol*. 2004;31:1077-1083.
20. Wennström JL, Ekstubby A, Gröndahl K, Karlsson S, Lindhe J. Implant-supported single-tooth restorations: a 5-year prospective study. *J Clin Periodontol*. 2005;32:567-574.
21. Bilhan H, Mumcu E, Arat S. The role of timing of loading on later marginal bone loss around dental implants: a retrospective clinical study. *Journal of Oral Implantology*. 2010;(5):363-376.
22. Mumcu E, Bilhan H, Cekici A. Marginal bone loss around implants supporting fixed restorations. *Journal of Oral Implantology*. 2011; (5): 549-558.
23. Buser D, Weber HP, Lang NP. Tissue integration of non-submerged implants. 1-year results of a prospective study with 100 ITI hollow-cylinder and hollow-screw implants. *Clinical Oral Implants Research*. 1990;1:33-40.
24. Albrektsson T, Zarb G, Worthington P, Eriksson AR. The long-term efficacy of currently used dental implants: a review and proposed criteria of success. *International Journal of Oral and Maxillofacial Implants*. 1986;(1): 11-25.
25. Albrektsson T, Isidor F. Consensus report of session IV. In: Lang, N. P. & Karring, T. (eds). *Proceedings of the 1st European Workshop on Periodontology, 1994* pp. 365-369. London: Quintessence Publishing Co. Ltd.
26. De Bruyn H, Raes F, Cooper LF, Reside G, Garriga JS, Tarrida LG, Wiltfang J, Kern M. Three-years clinical outcome of immediate provisionalization of single OsseospeedTM implants in extraction sockets and healed ridges. *Clin Oral Implants Res*. 2012; Apr 2.
27. Galindo-Moreno P, Nilsson P, King P, Becktor J, Speroni S, Schramm A, Maiorana C. Clinical and radiographic evaluation of early loaded narrow diameter implants - 1-year follow-up. *Clin Oral Implants Res*. 2012 May;23(5):609-16.
28. Chang M, Wennstrom JL. Bone alterations at implant-supported FDPs in relation to inter-unit distances: a 5-year radiographic study. *Clin Oral Impl Res*. 2010; 21:735-740.
29. Hjalmarsson L, Smedberg, JI. A 3-year retrospective study of Cresco frameworks: preload and complications. *Clinical Implant Dentistry & Related Research*. 2005;7: 189-199.
30. Hedkvist L, Mattsson T, Hellden LB. Clinical performance of a method for the fabrication of implant-supported precisely fitting titanium frameworks: a retrospective 5- to 8-year clinical follow-up study. *Clinical Implant Dentistry & Related Research*. 2004;(6):174-180.
31. Jokstad A, Ellner S, Gussgard A. Comparison of two early loading protocols in full arch reconstructions in the edentulous maxilla using the Cresco prosthetic system: a three-arm parallel group randomized-controlled trial. *Clin Oral Impl Res*. 2011;22:455-463.
32. Nordin T, Graf J, Frykholm A, Helldén L. Early functional loading of sand-blasted and acid-etched (SLA) Straumann implants following immediate placement in maxillary extraction sockets. *Clinical and radiographic result*. *Clinical Oral Implants Research*. 2007;18:441-451.
33. Rungsiyakull C, Rungsiyakull P, Li Q, Li W, Swain M. Effects of occlusal inclination and loading on mandibular bone remodeling: a finite element study. *The International Journal of Oral and Maxillofacial Implants*. 2011;26:527-537.
34. Assuncao WG, Gomes EA, Rocha EP, Delben JA. Three-dimensional finite element analysis of vertical and angular misfit in implant-supported fixed prostheses. *The International Journal of Oral and Maxillofacial Implants*. 2011;26: 788-796.
35. Hermann JS, Cochran DL, Nummikoski PV, Buser D. Crestal bone changes around titanium implants. A radiographic evaluation of unloaded nonsubmerged and submerged implants in the canine mandible. *Journal of Periodontology*. 1997;68:1117-1130.
36. Brogginini N, McManus LM, Hermann JS, Medina R, Schenk RK, Buser D, Cochran DL. Peri-implant inflammation defined by the implant abutment interface. *Journal of Dental Research*. 2006;85:473-478.
37. Heijdenrijk K, Raghoobar GM, Meijer HJ, Stegenga B, van der Reijden WA. Feasibility and influence of the microgap of two implants placed in a non-submerged procedure: a five-year follow-up clinical trial. *Journal of Periodontology*. 2006;77:1051-1060.
38. Jemt T, Book K. Prosthesis misfit and marginal bone loss in edentulous implant patients. *The International Journal of Oral & Maxillofacial Implants*. 1996;11:620-5.
39. Jansen VK, Conrads G, Richter EJ. Microbial leakage and marginal fit of the implant-abutment interface. *Int J Oral Maxillofac Implants*. 1997; Jul-Aug;12(4):527-40.

Correspondence to:

Dr. Nicola Baldini
Dipartimento di Scienze Odontostomatologiche
Università degli Studi di Siena, Policlinico Le Scotte
Viale Bracci, Siena, Italy
E-mail: baldini.nicola@gmail.com