

A NOVEL TECHNIQUE TO CLOSE LARGE PERFORATION OF SINUS MEMBRANE

M. CLEMENTINI, L. OTTRIA, C. PANDOLFI, P. BOLLERO

*Department of Clinical Science and Translational Medicine, University of Rome "Tor Vergata", Rome, Italy
U.O.C. of Odontostomatologic Clinic - Director and Chief: Prof. Alberto Barlattani*

SUMMARY

Maxillary sinus floor elevation is generally accepted as a regenerative procedure to facilitate dental implants placement in the posterior atrophic maxilla. Although the sinus lift procedure is relatively safe, some potential problems could occur. The most prevalent intraoperative complication is perforation of sinus membrane, which can lead to graft infection and early failure.

The Aim of this work. Is to present a new technique to repair large perforation of sinus membrane.

This case report. Is focused on a 10 mm perforation of sinus membrane occurred during preparation of the sinus window. The obliteration of the perforation was obtained by means of suturing sinus membrane with a resorbable material to the bone directly lateral to the osteotomy site. Sinus augmentation procedure could complete and the insertion of a graft was permitted.

Key words: sinus augmentation; sinus membrane; membrane perforation; complication management.

Introduction

Maxillary sinus floor elevation is a well-documented technique and it is generally accepted as a regenerative procedure to facilitate dental implants placement in the posterior atrophic maxilla (1, 2). Freeing the membrane during sinus surgery is a delicate procedure, and perforation of membrane could occur very frequently (from 11% to 56%) (3). A tear of Schneiderian membrane results in direct communication between the graft material and the contaminated sinus cavity; this event can cause infection and chronic sinusitis, which can lead to loss of graft volume (4). Perforation of the Schneiderian membrane most often occurs when the lateral wall is being fractured, but it can also happen when the membrane is being elevated off the inferior and anterior bony aspect of the sinus or it can occur due to irregularities of the sinus floor (5-8). It has also been suggested that previous sinus surgery is a risk factor to perforations of the maxillary sinus, which tend to be large in those cases.

When the perforation is small and located in an area where the elevated mucosa is folded together, it will be healed by itself (9, 10). If the perforation is large and located in an unfavorable area, the perforation needs to be closed in order to prevent loss of the bone graft (9, 10). In such cases sinus floor is usually managed by use of a collagenous membrane, fibrin adhesive, use of a block graft or, at least, one has to abandon the procedure (9, 10).

If adequately repaired, perforations have no effect on the ultimate survival of the implants placed in the affected sinuses (5).

The main purpose of this report was to present a novel technique to repair a large perforation of sinus membrane by means of absorbable suture, when a collagen membrane is not available.

Case Report

A 40-year-old woman was referred to our department for an implant-supported prosthesis in a par-

tially edentulous maxilla. Radiographic exams revealed not only an insufficient bony support but also a residual root apex in the region where implant should be programmed (Figs. 1, 2).

It was decided to remove the root before starting the regenerative procedure. During the extraction, a perforation of sinus membrane occurred (Fig. 3). It was located in the mid superior aspect of the osteotomy, extending mesiodistally for two-thirds of the dimension of the total osteotomy site. Because of a collagen membrane wasn't available, the obliteration of the perforation was obtained through suturing sinus membrane with a resorbable material to the bone directly lateral to the osteotomy site (Fig. 4A, B), giving the chance to not abort sinus augmentation procedures and to place the graft material (Fig. 5). Finally detached sutures were positioned (Fig. 6).

Post operative medications were prescribed and after fifteen days sutures were removed.

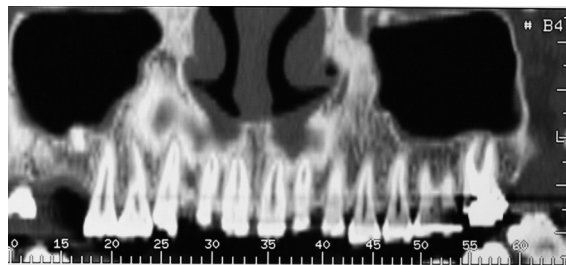


Figure 1
Radiographic exams (coronal images) revealed not only an insufficient bony support but also a residual root apex in the region of the first upper molar where implant should be programmed.

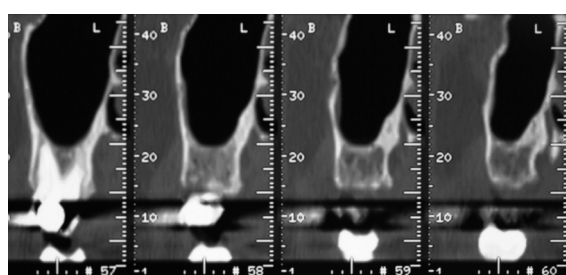


Figure 2
Radiographic exams (parasagittal images) also revealed not only an insufficient bony support and the residual root apex in the palatal side.

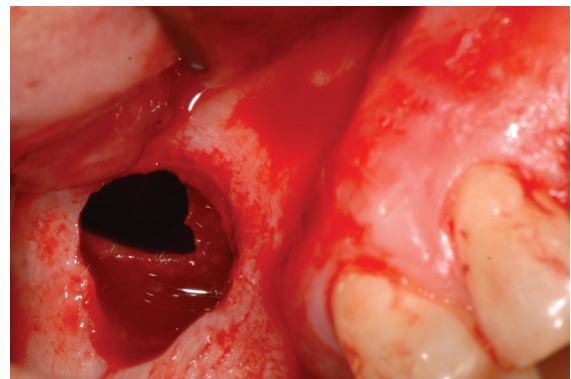


Figure 3
During the extraction, a perforation of sinus membrane occurred.

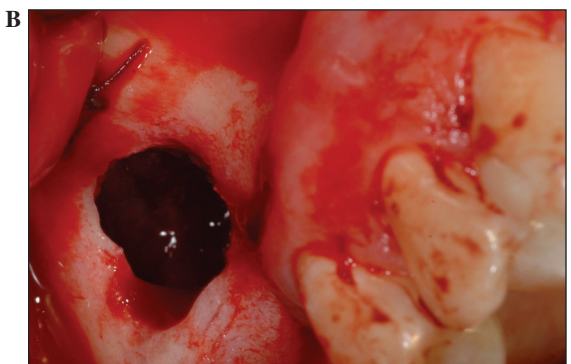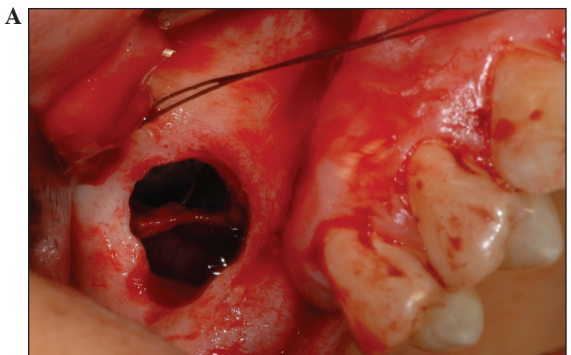


Figure 4
A) The obliteration of the perforation was obtained through suturing sinus membrane with a resorbable material to the bone directly lateral to the osteotomy site. **B)** The obliteration of the perforation was obtained through suturing sinus membrane with a resorbable material to the bone directly lateral to the osteotomy site.

The clinical checks done at 15 days, 1 months, 3 months and 6 months showed a postoperative course without complications. No serious infec-

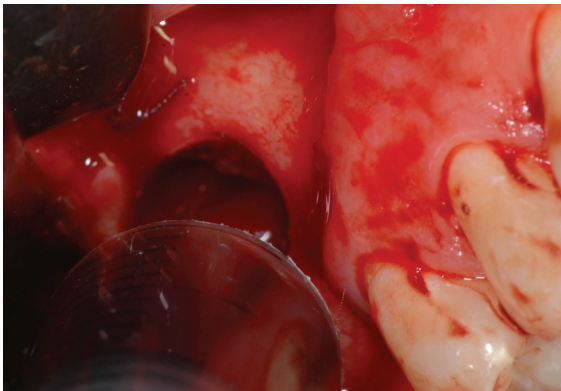


Figure 5
Graft material placement.

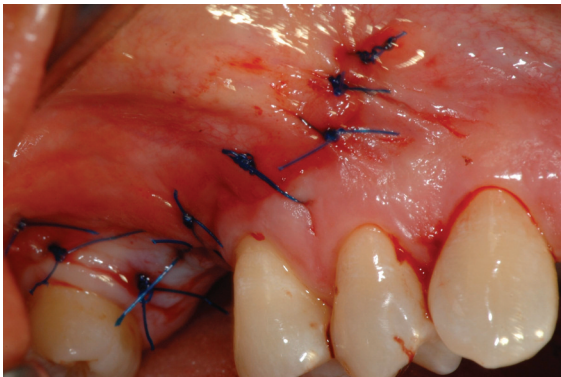


Figure 6
Detached sutures.

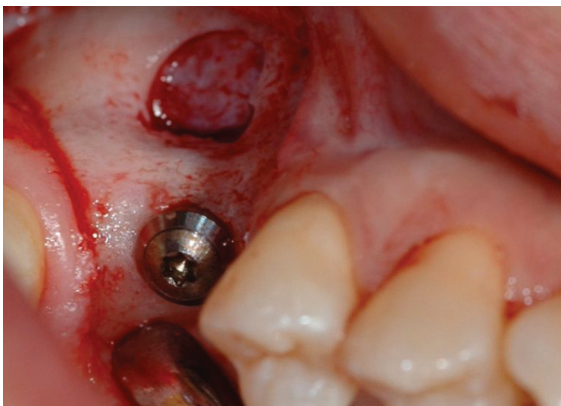

Figure 7
The placement of a osseointegrated implant.

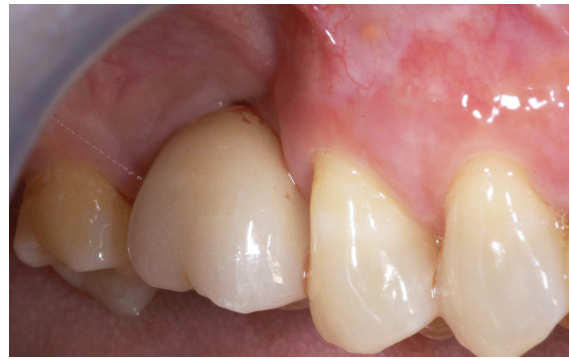

Figure 8
The rehabilitation with a PFM crown.

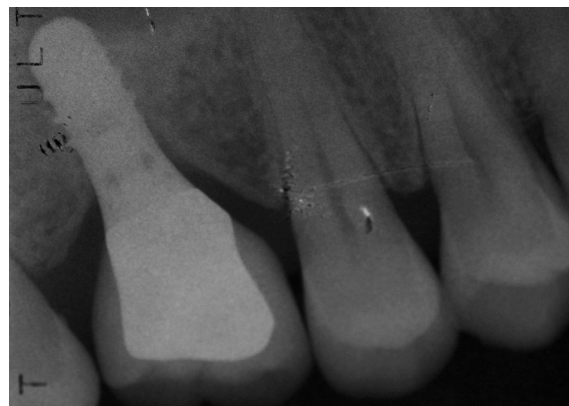

Figure 9
The intraoral radiographic control.

ams after 6 months revealed a good quantity of bone to receive an implant, so an osseointegrated implant was placed (Fig. 7) and the patient was rehabilitated with a PFM crown (Fig. 8). The intraoral radiographic control (Fig. 9).

This technique resulted useful to obtain the closure of a large perforation providing the clinician safe for the placement of the planned regenerative materials and for the following scheduled therapies.

References

1. Boyne Pj, James RA. Grafting of the maxillary sinus floor with autogenous marrow and bone. *J Oral Surg* 1980; 38:613-616.

tions, no signs of sinus membrane inflammation or hypertrophy were detected. Radiographic ex-

2. Tatum OH. Maxillary ad sinus implant reconstruction. Dent Clin North Am 1986; 30:207.
3. Ardekian et al. The clinical significance of sinus membrane perforation during augmentation of the maxillary sinus. J Oral Maxillofac Surg 2006; 64:277-382.
4. Mish CE. The maxillary sinus graft and sinus graft surgery. In: Misch CE. Contemporary Implant Dentistry. Chicago Mosby 1999; 469-495.
5. Shwartz-arad D, Herzberg R, Dolev E. The prevalence of surgical complications of the sinus graft procedure and their impact on implant survival. J Periodontol 2004; 75:511-16.
6. Katranji A. Sinus augmentation complications: etiology and treatment. Implant Dentistry 2008; 17:393-348.
7. Galli SKD, Lebowitz RA, Giacchi RJ, et al. Chronic sinusitis complicating sinus lift surgery. Am J Rhinol 1997; 15:181.
8. Bergh van den JPA, Bruggenkate ten CM, Dish FJM, et al. Anatomical aspects of sinus floor elevation. Clin Oral Implant Res 256, 2000.
9. Valassis JM, Fugazzotto PA. A classification system for sinus membrane perforations during augmentation with option to repair. J Periodontol 1999; 70:692.
10. Fugazzotto PA, Vlassis J. A simplified classification and repair system for sinus membrane perforations. J Periodontol 2003; 74:1534-1541.

Correspondence to:

Marco Clementini

Tel. +39 338 8378866

E-mail: mclementini@me.com