

# Meniscal sutures with outside-in technique: our experience with a less expensive method

Filippo Calderazzi  
 Claudio Violi  
 Alessandro Paraskevopoulos  
 Paolo Schiavi  
 Francesco Ceccarelli

Department of Surgical Sciences, Orthopaedics and Traumatology Unit, Parma University Hospital, Italy

## Corresponding author:

Filippo Calderazzi  
 Department of Surgical Sciences, Orthopaedics and Traumatology Unit,  
 Parma University Hospital  
 Via Gramsci 14, 43100 Parma, Italy  
 E-mail: filippo.calderazzi@tin.it

**KEY WORDS:** *dilator knot, meniscal sutures, mulberry knot, knee, outside-in technique.*

Dear Editor,

since the meniscus is a necessary load-bearing structure that optimizes articular biomechanics giving a lower contact stress, a meniscal resection leads to an alteration of these factors with consequences on knee's biomechanics<sup>1</sup>.

Arthroscopy has been recognized as the gold standard for acute and degenerative meniscal pathologies and several techniques have been developed with the aim to preserve meniscal functions<sup>2</sup>. Today the recognized techniques for meniscal suture are: inside-out, all-inside and outside-in procedures<sup>2</sup>.

The authors have investigated the outcome of the outside-in suture technique using dilator-knot and mulberry knot in a series of 28 patients.

Using standard arthroscopical portals the meniscal sutures had been performed.

An identical post-operative rehabilitation protocol was used for all the patients. Patients were clinically and functionally evaluated with Lysholm knee score, Tegner activity score, and International Knee Documentation Committee (IKDC) score, before surgery and at a mean of 32 (range 12-74) months postoperatively.

In our series of 28 patients there were 17 males and 11 females whose mean age at the time of surgery was 39.9 years (23-55). Of these patients, 22 had isolated meniscal tears (Group A), and 6 had menis-

cal tears with anterior cruciate ligament (ACL) rupture (Group B) and all of them underwent concomitant ACL reconstruction.

The meniscal tears morphologies were longitudinal in 22 cases (78%) and menisco-capsular disjunction in 6 cases (22%). The medial meniscus was affected in 17 cases (60.7%) and the lateral meniscus was affected in 11 cases (39.3%).

At the follow-up, no symptoms of meniscal tears were observed in 27 (96.3%) cases. Overall, the Lysholm score increased from a preoperative mean value of 62.5 (35-78) to a post-operative mean value of 93.4 (58-100) ( $p < 0.0001$ ). The IKDC score increased from a preoperative mean value of 58,8 (21.4-71.3) to post-operative mean value of 87.5 (23-96.6) ( $p < 0.0001$ ). The difference between the mean values of the Tegner activity score, before the injury 4.4 and in the post operative 3,8, showed a significant value ( $p < 0.001$ ). Furthermore, we divided our results in 2 groups: Group A (only repaired meniscus) and Group B (repaired meniscus + ACL reconstruction) comparing which we did not find any statistically significant difference in the outcome ( $p > 0.05$ ). None of the patients had neurovascular complications or infections.

There are several well-known techniques for repairing the meniscus. At present it can be concluded that no single meniscal repair technique is superior in all situations<sup>2,3</sup>.

Using outside-in technique it is possible to perform a good meniscal repair in the anterior two thirds of the meniscus. This is a quite simple technique that doesn't require dedicated hardware and the placement of the sutures in the planned direction is easy. Some specific advantages of this technique include the possibility to suture also meniscal replacement device and the feasibility to avoid neurovascular injury without the need of a large posterior incision.

Each type of knot has different biomechanical characteristics<sup>4</sup>, considering such we decided, in our surgical approach, to switch dilator knot (Fig. 1) and mulberry knot (Fig. 2) to combine the advantage of these techniques, trying to giving back to the meniscus a more physiological condition.

This technique is not recommended for posterior horn, considering the risk to damage vascular and nervous structure and because with this approach is not possible to insert the needle in a jointly liable direction respect the meniscal fibers<sup>5</sup>. If this contraindication is well kept in memory, outside-in has a low incidence of complication, a faster time of execution and a low cost.

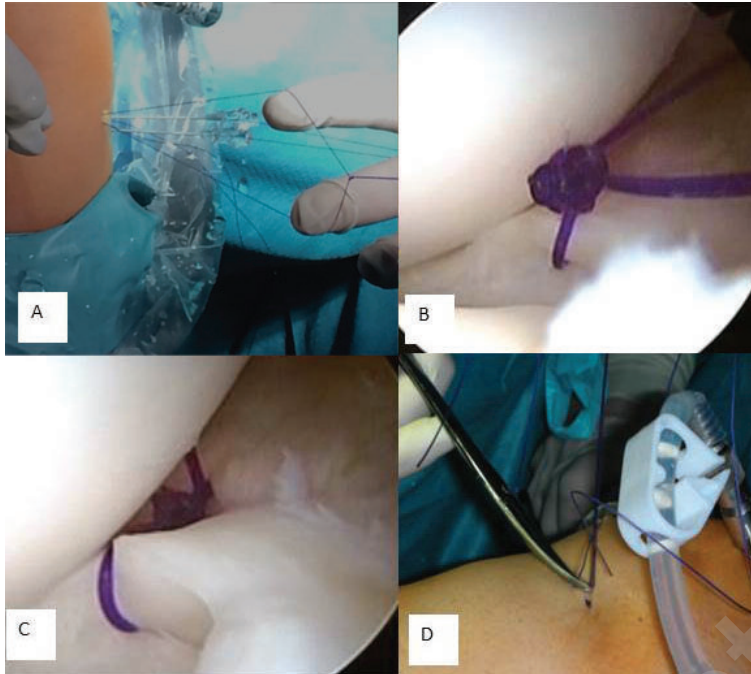


Figure 1. A,B: Creation of a knot with the ends of sutures which is pulled back until it lies on the meniscal surface. C: Visualization of the dilator knot. D: Cutting of the sutures under direct visualization.



Figure 2. A,B: Insertion of a needle and of a polydioxanone suture through an anterior portal. C: Visualization of the mulberry knot.

## References

1. Hutchinson ID, Moran CJ, Potter HG, Warren RF, Rodeo SA. Restoration of the Meniscus: Form and Function. *Am J Sports Med.* 2013. [Epub ahead of print]
2. Laible C, Stein DA, Kiridly DN. Meniscal repair. *J Am Acad Orthop Surg.* 2013;21(4):204-213.
3. Nepple JJ, Dunn WR, Wright RW. Meniscal repair outcomes at greater than five years: a systematic literature review and meta-analysis. *J Bone Joint Surg Am.* 2012;94(24):2222-2227.
4. Fantasia F, Potalivo G, Placella G, Fantasia L, Cerulli G. Meniscal sutures: biomechanical study of "mulberry" and horizontal loop techniques. *J Orthop Traumatol.* 2012;13(1):13-19.
5. Turman KA, Diduch DR. Meniscal repair: indications and techniques. *J Knee Surg.* 2008;21(2):154-162.
6. Padulo J, Oliva F, Frizziero A, Maffulli N. Muscle, Ligaments and Tendons Journal. Basic principles and recommendations in clinical and field science research. *MLTJ.* 2013;4:250-252.