

G Chir Vol. 26 - n.11/12 - pp.415-418
 Novembre-Dicembre 2005

Rectal bleeding by Dieulafoy-like lesion: successful endoscopic treatment

G. CASELLA, G. BONFORTE¹, R. CORSO², C. A. BUDA³, G. CORTI²,
 A.R. CAMBARERI², F. MAGRÌ², V. BALDINI

SUMMARY: Rectal bleeding by Dieulafoy-like lesion: successful endoscopic treatment.

G. CASELLA, G. BONFORTE, R. CORSO, C.A. BUDA, G. CORTI,
 A.R. CAMBARERI, F. MAGRÌ, V. BALDINI

A 81-year old woman affected by chronic renal failure, non insulin-dependent diabetes mellitus (NIDM) and hypertension, had an severe anemia bassive hematochezia. The colonoscopy could not localize the bleeding site except some blood spots in the rectum. The patient was readmitted after 1 month with hypovolemic shock by massive hematochezia and required several blood transfusions. The endoscopic examination showed an important arterial bleeding treated successfully with epinephrine and bipolar elettro-coagulation (BICAP).

We suggested that the patient presented a Dieulafoy-like lesion; this is an uncommon gastrointestinal cause of bleeding due to a defect of a submucosal artery without evidence of atherosclerosis or vasculitis. Both chronic renal failure and age could be considered as predisponent factors in this patient. Hematochezia is the most important sign and is often complicated by haemorrhagic shock. The diagnosis was delayed due to the difficulty in localizing the bleeding site; moreover, the patient needed several blood transfusions. The arteriographic diagnosis associated to endoscopic treatment by epinephrine and BICAP enabled a successful therapy.

RIASSUNTO: **Terapia endoscopica di un sanguinamento da ulcera simil-Dieulafoy rettale.**

G. CASELLA, G. BONFORTE, R. CORSO, C.A. BUDA, G. CORTI,
 A.R. CAMBARERI, F. MAGRÌ, V. BALDINI

Descriviamo il caso di una paziente di 81 aa, caucasica, affetta da insufficienza renale cronica, diabete mellito non insulino-dipendente ed ipertensione arteriosa. Si è presentata alla nostra osservazione per importante stato anemico determinato da abbondante proctorragia. La prima colonscopia non ha permesso di evidenziare l'origine del sanguinamento ed ha rilevato solo la presenza di materiale ematico in ampolla rettale. La paziente si ripresentava in reparto dopo 1 mese per shock ipovolemico da proctorragia severa che richiedeva l'infusione di numerose unità di sangue. La nuova colonscopia ha permesso di individuare un importante sanguinamento arterioso rettale e di trattarlo endoscopicamente con infusione locale di epinefrina ed Elettrocoagulazione Bipolare (BICAP).

L'evidenza clinica è che possa trattarsi di una lesione rettale simil-Dieulafoy. Questa è una rara causa di sanguinamento rettale determinato da un difetto di un'arteria sottomucosa senza evidenza di processi aterosclerotici o vasculitici. L'età avanzata e l'insufficienza renale cronica potrebbero essere considerate fattori predisponenti. La proctorragia è il segno clinico più importante e spesso è complicato da shock ipovolemico. La diagnosi è stata tardiva per la difficoltà di identificare il punto di sanguinamento. L'arteriografia associata alla terapia endoscopica con epinefrina e BICAP ha permesso il successo terapeutico.

KEY WORDS: Rectal Dieulafoy-like lesion - Rectal bleeding - Endoscopic therapy,
 Ulcera rettale simil-Dieulafoy - Sanguinamento rettale - Terapia endoscopica.

Introduction

The Dieulafoy lesion is an uncommon cause of gastrointestinal bleeding; it is more frequent in the upper gastrointestinal tract, sometimes associated to a massive and life-threatening haemorrhage (1). Rectal Dieulafoy lesion is rarely observed; it is represented by a tiny mucosal defect with arterial protruding vessels surrounded by normal mucosa (2).

Before introduction of the endoscopic procedures, the "Dieulafoy lesion" was only diagnosed as a result of histological studies of postmortem or resected specimens. Now a - days, the diagnosis is possible by means of endoscopic criteria so that the term "Dieulafoy-like lesion" is more correct (1).

A rectal "Dieulafoy-like lesion" in an old diabetic patient with chronic renal failure is reported; the patient was treated endoscopically with success thanks to an accurate angiographic study.

Case report

C.F., an 81 year-old Caucasian female, was affected by chronic

Azienda Ospedaliera di Vimercate
 Ospedale di Desio, Desio (MI)
 Divisione di Medicina
¹ Divisione di Nefrologia
² Divisione di Chirurgia
³ Policlinico Universitario di Messina
 Dipartimento di Oncologia

© Copyright 2006, CIC Edizioni Internazionali, Roma

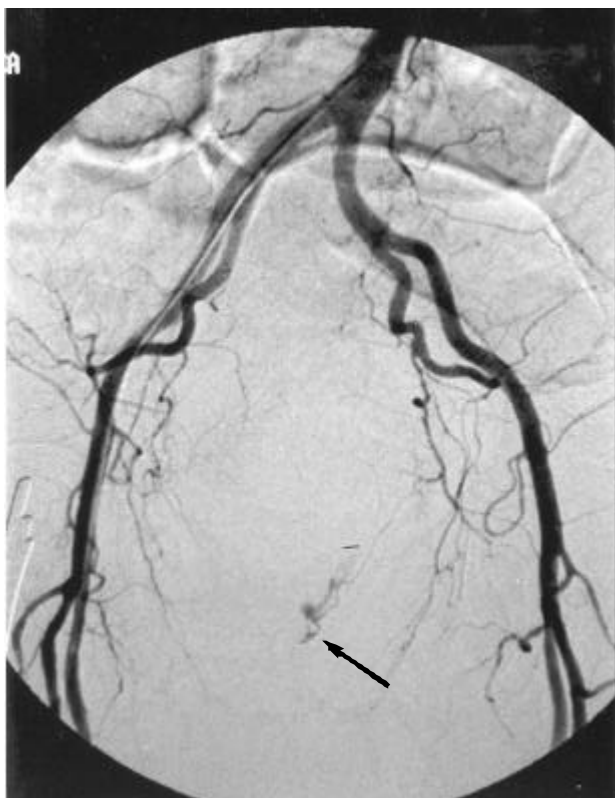


Fig. 1 - Angiographic imaging of non-tapered, convoluted artery, diagnostic for rectal Dieulafoy-like lesion.

renal failure due to non insulin-dependent diabetes mellitus (NIDM). 17 years before, she underwent a left nephrectomy due to nephrolithiasis. She suffers from other severe associated diseases, such as gastric peptic ulcer, hypertension, gallstones and an important retinopathy. In October 2000, the patient was referred to our Hospital because of important hematochezia. When the patient was admitted she was pale and in poor general conditions. The blood examination showed important anaemia (Hb 7.1 g/dL with HTC 31.1%), mild hyperkalemia (5.1 mEq/L), severe renal function abnormalities (creatinine 2.56 mg/dL, blood urea 96 mg/dL associated to proteinuria 2.92 g/L/day), and hyperglycemia 142 mg/dL. An intravenous infusional therapy, for correction of the acid-base and electrolytes disorders, was necessary to treat severe metabolic acidosis (pH 7.3, pO₂ 70 mmHg, pCO₂ 25 mmHg). The electrocardiography (ECG) was normal; chest X-ray documented a mild vascular congestive lung. An hyperechogenic liver, wrinkled gallbladder due to cholelithiasis and absence of left kidney (previous nephrectomy) was evidenced by ultrasound exploration. The colonoscopy did not localize the haemorrhage site, but only blood spots were evident in colonic explored tracts. The patient denied enema or other traumatic rectal procedures. The patient improved and few days later she was discharged on insulin therapy, oral sodium bicarbonate, sucralfate and oral iron.

One month later, the patient was readmitted to our hospital because of hypovolemic shock by massive hematochezia; ten blood transfusion units were necessary due to important anaemia (Hb 5.5 g/dL, HTC 21.5%). A new endoscopic examination revealed an important hematochezia without evident haemorrhagic lesions spurting. Considering the risk of endovenous contrast medium and performing a moderate hydration, arteriography was performed, thus enabling to localize the bleeding site (Fig. 1); a new colonoscopy revealed a haemorrhagic lesion in the left lateral

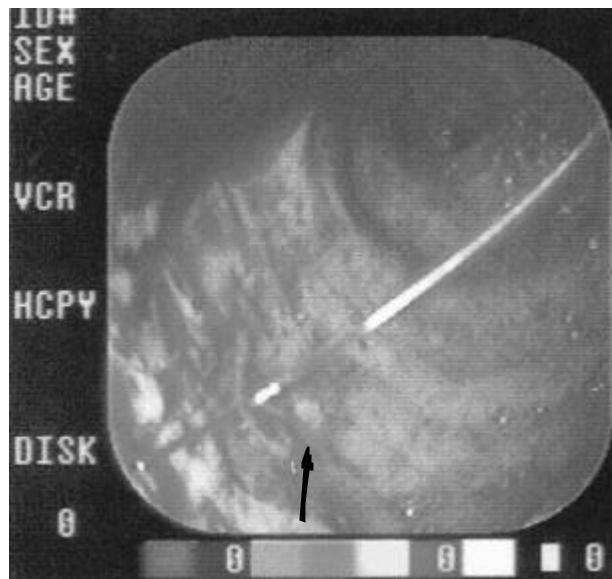


Fig. 2 - Active bleeding "spurting" by rectal Dieulafoy-like lesion.

rectal mucosa, 5 cm above the anal sphincter (Fig. 2). A 10 ml of epinephrine (1:10.000) and Bipolar Electrocoagulation (BICAP) was performed, thus stopping (Fig. 3) the important bleeding. The patient was discharged and now, after 3 years of follow-up, the patient is in good health.

Discussion

"Dieulafoy-like ulcer" was first reported by Gallard in 1884, but in 1898 a French surgeon, Dieulafoy, described this lesion anatomically (3). The classical Dieulafoy's lesion has been identified along the lesser curve of the stomach with the possibility to involve the whole gastrointestinal tract (4). Only few rectal "Dieulafoy-like lesion" are described in world literature (2). The incidence seems to be higher in middle-aged patients, but this disease has been reported at all ages (4); for instance, Tooson (5) reports a rectal Dieulafoy's lesion in a 5-year-old child. It is to be noticed a higher incidence of small intestinal and colonic "Dieulafoy-like lesion" in females (1). In Dieulafoy's disease, gastrointestinal bleeding is caused by a defect in an unusually large submucosal artery, through a minute mucosal erosion (6).

The vascolarization, within the gastro-intestinal tract mucosa, including capillaries and venules, develops from a ramification process involving penetrating serosal arteries; the progressive reduction of these arterial vessels occurs within the outer muscular and sub-mucosal layers of the bowel wall (1).

Histologically, the responsible vessels are hypertrophied, tortuous and ulceration or inflammation signs are absent near the lesion (4). These submucosal arteries have the typical structure of larger muscular arteries and they are called "caliber persistence" (7).

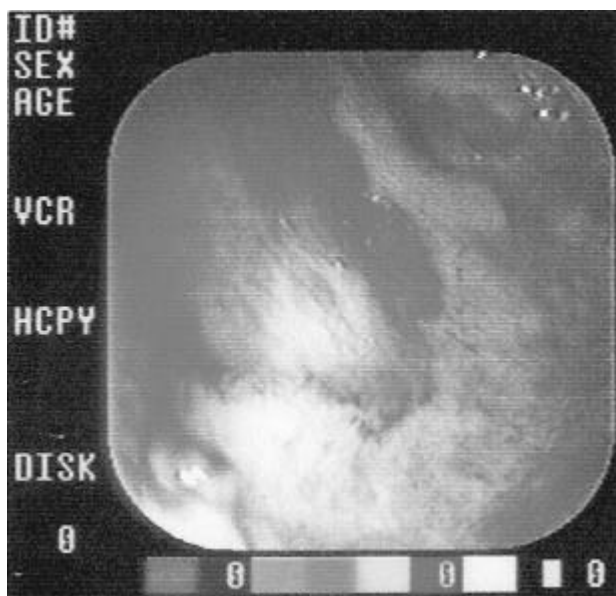


Fig. 3 - Appearance of the lesion after the endoscopic treatment.

These vessels can be extended over a long course of submucosal layer, with a predisposition to erosions and bleeding in different sites due to strong pulsations, which may mechanically damage the overlying mucosa, and "to expose" the arterial wall (1). Vasculitis and atherosclerosis are never identified in resected specimens and "Dieulafoy-like" lesion may be considered a primary vascular anomaly (7). As it is in our case, in old patients submucosal arteries elongate and become tortuous, like in the temporal areas (6) this tortuous profile may cause pressure on the overlying mucosa leading to mucosal ischemia, erosion, and then to arterial rupture.

Dieulafoy's disease is a disorder connected with aging; some authors hypothesize the existence of congenital lesions, but it is difficult to explain the clinical evidence in old age (6). Age-related atrophy of the overlying mucosa is a predisponent factor of vessel erosion. It is interesting to point out that our patient was affected by chronic renal failure (CRF); CRF is often associated to vascular ectasia (VE) and it is to be noticed that a long duration and severity of renal disease may be considered a predisponent factor (8).

Hematochezia is the most important symptom of these patients, and it frequently represents a life-threatening hemodynamic instability (1). Hematochezia is often massive, because the defect is in tangential position toward the lumen, and effective hemostasis by vascular contraction or thrombosis is unsatisfactory (7); vascular contraction is impaired for loss or absence of the circular layer and innermost layer of muscularis propria, because the lesion is often surrounded by fat accumulation (9). Clinically, massive bleeding enables a

different diagnosis of vascular ectasia, where the bleeding is usually silent and low-grade (9).

Endoscopically, the Dieulafoy's disease consists in bleeding from a tiny mucosal defect surrounded by normal mucosa or, otherwise, in a protruding vessel (6). Endoscopic diagnostic criteria are (4):

- 1) active arterial spurting or micropulsatile streaming from minute (< 3 mm) mucosal defects or through normal surrounding mucosa;
- 2) visualization of a protruding vessel with or without active bleeding within a minute mucosal defect or through a normal appearing mucosa;
- 3) fresh, adherent clot with a narrow point of attachment to a minute mucosal defect or normal appearing mucosa.

The bleeding may be of an oozing type, a streaming type, a spurting type and, however, an inactivity type (6). The absence of a widespread, macroscopic surrounding inflammatory process is an important criteria for endoscopic diagnosis (1).

Left lateral position in the rectal wall enables a differential diagnosis of solitary rectal ulcer (SRU) (10); solitary rectal ulcer affects young people, particularly people aged 20-40, and it is identified on the anterior rectal wall within 13 cm of the anal verge (10). There may be surrounding erythema. The removal of adherent clots is advisable, only if endoscopic therapy and surgical backup are available; these cautions should be applied to Dieulafoy's lesion endoscopic treatment in all gastrointestinal tract (6). Selective arteriography, as it is in our case, is helpful for the diagnosis, particularly when active bleeding is present. A non-tapered, convoluted artery is a typical diagnostic angiographic aspect and enables to distinguish vascular ectasia (11).

As reported by Eguchi (2), Technetium-99m (99mTC)-red blood cells (RBC) scintigraphy may be fundamental to detect the bleeding site; in our case, it is not performed because of the patient's life-threatening general conditions.

Until 1993, before Abdulian's report (11), surgical resection was the standard therapy used to control bleeding in Dieulafoy's disease (6). Endoscopic treatment of these "Dieulafoy-like lesions" is safe and effective; Epinephrine injection (1: 10.000 solution- 3-5 cc volume/range), Heater probe thermocoagulation (25-30 joules/pulse), BICAP and Nd:YAG laser (40-50 watts/pulse) are the most commonly used endoscopic devices. Polidocanol sclerotherapy, histoacryl tissue glue, ethanol injection sclerotherapy and hypertonic glucose have been also used (6). The requirement of more than 6-8 unit transfusions is an indication to surgery, but in our case endoscopic therapy enabled to avoid surgical procedure, considering the advanced age of the patient; however, our patient also needed blood transfusions, because the diagnosis was delayed

due to the difficulty in localizing the bleeding site. Actually, in less than 50% of the patients affected by Dieulafoy's lesion it is possible to localize the bleeding site during the initial endoscopy, because of the small size of the mucosal defect and of the intermittent bleeding (9).

A combination of epinephrine injection and heater probe thermo-coagulation, as it is in our case, may be considered a possible endoscopic treatment with a high immediate success rate without deaths or complications related to endoscopic procedure (6); BICAP probe has a low grade of penetration in the deepest layers of rectal wall. Moreover, the thickness of the lower rectal wall also enables a more aggressive endoscopic treatment with endoscopic devices, as described by Abdulian (11). In 1993, as referred before, this author was the first to treat endoscopically and successfully rectal Dieulafoy's lesion.

During the sclerotherapy treatment caution must be used above the level of the peritoneal reflection (7-10cm), as the risk of perforation is higher (11).

Nomura et al (12) describe a successful endoscopic clipping in the treatment of this lesion, while Mizukami et al (13) have achieved a good result by endoscopic band ligation. Some Authors prefer a surgical resection of the lesion, because endoscopic therapy may fail due to the long course of the abnormal tortuous artery (3). Surgical treatment was needed in a young 18-year-old female suffering 45% body surface area burns; after 1 month, she developed sudden massive rectal bleeding by Dieulafoy rectal lesion localized at the anorectal junction, thus both endoscopy and angiography failed to stop the bleeding (14).

Our case confirms the importance of endoscopy in the diagnosis and treatment of rectal "Dieulafoy-like lesion".

References

1. Dy NM, Gostout CJ, Balm RK. Bleeding from the endoscopically identified Dieulafoy lesion of the proximal small intestine and colon. *Am J Gastroenterol* 1995; 90: 108-111.
2. Eguchi S, Maeda J, Taguchi H, Kanematsu T. Massive gastro-intestinal bleeding from a Dieulafoy-like lesion of the rectum. *J Clin Gastroenterol* 1997; 24: 262-263.
3. Franko E, Chardavoyne R, Wise L. Massive rectal bleeding from a Dieulafoy's type ulcer of the rectum: A review of this unusual disease. *Am J Gastr* 1991; 86: 1545- 1546.
4. Abdelmalek MF, Pockaj BA, Leighton JA. Rectal bleeding from a mucous fistula secondary to a Dieulafoy's lesion. *J Clin Gastroenterol* 1997; 24: 259-261.
5. Tooson JD, Marsano LS, Gates LK. Pediatric rectal Dieulafoy's lesion. *Am J Gastroent* 1995; 90: 2232-3.
6. Stark ME, Gostout CJ, Balm RK: Clinical features and endoscopic management of Dieulafoy's disease. *Gastr End* 1992; 38: 545-550.
7. Barbier P, Luder P, Triller J et al. Colonic hemorrhage from a solitary minute ulcer: report of three cases. *Gastroenterology* 1985; 88: 1065-8.
8. Chalasani N, Cotsonis G, Wilcox CM. Upper gastrointestinal bleeding in patients with chronic renal failure: role of vascular ectasia. *Am J Gastroent* 1996; 91: 2329-2332.
9. Chan KMa, Padda H, Pace E, Szilagyi E. Submucosal arterial malformation of the colon with massive hemorrhage. *Dis Col& Rect* 1989; 32: 149-152.
10. Ford MJ, Anderson JR, Gilmour HM, Holt S, Sircus W, Heading RC. Clinical spectrum of solitary ulcer of the rectum. *Gastroenterology* 1983; 91: 1123-9.
11. Abdulian JD, Santoro MJ, Chen YK, Collen MJ. Dieulafoy-like lesion of the rectum presenting with exsanguinating hemorrhage: Successful endoscopic sclerotherapy. *Am J Gastrent* 1993; 88: 1939-1941.
12. Nomura S, Kawahara M, Yamasaki K, Nakanishi Y, Kaminishi M. Massive rectal bleeding from a Dieulafoy lesion in the rectum: successful endoscopic clipping. *Endoscopy* 2002; 34: 237.
13. Mizukami Y, Akahoshi K, Kondoh N, Harada N, Nawata H. Endoscopic Band Ligation for Rectal Dieulafoy's lesion: Serial Endoscopic Images. *Endoscopy* 2002; 34: 1032.
14. Guy RJ, Ang ES, Tan KC, Tsang CB. Massive bleeding from a Dieulafoy-like lesion of the rectum in a burns patient. *Burns* 2001; 27: 767-9.
15. Enns R. Dieulafoy's lesions of the rectum: a rare cause of lower gastrointestinal bleeding. *Can J Gastroenterol* 2001; 15: 541-5.