

## Role of virtual colonoscopy following incomplete optical colonoscopy: our experience

I. SALAMONE, C. BUDA<sup>1</sup>, T. ARCADI, G. CUTUGNO, M PICCIOTTO<sup>1</sup>

**SUMMARY:** Role of virtual colonoscopy following incomplete optical colonoscopy: our experience.

I. SALAMONE, C. BUDA, T. ARCADI, G. CUTUGNO, M PICCIOTTO

**Aim.** To evaluate the role of Computed Tomography Colonography (CTC) in patients who failed an Optical Colonoscopy (OC).

**Patients and methods.** Sixtyeight patients (48 female, 20 male; mean age 60,4 years) with a previous incomplete OC underwent CTC.

**Results.** A complete CTC examination was achieved in all 68 patients. We classified the detected polyps in relation to the diameter in small (<5mm), medium (from 5 to 10mm) and large (>10mm). In 19 patients (27,9%) any pathological finding was observed. In 11 patients (16,2%) one or more polyps not detected with the previous OC have been found. Only in one case the number of detected polyps corresponded to the OC findings.

In 18 (26,4%) patients a diverticular disease was observed, and in 15 of them it was diagnosed by the previous OC (26,5%). In 8 patients (11,8%) the diverticular disease was associated to the presence of polyps. In 12 patients (17,6%) colonic stenosis or masses have been observed.

**Conclusions.** CTC was performed in all patients with a previous incomplete OC, obtaining a complete and accurate visualization of the colon without any patient's discomfort.

**RIASSUNTO:** Ruolo della colonscopia virtuale dopo colonscopia tradizionale incompleta: nostra esperienza.

I. SALAMONE, C. BUDA, T. ARCADI, G. CUTUGNO, M PICCIOTTO

**Scopo.** Valutazione del ruolo della colonscopia virtuale (CV) in pazienti sottoposti a colonscopia tradizionale (CT) incompleta.

**Pazienti e metodi.** Sessantotto pazienti (48 donne e 20 uomini, età media 60,4 anni) con precedente CT incompleta sono stati sottoposti a CV.

**Risultati.** Nei 68 pazienti sottoposti a CV i polipi individuati sono stati classificati in piccoli (diametro < 5 mm), medi (da 5 a 10 mm) e grandi (> 10 mm). In 19 pazienti (27,9%) non è stata osservata alcuna patologia. In 11 pazienti (16,2%) sono state evidenziate una o più formazioni polipoidi non riscontrate alla CT. Solo in un paziente vi era corrispondenza tra il dato della CT e della CV. In 18 pazienti (26,4%) è stata riscontrata malattia diverticolare che in 8 (11,8%) era associata alla presenza di polipi. In 12 pazienti (17,6%) era presente una stenosi o una formazione colica.

**Conclusioni.** I dati emersi dal nostro studio confermano la validità della CV, effettuata nei pazienti con CT incompleta, sia per l'accuratezza diagnostica che per la tollerabilità della metodica.

**KEY WORDS:** Computed tomography colonography - Colonoscopy - Colorectal cancer.  
Colonscopia virtuale - Colonscopia tradizionale - Cancro coloretale.

### Introduction

Colorectal cancer (CRC) is the third most common cancer and the second leading cause of death from cancer in the United States. Conventional endoscopy represents the gold standard technique for the evaluation of colorectal diseases. Moreover, during direct visual examination

it is possible to perform biopsy of suspected lesion and polypectomy.

Optical Colonoscopy (OC) is recommended in patients with colon malignancy, because the high rate of synchronous polyps and carcinoma (1). However, OC is an invasive, not well accepted examination, and often requires sedation.

In addition, about 6-26% of conventional colonoscopy examinations are incomplete and fail to reach the initial tract of the colon and cecum (2, 3, 28) for several reasons: redundant and tortuous colon with angulations or fixation of colonic loops, most commonly due to previous abdominal surgery, severe diverticular disease,

University of Messina, Italy  
Department of Radiological Sciences  
<sup>1</sup> Department of General Surgery, Oncology and Pathological Anatomy  
© Copyright 2011, CIC Edizioni Internazionali, Roma

obstructing masses and strictures (4, 11). The reported rate of incomplete OC is 22-33% (5, 12) and it tends to increase in older patients.

In the last years Computed Tomography Colonography (CTC), also called “virtual colonoscopy”, has been used. It is a non-invasive imaging technique with the advantages of rapid acquisition, minimal patient discomfort and no need for sedation.

The purpose of our study is to evaluate the role of CTC in patients with incomplete OC.

## Patients and methods

From January 2007 to December 2009, 205 CTC examinations have been performed in our Department of Radiology in adult patients with or without symptoms. Sixty-eight of these patients (48 female, 20 male; mean age 60,4 years) were referred from the Service of Endoscopy of the Department of Integrated Therapies in Oncology of our Hospital, because of an incomplete OC; in other patients virtual colonoscopy was performed as screening for colorectal cancer. Indications for colonic evaluation were: rectal bleeding (n=8), history of polyps (n=23), anaemia (n=6), change in bowel habits (n=7), history of colon carcinoma (n=9), screening for colon cancer (n=13) and increased uptake of <sup>18</sup>F-FDG in the area of cecum on PET (n=2) (Fig. 1).

Incomplete OC was caused by dolichocolon (9,7%), severe diverticular disease (25,2%), angulations and adherences due to previous abdominal surgery (46,9%), patient discomfort (15,5%) (Table 1).

CTC was performed on the same day of the OC, using just only one bowel preparation and colonic distension obtained during the previous examination, and after manual air insufflation if necessary (Table 2). Every patient underwent a standard bowel preparation by drinking 4L of polyethylene glycol (PEG) solution within the day before the procedure and a low-residue and/or clear fluid diet for 24–48 h prior to the examination. All the examinations were performed

in agreement with the recommendations of our institutional review board. Preliminarily, the degree of colonic distension was assessed on axial images obtained by a CT scout-view of abdomen and pelvis. At the same time the adequacy of bowel preparation was evaluated by assessing the proportion of colonic segments containing residual faecal matter: fluid, solid or mixed for each patient (respectively 5, 11 and 8 patients). It was considered good in 44 patients. If the entire colon, particularly the sigmoid, was not well distended, we repeated the administration of gas according to maximum patient tolerance (Fig. 2). Following supine axial image acquisition, the patient was turned prone and another CT scout image was obtained with additional gaseous insufflation if segments of colon with suboptimal distension were noted. Then a prone acquisition was performed.

All CTC were performed by a 16-detector CT scanner (Sensation 16, Siemens, Erlangen, Germany) or a dual source CT scanner (Definition, Siemens, Erlangen, Germany) using the following parameters: 50 or 30 mAs (supine or prone) without CareDose, 120 kV, collimation 16 x 0,75 mm or 64 x 0,75 mm, recon 1 mm with B30f or B10f kernel. Axial images were then post-processed by a computed software (Syngo Colon, Siemens, Erlangen, Germany), using MPR and SSD reconstructions.

## Results

A complete CTC examination was achieved in all 68 patients.

In relation to the diameter we classified the detected polyps in small (<5mm), medium (from 5 to 10mm) and large (>10mm) (Table 3). Then we compared the virtual colonoscopy findings to those obtained by conventional colonoscopy (Fig. 3).

In 19 patients (27,9%) no pathological finding was observed. CTC detected a total of 23 polyps: 3 of them were small, 12 medium, 8 large.

In 11 patients (16,2%) one or more polyps not de-

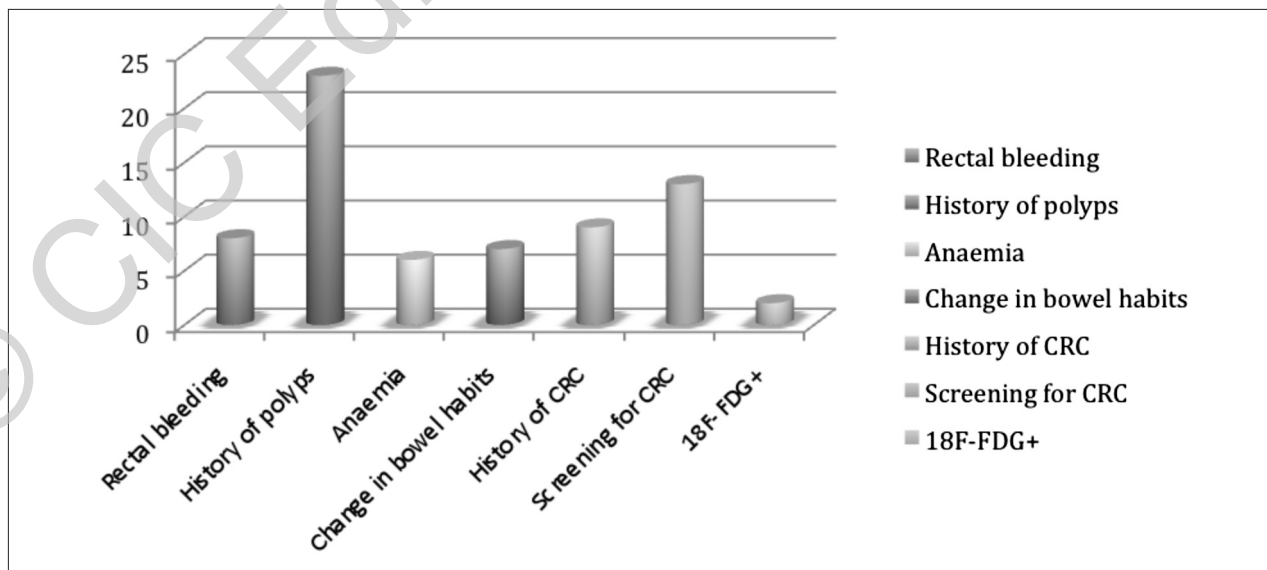


Fig. 1 - Indications for colon assessment.

TABLE 1 - CAUSES OF FAILED OPTICAL COLONOSCOPY (OC).

Cause	%
Angulations and adherences	46,9
Severe diverticulosis	25,2
Patient discomfort	15,5
Dolichocolon	9,7

tected with the previous OC have been found. Only in one case the number of detected polyps corresponded to the OC findings.

In 18 patients a diverticular disease was observed; among them, OC previously detected a diverticular disease in 15 cases (26,5%). In 8 patients (11,8%) it was associated to polyps.

In 12 patients (17,6%) a colonic stenosis or mass has been observed (Table 4).

Extra-colonic findings were found in 44 patients (64,7%); they were then studied with CT or US (Table 5).

## Discussion

Most CRC arise from pre-existing adenomatous polyps that undergo malignant transformation in 10 to 15 years (17). Due to its natural history, colorectal cancer is an ideal candidate for screening.

So an accurate and complete visualization of the whole colon is necessary. Particularly, a well-done examination is important also for a correct treatment, overall in case of synchronous adenomas and adenocarcinoma, found respectively in 14-48% and 2-9% (18, 19).

Several studies showed that double-contrast barium enema (DBCE) has a low accuracy for the detection of colonic neoplasm, with a sensitivity of 45-50% for >9 mm adenomas (20).

Optical Colonoscopy (OC) is regarded as the gold standard for the evaluation of the colon (16). In a complete colonoscopy examination, all the colonic segments from rectum to cecum must be evaluated. Although the rate of incomplete colonoscopy depends on the operator's interpretation, it occurs in 2-10% of cases (11). In our experience it is about 10%. The rate of incomplete OC and the number of relative contraindications to

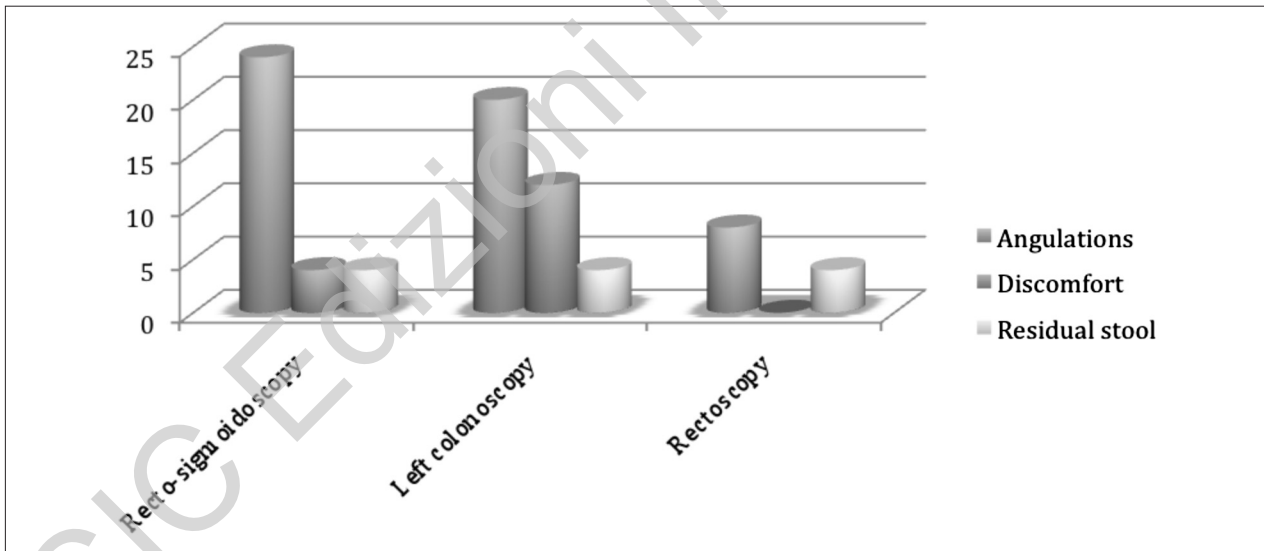


Fig. 2 - Causes of incomplete optical colonoscopy (OC).

TABLE 2 - OPTICAL COLONOSCOPY FINDINGS.

Optical colonoscopy finding	(n)
Polyps	24
Stenosing lesions	12
Diverticula	24
No lesions	32

TABLE 3 - CLASSIFICATION OF POLYPS ACCORDING TO DIAMETER (mm).

Polyp classification
• Small (<5mm)
• Medium (from 5 to 10mm)
• Large (>10mm)

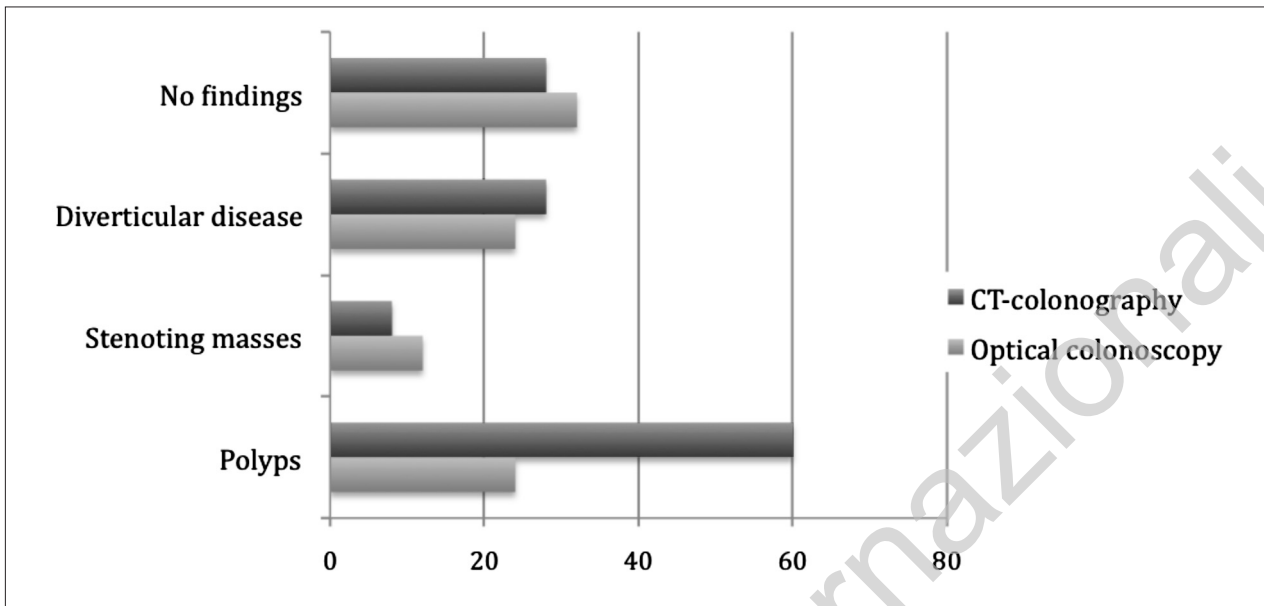


Fig. 3 - Comparison between Optical Colonoscopy versus CT-Colonography findings.

TABLE 4 - CT-COLONOGRAPHY (CTC) FINDINGS.

CT-colonography finding	(n)
Polyp < 5 mm	12
Polyp 5 – 10 mm	28
Polyp > 10 mm	20
Diverticula	28
Stenosing lesions	8
Accentuated haustra	12
Lipomatosis of ileo-cecal valve	8
No lesions	28
Extra-colonic findings	44

TABLE 5 - EXTRA-COLONIC FINDINGS.

Extra-colonic findings	(n)
Focal lesions of kidney	6
Lythiasis of gallbladder	3
Fibromatosis of uterus	3
Hypodense hepatic lesions	3
Renal cysts	3
Urolythiasis	3
Atherosclerosis	3
Miscellaneous	12
Others	10

OC tend to increase with the patient's age (13).

OC examination can be incomplete for many reasons. Redundant colon, colonic spasm, severe diverticulosis, obstructing masses or strictures, angulations or fixation of colonic loops are often the causes of failed OC (11, 12). DBCE has been used to image colon after failed or incomplete OC; when performed immediately after OC, the visualization of the entire colon can be reached in 77-94% of cases (14, 15).

CT colonography or "virtual colonoscopy" has increasing support as a screening tool for colorectal polyps and carcinoma. Several studies highlighted the role of CTC in the evaluation of the proximal colon, which is sometimes not explored by OC (6, 7). The American

Gastroenterologists Association (AGA) recommends CTC as an alternative tool when it is not possible to perform a complete OC (8, 9). Although some controversies, there is evidence that sensitivity of CTC compares favourably with OC in the detection of colorectal neoplasm (10).

CTC is indeed a relatively new imaging technique with the advantage of combining cross-sectional imaging data with computer software that postprocesses the data to generate both 2- and 3-D endoluminal images of the colon for analysis. The key element for a high diagnostic-quality CT colonography examination is a well-clean-

sed and well-distended colon, particularly if fecal and fluid tagging is not employed. When the colon contains residual fluid and/or stool or it is poorly distended, false-negative and false-positive results can occur; the diagnostic usefulness of computer-aided detection algorithms will be limited too.

In our practice patients are typically scanned in two opposing positions (supine and prone) so that portions of the colon that have residual material or poor distension in one position may be re-evaluated in the opposing view.

CTC is also well tolerated by patients because it is a non invasive examination and leads to diagnosis of polyps with 5mm or greater diameter.

Although CTC is operator-and technique-dependent, it has a relatively high specificity (21).

Unlike OC or DBCE, this examination depicts simultaneously all the intra-abdominal structures with the advantage of incidental extra-colonic findings, which can be observed with an overall prevalence of 15 to 85%, whereas the prevalence of high important findings ranged from 4,5 to 13% (22).

Moreover CTC can be performed on the same day

of the incomplete OC using its previous bowel preparation and air insufflation, without any discomfort or contraindication for the patient (23, 24).

However, CTC has some limitations: flat lesions may be more difficult to be detected on 3D endoluminal imaging. The lack of informations about hyperaemia, inflammatory infiltration and mucosal erosion is another limitation of CTC, but the most important disadvantage is that it is unable to provide a pathological specimen (25, 26). Anyway, CTC has the potential to become an accepted technique for the evaluation of non visualized part of colon after an incomplete OC and it can increase the diagnostic yield in the evaluation of colorectal cancer.

## Conclusion

Our study demonstrated that CTC should actually become the most feasible, well-tolerated and useful technique for the assessment of the entire colon, when it is not possible to perform a complete OC, according to the most recent literature (27).

## References

1. Smith RA, Cokkinnides V, von Eschenbach AC, et al. American Cancer Society guidelines for the early detection of cancer. *CA Cancer J Clin* 2002; 52:8-22.
2. Schrock TR, Colonoscopy versus barium enema in the diagnosis of colorectal cancers and polyps. *Gastrointest Endosc Clin N Am* 1993 3:585-610.
3. Culpan DG, Mitchell AJ, Hughes S, et al. Double contrast barium enema sensitivity: a comparison of studies by radiographers and radiologist. *Clin Radiol* 2002; 57:604-607.
4. Gollub MJ, Flaherty F. Barium enema following incomplete colonoscopy. *Clin Imaging* 1999; 23:367-374.
5. Burtin P, Bour B, Chros T, et al. Colonic investigation in the elderly: colonoscopy or barium enema? *Aging* 1995; 7:190-194.
6. Macari M, Berman P, Dicker M, Milano A, Megibow AJ. Usefulness of CT colonography in patients with incomplete colonoscopy. *AJR Am J Roentgenol* 1999; 173:561-564.
7. Pickhardt PJ, Choi JR, Hwang I, et al. Computed tomography virtual colonoscopy to screen for colorectal neoplasia in asymptomatic adults. *N Engl J Med* 2003; 349:2191-2200.
8. Pavone P, Luccichenti G, Cademartiri F. Improving the results of virtual colonoscopy: what the future will bring. *Semin Ultrasound CT MR* 2001; 5:400-402.
9. Rockey DC, Barish M, Brill JV, Cash BD, Fletcher JG, Sharma P, Wani S, Wiersema MJ, Peterson LE, Conte J. Standards for gastroenterologists for performing and interpreting diagnostic computed tomography colonography. *Gastroenterology* 2007; 133:1005-1024.
10. Dachman A. Virtual colonoscopy: potential applications of a new technique. *Gastroenterol Clin N Am* 2002; 31:747-757.
11. Copel L, Sosna J, Kruskal JB, Raptopoulos V, Farrell RJ, Morrin MM. CT colonography in 546 patients with incomplete colonoscopy. *Radiology* 2007; 244:471-478.
12. Yucel C, Lev-Toaff AS, Moussa N, Durrani H. CT Colonography for incomplete or contraindicated optical colonoscopy in older patients. *AJR* 2008; 190: 145-150.
13. Burtin P, Bour B, Charlois T, et al. Colonic investigations in the elderly: colonoscopy or barium enema? *Aging* 1995; 7:190-194.
14. Brown AL, Skehan SJ, Greaney T, Rawlinson J, Somers S, Stevenson GW. Value of double-contrast barium enema performed immediately after incomplete colonoscopy. *AJR* 2001; 176:943-945.
15. Martinez M, Kondylis P, Reilly J. Limitations of barium enema performed as an adjunct to incomplete colonoscopy. *Dis Colon Rectum* 2005; 48:1951-1954.
16. Winawer SJ, Fletcher RH, Miller L, et al. Colorectal cancer screening: clinical guidelines and rationale. *Gastroenterology* 1997; 112:594-642
17. Muto T, Bussey HJ, Morson BC. The evolution of cancer of the colon and rectum. *Cancer* 1975; 36:2251-2270.
18. Arenas RB, Fichera A, Mhoon D, Michelassi F. Incidence and therapeutic implications of synchronous colonic pathology in colorectal adenocarcinoma. *Surgery* 1977; 122:706-710.
19. Takeuchi H, Toda T, Nagasaky S, Kawano T, Minamisono Y, Maehara Y, et al. Synchronous multiple colorectal adenocarcinomas. *J Surg Oncol* 1997; 64:304-307.
20. Winawer SJ, Stewart ET, Zauber AG, Bond JH, Ansel H, Wayne JD, Hall D, Hamlin JA, Schapiro M, O'Brien MJ, Sternberg SS, Gottlieb LS. A comparison of colonoscopy and double-contrast barium enema for surveillance after polypectomy. National Polyp Study Group. *N Engl J Med* 2000; 342:1766-1772.
21. Fenlon IIM, Nunes DP, Schroy PC, et al. A comparison of virtual and conventional colonoscopy for the detection of colorectal polyps. *N Engl J Med* 1999; 341: 1496-1503.
22. Hara AK. Extracolonic findings at CT colonography. *Semin Ul-*

- trasound CT MR 2005; 26:24-27.
23. Neri E, Giusti P, Battola L, Vagli P, Boraschi P, Lencioni R, et al. Colorectal cancer: role of CT colonography in preoperative evaluation after incomplete colonoscopy. *Radiology* 2002; 223:615-9.
  24. Fenlon HM, McAneny DB, Nunes DP, Clarke PD, Ferrucci JT. Occlusive colon carcinoma: virtual colonoscopy in the preoperative evaluation of the proximal colon. *Radiology* 1999; 210:423-8.
  25. Pickhardt PJ, Nugent PA, Choi JR, Schindler WR. Flat colorectal lesions in asymptomatic adults: implications for screening with CT virtual colonoscopy. *AJR* 2004; 183:1343-1347.
  26. Park SH, Lee SS, Choi EK, et al. Flat colorectal neoplasm: definition, importance, and visualization on CT colonography. *AJR* 2007; 188:953-959
  27. Lapo S, Falchini M, Bonanomi AG, Castiglione G, Ciatto S, Mantellini p, Mungai F, et al. CT colonography after incomplete colonoscopy in subjects with positive faecal occult blood test. *World J Gastroenterol* 2008; 14(28):4499-4504.
  28. Joo Hee Kim et al. Incomplete Colonoscopy in Patients with Occlusive Colorectal Cancer: Usefulness of CT Colonography According to Tumor Location. *Yonsei Med J* 2007;48:934-941.
-