

## Interposition of the gallbladder in the common hepatic duct: a rare dangerous anomaly. Case report

L. ROSATO, A. GINARDI, G. MONDINI

**SUMMARY:** Interposition of the gallbladder in the common hepatic duct: a rare dangerous anomaly. Case report.

L. ROSATO, A. GINARDI, G. MONDINI

**Introduction.** Anomalies of the gallbladder position in the biliary tract are rare, but they could be very dangerous during cholecystectomy.

**Case report.** A 48-year-old man presented with a 2-week history of intermittent epigastric pain, scleral jaundice and elevation of liver function tests. After a magnetic resonance cholangiogram and an endoscopic retrograde cholangiogram with sphincterotomy, he was submitted to laparoscopic cholecystectomy, the conversion to laparotomy was decided for the suspect of gallbladder interposition. The anatomical anomaly was confirmed and a Roux-en-Y hepaticojejunostomy was executed, with end-to-side anastomosis between the confluence of the hepatic ducts and the fourth loop of jejunum, on a biliary stent. This catheter was removed in the tenth postoperative day; after cholangiography and CT abdominal scan the patient was discharged, without complications.

**Conclusion.** The gallbladder interposition is a rare malformation which seems to arise from an embryonic anomaly occurring between the 4<sup>th</sup> and the 5<sup>th</sup> week and whose potential causes have not been detected. A similar outcome could be also determined by a Mirizzi syndrome, but in our case it is excluded because intra-operatively there was no inflammatory reaction that could justify the presence of a fistula between the gallbladder and the common hepatic duct. Once the gallbladder interposition is found, the surgical treatment consists in removing the gallbladder itself and the corresponding part of the common hepatic duct. The reconstruction is carried out by a Roux-en-Y hepaticojejunostomy with anastomosis at the hepatic hilum, positioning a biliary stent.

**KEY WORDS:** Gallbladder interposition - Common hepatic duct - Cholecystohepatic duct.  
Colecisti interposta - Dotto epatico comune - Dotto colecistoepatico.

**RIASSUNTO:** Colecisti interposta nel dotto epatico comune: una rara ma pericolosa anomalia. Caso clinico.

L. ROSATO, A. GINARDI, G. MONDINI

**Introduzione.** Le anomalie anatomiche della posizione della colecisti nel tratto biliare sono rare, ma possono essere molto pericolose durante la colecistectomia.

**Case report.** Un uomo di 48 anni presentava da due settimane dolore epigastrico intermittente, subittero, innalzamento degli enzimi di colesterasi e di citolisi epatica. Dopo aver eseguito una colangio-RM e una colangiopancreatografia endoscopica retrograda con papillotomia, il paziente è stato sottoposto a colecistectomia videolaparoscopica. Nel sospetto di colecisti interposta, si è proceduto alla conversione laparotomica con conferma della anomalia anatomica. È stata eseguita, quindi, una derivazione biliodigestiva con anastomosi termino-laterale su ansa alla Roux, tra la confluenza degli epatici e la quarta ansa digiunale, previo posizionamento di un tutore biliare. In decima giornata postoperatoria, dopo aver eseguito colangiografia di controllo e TC addominale, il catetere biliare è stato rimosso e il paziente è stato dimesso senza complicanze.

**Conclusioni.** L'interposizione della colecisti è una rara malformazione che si manifesta a seguito di una anomalia embrionale tra la quarta e la quinta settimana, senza una apparente causa. Un quadro simile può anche essere determinato da una sindrome di Mirizzi, ma nel nostro caso è stata esclusa perché intraoperatoriamente non è stata trovata una reazione infiammatoria, tale da giustificare la presenza di una fistola colecisto-coledocica. Quando si riscontra una interposizione della colecisti, il trattamento chirurgico consiste nell'asportare la colecisti con la corrispondente porzione di dotto epatico comune. La ricostruzione si esegue con una epatico-digiunoanastomosi su ansa defunzionizzata a Y secondo Roux all'ilo epatico e posizionando un tutore biliare.

### Introduction

Anomalies in the shape of the gallbladder (bilobate, hourglass shaped, phrygian cap shaped, floppy) are common and usually haven't a clinical relevance. However, anatomical anomalies of the gallbladder position in the biliary tract are rare. Despite lacking clinical significance, they

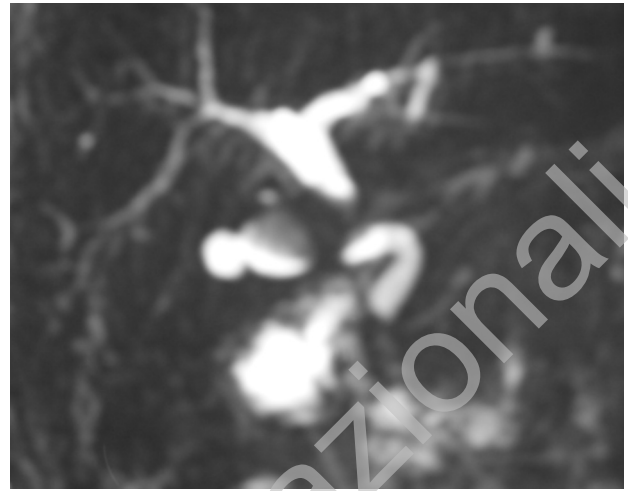could be very dangerous during cholecystectomy, particularly if an important inflammatory reaction is present.

This anatomical anomaly has been described in the past (1), but rarely properly reported. Therefore its actual existence has not been confirmed.

## Case report

A 48-year-old man presented with a 2-week history of intermittent epigastric pain, radiating to right hypochondrium, scleral jaundice and elevation of liver function tests with normal coagulation and haemochrome values. In the past he had no operations, injuries or allergies. The magnetic resonance cholangiogram (MRC) revealed a large gallstone in the gallbladder, no dilatation of the intrahepatic biliary tracts and a slight dilation of the first part of the common biliary duct. In addition, there was no visibility of the middle part of the biliary tract; however, the distal choledochus was still evident even though a microlithiasis and biliary sludge were suspected (Fig. 1). The Endoscopic Retrograde Cholangio-Pancreatography (ERCP) with sphincterotomy diagnosed an angle in the medial part of the choledochus without any anomalies of the common hepatic duct and nor evidence of gallstones after the sphincterotomy.

When the laparoscopic cholecystectomy has been performed, the gallbladder was found sclero-atrophic, enveloped by omentum and almost completely occupied by a single large stone. After removing the adhesions with omentum from the gallbladder, the hepatoduodenal ligament was opened. An anatomical structure going to the gallbladder was identified as the cystic duct; it was clipped and divided. While performing the dissection of the gallbladder bed, another duct

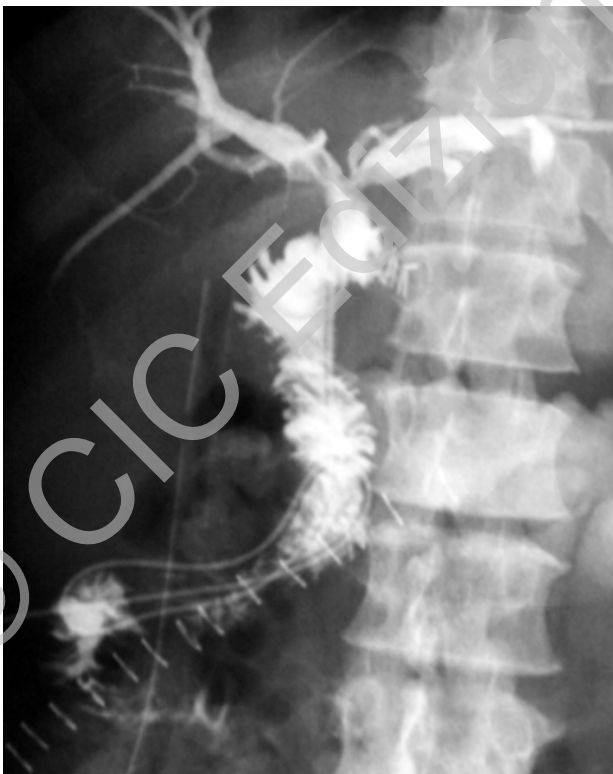

**Fig. 1 - The magnetic resonance cholangiogram (MRC): a large gallstone in the gallbladder, no dilatation of the intrahepatic biliary tracts, no visibility of the middle part of common hepatic duct.**

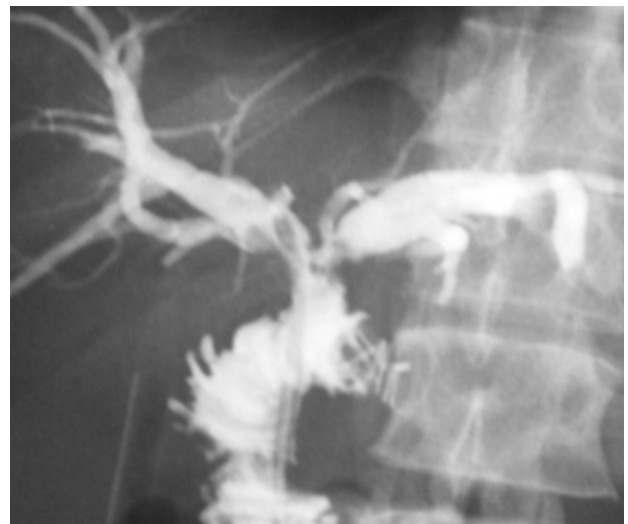was detected: it was entering the gallbladder. Given the unclear anatomical situation and the suspect gallbladder interposition, it has been decided to perform a laparotomy. It was executed in the right upper quadrant, under the costal margin. The anatomy of the region was carefully examined, and the presence of an interposition of the gallbladder in the biliary tract confirmed at about two centimeters from the hepatic hilus. After the total dissection of the gallbladder, a Roux-en-Y hepaticojejunostomy was executed, with an end to side anastomosis between the confluence of the hepatic ducts and the fourth loop of jejunum. The anastomosis was performed with an interrupted suture in 4/0 Sorbifil on a biliary stent that exited from the wall of the jejunum after running through it for about 20 centimeters from the anastomosis. This stent was then fixed to the abdominal wall. No leakage from the hepaticojejunostomy was observed after injecting about 15 ml of saline solution through the biliary stent.

An end-to-side enteroenterostomy was performed in the Roux-en-Y limb at about 60 centimeters from the hepaticojejunostomy.

A postoperative cholangiography through the biliary stent (Figs. 2, 2a) and a CT abdominal scan, executed after 10 days from



**Fig. 2 - Postoperative cholangiography through the biliary stent which shows the reconstruction with Roux-en-Y hepaticojejunostomy without bile leakage.**



**Fig. 2a - Detail of hepaticojejunostomy.**

the operation, revealed a regular retrograde opacification of the whole biliary tract and no evidence of bile leakage or intrabdominal collection. The biliary catheter was removed in the tenth postoperative day and the patient was discharged without complications.

Pathology: gallbladder's size of 4.5x2.5x1.5 centimeters, with moderately thickened walls, rough mucosa, follicular features and low grade focal dysplasia, presenting two openings at the extremities of the pouch.

## Discussion

The gallbladder interposition is such a rare anomaly that its existence itself has been often questioned (2). Nevertheless some sporadic cases have been recently documented (3-7). In a series of 1410 cholecystectomies, only one case can be actually classified as a cholecystohepatic duct (8). This malformation seems to arise from an embryonic anomaly that occurs between the 4<sup>th</sup> and the 5<sup>th</sup> week and whose potential causes have not been detected (9,10). An outcome similar to the gallbladder interposition could be also determined by a fistula between the gallbladder and the common hepatic duct caused by a chronic inflammatory process, such as the one resulting from Mirizzi syndrome (3,11,12).

Our case is documented by the magnetic resonance cholangiogram (Fig. 1). However, the MRC had initially led us to mistakenly assume that a voluminous gallbladder stone had strongly compressed the hepatic duct. Even the endoscopic retrograde cholangiogram only diagnosed an angle of the middle part of the common hepatic duct. During the laparoscopic cholecystectomy the unclear anatomical picture and the doubt of a gallbladder interposition induced us, to execute a laparotomy. This decision enabled us to corroborate our suspect and avoid surgical procedure potentially highly dangerous (13).

The case reported has to be identified as an uncommon congenital anomaly consisting of an interposition of the gallbladder in the common hepatic duct. The possibility of a Mirizzi Syndrome with cholecystobiliary fistula has to be excluded because, even though the anatomical picture is similar to Type II of McSherry classification (11) or to Type III-IV of Csendes classification (12), intra-operatively there was no inflammatory reaction that could justify the presence of a fistula (Fig. 3).

Once the anomaly is found, the surgical treatment




Fig. 3 - Cholecystohepatic duct corresponding to Type III-IV of Csendes classification and to Type II of McSherry classification.

consists of removing the interposed gallbladder and, consequently, the corresponding part of the common hepatic duct. The reconstruction is necessarily carried out by a Roux-en-Y hepaticojejunostomy. The anastomosis needs to be executed at the hepatic hilum level in order to exploit the greater width of the bile duct and not to end up with a non-vascularized stump of bile duct. The latter case would result in a stenosis of the anastomosis secondary to undetected duct ischemia, more frequent in low bilioenteric anastomosis (14). The Roux en Y loop needs to be long enough: at least 60 centimeters from the hepaticojejunostomy. It is appropriate to position a biliary stent, which exits from the wall of the jejunum after running about 20 centimeters from the anastomosis; this stent is then fixed to the abdominal wall. The graft of expanded polytetrafluoroethylene (ePTFE) or of jejunal tube interposition to repair bile duct defects is feasible, as described in some still experimental studies (15,16). Currently, after radical resection of gallbladder interposition, a wide hilar hepaticojejunostomy is a safe, effective and durable reconstructive technique that can be performed at any age and may help to minimize the long-term risk of complications.

## References

1. Kehr H. Eine selbste anomalie der gallengänge. Munchen Med Wech 1902; 49: 229.
2. Bismuth H, Mutricy J. Anomalies des Voies Biliaires. In: Encyclopédie Médico- Chirurgicale, Techniques chirurgicales appareil digestif, Elsevier Masson, Paris 1988; 40-905: 1-8.
3. Jackson JB, Kelly TR. Cholecystohepatic duct: case report. Ann Surg 1964; 159: 581-584.
4. Gergely M, Csipö L, Györy-Kiss F. Interposition of the gallbladder: a rare congenital malformation of the extrahepatic bile ducts. Acta Chir Acad Sci Hung 1979; 20(4): 335-340.

5. Walia HS, Abraham TK, Baraka A. Gallbladder interposition: a rare anomaly of the extrahepatic ducts. *Int Surg* 1986; 71(2): 117-121.
6. Stringer DA, Dobranowski J, Ein SH, Roberts EA, Daneman A, Filler RM. Interposition of the gallbladder – or the absent common hepatic duct and cystic duct. *Pediatr Radiol* 1987; 17: 151-153.
7. Schofield A, Hankins J, Sutherland F. A case of cholecystohepatic duct with atrophic common hepatic duct. *HPB (Oxford)* 2003; 5(4): 261-263.
8. Champetier J, Letoublon C, Alnaason I, Charvin B. The cystohepatic duct: surgical implications. *Surg Radiol Anat* 1991; 13: 203-211.
9. Snyder WH. Malformations of the esophagus, small intestine and biliary tract. *Surg Clin N Amer* 1959; 39: 1151.
10. Gerwig WH Jr, Countryman LK, Gomez AC. Congenital absence of the gallbladder and cystic duct. *Ann Surg* 1961; 153:113.
11. McSherry CK, Ferstenberg H, Virshup M. The Mirizzi syndrome: suggested classification and surgical therapy. *Surg Gastroenterol* 1982; 1: 219-225.
12. Csendes A, Díaz JC, Burdiles P, Maluenda F, Nava O. Mirizzi syndrome and cholecystobiliary fistula: a unifying classification. *Br J Surg* 1989; 76(11): 1139-1143.
13. Nuzzo G, Giuliante F, Giovannini I, Ardito F, D'Acapito F, Velone M, Murazio M, Capelli G. Bile duct injury during laparoscopic cholecystectomy. Results of an Italian National Survey on 56591 cholecystectomies. *Arch Surg* 2005; 140: 986-992.
14. Mercado MA, Chan C, Orozco H, Tielve M, Hinojosa CA. Acute bile duct injury. The need for a high repair. *Surg Endosc* 2003; 17(9): 1351-1355.
15. Trentini EA, Crema E, Llanos JC, Lerco MM, Magna LA, Leonardis LS. Biliary tract reconstruction using jejunal tube: an experimental study in dogs. *Hepatobiliary Pancreat Dis Int* 2009; 8(2): 179-185.
16. Ren W, Shi D. Experimental study on repair of bile duct defects with expanded polytetrafluoroethylene. *Zhongguo Xiu Fu Chong Jian Wai Ke Za Zhi* 2001; 15(5): 305-307.