

## Duplex ultrasound and magnetic resonance imaging of the supra-aortic arches in patients with non recurrent inferior laryngeal nerve: a comparative study

F. TARTAGLIA, S. BLASI, L. TROMBA, M. SGUEGLIA, G. RUSSO, F.M. DI MATTEO, G. CARBOTTA, F.P. CAMPANA, A. BERNI

**SUMMARY:** Duplex ultrasound and magnetic resonance imaging of the supra-aortic arches in patients with non recurrent inferior laryngeal nerve: a comparative study.

F. TARTAGLIA, S. BLASI, L. TROMBA, M. SGUEGLIA, G. RUSSO, F.M. DI MATTEO, G. CARBOTTA, F.P. CAMPANA, A. BERNI

**Background.** *Non-recurrent inferior laryngeal nerve (NRILN) is usually discovered during thyroid surgery. It is often associated with vascular abnormalities that can be detected with magnetic resonance imaging (MRI) or duplex ultrasound scan. The aim of this study was to compare the diagnostic sensitivity of ultrasonography with MRI to identify the vascular abnormalities associated to NRILN.*

**Patients and methods.** *We revised 2713 total thyroidectomies to select patients with NRILN. The NRILN was identified in 17 patients (0,6%). A postoperative ultrasonic duplex scanning and a MRI was performed in 15 cases as 2 patients refused to submit to the exams.*

**Results.** *At MRI an unique origin of common carotid trunk and a concomitant aberrant retroesophageal subclavian right artery was showed in 11 patients. In 2 cases vascular abnormality consisted in separated origin of supra-aortic arteries. At duplex ultrasound scan only in 2 patients was impossible to identify vascular abnormalities detected at MRI. The diagnostic sensitivity of duplex ultrasound was 84,6%.*

**Conclusions.** *Preoperative duplex ultrasound is a non invasive method with high diagnostic sensitivity that can easily complete the preoperative thyroid ultrasonography.*

**RIASSUNTO:** Ecocolor-Doppler e risonanza magnetica dei vasi epiaortici in pazienti con nervo laringeo inferiore che non ricorre: metodiche a confronto.

F. TARTAGLIA, S. BLASI, L. TROMBA, M. SGUEGLIA, G. RUSSO, F.M. DI MATTEO, G. CARBOTTA, F.P. CAMPANA, A. BERNI

**Introduzione.** *Il nervo ricorrente che non ricorre (NRILN) è un'anomalia anatomica del decorso del nervo laringeo inferiore identificata nella maggior parte dei casi intraoperatoriamente in corso di interventi di chirurgia tiroidea. Il NRILN si associa ad anomalie vascolari che possono essere individuate mediante angio-RM e con ecocolor-Doppler dei vasi epiaortici. Abbiamo confrontato sensibilità e accuratezza dell'ecocolor-Doppler rispetto all'angio-RM nello studio di tali anomalie.*

**Pazienti e metodi.** *Abbiamo revisionato la nostra casistica costituita da 2713 tiroidectomie totali per selezionare pazienti con NRILN. Il NRILN è stato individuato in 17 pazienti (0,6%). Abbiamo sottoposto 15 pazienti allo studio post-operatorio dei vasi epiaortici mediante ecocolor-Doppler e angio-RM; due pazienti hanno rifiutato il consenso allo studio.*

**Risultati.** *L'angio-RM ha evidenziato in 11 pazienti che le arterie carotidi comuni originavano da un tronco comune a partenza dall'arco aortico con concomitante arteria succlavia retroesofagea. In due pazienti l'anomalia vascolare consisteva nell'origine separata dei vasi epiaortici dall'arco aortico. L'ecocolor-Doppler in due casi non ha confermato i risultati dell'angio-RM. La sensibilità diagnostica dell'ecocolor-Doppler è pertanto risultata essere dell'84,6%.*

**Conclusioni.** *L'ecocolor-Doppler costituisce una metodica non invasiva dotata di alta sensibilità che può essere utilizzata per completare lo studio tiroideo preoperatorio al fine di porre il sospetto di NRILN identificando le anomalie vascolari associate.*

**KEY WORDS:** Non-recurrent inferior laryngeal nerve - Total thyroidectomy - Duplex ultrasound - Magnetic resonance imaging.  
Nervo laringeo inferiore che non ricorre - Tiroidectomia totale - Ecocolor-Doppler - Risonanza magnetica.

### Introduction

First reported in 1823 by Stedman (1), non-recurrent inferior laryngeal nerve (NRILN) is an anatomical abnormality that can be associated with malformation of the aortic arch. In 1932, its importance from a surgical perspective was clearly shown by Pemberton (2), who accidentally dissected a NRILN mistaking it for a branch of the inferior thyroid artery (ITA).

"Sapienza" University of Rome, Italy  
Surgical Sciences Department

No financial support was received for this work from any company.

© Copyright 2011, CIC Edizioni Internazionali, Roma

Non-recurrent inferior laryngeal nerve, which is an uncommon finding, mainly occurs on the right side with an incidence ranging from 0.3 % to 1.6 %; conversely, its occurrence on the left side, where it can be associated with situs viscerum inversus (3,4), is exceptional (0.04%). It is usually discovered during thyroid surgery and failure to identify it, pre- or intra-operatively, can result in iatrogenic vocal cord paralysis. NRILN is often associated with vascular anomalies (absence of the right brachiocephalic trunk and presence of a retro-oesophageal right subclavian artery), which can be detected on MRI or duplex ultrasound scans.

In this study, drawing on our 15-year experience in thyroid surgery, we reviewed and compared imaging data, from duplex ultrasound and MRI studies, collected from patients with intraoperatively detected NRILN, taking in consideration the various aspects of this abnormality.

## Patients and methods

All the thyroidectomies (n=2713) performed by our group over the past 15 years (1995 to 2009) were reviewed in order to select patients with NRILN. All data relating to the surgical procedures used, histopathological findings, postoperative courses and first-year follow up were entered into a computerised database.

The thyroidectomised patients had a mean age of 50.7 years and a male:female ratio of 1:5. The NRILN cases were classified into different types according to Soustelle's 1976 classification (5). Three anatomical variants of NRILN are described: in Type 1, the NRILN arises directly from the cervical vagus and runs together with the vessels of the superior thyroid peduncle; in Type 2A, it follows a transverse path, running parallel to and then over the trunk of the ITA, while in Type 2B its transverse path takes it parallel to and then under the trunk, or between the branches, of the ITA (Fig. 1).

All the patients with NRILN were invited to undergo postoperative duplex ultrasound and MRI scans of the supraortic arches with the aim of comparing the results of the two imaging procedures.

The purpose of the duplex ultrasound scan was to establish whether the right brachiocephalic trunk was absent and to look for a retro-oesophageal right subclavian artery.

## Results

A NRILN was identified in 17 of the 2713 patients (0.6%), 13 females and 4 males. In all cases the abnormality was on the right side. Two patients had a classic Type 1 abnormality (Fig. 2), 14 a classic Type 2A abnormality (Fig. 3) and one a Type 2B abnormality in which the nerve, after following a transverse path, passed under the trunk of the ITA (Fig. 4).

Postoperative duplex ultrasound and MRI scans were performed in 15 cases as two patients refused to undergo these examinations.

In two cases, no vascular abnormalities could be identified by either imaging procedure.

In 11 patients, MRI disclosed a single origin of the

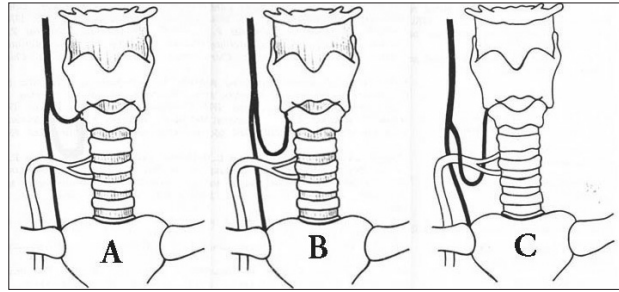


Fig. 1 - Schematic presentation of the three types of NRILN. A: Type 1. B: Type 2A. C: Type 2B.



Fig. 2 - Type 1 NRILN. CCA: common carotid artery.

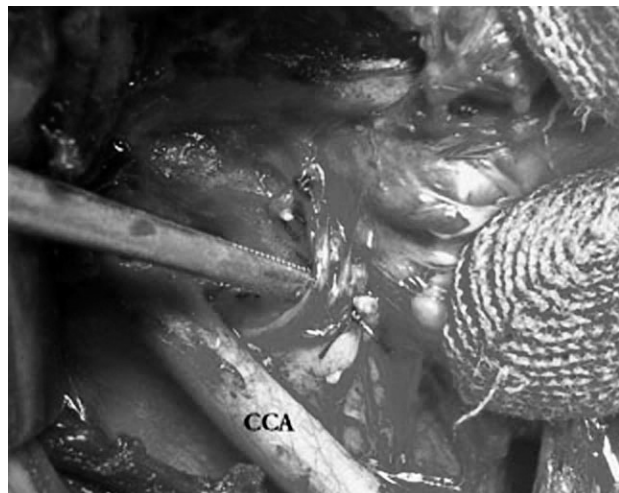


Fig. 3 - Type 2A NRILN. CCA: common carotid artery.

common carotid trunk, which arose from the aortic arch, and a concomitant aberrant retro-oesophageal subclavian right artery (Fig. 5). Two of these patients had a preoperative history of dysphagia. These were the only two

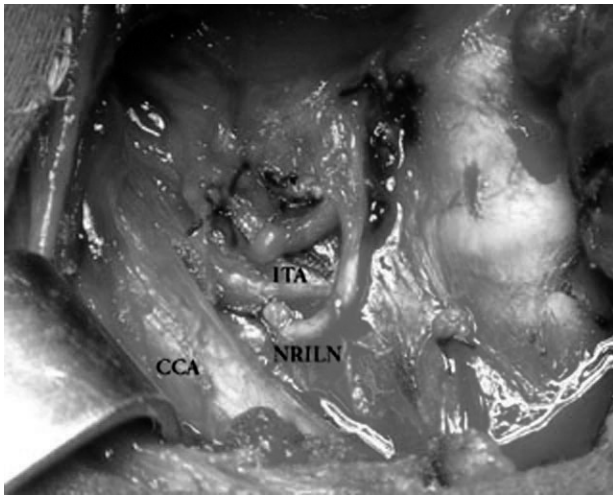


Fig. 4 - Type 2B NRILN. CCA: common carotid artery. ITA: inferior thyroid artery.

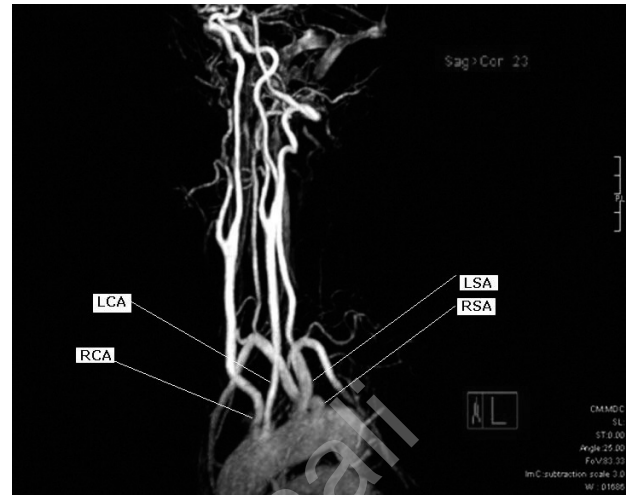


Fig. 6 - MRI angiogram. Separate origin of supraortic arteries. RCA: right carotid artery. LCA: left carotid artery. LSA: left subclavian artery. RSA: right subclavian artery.

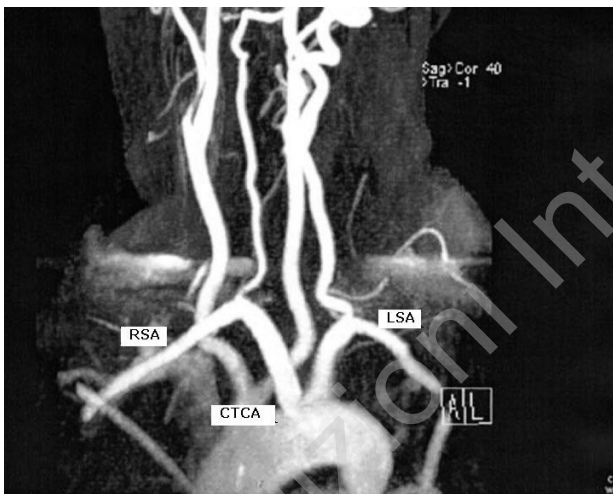


Fig. 5 - MRI angiogram. Single origin of the common carotid trunk from the aortic arch and concomitant aberrant retro-oesophageal subclavian right artery. RSA: right subclavian artery. CTCA: common trunk of carotid arteries. LSA: left subclavian artery.

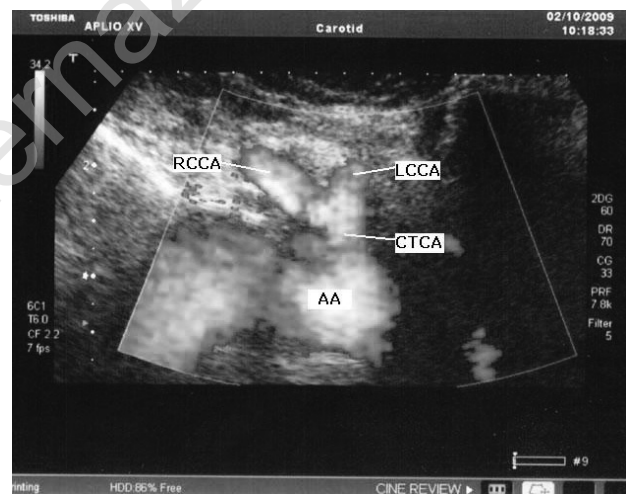


Fig. 7 - Duplex ultrasound scan. RCCA: right common carotid artery. LCCA: left common carotid artery. CTCA: common trunk of the carotid arteries. AA: aortic arch.

cases to undergo a preoperative barium swallow test, which revealed compression of the oesophagus on the posterior margin.

In two cases the vascular abnormality consisted of separate origins of the supraortic arteries emerging in the following order from right to left: right common carotid artery, left common carotid artery, left subclavian artery and right subclavian artery. The latter showed a retro-oesophageal course (Fig. 6).

Duplex ultrasound scanning confirmed the MRI data (Figs. 7,8). In only two patients was duplex ultrasound

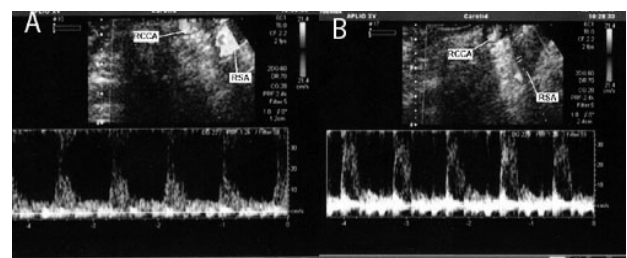


Fig. 8 Duplex ultrasound scan. RCCA: right common carotid artery. RSA: right subclavian artery. The flow in the right carotid artery is registered in A. The flow in the subclavian artery is registered in B.

unable to identify vascular abnormalities detected on the MRI angiogram.

No patient had vocal cord deficit.

## Discussion

The dual abnormality, vascular and neural, characteristically encountered in patients with NRILN can be explained by an embryological error. The development of the neck and of the upper part of thorax depends on the embryogenesis of the aortic arches, which differentiate at the end of the first month of development (6).

The inferior laryngeal nerves (ILNs) are derived from the sixth branchial arch. When the heart descends as the embryo elongates, these nerves pass beneath the sixth aortic arch and ascend to the larynx. In normal evolution, the fifth left and right aortic arches, as well as part of the sixth right aortic arch, regress. As a result the ILNs follow a different recurrent courses towards the cricothyroid membrane. The ILN on the right side runs under the fourth arch which will become the right subclavian artery, while on the left side it runs under the distal part of the sixth arch (ductus arteriosus) and under the fourth arch which will form the aortic arch (7).

However, if the fourth right aortic arch disappears, the right ILN reaches the cricothyroid membrane directly, resulting in a NRILN. In this circumstance, the right subclavian artery originates from a point distal to the left subclavian artery, directly from the aortic arch and crosses the mediastinum behind the oesophagus to reach the right axillary area (8). A NRILN occurring on the left side is due to the presence of three developmental abnormalities: a right aortic arch, an aberrant subclavian artery and finally an absent ductus arteriosus (9). Henry et al. described two cases of left NRILN in patients with complete situs viscerum inversus and a left retro-oesophageal subclavian artery (10). Two additional cases were discussed by Feind in 1988 but were not confirmed (11).

Recently, Fellmer et al. reported, a true case of left NRILN caused by a right aortic arch, an aberrant left innominate artery and the absence of a ductus arteriosus due to the presence of truncus arteriosus communis (12).

Kieffer et al. reported that aberrant subclavian artery is associated with multiple vascular abnormalities and ischaemic vascular diseases such as thrombosis, distal embolism, aneurysmal thoracic aorta and aneurysm of the aberrant artery (13).

Kobayashi et al. described the first case of NRILN associated with aplasia of the bilateral posterior communicating arteries composing the circle of Willis, in addition to an aberrant subclavian artery, in a patient with a symptomatic occlusion of the right internal carotid artery (14). The English literature contains descriptions of

NRILNs without vascular abnormalities as genuine entities (15) and in the course of our experience we have encountered two similar cases.

Some authors describe structures that can be confused with NRILNs during neck surgery. Anastomotic branches between the cervical sympathetic chain and the ILN have been reported. These can spring from the middle cervical sympathetic ganglion, the inferior cervical ganglion or the stellate ganglion. The anastomotic branch between the sympathetic trunk and ILN is usually thin. It can resemble the NRILN in its diameter and course and the two can sometimes be confused (16). In a morphological study of adult human necks the rate of occurrence of this anastomotic branch was found to be 17.3% (17), although we have never encountered it in our clinical practice.

Electrical identification and intraoperative monitoring of the ILN, to verify its functional integrity, has been proposed by some authors as a routine adjunct to the gold standard of visual nerve identification (18,19). In our experience, the need for this kind of technique has never arisen, even in cases with neural abnormalities, the nerve always proving easily detectable by digital examination and taking into consideration the relevant anatomical landmarks.

Preservation of a recurrent ILN during thyroid surgery is, indeed, crucially important since iatrogenic injury to this nerve, or to its branches, can have severe consequences: vocal cord paralysis or, in the worst cases, tracheostomy. Therefore it is necessary to look for, identify and expose the nerve, carefully following its course.

It is important to perform a dissection following the plane close to the nerve composed of soft connective tissue that can turn sclerotic as a result of thyroiditis or previous surgery. In this way anatomical integrity is guaranteed. To preserve the nerve, our approach is to uncover the nerve, exposing its anterior face along its cervical length until its entrance into the larynx, behind the margin of the inferior pharyngeal constrictor muscle (20).

In many cases, the ILN can be located below the ITA by means of digital palpation, exerting upward-medial traction on the thyroid parenchyma.

When it proves impossible to locate the nerve in this way, it is necessary to open the anterior layer of the perithyroid sheath below the ITA and to look carefully for the nerve which follows an upwards oblique course.

When the ILN cannot be located in the anatomical triangle formed by the common carotid artery, trachea and ITA, a NRILN must be suspected.

Therefore, in our opinion, investigation of vascular abnormalities should be performed in all patients prior to thyroidectomy in order to prevent vascular accidents and life-threatening events.

Devèze et al. showed that duplex ultrasound scanning is a simple non-invasive method of identifying patients with

the arterial abnormalities associated with NRILN. According to these authors, this method, able to diagnose the absence of the brachiocephalic artery, can easily be added to the thyroid or parathyroid ultrasonography that is often performed in preoperative thyroid assessment (8). In their experience, duplex ultrasound examination failed to disclose the brachiocephalic artery in 12 patients who had an operative diagnosis of right NRILN. Therefore, in their study, postoperative duplex scanning diagnosed the vascular abnormalities with a sensitivity and predictive value of 100%. We agree with Devéze that the main limitation of duplex ultrasonography is linked to the patient's morphology, as it is less effective in the obese.

The aim of this paper was to compare the diagnostic reliability and sensitivity of ultrasonography and MRI in identifying the vascular abnormalities associated with NRILN. Two of the 17 patients with NRILN identified in our patient series refused to take part in this study. On MRI a single origin of the common carotid trunk from the aortic arch and a concomitant aberrant retro-oesophageal subclavian right artery were shown in 11 patients.

In two cases, the vascular abnormalities consisted of separate origins of the supraortic arteries; in particular, the right subclavian artery arose from a point distal to all the other trunks and passed behind the oesophagus. MRI identified no vascular abnormality in two patients; accordingly, the duplex ultrasound scans of these two patients were normal.

In 13 cases, duplex ultrasonography showed the absence of brachiocephalic artery. Thus the diagnostic sensitivity of this technique, in our patient series, was 84.6%. In view of this finding we now routinely perform duplex ultrasound scans of the supraortic arches during preoperative thyroid assessment to identify patients with arterial abnormalities, such as absence of the brachiocephalic artery on the right side. This condition can suggest the presence of NRILN.

We conclude that preoperative duplex ultrasonography of the vessels of the neck is a non-invasive method with high diagnostic sensitivity that can easily be added to the preoperative ultrasound thyroid work up in order to look for the vascular anomalies potentially associated with NRILN. We suggest that this preoperative diagnostic assessment should be used in all patients to be submitted to thyroidectomy and not only those who use their voice professionally or who already have left recurrent nerve paralysis as proposed by Deveze et al. (8)

Even though the NRILN is a rare occurrence, careful and diligent intraoperative surgical approaches are necessary to detect and preserve the nerve.

## Acknowledgements

Thanks to Mrs Catherine Wrenn for her assistance and for the translation of the paper.

## References

1. Stedman GW. A singular distribution of some of the nerves and arteries of the neck and the top of the thorax. *Edinb Med Surg J* 1823;19:564.
2. Pemberton J, Beaver MG. Abnormality of the right recurrent laryngeal nerve. *Surg Gynecol Obstet* 1932;54:5994-5995
3. Henry JF, Audiffret J, Denizot A, Plan M. The nonrecurrent inferior laryngeal nerve : review of 33 cases , including two on the left side . *Surgery* 1988 Dec 104(6) :977-84
4. Toniato A, Mazzarotto R, Piotta A, Bernante P, Pagetta C, Pelizzo MR. Identification of the nonrecurrent laryngeal nerve during thyroid surgery: 20-year experience. *World J Surg*. 2004 Jul 28(7):659-661
5. Soustelle J, Vuillard P, Tapissier J, et al La non recurrence du nerf larynge inferieur : a propos de 9 cas. *Lyon Chir* 1976;72:57-71
6. Lescalié F, Peret M, Reigner B, Cronier P, Pillet J. Reconstruction of an abnormal artery observed in an 11 mm embryo : considerations on the embryologic origin of the subclavian artery. *Surg Radiol Anat* 1992;14(1):71-79
7. Avisse C, Marcus C, Delattre JF, Marcus C, Calliez-Tomasi JP, Palot JP, Ladam-Marcus V, Menanteau B, Flament JB. Right nonrecurrent inferior laryngeal nerve and arteria lusoria : the diagnostic and therapeutic implications of an anatomic abnormality. Review of 17 cases. *Surg Radiol Anat* 1998;20(3):227-32
8. Deveze A, Sebag F, Hubbard J, Jaunay M, Maweja S, Henry JF. Identification of patients with a non-recurrent inferior laryngeal nerve by duplex ultrasound of the brachiocephalic artery. *Surg Radiol Anat* 2003 Jul-Aug; 25(3-4):263-269.
9. Sanders G, Uyeda RY, Karlan MS. Nonrecurrent inferior laryngeal nerves and their association with a recurrent branch. *Am J Surg* 1983 Oct 146(4):501-503
10. Henry JF, Audiffret J, Plan M. The nonrecurrent inferior laryngeal nerve. Apropos of 19 cases including 2 on the left side *J Chir (Paris)* 1985 Jun-Jul ; 122 (6-7): 391-397
11. Feind CR Discussion on "The nonrecurrent inferior laryngeal nerve :review of 33 cases, including two on the left side" . *Surgery* 1988 Dec 104(6) :983.
12. Fellmer PT, Böhner H, Wolf A, Röher HD, Goretzki PE. A left nonrecurrent inferior laryngeal nerve in a patient with right-sided aorta, truncus arteriosus communis, and an aberrant left innominate artery. *Thyroid* 2008 Jun;18(6):647-649.
13. Kieffer E, Bahnini A, Koskas F. Aberrant subclavian artery : surgical treatment in thirty-three adult patients. *J Vasc Surg* 1994 Jan;19(1):100-109.
14. Kobayashi M, Yuta A, Okamoto K, Majima Y. Non-recurrent inferior laryngeal nerve with multiple arterial abnormalities *Acta Otolaryngol* 2007 Mar;127(3):332-336
15. Tateda M, Hasegawa J, Sagai S, Nakanome A, Katagiri K, Ishida E, Kanno R, Hasegawa T, Kobayashi T. Nonrecurrent inferior laryngeal nerve without vascular abnormality as a genuine entity. *Tohoku J Exp Med*. 2008 Oct;216(2):133-7.

16. Raffaelli M, Iacobone M, Henry JF. The "false" nonrecurrent inferior laryngeal nerve. *Surgery* 2000 Dec ;128(6):1082-7
  17. Maranillo E, Vazquez T, Quer M, Niedenführ MR, Leon X, Viejo F, Parkin I, Sanudo JR. Potential structures that could be confused with a nonrecurrent inferior laryngeal nerve: an anatomic study. *Laryngoscope*. 2008 Jan;118(1):56-60
  18. Alon EE, Hinni ML. Transcricothyroid electromyographic monitoring of the recurrent laryngeal nerve. *Laryngoscope* 2009 Oct ;119 (10) :1918-21
  19. Dralle H, Sekulla C, Lorenz K, Brauckhoff M, Machens A; German IONM Study Group. Intraoperative monitoring of the recurrent laryngeal nerve in thyroid surgery. *World J Surg* 2008 Jul;32(7):1358-66
  20. Campana FP, Marchesi M, Biffoni M, Tartaglia F, Nuccio G, Stocco F, Jaus MO, Nobili Benedetti R, Faloci C, Mastropietro T, Millarelli M. Total thyroidectomy technique: suggestions and proposals of surgical practice. *Ann Ital Chir*. 1996 Sep-Oct;67(5):627-35.
- 

© CIC Edizioni Internazionali