

## Multifocal pyomyositis and meningitis after bone marrow biopsy in a diabetic patient

C. CHARITIDIS<sup>1</sup>, N. STAMPOLIDIS<sup>2</sup>, E. FALIDAS<sup>1</sup>, E. TSOCHATARIDIS<sup>2</sup>

**SUMMARY:** Multifocal pyomyositis and meningitis after bone marrow biopsy in a diabetic patient.

C. CHARITIDIS, N. STAMPOLIDIS, E. FALIDAS, E. TSOCHATARIDIS

*Primary or tropical pyomyositis is a subacute infection of the skeletal muscle complicated by abscess formation. The disease is rare in the temperate climates and often misdiagnosed because of the vague clinical presentation. We herein report a case of a 38-year-old diabetic patient with a history of recent bone marrow biopsy presented multifocal primary pyomyositis complicated by meningitis.*

**RIASSUNTO:** Piomiosite multifocale e meningite dopo biopsia di midollo osseo in un paziente diabetico.

C. CHARITIDIS, N. STAMPOLIDIS, E. FALIDAS, E. TSOCHATARIDIS

*La piomiosite primaria o tropicale è una infezione subacuta dei muscoli scheletrici, con formazione di ascessi. La malattia è rara nei climi temperati e spesso la diagnosi si rende difficile per la sintomatologia non specifica.*

*Riportiamo il caso di un paziente diabetico di 38 anni con una storia di recente biopsia di midollo osseo che ha presentato un quadro clinico di piomiosite primaria complicata da meningite.*

**KEY WORDS:** Primary pyomyositis - Tropical pyomyositis - Multifocal pyomyositis - Diabetes - Meningitis.  
Piomiosite primaria - Piomiosite tropicale - Piomiosite multifocale - Diabete - Meningite.

### Introduction

Tropical pyomyositis is a primary subacute bacterial infection of the muscles progressively leading to the formation of abscesses. The disease is rare in the temperate climates and often misdiagnosed because of the vague and nonspecific symptomatology. We present a case of a 38-year-old diabetic patient with multifocal pyomyositis of the gluteal, iliopsoas, deltoid and quadriceps muscles complicated by meningitis after a bone marrow biopsy.

### Case report

A 38-year-old man presented at the emergency department with a 6-day history of malaise, fever, lumbar and left hip pain. The pa-

tient had a history of minor mental retardation, diabetes mellitus type 2 and goiter. He underwent a left ilium bone marrow biopsy 15 days before in order to investigate a persistent anemia and eosinophilia.

Physical examination revealed lumbar pain and painful limitation of the left hip joint. His temperature was elevated (39.8°C) and the relatives referred intense chills before the admission to the hospital. The blood pressure was 85/45 mmHg and the pulse was 110 beats/min regular. Remarkable laboratory findings included leukocytosis (WBC: 14700/mm<sup>3</sup> with 79% neutrophils, 11% eosinophils), C-reactive proteina: 7.34 mg/dl, Urea:163 mg/dl, Creatinine:1.8 mg/dl, hyperglycaemia (483 mg/dl) and high hemoglobin A1c (8.8%) Plain X-ray series of the chest and the abdomen were normal as well as abdominal ultrasound scan. There was no sign of inflammation at or near the entry point of the previously performed bone marrow biopsy.

Abdominal and pelvic computed tomography (CT) scan demonstrated multiple abscesses of the iliopsoas muscles and of the left gluteus maximus muscle (Figs.1, 2). Within the following 8 hours the abscess of the gluteus maximus was surgically drained. Cultures of the purulent material as well as blood cultures were positive for Methicillin-Sensitive-Staphylococcus Aureus (MSSA). Treatment with cloxacillin was initiated. Within the following 48 hours, the patient presented signs of meningeal irritation. The CT of the brain did not demonstrate abnormalities and lumbar puncture was carried out. Cerebrospinal fluid (CSF) was blurry and its cultures were also positive for MSSA. Ceftriaxone (2g) and dexametasone (10mg) were also administered as a single boost dose. Within the following five days,

Veterans Hospital of Athens, Greece

<sup>1</sup> First Department of General Surgery

<sup>2</sup> Second Department of General Surgery

© Copyright 2011, CIC Edizioni Internazionali, Roma

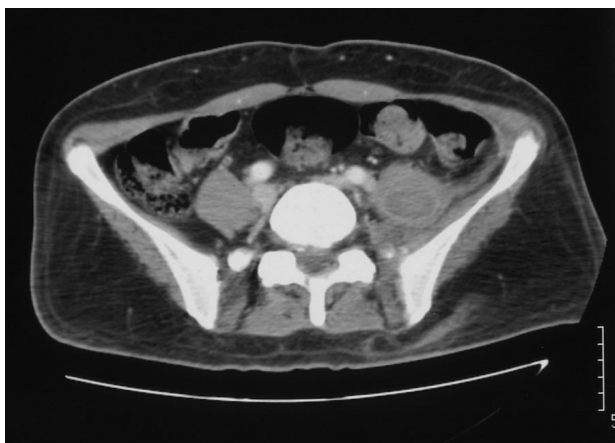

Fig. 1

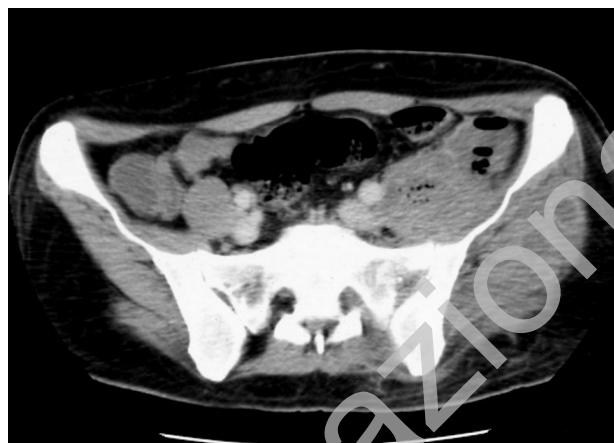

Fig. 2

Figs. 1, 2 - Abdominopelvic CT: abscess of the left iliopsoas muscle and multiple abscesses of the left gluteus maximus muscle on admission.

a clinical improvement was observed although pyrexia was still continuous. For that reason a surgical drainage of the iliopsoas abscess was performed. The patient remained without fever for the following three days.

On day 9 after admission, a swelling of the right shoulder occurred and a limitation of the passive and active movements of the joint was observed. A new CT scanning revealed a large abscess of the right deltoid muscle, another of the right quadriceps muscle (Figs. 3, 4) and a recurrence of the iliopsoas abscess. Amikacin was administered and surgical drainage was performed for the deltoid and quadriceps muscle abscess. A clinical improvement was rapidly observed and the patient was discharged 26 days after the initial admission.

## Discussion

Primary or tropical pyomyositis (PPM) is a rare subacute bacterial infection of the muscles that can lead to abscess formation. The disease commonly occurs in

the tropics but constitutes an emerging and often misdiagnosed condition in the temperate climates (1).

Primary pyomyositis is most common in the first and second decade of life with a slight male predominance (1). *Staphylococcus Aureus* is the most commonly implicated organism while other infectious agents such as *Streptococcus pyogenes*, *Streptococcus pneumoniae* and *Escherichia coli* are rarely found in cultures of blood or purulent material (1). At the time of the diagnosis, positive blood cultures have been reported in 29-38% of all patients and positive cultures of purulent material range from 21 to 41% of the cases (1, 2). In our case *S.aureus* was identified in blood, in purulent material and in cerebrospinal fluid cultures.

PPM usually involves a single muscle, although 16% of patients suffer from multifocal pyomyositis (1). The most common site of infection is the quadriceps muscle (26.3%), followed by the iliopsoas (14%), gluteal

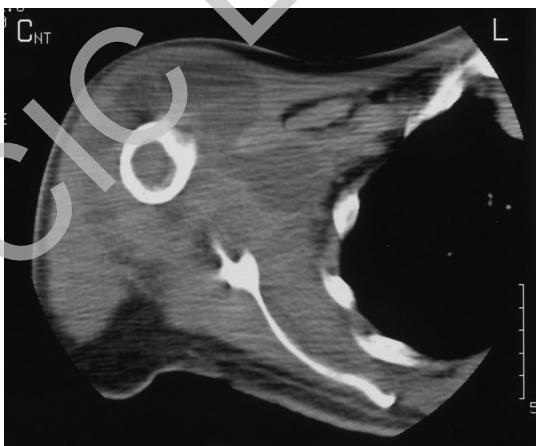


Fig. 3

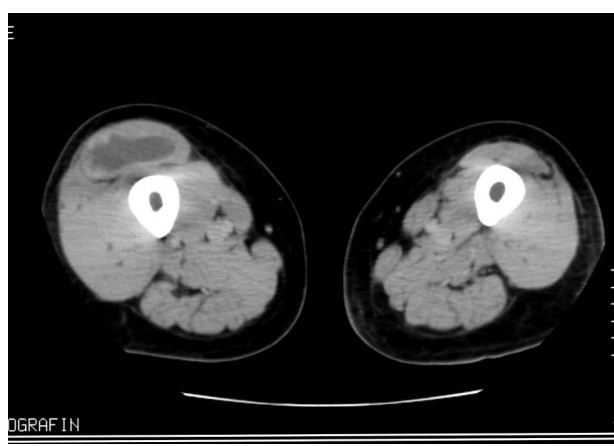


Fig. 4

Figs. 3, 4 - Abscess of the right deltoid muscle and of the right quadriceps muscle on day 9 of hospitalization.

(10.8%) and deltoid muscles (7.9%) (1). PPM of the iliopsoas is rare and the cases reported in the past were secondary infections due to adjacent tuberculosis of the spine or to iliac lymph nodes or associated with gastrointestinal or urinary tract infection (1). Initial involvement of iliopsoas muscle and gluteus maximus was the main cause of symptomatology in our case.

Many authors believe that PPM is a result of transitory bacteremia due to recent muscle trauma, although trauma is reported by less than 5% of the patients (1). Viruses or parasitic infections have been also described as possible etiologic factors of PPM (1). An underlying condition of immunosuppression such as malnutrition, autoimmune diseases, acquired immunodeficiency syndrome (AIDS), malignancies, intravenous drug use and chronic blood and liver diseases is usually discovered in patient's medical history (1, 2, 3). Diabetes increases susceptibility to infections and the incidence of PPM in diabetic patients ranges from 8% to 31% of cases (2, 4, 5). Our patient was diabetic with a poorly controlled glycaemic profile that contributed to increased susceptibility to the infection. Inflammation of the entry point of the bone marrow biopsy was not found.

Pyomyositis usually occur with three overlapping stages. The initial invasive stage begins with a cramping pain progressing in 'wooden stiffness' in a group of muscles with minimal signs of local inflammation. Low-grade fever, general malaise, mild leukocytosis and eosinophilia can also be found during this stage. By suppurative stage, abscesses have been formed and may be palpated as soft tissue masses while the overlying skin may be erythematous and warm. Systemic manifestations, local tenderness and functional disability can also be present. If PPM is not treated, it progresses to the late stage with predominant signs of systemic toxicity and septic shock. Half of the patients at this stage may have extramuscular complications such as pneumonia, empyema, pericarditis or meningitis, like in our case (6). Pyomyositis

of the iliopsoas muscle may be insidious considering the retroperitoneal position of the muscle and its proximity to intra-abdominal organs, the hip joint and the femoral nerve. Deep diffuse pain in the back, flank or hip may be present while the affected thigh is often held in flexion and extrarotation (1).

Routine laboratory exam results are not disease-specific and, therefore, rarely helpful. C-reactive protein may be elevated and leukocytosis with a left shift may be present while eosinophilia is rare in temperate climates (1, 4-7). Muscle enzymes levels are variable (5). In our case, the patient presented an unexplained eosinophilia and bone marrow biopsy was performed in order to investigate the hematologic disorder. It is not clear if the eosinophilia was a sign of a subacute staphylococcal infection and if the bone marrow biopsy caused a transitory bacteremia leading in abscess formation.

Magnetic resonance imaging (MRI) has the greatest diagnostic value, but CT, U/S, technetium and gallium scintigraphy are also used (1). Percutaneous drainage of the muscle abscesses can be achieved under U/S or CT-guidance (1).

At the invasive stage, pyomyositis can be treated effectively with antibiotics. Cloxacillin alone or in combination with an aminoglycoside in cases of immunocompromised patients are valid options while at suppurative stage, surgical or percutaneous drainage with concurrent use of antibiotic therapy is imperative; just like in our case. In cases of meningitis due to MSSA, cloxacillin or vancomycin is usually effective (8). Intravenous administration of antibiotics is administered for a period of 7 to 10 days because few days of clinical improvement or apyrexia do not mean definitive recovery, like in our case. For this reason, oral administration of appropriate antibiotic treatment is needed for a period of 5 to 6 weeks. Treatment of immunocompromised patients requires a longer period of intravenous and oral administration of antibiotics (1, 9).

## References

1. Bickels J, Ben-Sira L, Kessler A, Wientroub S. Primary pyomyositis. *J Bone Surg Am* 2002; 84 : A2277-A2286.
2. Patel SR, Oleginski TP, Perruquet JL, Harrington TM. Pyomyositis: Clinical features and predisposing conditions. *J Rheumatol* 1997;24:1734-1738.
3. Aki Z, Dagdas S, Akoz AG, Erdem EZ, Yilmaz M, Guler N, Ayli M, Alanoglu G, Ozet G. Bacterial pyomyositis in a patient with adult lymphoblastic leukaemia. *Haema* 2004;7(3):374-377.
4. Christin L, Sarosi GA. Pyomyositis in north America: case reports and review. *Clin Infect Dis* 1992; 15:668-677.
5. Seah MYY, Anavekar SN, Savige JA, Burrell LM. Diabetic Pyomyositis: An uncommon cause of painful leg. *Diabetes Care* 2004;24:1743-1744.
6. Chiedozi LC. Pyomyositis. Review of 205 cases in 112 patients. *Am J Surg.* 1979;137:255-9.
7. Fan HC, Lo WT, Chu ML, Wang OC. Clinical characteristics of Staphylococcal pyomyositis. *J Microbiol Immunol Infect* 2002; 35:121-124.
8. Chaudhuri A, Martinez-Martin P, Kennedy PG, Andrew Seaton R, Portegies P, Bojar M, Steiner I, EFNS Task Force. EFNS guideline on the management of community-acquired bacterial meningitis: report of an EFNS Task Force on acute bacterial meningitis in older children and adults. *Eur J Neurol* 2008 Jul;15(7):649-59.
9. Nizet VF. Myositis and pyomyositis. In: Long SS, Pickering LK, Prober CG, editors. *Principles and practice of pediatric infectious diseases*. New York NY: Churchill Livingstone; 1997. 517-23.