

G Chir. Vol. 26 - n. 5 - pp. 215-217
Maggio 2005

Rupture of an isolated true superficial femoral artery aneurysm: case report

A. SIANI, I. FLAISHMAN, F. NAPOLI, A. SCHIOPPA, A. ZACCARIA

SUMMARY: Rupture of an isolated true superficial femoral artery aneurysm: case report.

A. SIANI, I. FLAISHMAN, F. NAPOLI, A. SCHIOPPA, A. ZACCARIA

True isolated atherosclerotic aneurysm of the superficial femoral artery is a rare pathology. We report a case of ruptured superficial femoral artery aneurysms (SFAA) not associated with aortic, common femoral or popliteal artery aneurysms. An emergency surgical procedure was performed and, after endoaneurysmal branches ligation, a ePTFE graft interposition was performed.

The literature review shows a prevalence of rupture as compared with ischemic complications and the need for surgical repair in case of SFAA with diameter twice the normal vessel size. Early diagnosis and management are recommended because of the lower morbidity and mortality rates associated with elective surgery by comparison with emergency procedures.

RIASSUNTO: Rottura di un aneurisma isolato dall'arteria femorale superficiale: nostra esperienza.

A. SIANI, I. FLAISHMAN, F. NAPOLI, A. SCHIOPPA, A. ZACCARIA

L'aneurisma aterosclerotico isolato dell'arteria femorale superficiale è una patologia rara. Gli Autori descrivono il caso di un'uomo di 63 anni con un aneurisma dell'arteria femorale superficiale rotto, non associato ad altre lesioni aneurismatiche di aorta, femorale comune o poplitea. Il paziente era stato operato in urgenza e, dopo la messa a piatto della sacca e la legatura dei vasi collaterali a partenza da essa, si confezionava un innesto sostitutivo in ePTFE.

La revisione della letteratura evidenzia come in tale patologia prevalga la rottura rispetto alle complicanze tromboemboliche e come l'indicazione chirurgica venga in tutti i casi in cui l'aneurisma presenti un diametro almeno doppio del normale diametro del vaso. Diagnosi precoce e trattamento aggressivo sono auspicabili per la più bassa morbi-mortalità legata all'intervento in elezione rispetto all'intervento d'urgenza.

KEY WORDS: Aneurysm - Atherosclerosis - Superficial femoral artery. Aneurisma - Aterosclerosi - Arteria femorale superficiale.

Introduction

True isolated atherosclerotic aneurysm of the superficial femoral artery is relatively rare. Reports and specific informations regarding its incidence, clinical onset and clinical findings are limited, especially about their expanding year rate and diameter rupture.

We report a case of isolated ruptured superficial femoral artery aneurysm.

The literature concerning this pathology is reviewed and discussed.

Case report

A 63 year old man was admitted to our medical center for a symptomatic expanding painful mass in the middle third of right thigh. At admission, the patient was hemodynamically stable; he had not received any kind of therapy, and did not pay attention

to this mass until the admission.

The mass was tender and pulsatile, with ecchymosis of the surrounding soft tissues. The peripheral arterial pulses were normal, and no embolization or distal ischemia was present. An urgent Duplex scan and CT scan were performed showing a 9 cm aneurysm of the right superficial femoral artery (SFA), with evidence of rupture into the surrounding soft tissues (Fig. 1). The controlateral femoral artery was normal. No popliteal or abdominal aortic aneurysm were associated.

An urgent operation was performed, through an extensive approach to the superficial femoral artery at the Hunter's canal, and showed a true aneurysm of the midportion of vessel. The arterial segments proximal and distal to the aneurysm were clamped. No signs of infection were present; the large hematoma was evacuated and patent intrasaccular branches were ligated. A prosthetic interposition graft of 8 mm expanded polytetrafluorethylene (ePTFE) was performed.

The patient had an uneventfully postoperative course; without ischemic or embolic complications. Ultrasound duplex follow up at 6 and 12 months revealed the patency of the vascular reconstruction and no dilatation of the controlateral artery.

Discussion

Isolated atherosclerotic aneurysms of superficial femoral artery (SFAA) are rare. The onset, natural

Ospedale "S.Pietro" Fatebenefratelli - Roma
Unità Operativa di Chirurgia Vascolare ed Endovascolare
(Responsabile: Dott. A. Zaccaria)

© Copyright 2005, CIC Edizioni Internazionali, Roma

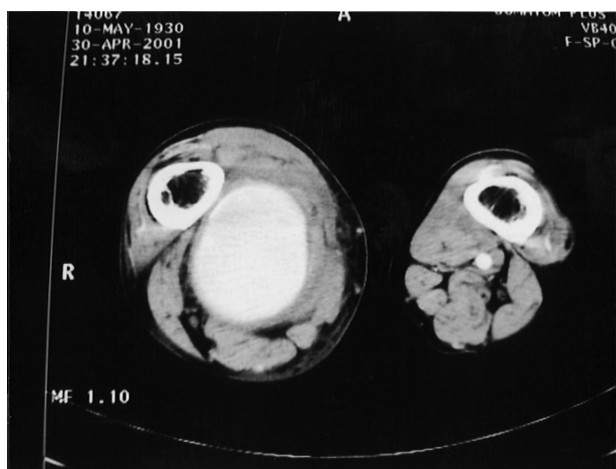


Fig. 1 - CT scan showing a 9 cm aneurysm of the right superficial femoral artery with evidence of rupture into the surrounding soft tissues.

history, complications and treatment of choice to obtain the best outcome are not yet codified.

Our experience and the literature review showed that these aneurysms occur generally in elderly patients, and that approximately 40% of these cases are associated with abdominal aorta and popliteal artery aneurysms (1, 2). These aneurysms can be frequently associated with infection or connective tissue diseases, like Ehlers-Danlos syndrome, or immunologic and inflammatory arteritis. In most cases the etiology has been attributed to an atherosclerotic degeneration even in the absence of clear manifestation of atherosclerotic lesions. In fact, in our case, no signs of atheromatous wall degeneration were present at the proximal and distal site of the artery and normal peripheral pulses were present.

In the majority of the cases these aneurysms are diagnosed following the onset of complications, with high incidence of morbidity and mortality (3). Rupture seems to be the most frequent complication in this type of aneurysms (4, 5); in fact, most of the SFA aneurysms are diagnosed at symptoms onset (35% of cases), as compared with patients with common femoral or popliteal artery aneurysms (7% of cases). In recent review of 17 true atherosclerotic SFA aneurysms, ischemic complications were less frequent

(35% thrombosis, 12% embolization) as compared to the rupture (65%) (1). The main problem remains the natural history of SFAA: the small number of reports does not provide data regarding the possible correlation between incidence of complications and aneurysm size, and the real year expansion rate.

These aneurysms, like those of the popliteal artery, can cause a lower limb threatening ischemia, especially when small in size, or rupture, suggesting that elective surgery represents the treatment of choice in consideration of the low mortality and morbidity rates. Usually, in patients with common femoral and popliteal artery aneurysms of 2-2,5 cm in size surgical procedure is indicated to prevent complications (6). SFAA seems to have the same indications and the surgical repair is recommended for symptomatic and asymptomatic aneurysms with 2.5 cm of diameter. In accord with Vasquez et coll., we believe that best criterion for surgical repair is the focal dilatation of at least twice the normal vessel diameter (7-9).

Repair of ruptured SFAA frequently required endoaneurysmal ligation of patent collateral branches (10). The graft material of choice is autogenous vein; ePTFE is a good alternative in elderly patients. An endovascular approach, through the placement of covered stent, is an evolving treatment, especially in high risk and in low life expectancy patients, though still of unknown durability.

Conclusion

Isolated SFAA are rare, but the high incidence of complications, like rupture, thrombosis or embolization, suggests that resection and grafting should be performed electively. The rupture seems to be the most frequent complication at presentation and fortunately it seldom leads to limb loss.

Surgical treatment with endoaneurysmal ligation of patent collateral branches and interposition grafting is the current preferred approach in consideration of the low mortality and morbidity rates. Endovascular approach can be an alternative choice treatment, but its mid and long term outcomes are still to be evaluated.

References

1. Rigdon EE, Monajjem N. Aneurysms of the superficial femoral artery: a report of two cases and review of the literature. *J Vasc Surg* 1992; 16: 790-3
2. Shortell CK, De Weese JA, Ouriel K, Green RM. Popliteal artery aneurysms: a 25 year surgical experience. *J Vasc Surg* 1991; 14:771-6
3. Atallah C, Al Hassan HK, Neglen. Superficial femoral artery aneurysm-an uncommon site of aneurysm formation. *Eur J Vasc Endovasc Surg* 1995;10:502-4
4. Bonelli U, Cerruti R, Arnuzzo L. Aneurysms of superficial femoral artery at the rupture stage. Two personal cases. *Min Chir* 1991; 46:1071-3

Rupture of an isolated true superficial femoral artery aneurysm: case report

5. Guegan H, Carles J, Janvier G, Videau J. Compressive thigh hematoma. A propos of a case of fissured superficial femoral aneurysm in megadolicho-arteries. Review of the litterature. *J Chir* 1991; 128: 247-50
 6. Dawson I, van Bockel JH, Brand R, Terpstra JL. Popliteal artery aneurysms. Long term follow-up of aneurysmal disease and results of surgical treatment. *J Vasc Surg* 1991;13:398-407
 7. Vasquez G, Zamboni P, Buccoliero F, Ortolani M, Berta R, Liboni A. Isolated true atherosclerotic aneurysms of superficial femoral artery. Case report and literature review. *J Cardiovasc Surg* 1993;34:511-2
 8. Jarrett F, Makaroun MS, Rhee RY, Bertges DJ. Superficial femoral artery aneurysms :an unusual entity? *J Vasc Surg* 2002; 36:571-4
 9. Levi N, Schroeder TV. Arteriosclerotic femoral artery aneurysms. A short review. *J Cardiovasc Surg* 1997, 38:335-8
 10. Metha M, Champagne B, Darling III RC, Roddy SP, Kreinberg PB, Ozsvath KJ, Paty PS, Chang BB, Shah DM. Outcome of popliteal artery aneurysms after exclusion and bypass:significance of residual patent branches mimicking type II endoleaks. *J Vasc Surg* 2004; 40:886-90
-