

G Chir Vol. 26 - n. 5 - pp. 201-205  
Maggio 2005

## Intestinal anisakiasis in Italy: a case treated by emergency surgery

C.M. MOSCHELLA, S. MATTIUCCI<sup>1</sup>, P. MINGAZZINI<sup>2</sup>, M. MONGARDINI<sup>3</sup>,  
A. CHEIN, D. MICCOLIS, C. MODINI

**SUMMARY:** Intestinal anisakiasis in Italy: a case treated by emergency surgery.

C.M. MOSCHELLA, S. MATTIUCCI, P. MINGAZZINI,  
M. MONGARDINI, A. CHEIN, D. MICCOLIS, C. MODINI

Anisakiasis is a fish-borne zoonotic disease.

A case of intestinal anisakiasis in a woman who had consumed raw marinated anchovies was reported. The intestinal localization resulted in occlusive acute abdomen which required an emergency surgical treatment. The histological examination of the eosinophilic granuloma removed from the resected colon revealed the presence of larval nematodes of the genus *Anisakis* as causative agents.

**RAISSUNTO:** Anisachiasi intestinale in Italia: un caso trattato con intervento chirurgico d'urgenza.

C.M. MOSCHELLA, S. MATTIUCCI, P. MINGAZZINI,  
M. MONGARDINI, A. CHEIN, D. MICCOLIS, C. MODINI

L'anisachiasi è una zoonosi parassitaria di origine ittica.

Viene riportato un caso di anisachiasi intestinale in una donna che aveva consumato alici crude marinate. La localizzazione intestinale ha determinato un quadro di addome acuto occlusivo, che ha richiesto il trattamento chirurgico d'urgenza. L'esame istologico del granuloma eosinofilo rinvenuto nel tratto di colon asportato ha rivelato la presenza di larve di nematodi del genere *Anisakis* quali agenti eziologici.

**KEY WORDS:** Intestinal anisakiasis - Parasitic zoonosis - Eosinophilic granuloma.  
Anisachiasi intestinale - Zoonosi parassitaria - Granuloma eosinofilo.

### Introduction

Anisakiasis is a fish-borne parasitic zoonosis caused by the marine ascaridoid nematodes belonging to the genus *Anisakis* (Dujardin, 1845). It is considered a visceral larva migrans disease caused by anisakid nematode larvae which invade the organs. They could migrate in humans but do not normally mature in them.

The nematodes belonging to this genus have a complex life cycle which involves marine mammals (mainly cetaceans) as definitive hosts and crustaceans, fish and cephalopods (mainly squids) as intermediate ones. Humans could acquire the infection

following ingestion of raw, undercooked or improperly processed (e.g. marinated) fish and squids parasitized by the larval stage of this nematode.

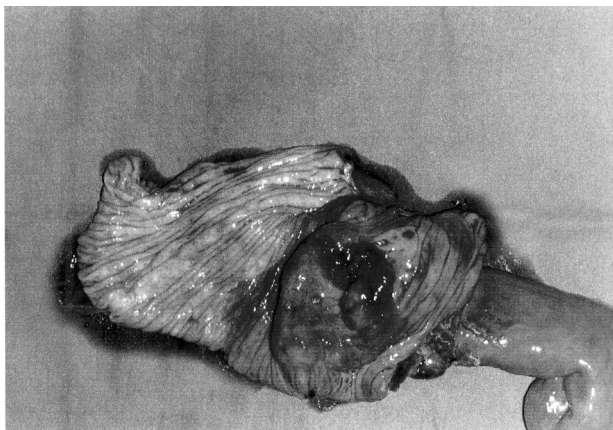
Based on the location of the lesions, various types of human anisakiasis have been identified: gastric or intestinal, which represents the majority of cases where larvae penetrate the tissues of the alimentary tract and is followed by severe pathology; extra-gastrointestinal, in which larvae enter the body cavities through the alimentary tract wall with resultant severe pathology; oropharyngeal, in which larvae only penetrate the tissues of the oropharyngeal cavity with resultant moderate pathology; transient luminal, in which anisakid larvae do not penetrate any tissue but dwell in the lumen of the alimentary tract for a period of time causing slight, transitory discomfort (32). Clinically, both acute and chronic infections have been described in gastric and intestinal locations. The histopathology of anisakiasis can be classified into four stages: first - phlegmon formation type; second - abscess formation type; third - abscess-granuloma formation type; and fourth - granuloma formation type (17).

University "La Sapienza" of Rome, Italy  
Department of Surgery "Pietro Valdoni"  
(Chief: Prof. A. Cavallaro)  
S.S. Emergency Surgery 1  
(Chief: Prof. C. Modini)

<sup>2</sup>Department of Public Health Sciences  
Parasitology Section  
(Chief: Prof. G.M. Fara)

<sup>3</sup>Department of Surgery "Pietro Valdoni"  
(Chief: Prof. A. Cavallaro)

<sup>4</sup>Department of Surgical Sciences  
UOC General Surgery L  
(Chief: Prof. F. Custureri)



**Fig. 1 - Surgical specimen: a tract of small bowel (28 cm) and of large bowel (20 cm) with stenotic ileo-caecal valve (extensively-edematous mucosa with severe thickening of the wall of the caecum).**

Anisakiasis was first recognized about 40 years ago in patients who had severe abdominal pain following ingestion of live *Anisakis* larvae in fish. Although most cases have been reported in Japan and Spain where large amounts of raw fish are consumed, the globalizing trend of eating sushi, sashimi, ceviche or boquerones is leading toward a worldwide increase in anisakiasis. In fact, more cases are now reported in other countries including Italy (3, 21, 24, 28, 33).

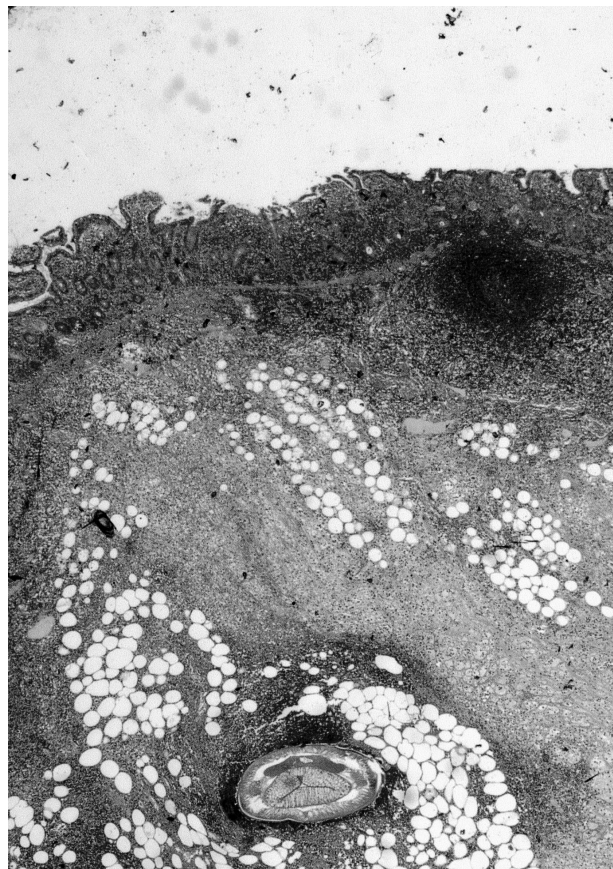
Human anisakiasis appears to be, however, underdiagnosed in Italy although considering the fact that larvae of *Anisakis* are widespread in several fish species in the Mediterranean Sea, with *A. pegreffii* mainly present in the Italian seas (22), and that consumption of raw fish and squids is becoming evermore common here.

The aim of this paper is to present a case report on complications of intestinal anisakiasis which required a surgical treatment in an emergency setting.

## Case report

A 37-year-old woman was brought to the Emergency Department of "Policlinico Umberto I" Hospital, University "La Sapienza" of Rome, with the complaints of acute abdominal pain in right lower quadrant (RLQ), nausea and emesis since few hours. She had no fever and was admitted with suspected acute appendicitis. Her past medical history was negative and the vital signs at admission were normal. Physical examination found abdominal distension and tenderness in RLQ of the abdomen. Bowel sounds were present. Laboratory tests revealed a WBC count of 9120/ $\mu$ L without eosinophilia. Abdominal X-rays showed few air-fluid levels in the small intestine and the ultrasonography detected dilation of the small bowel, distension of the ascending colon and asciti fluid.

With physical, laboratory and radiological findings suggesting an acute appendicitis, a surgical procedure by McBurney's incision was planned. During the surgical exploration, a strongly-suspected neoplastic lesion of the caecum was detected. The caecum was dilated with edematous, inflamed and thickened walls. Therefore a midline laparotomy was performed, followed by a right colectomy with hand-sewn, single-layer, end-to-end ileo-



**Fig. 2 - A cross-section of *Anisakis* in the intestinal submucosa under high resolution (H&E stain; original magnification x10).**

transverse anastomosis.

The postoperative period was uneventful; the patient was treated with 200 mg mebendazole b.i.d. for three days and was discharged after 10 days. At 3, 6, and 12 month follow-ups, the patient showed up in good condition with no abdominal symptoms.

The surgical specimen consisted of a tract of small bowel measuring 28 cm and of large bowel measuring 20 cm, with a 4 cm appendix. The ileo-caecal valve was stenotic and the mucosa appeared to be extensively edematous with severe thickening of the wall of the caecum to a length of 6 cm (Fig. 1).

The histological examination revealed, on the ileo-caecal valve towards the ileum and the colon, a transmural inflammation with marked infiltration of eosinophils, histiocytes, lymphocytes and plasmacells across all layers of the bowel wall and in the peri-intestinal fat tissue. In the submucosa, close to the ileo-caecal valve where the eosinophilic infiltration was most evident, we found an organoid structure surrounded by a thick, multi-layered cuticle a parasite nematode in a good state of preservation was found in there. Upon further investigation of the surgical specimen, two nodules, measuring 1.4 cm and 0.5 cm respectively, consisting of debris surrounded by a diffusely-calcified, fibrous-hyaline connective shell were found in the peri-intestinal fat near the caecum.

The parasitological findings resulted from the histological study of the removed granuloma (Fig. 2) allowed to identify the aetiological agent as the larval nematode of *Anisakis*. Their morphological features were reported in details in our previous paper (24). The histopathological study documented a case of intestinal anisakiasis of the granuloma-formation type, according to Kojima et al. classification (17).

## Discussion

Food-borne parasitic diseases are becoming relatively frequent due to changes in lifestyle as well as in eating habits. However, food-borne parasitic zoonoses, which are parasitic diseases common to man and animals, are somewhat taken into less consideration by clinicians and pathologists. Many of these zoonoses are a kind of visceral larva migrans *disease* and they are often misdiagnosed as tumours and malignancies.

Human anisakiasis is, among them, a fish-born disease caused by the larval stage of nematodes which are parasitic on marine organisms. Our case documented surgical complications of intestinal anisakiasis which required an emergency surgical treatment.

Although it has been well documented the presence of various species belonging to the genus *Anisakis*, with *A. pegreffii* being the main species, parasitizing fish and squids of commercial importance in the Mediterranean Sea (22), and the consumption of raw and undercooked fish and squids has been a staple food in several seaside villages, there have been only a few cases reported to date. Nevertheless, in most patients a definite diagnosis of intestinal anisakiasis could be made only after laparotomy, by histological and parasitological investigations of the specimen, like in our case (3, 21, 24, 33). Just a small number of cases have been documented in Italy; it could be due to lack of knowledge concerning human infection among clinicians and pathologists. And, moreover, eating habits in Italy mainly include consumption of cooked fish.

Following human infestation, larvae could either be expelled in vomit or stool, or penetrate the gastrointestinal wall where they normally die in a few minutes. But some larvae were extracted alive hours and days after the infestation. Besides, there have been indications that they might be able to persist for weeks or even months within the human host. And subsequently a local granulomatous reaction would surround the larvae, and perforations and occlusive syndromes with voluminous granulomas could later be formed. There is a classic relationship between clinical manifestations and location of the lesions. Recently, human anisakiasis was classified into the following disease forms (32): 1) gastric or intestinal, 2) extragastrointestinal, 3) oropharyngeal, and 4) transient luminal. The initial clinical appearances can be widely dissimilar and aspecific either in acute or in chronic forms, but difficulties in differential diagnosis are present mainly in chronic forms. An acute form often has a gastric localization with clinical manifestations of transient gastritis and is possible to remove the larva by endoscopy. The authors recommended removal of the entire larva as well as the surrounding

gastrointestinal mucosa with the biopsy forceps. It is important to follow this recommendation because as long as the head of a (dead) penetrated larva remains in the alimentary tract wall, there will be an antigen-developing eosinophilic granuloma (1, 4, 29). When it reaches the intestinal site, it can resolve itself after an enteritic syndrome. But such cases are rarely diagnosed correctly and they could become chronic with similar clinical symptoms which might last for more than a year. Symptoms usually disappear following endoscopic removal of the complete worm (25).

Chronic intestinal anisakiasis mostly worsens into acute abdomen through peritonitis or bowel obstruction, and therefore it could become a surgical problem and simulate many gastrointestinal diseases such as acute appendicitis, Crohn's disease, colo-rectal cancer, tuberculous peritonitis, etc. Diagnosis is generally made by histological examination of the tissue; the characteristic lesion is a granuloma surrounding the larva. Hemato-chemical data are generally normal and patients rarely present neutrophilia or an increase in IgE in the serum (21). In Japan, where the disease has the highest incidence, some Authors (18) begin to use radiographic (edema of Kerckring's folds and roundworm outline) and ultrasound findings (ascitic fluid, localized edema of Kerckring's folds and thickness of the intestinal wall) for an early diagnosis of intestinal Anisakiasis (18).

In our case, the initial suspicion of acute appendicitis based on physical examination and instrumental findings was later turned out to be inaccurate because the air-fluid levels detected in abdominal X-rays were underestimated and, during the surgical exploration, distension of the caecum, dilatation of the small bowel and a tumor-like neoplasm in the caecum were found. The past medical history also indicated consumption of raw marinated anchovies 20 days before the onset of abdominal pain. In addition, based on the suspect of neoplastic disease, a right colectomy with end-to-end ileo-transverse anastomosis was performed. The histological study of tumour, edema and congestion of the caecum and that of the ileo-caecal valve with no evidence of neoplastic findings necessitated a differential diagnosis from Crohn's disease, tuberculosis and lymphoma. Microscopic examination revealed several nodules, most of which were altered except one near the ileo-caecal valve where a parasitic larva was found quite clearly and intact. The parasitological study brought to the identification of the nematode as an *Anisakis* larva type 1 that had caused the granuloma, the pseudotumour and eventually an acute abdomen.

The presence of many altered nodules could indicate a possible spontaneous resolution of human anisakiasis or the necessity instead for many exposures

to parasite allergens for the disease appearance (19). Desowitz (8) stated that massive destruction of the tissues, slow resolution of the granuloma particularly in ileitis-like syndromes, and presence of something like non-specific granulomas suggest a "toxic-immunosuppressive effect". In humans, parasitic infections are a well-known trigger of IgE synthesis which can lead to the activation of mast cells causing inflammatory allergic reactions (2). The worm survives only 2-3 weeks in the human body, during which time it releases a wide range of proteins and some of which have immunological similarities to common allergens inhaled or ingested. Therefore, reactions mediated by IgE antibodies could be mistaken for seafood allergy, as revealed by a study in Japan in which mackerel-induced urticaria was more often caused by *Anisakis* rather than by the fish (15). A recent randomized study on the quantification of specific IgE among almost 5 million Japanese identified a higher prevalence of *Anisakis* sensitivity than seafood sensitivity (16). In support of these findings, recent reports from Spain also indicated a high prevalence of *Anisakis* sensitivity (1 in 6000) in the general population (10) which was attributed to particular eating habits like consumption of raw pickled anchovies (boquerones) (9). *Anisakis*, a hidden food allergen, is also the primary cause of food-related allergies in Spain. According to the Authors, the allergens involved may be resistant to cooking and deep freezing.

## Conclusion

In Italy people in many regions are prone to this parasitic zoonosis because of the rather newly-popu-

lar gastronomic trend of eating raw fish, especially marinated anchovies which are parasitized by *A. pegreffii* in the Italian seas (22). We may hypothesize that such infection is greatly underestimated and many cases are missed because of lack of knowledge about the disease. Diagnosis is generally based on the histological examination of the tissue and the characteristic lesion is a granuloma surrounding the larva. The first clinical appearances can be widely dissimilar and aspecific either in acute or in chronic forms, but difficulties in differential diagnosis are present mainly in chronic forms. Some Authors in Japan now begin to use radiographic and ultrasound findings for an early diagnosis of intestinal anisakiasis (18). When an acute intestinal anisakiasis is strongly suspected, a surgical treatment should be replaced by a more conservative treatment, because the disease is often transient and has the gastric localization with the possibility of larva's removal by endoscopy utilizing biopsy forceps. It is important that the entire larva as well as the surrounding gastrointestinal mucosa be removed because as long as the head of a (dead) penetrated larva remains in the alimentary tract wall, there will be an antigen-developing eosinophilic granuloma (1, 7).

Complications of chronic intestinal anisakiasis might require an emergency surgical treatment because they could cause acute abdomen simulating pathologies of malignant nature as in this case reported. Moreover, recent guidelines (11) suggested the mebendazole therapy during the postoperative period in every patient surgically treated to eliminate any larvae missed during the laparotomy (11, 21).

## References

1. Audicana MT, Fernandez De Corres L, Munoz D, et al. Recurrent anaphylaxis caused by *Anisakis simplex* parasitizing fish. *J Allerg Clin Immunol* 1995; 96: 558-560.
2. Barner M, Mohrs M, et al. Differences between IL-4R alpha-deficient and IL-4-deficient mice reveal a role for IL-13 in the regulation of Th2 responses. *Curr Biol* 1998; 8: 669-672.
3. Cancrini G, Magro G, Giannone G. Primo caso di Anisakiasis extragastrointestinale nell'uomo diagnosticato in Italia. *Parassitologia* 1997; 39: 13-17.
4. Corres LF, De Audicana M, Pozo MD, et al. *Anisakis simplex* induces not only Anisakiasis: report on 28 cases of allergy caused by this nematode. *J Invest Allerg Clin Immunol*, 1996; 6: 315-319.
5. D'Amelio S, Mathiopoulos KD, Brandoniso O.: Diagnosis of a case of gastric Anisakidosis by PCR-based restriction fragment length polymorphism analysis. *Parassitologia* 1999; 41: 591-593.
6. Dell'Olmo Escribano M, Cozar Ibatmez A, Martinez De Victoria JM, Uretma Tirao C. *Anisakis* a nivel ileal. *Rev Esp Enfer Dig* 1998; 90: 120-123.
7. Del Pozo MD, Audicana M et al. *Anisakis simplex*, a relevant etiologic factor in acute urticaria. *Allergy* 1997; 52: 576-579.
8. Desowitz RS. Human and experimental Anisakiasis in the United States. *Hokkaido Igaku-Zasshi* 1986; 61: 358-371.
9. Foti C, Netti E et al. Acute allergic reactions to *Anisakis simplex* after ingestion of anchovies. *Acta Derm Venereol* 2002; 82: 121-123.
10. Garcia-Palacios L, Gonzalez ML. Enzyme-linked immunosorbent assay, immunoblot analysis and RAST fluorimmunoassay of serum responses against crude larval antigens of *Anisakis simplex* in a Spanish random population. *J Helminthol* 1996; 70: 281-289.
11. Gilbert DN, Moellering RC, Sande MA. The Sanford guide to antimicrobial therapy. Wien Va Antimicrobial Therapy, 28th Ed. Inc 1998; p. 136.
12. Ido K, Yuasa H, Ide M, Kimura K, Toshimitsu K, Suzuki T. Sonographic diagnosis of small intestinal Anisakiasis. *J Clin*

- Ultrasound 1998; 26: 125-130.
13. Ioli A, Leoanaldi R, Gangemi C, Lo Giudice L, Bottari M, Petithory JC. A propos d'un cas d'anisakiase contractée en Sicile. *Bull Soc Patol Exot* 1998; 91: 232-234.
  14. Juglard R, Talarmin B, Casse JP, Croq M, Le Gall R, Garcia JF. Anisakidose, une localisation colique pseudotumorale rare. *J Radiol* 1998; 79: 883-885.
  15. Kasuya S, Hamano H et al. Mackerel-induced urticaria and Anisakis. *Lancet* 1990; 335:665.
  16. Kimura S. Positive ratio of allergen specific IgE antibodies in serum from a large scale study. *Rinsho Byori* 2001; 49: 376-380.
  17. Kojima K, Koyanagagi T, Shiraki K. Pathological studies of Anisakiasis parasitic abscess formation in gastrointestinal tracts. *JPN J Clin Med* 1996; 24 : 134-143.
  18. Kouki I, Hajime Y, Mitsuru I et al. Sonographic diagnosis of small intestinal Anisakiasis. *J Clin Ultrasound* 1998; 26: 125-130.
  19. Kuipers FC. Pathogenese van de haringwormflegmone bij de mens. *Nederlands Tijdeschrift vor Geneeskunde*, 1964; 108: 304-305.
  20. Louredo Mendez A, Acedo De La Rosa F, Arribas De Paz V, Sanz Ortega E, Bernardo Quiros L, Goyanes Martinez A. Anisakiasis del colon como causa de abdomen agudo. *Rev Esp Enfer Dig* 1997; 89: 403-406.
  21. Maggi P, Caputi-Imbrenghi O, Scardigno A et al. Gastrointestinal infection due to Anisakis simplex in Southern Italy. *Eur J Epidemiol* 2000; 16: 75-78.
  22. Mattiucci S, Nascetti G, Cianchi R, Arduino P, Margolis L, Brattery J, webb S, D'Amelio S, Orecchia P, Bullini L. Genetic and ecological data on the Anisakis simplex complex with evidence for a new species (Nematoda, Ascaridoidea, Anisakidae). *J Parasitol* 1997; 83: 401-416.
  23. Matsumoto T, Iida M, Kimura Y, Tanaka K, Kitada T, Fujishima M. Anisakiasis of the colon: radiologic and endoscopic features in six patients. *Radiol* 1992; 183: 97-99.
  24. Moschella CM, Mattiucci S, Minigazzini P, De Angelis G, Assenza M, Lombardo F, Monaco S, Paggi L, Modini C. Intestinal Anisakiasis in Italy: case report. *J Helminthol* 2004; 78: 1-4.
  25. Namiki M, Yazachi Y. Treatment of gastric Anisakiasis with acute symptoms. In: Inshikura H, Namiki M, eds, *gastric Anisakiasis in Japan*. Tokio Springer Verlag 1989; 129-131.
  26. Okada K, Tsuchiya M, Tanaka M, Hashizume Y: A case of acute Anisakiasis of the stomach making rapid progress to parasitic granuloma. *Progr Dig Endos* 1978; 12: 153-155.
  27. Orecchia P, Paggi L, Mattiucci S, Di Cave D, Catalini N. Infestazione da larve di Anisakis simplex A e Anisakis physeteris in specie ittiche dei mari italiani. *Parassitologia* 1989; 31: 37-43.
  28. Pampiglione S, Rivasi F, Criscuolo M et al. Human Anisakiasis in Italy: a report of eleven new cases. *Path Res Pract* 2002; 198: 429-434.
  29. Pozo MD, Del Moneo I, Corres LF et al. Laboratory determinations in Anisakis simplex allergy. *J All Clin Immunol* 1996; 97: 977-984.
  30. Sakamaro JA, Loinaz M, Deardoff TL, Raybourne RB, McKerrow JH, Gordon Frierson J. Intestinal Anisakiasis. A case diagnosed by morphologic and immunologic methods. *Am J Clin Pathol* 1988; 90: 107-113.
  31. Shirahama M, koga T, Uchida S, Miyamoto Y, Ohta Y: Colonic Anisakiasis simulating carcinoma of the colon. *AJR* 1990; 155.
  32. Smith JW. Ascaridoid nematode and pathology of alimentary tract and its associated organs in vertebrates including man: a literature review. *Helmint Abstr* 1996; 68: 49-96.
  33. Stallone O, Paggi L, Balestrazzi A, Mattiucci S, Montinari M. Gastric Anisakiasis in Italy: case report. *Medit J Surg Med* 1996; 4: 13-16.