

G Chir Vol. 26 - n. 4 - pp. 135-137
Aprile 2005

casistica clinica

Anal GIST in older old patient: a case report

R. LANTERI, I. ALIOTTA, A. RACALBUTO, A. LICATA

SUMMARY: Anal GIST in older old patient: a case report.

R. LANTERI, I. ALIOTTA, A. RACALBUTO, A. LICATA

GIST are a group of quite rare neoplastic pathologies. This type of pathology is currently the subject of discussion as for their origin and treatment. It is generally difficult to determine if they are to be considered as a benign or malign neoplastic disease.

We present the case report of a patient with a recurrence of anal GIST who was examined 8 years after the first treatment. Case report: C.M., female, 81 years old, came to our Clinic in March 2001 complaining of rectal haemorrhage and abdominal pain in the lower quadrants; he had also suffered from constipation for 1 month. During rectal exploration we found a mass spreading inside the lumen 3 cm from the anal verge. Colonoscopy showed that the tumour, which was 7x5 cm in size, was inside the wall with normal mucosa. EUS revealed that the origin was within the muscular layer; therefore we chose transanal excision as surgical treatment. The patient was discharged 5 days after surgery and is alive; he only showed a small local recurrence of disease 30 months after treatment. Histological examination confirmed that the tumour was a GIST.

This case provides the basis for a discussion about characteristics and the evolution of this group of pathologies.

RIASSUNTO: GIST anale in paziente anziano. Case report.

R. LANTERI, I. ALIOTTA, A. RACALBUTO, A. LICATA

I GIST sono un gruppo di patologie neoplastiche piuttosto rare, tutt'oggi oggetto di discussione riguardo la loro origine ed il loro trattamento. È molto difficile stabilire se si debba considerare questa patologia, di volta in volta, come una malattia neoplastica benigna o maligna.

Descriviamo un caso clinico riguardante una paziente con recidiva di GIST anale osservata 8 anni dopo il primo trattamento. Caso clinico: C.M., donna, 81 anni, osservata nel marzo 2001 in quanto affetta da rettorragia, dolore ai quadranti inferiori dell'addome e stipsi da un mese. All'esplorazione digitoanorettale si apprezzava una massa aggettante nel lume a 3 cm dal margine anale. La colonscopia mostrava la presenza della neoplasia apparentemente intramurale ricoperta da mucosa normale, delle dimensioni di cm 7x5. L'ecoendoscopia dimostrava l'origine a partenza dalla muscolare propria; quindi è stata proposta ed eseguita l'escissione transanale della lesione. La paziente è stata dimessa in 5ª giornata postoperatoria ed attualmente è vivente con una piccola recidiva locale a 30 mesi dall'intervento. L'esame istologico ha confermato che si trattava di un GIST.

Questo caso apre una discussione circa la natura, le caratteristiche e l'evoluzione di questo particolare tipo di tumori.

KEY WORDS: Anus - GIST - Elderly - Recurrence.
Ano - GIST - Anziano - Recidiva.

Background

Gastrointestinal stromal tumour (GIST) is the designation given to specific Kit-expressing and signalling mesenchymal tumours, many of which have Kit-activating mutations (1). They are believed to arise from the interstitial cell of Cajal (ICC) or its precursor, the interstitial mesenchymal precursor cell (2, 3). The majority of GIST cases are located in the stomach (65%), followed by those of the small intestine (30-35%) (4) and are sporadically reported in the rectum (5).

We report the case of a patient affected by a recurrent rectal GIST, who had been treated surgically eight years earlier.

Case report

MC, female, 81 years old, came to our observation in March 2001 complaining of the appearance, approximately one week before, of colic pain in the lower quadrants of the abdomen and rectal bleeding of light entity. Eight years earlier, the patient had undergone the transanal removal of one intramural mass of benign nature situated at the level of the straight-anal splice.

The objective examination of the abdomen resulted negative. On rectal exploration, the introduction of the exploratory finger also provoked light pain; however, it was easy. Palpation indicated that the presence of a 5 cm mass was possible on the left side

Catania University, Italy
Department of Surgical Sciences,
Organ Transplantation and Advanced Technologies
© Copyright 2005, CIC Edizioni Internazionali, Roma

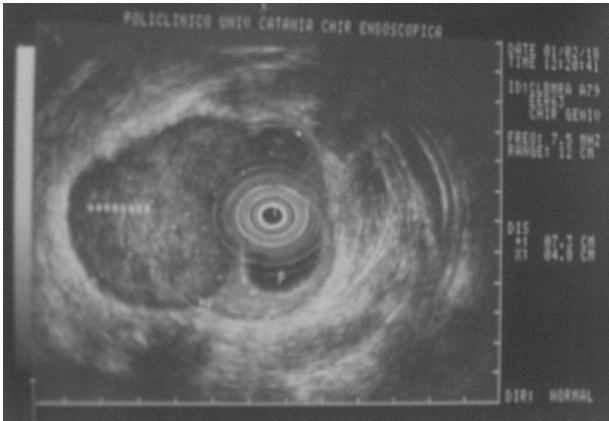


Fig. 1 - EUS: the examination demonstrated the origin of mass from muscular layer.

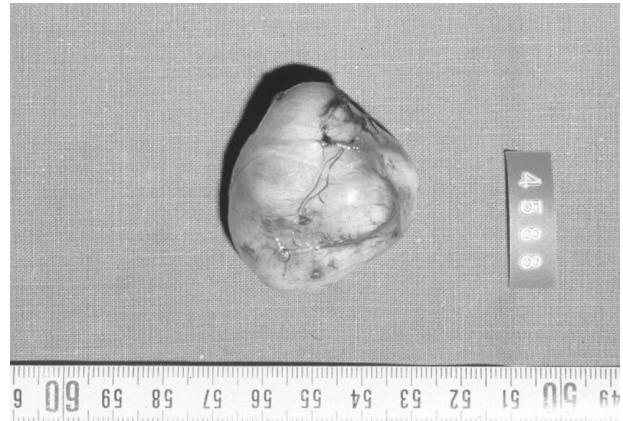


Fig. 2 - The mass after the excision.

of the anal channel, approximately 4 cm from the external anal edge, and so was a second mass approximately 2 cm along the anterior wall, which seemed to be related to the first. The two masses protruded into the lumen, rendering it stenotic, and were covered by smooth mucosa.

Endoscopic examination revealed a mass of approximately 7 cm located at the level of the line bite, occupying nearly 50% of the rectal ampoule, covered by mucosa of normal aspect and from which bioptic samples were taken. Furthermore, EUS examination showed an ipoechoic alteration, with anechoic areas deriving from colliquation, originating from the muscular tunica, and the absence of regional lymphadenopathies (Fig. 1). The histological diagnosis obtained from the biopsies was not clear, probably because the samples were not taken at a depth great enough, describing an interstitial picture of oedema and gland hyperplasia. Taking into account the distal localisation of the lesion, we decided to perform transanal ablation (Fig. 2).

Histo-anatomopathologic examination of the removed mass led to diagnose a fused cell malignant stromal tumour (GIST) with undetermined immunophenotype: vimentine and CD34 positive, elevated mitotic index with >10 mitosis x 10 HPF with the presence of haemorrhagic and necrotic areas. Therefore, we suggested a radical treatment by means of Miles procedure but the patient refused surgery. The patient was discharged 5 days after surgery in the absence of complications. Through experiencing a small local recurrence of the disease 30 months after the treatment, today the patient is alive.

Discussion

Gastrointestinal stromal tumours are regarded as the largest group of mesenchymal tumours in the gastrointestinal tract, whereas true smooth muscle tumours are rare, except for the oesophagus and the muscularis mucosae of the colon and the rectum (5). GIST occurs in adults aged 17-90 (on average 60) and especially in males (71%)(5).

GIST can be divided into four principal types: 1) forms of smooth muscular type; 2) GANT (gastrointestinal autonomic nerve tumours); 3) mixed types (smooth muscular type/GANT); 4) undifferentiated GIST (6, 7). Rectal localization is quite rare (7-10%)

and has a typical immunohistochemical profile. A large majority of these are positive for CD34, and very few are positive for smooth muscle actine and occasionally for desmine, while smooth muscle actine positivity is more common in small intestinal GIST and desmine positivity is well documented for oesophageal GIST (8).

In a recent study Miettinen et al. (5) classified 133 anal GIST according to mitosis and size, trying to correlate at the same time these two parameters with recurrence and survival rates. It is particularly interesting that diameters larger than 5 cm and more than 5 mitoses/50 HPF can be considered as statistically independent factors which influence the 5 year survival and recurrences rates.

We can include our case in Miettinen's sixth group. In the Miettinen series (5), recurrence, metastases and death from tumour represent 85%. This background information poses a question regarding the nature of the primary lesion removed 10 years ago, which the anatomopathologist classified as leiomyoma. As reported by other authors in similar cases, we suggest that this neoplasia was included in the smooth muscle tumours without immunohistochemical analysis, and that it was probably a GIST.

Conclusion

The present case is particular: firstly because of the long period between the first excision and the first recurrence (about 8 years); secondly, because of the short period between the second excision and local recurrence (about 2 years). Is it possible that a GIST develops more malignant characteristics due to differentiation? It is hard to answer this question because, to our knowledge, this is the first case report having this characteristic and it could lead to further discussions on the unclear chapter of oncology.

References

1. Miettinen M, Majidi M, Lasota J. Pathology and diagnostic criteria of gastrointestinal stromal tumour (GISTs): a review. *Eur J Cancer* 2002; 38 Suppl 5: S39-51
 2. Huigol RL, Young CJ, Solomon MJ. The GIST of it: case report of a gastrointestinal stromal tumour and a leiomyoma of the anorectum. *ANZ J Surg* 2003; 73: 167-70.
 3. Hirota S, Isozaki K, Moriyama Y et al. Gain-of-function mutation of c-Kit in human gastrointestinal stromal tumours. *Science* 1998; 279: 577-80.
 4. Shibata Y, Ueda T, Seki H, Yagihashi N. Gastrointestinal stromal tumour of the rectum. *Eur J Gastroenterol Hepatol* 2001; 13: 283-6.
 5. Miettinen M, Furlong M, Sarlomo-Rikala M, Burke A, Sobin L, Lasota J. Gastrointestinal stromal tumours, intramural leiomyomas, and leiomyosarcomas in the rectum and anus. *Am J Surg Pathol* 2001; 25 (9): 1121-33.
 6. Ricca L, Ferri M, De Siena T, Ricci F, Laghi A, Ziparo V. Tumori stromali gastrointestinali (GIST) a localizzazione rettale. Un nuovo caso e revisione della letteratura. *Chir Ital* 2002; 54 : 709-16.
 7. Erlandson RA, Klimstra DS, Woodruff JM. Subclassification of gastrointestinal stromal tumors based on evaluation of electron microscopy and immunohistochemistry. *Ultrastructural Pathology* 1996; 20: 373-93.
 8. Miettinen M, Sarlomo-Rikala M, Sobin LH et al.: Esophageal stromal tumors: a clinico-pathologic, immunohistochemical and molecular genetic study of seventeen cases and comparison with esophageal leiomyomas and leiomyosarcomas. *Am J Surg Pathol* 2000; 24: 211-22.
-