

G Chir Vol. 24 - n. 4 - pp. 115-118
Aprile 2003

casistica clinica

Bile leak from the accessory biliary duct following laparoscopic cholecystectomy

A. PISANU, M.L. ALTANA, S. PIU, A. UCCHEDDU

SUMMARY: Bile leak from biliary duct following laparoscopic cholecystectomy.

A. PISANU, M.L. ALTANA, S. PIU, A. UCCHEDDU

Anatomists and surgeons have described the presence of accessory biliary ducts between the liver and gallbladder. Bile leakage from accessory duct following laparoscopic cholecystectomy (LC) is an unusual post-operative complication.

Aim of the study was to assess its incidence, the intraoperative methods helpful for notice the anatomical anomaly and the impact of endoscopic procedure as a suitable treatment.

From January 1997 to September 2002, 185 patients underwent LC for symptomatic cholelithiasis in our surgical department. Post-operative bile leakage from accessory biliary duct occurred in two patients (1%): one case from the liver bed of gallbladder (duct of Luschka) and one case from an aberrant cholecystohepatic duct entering Hartmann's pouch. One patient underwent open celiotomy because of unavailability of endoscopic retrograde cholangiopancreatography. The other patient was successfully treated by endoscopic sphincterotomy and nasobiliary tube placement. By careful dissection, accessory ducts were noticed and clipped in three other patients with overall incidence of 2.7%.

Meticulous laparoscopic technique aimed to carefully recognize all structures during LC is the main policy to contain biliary injury within its nadir incidence. Depending of availability, endoscopic sphincterotomy and nasobiliary drainage allow diagnosis and treatment of bile leakage, preserving the effectiveness of laparoscopic procedure.

RIASSUNTO: Perdita biliare da dotto accessorio dopo colecistectomia laparoscopica.

A. PISANU, M.L. ALTANA, S. PIU, A. UCCHEDDU

La presenza di dotti biliari accessori tra fegato e colecisti è stata descritta da chirurghi e da anatomisti. Il leakage biliare da dotto accessorio dopo colecistectomia laparoscopica (LC) è una complicanza inusuale.

Scopo dello studio era di valutarne l'incidenza, i metodi intraoperatori per identificare l'anomalia anatomica e l'impatto delle procedure endoscopiche quale appropriato trattamento.

Dal gennaio 1997 al settembre 2002, 185 pazienti sono stati sottoposti a LC per colelitiasi sintomatica nel Dipartimento degli autori. Il leakage biliare da dotto accessorio è stato riscontrato in due pazienti (1%): un caso dal letto epatico della colecisti (dotto di Luschka) e un caso da un dotto accessorio dell'infundibolo. Un paziente è stato sottoposto a laparotomia per indisponibilità della colangiopancreatografia retrograda endoscopica. L'altro paziente è stato trattato con sfinterotomia endoscopica e sondino naso-biliare. Attraverso un'attenta dissezione, un dotto biliare accessorio fu identificato e "clippato" in tre altri pazienti, per un'incidenza complessiva del 2.7%.

Una tecnica laparoscopica finalizzata ad identificare con sicurezza tutte le strutture è la strategia migliore per contenere al minimo l'incidenza di lesioni biliari. In relazione alla disponibilità, la sfinterotomia endoscopica e il drenaggio nasobiliare consentono la diagnosi e il trattamento del leakage biliare, non compromettendo l'efficacia della procedura miniinvasiva.

KEY WORDS: Laparoscopy – Cholecystectomy – Accessory bile duct – Bile leakage.

Laparoscopia – Colecistectomia – Dotto biliare accessorio – Filtrazione biliare.

Introduction

Laparoscopic cholecystectomy (LC) has become the gold standard in the surgical management of symptomatic gallstone disease (12). LC is safe and effective in terms of reduced hospital stay and quicker recovery (13, 19). Moreover, several reports in the literature show an incidence of iatrogenic biliary tree injuries ranging from 0 to 7% as against up to 0.25% of the open approach (22). Bile leakage has been

reported to occur from 0.2% to 1.5% of patients undergoing LC (7, 21). One of the not so common causes is the unrecognised accessory cholecystohepatic duct from the hepatic bed of the gallbladder (duct of Luschka) or from not identified aberrant cholecystohepatic ducts entering Hartmann's pouch, during laparoscopy. The usefulness of intraoperative cholangiography (IOC) as a prerequisite to avoid biliary injuries, also in the case of accessory bile ducts, is still matter of debate (8, 21). On the other hand, there is agreement in literature with the concept that most patients experiencing bile leak can be successfully treated by endoscopic means (3, 10, 11). The aim of this study was to report two cases of bile leakage from

University of Cagliari (Italy)
Department of Surgery - Semeiotica Chirurgica
Centro di Studio per la Chirurgia Laparoscopica Avanzata in Chirurgia Generale
(Responsabile: Prof. A. Uccheddu)

© Copyright 2003, CIC Edizioni Internazionali, Roma

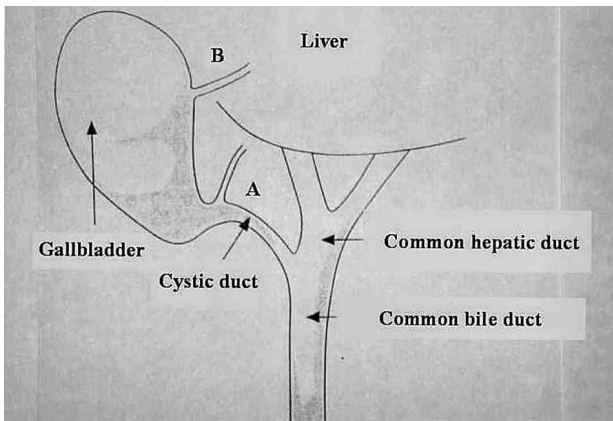


Fig. 1 - Accessory biliary ducts type A (entering Hartmann's pouch) and type B of Luschka (entering gallbladder body).

accessory cholecystohepatic duct following LC, in order to assess the incidence of this unusual complication, highlighting the intraoperative methods helpful for notice the presence of the anatomical anomaly and the impact of endoscopic procedure as a suitable treatment.

Patients e methods

Over the period from January 1997 to September 2002, 185 patients underwent laparoscopic cholecystectomy for symptomatic cholelithiasis in our surgical department. Acute cholecystitis was the surgical indication in 20% of patients. Laparoscopic cholecystectomy was performed according to the "French technique" with intraoperative cholangiography only in selected cases, in relation to the accuracy of preoperative study. Laparoscopic dissection started between Hartmann's pouch and cystic duct according to the "drapeau" method. This method consisted in a "flag-like" extended dissection posterior to the ampulla of the gallbladder. Fat and peritoneum were dissected in order to expose the cystic duct and the cystic artery. In the aim to open Calot's triangle, the cystic artery was divided before the cystic duct. Using blunt dissection, gallbladder was elevated to create a space between Hartmann's pouch and liver, prior to sectioning of the anatomical structures. Common bile duct was also systematically noticed and safely exposed. A drain was positioned in the gallbladder bed in the case of acute cholecystitis and when there was some doubts regarding laparoscopic dissection.

In two patients bile leakage was observed in the surgical drain during post-operative period. One patient underwent urgent exploratory celiotomy depending on unavailability of Endoscopic Retrograde Cholangiopancreatography (ERCP). Open operative view showed a gallbladder fossa bile leak due to an unrecognised accessory cholecystohepatic duct of Luschka that was ligated (Fig. 1 - type B).

In the other patient, ERCP was carried out showing a bile leak from an aberrant duct of type A (Figs. 1 and 2). The treatment consisted of an endoscopic sphincterotomy with nasobiliary tube drainage placement. Abolishing the Oddian control using endoscopic sphincterotomy, permitted a decrease of pressure gradient between the bile duct and the duodenum created by muscular contraction of ampullary sphincter, allowing a fast reduction of bile leak.

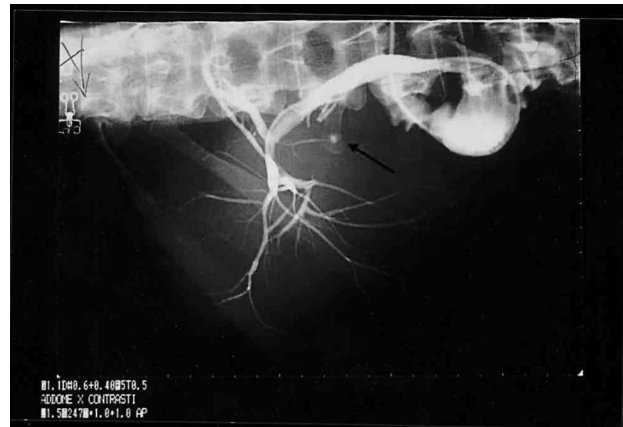


Fig. 2 - Leakage from accessory biliary duct type A on ERCP imaging.

There were three other patients in whom a small accessory biliary duct entered Hartmann's pouch closing to the junction with the cystic duct (Fig. 1 - type A). Tank to the "drapeau method", this duct was noticed during operation and clipped.

In neither patient there was any indication on routine preoperative assessment about an accessory hepatic duct. Only in one patient there was a suspect of biliary anomaly on Magnetic Resonance Cholangiopancreatography (MRCP) imaging, performed for common bile duct stones suspicion.

Results

The Authors have observed a 1% incidence of bile leakage, one from the hepatic bed of gallbladder (Fig. 1-type B) and the other from an accessory cholecystohepatic duct entering Hartmann's pouch (Fig. 1-type A). Cholecystohepatic accessory duct was noticed and clipped in other three patients with overall incidence of 2.7%.

Bile drain content was helpful to early identify bile leakage. One patient underwent open surgery because of unavailability of ERCP in emergency setting. The other patient was successfully treated by endoscopic sphincterotomy and placement of a naso-biliary drainage (Fig. 2). Bile leakage reduced and resolved by a facilitate internal drainage of sphincterotomy. No major biliary injuries were encountered in authors experience.

Discussion

LC has gained acceptance among surgeons as the procedure of choice in the treatment of symptomatic cholelithiasis (12). The benefits of LC in terms of lower postoperative morbidity, reduction of the hospital stay and more rapid return to full activity have been well standardised (13, 19). Since its introduction in 1987 (12), injuries to the biliary tree during LC have been one of the most impor-

tant causes for concern (21). Within a number of biliary complications, bile leak has been reported to occur from 0.2% to 1.5% of patients undergoing LC (7, 21). In their experience, the authors have observed a 1% incidence of bile leak from cholecystohepatic ducts following LC, with an overall incidence of 2.7% of aberrant biliary ducts. The presence of accessory ducts travelling between the liver and gallbladder has been recognized by anatomists and surgeons (5). The cholecystohepatic duct known as the duct of Luschka enter the body of gallbladder (Fig. 1–type B) while another one enter Hartmann's pouch close to the junction with the cystic duct (Fig. 1–type A) (6, 9, 21).

The authors report two cases of bile leakage from accessory cholecystohepatic duct following LC. Early in the authors' experience, this anomaly was not well-known and appropriately considered. On the basis of two patients experiencing bile leak from accessory duct and of surgical expertise gained by early laparoscopic management of acute cholecystitis (16), we have standardised a laparoscopic technique of cholecystectomy helpful to prevent and avoid laparoscopic injuries. The "drapeau method" provide that all structures crossing the space between the liver and Hartmann's pouch can be noticed, thus allowing safely ligature both of the cystic duct and of the accessory cholecystohepatic ducts, without biliary injuries (21). Tank to the above surgical rule, aberrant cholecystohepatic duct was detected and clipped during laparoscopic dissection in three subsequent patients in whom an accessory biliary duct entered Hartmann's pouch closing to the junction with the cystic duct (Fig. 1–type A).

The cholecystohepatic duct commonly known as the duct of Luschka (Fig. 1–type B) should be kept in mind during laparoscopic dissection within gallbladder fossa and clipped if identified (5, 6). In the case of doubts regarding laparoscopic dissection, positioning a drain in the gallbladder bed is recommended. Effectively, in our two patients bile leakage was observed in the surgical drain during post-operative period.

We perform LC without intraoperative cholan-

giography because we think that this procedure is indicated only in selected cases, i.e. suspect of common bile duct stones (16). Other surgeons systematically use cholangiography during laparoscopy (2), (4, 18). The helpful of IOC in identifying an accessory bile duct during LC is also debatable. According to some authors, the accessory duct can be clearly seen filling with contrast on IOC (1, 8), (9). On the other hand, a number of authors have stressed the IOC failure to detect this biliary anomaly (17, 19). In this scenario, we believe that IOC cannot compensate safe and meticulous dissection of the anatomical structures. Although IOC could early recognise biliary complications, it mustn't be considered as a universal remedy for preventing iatrogenic bile injuries! (17, 20 – 22). In a recent national survey of Italian Society of Surgery, no difference was found between systematic and selective approach of IOC regarding incidence of biliary injuries during LC (14).

Biliary fistulae or bile leakage are maintained by high pressure of contraction of Oddian sphincter (15). From experience achieved in the management of biliary fistulae of hepatic hydatid cysts open to the biliary tree (15), we have safely performed endoscopic treatment in the setting of iatrogenic bile leak of laparoscopy (Fig. 2). Depending of its availability in emergency, the combination of sphincterotomy and nasobiliary tube drainage is effective for immediate decompression of bile ducts and for fast reduction of bile leakage (3, 7, 11). Temporary biliary endoscopic stenting may be also indicated in the resolution of biliary leaks (10).

In view of the considerations outlined above, the Authors believe that a meticulous minimally invasive technique aimed to carefully identify all structures during LC is the main way to contain biliary injury within its nadir incidence. In the case of current bile leakage from accessory cholecystohepatic biliary duct, ERCP by means of sphincterotomy and nasobiliary tube drainage allow diagnosis and treatment, preserving the effectiveness of the laparoscopic procedure, without any need for conversion to laparotomy.

Bibliografia

1. Bernard P., Letessier E., Denimal F., Le Neel J.C.: Accessory cystic duct discovered by intraoperative cholangiography during cholecystectomy. *Ann Chir* 2001; 126: 10, 1020.
2. Capelluto E., Barrat C., Catheline J.M., Champault G.: Expérience de la cholangiographie peropératoire systématique au cours de la cholécystectomie laparoscopique. *Chirurgie* 1999; 124: 536.
3. Chow S, Bosco JJ, Heiss FW, Shea JA, Qaseem T, Howell D: Successful treatment of post-cholecystectomy bile leaks using nasobiliary tube drainage and sphincterotomy. *Am J Gastroenterol* 1997; 92: 1839.
4. Cuschieri A, Shimi S, Banting S, Nathanson IK, Pietra Bissa A: Intraoperative cholangiography during laparoscopic cholecystectomy. Routine vs selective policy. *Surg Endosc* 1994; 8: 302.
5. Edelman DS: Bile leak from the liver bed following lapar-

- scopic cholecystectomy. *Surg Endosc* 1994; 8: 3, 205.
6. JAMSHIDI M, OBERMEYER RJ, GARCIA G, HASHMI M: Post-laparoscopic cholecystectomy bile leak secondary to an accessory duct of Luschka. *Int Surg* 1999; 84: 86.
 7. Jenkins MA, Ponsky JL, Lehman GA, Fanelli R, Bianchi T: Treatment of bile leaks from the cystohepatic ducts after laparoscopic cholecystectomy. *Surg. Endosc* 1994; 8: 3, 193.
 8. Kellam LG, Howerton RL, Goco IR, Nolan RE: Accessory bile duct and laparoscopic cholangiography: report of three cases. *Am Surg* 1996; 62: 270.
 9. Kullman E, Borch K, Lindstrom E, Svanvik J, Anderberg B: Value of routine intraoperative cholangiography in detecting aberrant bile ducts and bile duct injuries during laparoscopic cholecystectomy. *Br J Surg* 1996; 83: 171.
 10. Marks JM, Ponsky JL, Shillingstad RB, Singh J: Biliary stenting is more effective than sphincterotomy in the resolution of biliary leaks. *Surg End* 1998;12: 327,.
 11. Mergener K, Strobel JC, Suhocki P, Jowell PS, Enns RA, Branch MS, Baillie J: The role of ERCP in diagnosis and management of accessory bile duct leaks after cholecystectomy. *Gastrointest Endosc* 1999; 50: 4, 527.
 12. Mouret P: From the first laparoscopic cholecystectomy to the frontiers of laparoscopic surgery. The first prospective futures. *Dig Surg* 1991; 8: 124.
 13. National Institute of health. Consensus development conference statement on gallstones and laparoscopic cholecystectomy. *Am J Surg* 1993; 165: 390.
 14. Nuzzo G. Le lesioni iatrogene della via biliare principale. Monografia del 104° Congresso della Società Italiana di Chirurgia. Roma, 13-16 Ottobre, 2002;
 15. Pisanu A, Cois A, Altana ML, Uccheddu A, Cagetti M: Pathophysiology of biliary fistulae in management of hepatic hydatid cysts open to the biliary tree. *Hepatogastroenterology* 1999; 46: 6.
 16. Pisanu A, Floris G, AmbuR, Uccheddu A: Early surgical treatment of acute cholecystitis. A retrospective comparative study of the laparoscopic and open approaches. *Chir Ital* 2001; 53: 159.
 17. Taylor OM, Sedman PC, Mancey JB, Royston CMS, Arulampalam T, Wellwood J: Laparoscopic cholecystectomy without operative cholangiogram: 2038 cases over a 5-years period in two district general hospitals. *Ann R Coll Surg Engl* 1997; 79: 376.
 18. Vezakis A, Davides D, Ammori BJ, Martin IG, Larvin M, McMahan MJ: Intraoperative cholangiography during laparoscopic cholecystectomy. *Surg Endosc* 2000; 14: 1118.
 19. Wastell C: Laparoscopic Cholecystectomy. Better for patients and the health service. *BMJ* 1991; 302: 303.
 20. Woods MS, Traverso LW, Kozarek RA, Donohue JH, Fletcher DR, Hunter JG, Oddsdottir M, Rossi RL, Tsac J, Windsor J: Biliary tract complications of laparoscopic cholecystectomy are detected more frequently with routine intraoperative cholangiography. *Surg Endosc* 1995, 9: 1076.
 21. Wright KD, Wellwood JM: Bile duct injury during laparoscopic cholecystectomy without operative cholangiography. *Br J Surg* 1998; 85: 191.
 22. Z'Graggen, Wehrli H, Metzger A, Bueheler M, Frei E, Klaiber C: Complications of laparoscopic cholecystectomy in Switzerland. A prospective 3-year study of 10.174 patients. Swiss Association of Laparoscopic and Thoracoscopic Surgery. *Surg Endosc* 1998; 12: 1303.
-