

Current guidelines for anal fissure treatment and evidence based approach towards hemorrhoids

P.J. GUPTA

ANAL FISSURE

An anal fissure is a split in the mucosa extending from the anal verge towards the dentate line. It was first recognized as a disease in 1834 and currently affects 10% of patients attending proctology clinics. Anal fissures occur with equal frequency in both sexes. Additionally, anal fissures tend to occur in younger and middle-aged persons.

The exact etiology of anal fissures is unknown, but the initiating factor is thought to be trauma from the passage of a particularly hard or painful bowel movement. Low-fiber diets, such as those lacking in raw fruits and vegetables, are associated with the development of anal fissures. No occupations are associated with a higher risk for the development of anal fissures. Prior anal surgery is a predisposing factor because scarring from the surgery may cause either stenosis or tethering of the anal canal, which makes it more susceptible to trauma from hard stool. Other risk factors include Crohn's disease and childbirth trauma. Fissures are occasionally seen in association with infections like tuberculosis, syphilis, HIV, and herpes.

The most commonly observed abnormalities are hypertonicity and hypertrophy of the internal anal sphincter, leading to elevated anal canal and sphincter resting pressures. Most patients with anal fissures have an elevated resting pressure, and this resting pressure returns to normal levels after surgical sphincterotomy.

Pathophysiology of anal fissure

The posterior anal commissure is the most poorly perfused part of the anal canal being supplied by endarteries, which pass through the internal anal sphincter before reaching the posterior commissure. In patients with hypertrophied internal anal sphincters, this delicate blood supply is further compromised, thus rendering the posterior midline of the anal canal relatively ischemic. This is thought to account for why many fissures do not heal spontaneously and may last for several months. Pain accompanies each bowel movement as this raw area is stretched while the injured mucosa is abraded by the stool. The internal sphincter goes in spasm when the stool is passed, which has two significant effects. First, the spasm itself is painful; second, the spasm further reduces the blood flow to the posterior midline and the anal fissure, contributing to the poor healing rate.

As the maximum resting anal pressure (MRAP) is usually greater than 90mmHg in patients with fissures, such hypertonia will compress the end arteries and cause ischemia of the posterior commissure. The hypertonia is not secondary to pain, as it is not relieved by the use of topical anesthetics. This explains the presence of sphincter spasm, severe pain (ischemic in nature), pre-dilection for the posterior midline, and poor healing in all chronic anal fissures (Fig. 1).

Clinical picture

Typically, the symptoms of an anal fissure are relatively specific, and the diagnosis can often be made based on history findings alone. The patient reports severe pain during a bowel movement, with the pain lasting several minutes to hours afterward. The pain recurs with every bowel movement, and the patient commonly becomes afraid or unwilling to have a bowel movement, leading to a cycle of worsening constipation, harder stools, and more anal pain.

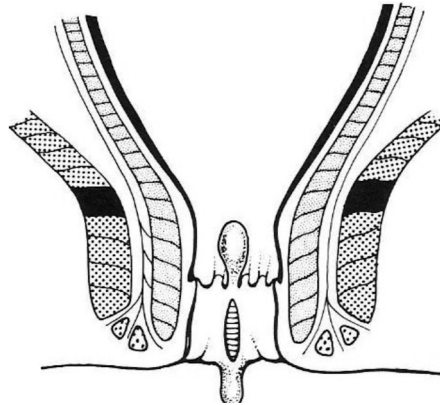


Fig. 1 - An anal fissure.

More than half of patients note bright red blood on the toilet paper or stool. Occasionally, a few drops may fall in the toilet bowl, but significant bleeding does not usually occur with an anal fissure. Other features include anal discharge, pruritus, constipation, dysuria and dyspareunia.

To begin with, the fissure is just a tear in the anal mucosa and is defined as an acute anal fissure. Acute anal fissures have sharply demarcated, fresh mucosal edges and granulation tissue at the base (Fig. 2). The majority of acute anal fissures heal spontaneously or with conservative treatment.

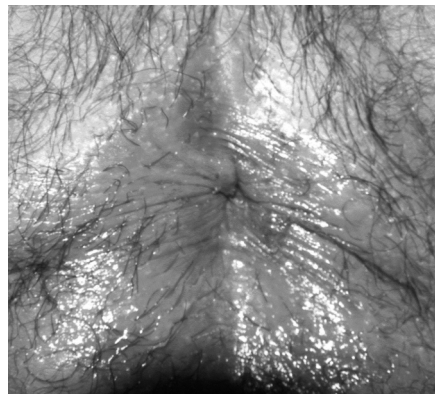


Fig. 2 - Acute anal fissure.

Some lesions do not improve after 6 weeks and develop secondary changes characteristic of chronic fissures. The skin on the distal end of the fissure becomes fibrotic and edematous, forming a sentinel pile. The fibers of the internal anal sphincter are visible in the base of the chronic fissure, and often, an enlarged anal skin tag is presented distal to the fissure and hypertrophied anal papillae are present in the anal canal proximal to the fissure (Fig. 3).

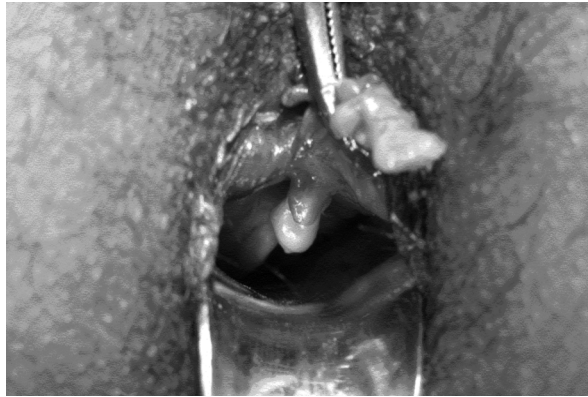

Fig. 3 - Chronic anal fissure with fibrous polyp and papilla.

Most anal fissures occur in the posterior midline, with the remainder occurring in the anterior midline. Two percent of patients have both anterior and posterior fissures. Fissures occurring off the midline (Fig. 4) should raise the possibility of other etiologies like Crohn's disease, sexually transmitted disease, AIDS, or cancer. Along with a history, the diagnosis can usually be made ba-

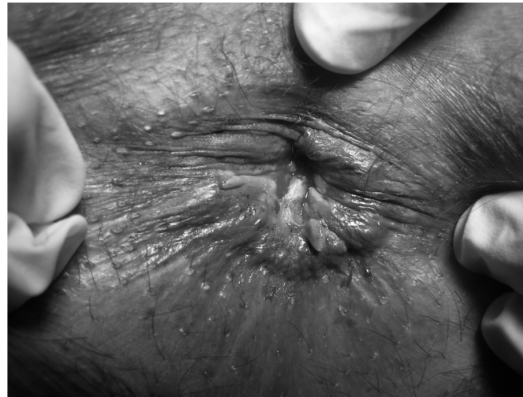

Fig. 4 - Multiple anal fissures with anal tag.

sed on findings from a gentle perianal examination with inspection of the anal mucosa. In this case, no diagnostic procedures are required. A digital rectal examination is painful and often can be deferred.

Medical therapy

Initial therapy for an anal fissure is conservative in nature, and more than 80% of acute anal fissures resolve without further therapy. The goals of treatment are to relieve the constipation and to break the cycle of hard bowel movement, associated pain, and worsening constipation. Softer bowel movements are easier and less painful for the patient to pass.

First-line medical therapy consists of prescribing stool-bulking agents, such as fiber supplementation and stool softeners. Laxatives are used as needed to maintain regular bowel movements. Sitz baths after bowel movements and as needed provide significant symptomatic relief because they relieve some of the painful internal sphincter muscle spasm. Use of oral analgesics is very effective in relieving pain after defecation. Although creams containing topical steroids and anesthetics often have shown little benefit in clinical trials, many anecdotal reports support their use as first-line treatment, with many reports of healing in approximately 50% of patients.

Second-line medical therapy is the topical application of 0.2% nitroglycerin or diltiazem ointment directly to the internal sphincter. Some physicians use these ointments as initial therapy in conjunction with fiber and stool softeners, and others prefer to add it to the medical regimen if fiber, analgesics and stool softeners alone fail to heal the fissure. The effects of this medication are termed as 'chemical sphincterotomy'. Many newer drugs are emerging in this category, but the following are mostly used.

Calcium channel blockers like nifedipine and diltiazem are found effective in relieving the anal sphincter spasm. Oral lacidipine 6 mg once daily or diltiazem 60 mg in divided doses can be used alternatively. These drugs have a short duration of action and need to be administered 2-3 times daily. Similarly, side effects like headache, palpitations, flushing, dizziness, colicky abdominal pain; ankle edema, reduced taste and smell, nausea and diplopia have been reported. All side effects are seen in the first four weeks of treatment. Use of cholinomimetic drug like bethanechol as 0.1 percent gel applied locally three times a day for eight weeks has also been reported to give equally satisfactory results.

Botulinum toxin (botox), a neurotoxin released from *Clostridium botulinum*, prevents the release of acetylcholine from presynaptic axon terminals. By causing temporary synaptic blockade, botulinum toxin has been shown to relax the internal anal sphincter when injected into it. Gonyautoxin, a type of phytotoxin produced by dinoflagellates has also been tried in place of botox.

Occasional reports of accidental injection of the toxin in the surrounding tissue resulting into a general poisoning, hematoma and infection have been reported. A need for repeat injection, high cost and slow healing is few other pitfalls in the use of botox therapy.

Less commonly, L-arginine ointment, potassium channel openers like topical minoxidil and nicorandil, alpha-1-adrenoceptor blockers like indoramin, Phosphodiesterase-5 inhibitors like sildenafil 10% ointment, ACE inhibitors like topical captopril (0.28%) and amino acid gel have also been tried with some success.

Surgical therapy

Anal dilatation was first described in 1838 and was popularized by Lord in the treatment of hemorrhoids. Lord's original eight finger dilatation was abandoned in favor of a more gentle four finger stretch for four minutes and more recently a standardized dilatation procedure using a Parks' retractor opened to 4.8 cm or with a 40 mm rectosigmoid balloon has been advocated in the treatment of chronic anal fissures. Although anal dilatation results in successful healing of anal fissures comparable to lateral internal sphincterotomy, there is no way to reliably standardize the procedure and both the internal and external sphincters can be disrupted or fragmented in an irregular manner. Anal dilatation has a higher risk of incontinence than that of lateral internal sphincterotomy. However, some authors still support a policy of gentle anal dilatation as the treatment of choice in chronic anal fissure. The number of fingers used and the amount of time the stretch is applied varies among surgeons.

Lateral internal sphincterotomy

This is the current surgical procedure of choice. Sphincterotomy was first described in 1835 and can be carried out using an open or a subcutaneous technique and under local or general anesthesia. Posterior internal sphincterotomy results in a keyhole deformity of the anal canal and a wound, which is slow to heal, presumably because of the inadequate blood supply.

The purpose of an internal sphincterotomy is to cut the hypertrophied internal sphincter, thereby releasing tension and allowing the fissure to heal. In lateral internal sphincterotomy, only the internal sphincter is cut; and the external sphincter is left undisturbed.

In the treatment of chronic anal fissures, the surgeon may choose to excise the fissure in conjunction with the lateral sphincterotomy. More simply, instead of excising the fissure along with the sphincterotomy and worrying whether it will heal, the surgeon can excise the hypertrophied papillae and the skin tag and leave the fissure to heal on its own. Sometimes, long-standing chronic fissures do not heal, even with an adequate sphincterotomy, and an advancement flap must be performed to cover the defect in the mucosa.

Stool softeners and fiber supplementation are necessary after the surgery. Fiber supplementation is recommended indefinitely to prevent future problems with constipation. Follow-up care is usually to ensure that the wound is healing appropriately and that the fissure and the spasm has resolved.

Surgical complications

Complications from surgery for anal fissure include infection, bleeding, fistula development, and disturbances of continence.

The incidence and definition of incontinence vary dramatically from study to study and among the different procedures. Incontinence rates are much lower with a properly performed internal sphincterotomy than with sphincter stretch, and these rates depend on the definition of incontinence. In most patients, the minor soiling or incontinence to flatulence that may occur in the immediate postoperative period usually resolves without any long-term sequel.

Points to ponder

- Once a fissure is diagnosed, initial treatment should include topical and oral treatment with dietary modification. If after 6 weeks of treatment, fissure persists and is symptomatic, the patient should be referred to secondary care. However, those patients having persistent but asymptomatic fissures should be prescribed with a further course of topical or oral treatment.
- Efforts should concentrate on developing non-surgical treatment.
- Almost two-thirds of patients can be treated without surgery.
- Medications chosen should have minimum side effects.
- Oral preparations should be the best choice to address compliance issues. Surgery should be reserved for those failing non-surgical treatment. Internal sphincterotomy should be the choice of surgery.
- Chemical Cauterization, use of direct current probe, anal dilatation using anoscope or recto-sigmoid balloon are few other options proposed. However, they are not substantiated with benefits on long term follow up and thus are not found employed in most part of the world.
- Drug therapy in chronic anal fissure includes oral nifedipine, diltiazem, lacidipine, bethnecol, salbutamol and indoramine.
- Local Applications include- 2% GTN ointment, diltiazem and L-arginine gel. However, increasing incidences of adverse effects and decreasing efficacy in long term have been the major drawbacks of these medications.
- Fissurectomy, fissurotomy, fissurectomy with skin grafting and posterior anal sphincterotomy are fraught with wound complication like delayed wound healing, infective complication and long convalescence period. Though a gentle anal stretch is still favored by surgeons in some parts of the world, it should be abandoned as it leads to disruption of both the internal and external sphincters in an irregular manner.
- Both open and closed methods of sphincterotomy are equally effective. Surgery is highly efficacious and successful in curing the fissure in more than 90% of patients. A systematic review of randomized surgical trial shows that the overall risk of incontinence is about 10%.

HEMORRHOIDS

Hemorrhoids and their symptoms are one of the most common afflictions in the human population. They can occur at any age and can affect both women and men. Unfortunately, hemorrhoids tend to get worse over time, unless it is diagnosed and treated as soon as it occurs. The presence of hemorrhoids alone, however, does not constitute disease. "Hemorrhoidal disease" requires the presence of pathologic changes that lead to bleeding, prolapse, thrombosis, or a combination thereof. The term "hemorrhoids" is frequently misused by patients to describe other anorectal problems, while the actual prevalence is much less. Although men and women are equally affected, men are more likely to seek treatment. The prevalence of hemorrhoids increases with age until the seventh decade, at which point there seems to be a slight decrease.

Hemorrhoidal complaints are usually not associated with other medical conditions or diseases. However, patients with inflammatory bowel disease have an increased risk of hemorrhoidal complaints: and hemorrhoidal problems occur frequently. Unusual hemorrhoidal presentations and findings should alert the clinician to search for inflammatory bowel disease. No relation between hemorrhoids and cancer has been found.

Pathophysiology

The term hemorrhoid is usually related to the symptoms caused by hemorrhoids. Hemorrhoids are present in healthy individuals. When these vascular cushions produce symptoms, they are referred to as hemorrhoids.

Many studies have proved that low-fiber diets cause small-caliber stools, which result in straining during defecation. This increased pressure causes engorgement of the hemorrhoids, possibly by interfering with venous return. Aging causes weakening of the support structures, which facilitates prolapse. Weakening of support structures can occur as early as the third decade of life.

Patients who report hemorrhoids have an anal canal resting tone that is higher than normal. Pregnancy clearly predisposes women to develop hemorrhoids, although the etiology is unknown. Notably, most patients revert to their previously asymptomatic state after delivery. The relationship between pregnancy and hemorrhoids is due to hormonal changes and direct pressure of the growing uterus impairing anal venous return. A family history of hemorrhoids likely reflects a particular type of diet consumed by the whole family or a bias toward seeking treatment as opposed to a true increased incidence. In the general population, dietary factors (spices, alcohol) played a predominant role, as well as episodes of acute constipation.

Relevant anatomy

Hemorrhoids are not varicosities; they are clusters of vascular tissue, smooth muscle i.e. Treitz muscle, and connective tissue lined by the normal epithelium of the anal canal.

Hemorrhoids result from the pathological changes in prolapsed anal cushions. They are symptomatic due to pathological enlargement and distal displacement of the cushions. Hemorrhoids are categorized into internal and external hemorrhoids. The dentate or pectinate line anatomically separates these categories. External hemorrhoidal veins are found circumferentially under the anoderm.

Presentation (Figg. 5 e 6)

Internal hemorrhoids

Internal hemorrhoids can bleed, prolapse, and, as a result of the deposition of an irritant onto the sensitive perianal skin, cause perianal itching and irritation.

Internal hemorrhoids can produce perianal pain by prolapsing and causing spasm of the sphincter complex around the hemorrhoids. This spasm results in discomfort while the prolapsed

hemorrhoids are exposed. Prolapse occurs with a bowel movement and is associated with an uncomfortable sensation of fullness and incomplete evacuation; patients complain of a lump at the anal verge. Soiling may occur in third and fourth degree hemorrhoids as a result of impaired continence or production of mucus discharge. Internal hemorrhoids most commonly cause painless bleeding with bowel movements.

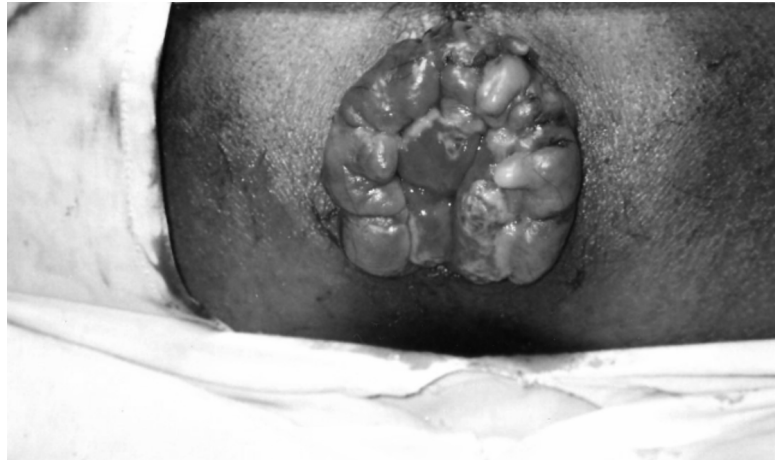


Fig. 5 - Hemorrhoids with edema, fibrosis and ulcerations.

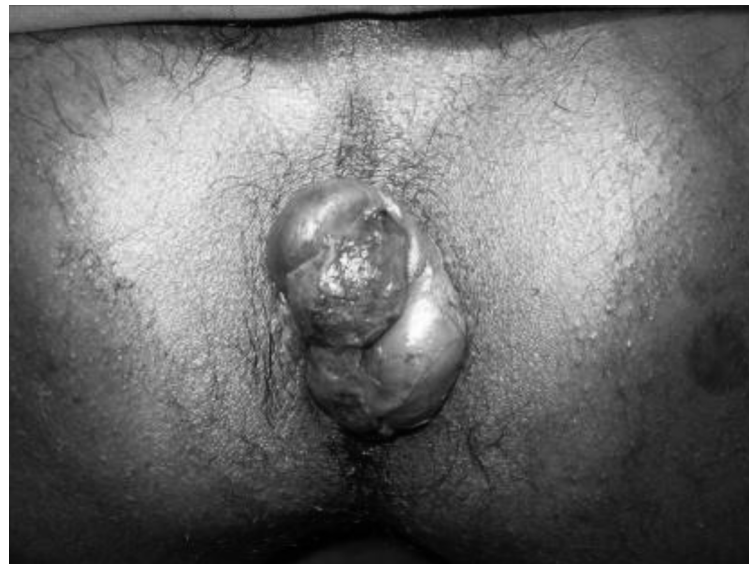

Fig. 6 - Interno-external hemorrhoids.

External hemorrhoids

External hemorrhoids cause symptoms in two ways. First, acute thrombosis of the underlying external hemorrhoidal vein can occur. Acute thrombosis is usually related to a specific event, such as physical exertion, straining with constipation, a bout of diarrhea, or a change in diet. These are acute, painful events. Pain results from rapid distension of innervated skin by the clot and surrounding edema. The pain lasts 7-14 days and resolves with resolution of the thrombosis. With this resolution, the stretched anoderm persists as excess skin or skin tags. External thromboses occasionally erode the overlying skin and cause bleeding.

External hemorrhoids can also cause hygiene difficulties, with the excess, redundant skin left after an acute thrombosis i.e. skin tags being accountable for these problems.

Treatment

Treatment will be guided by degree and severity of symptoms. Further evaluation of rectal bleeding is prudent in patients with alteration of bowel habit, blood mixed with stool, or with risk factors like coagulation abnormalities, immuno-suppressive diseases, etc.

Treatment is divided by the cause of symptoms, into internal and external treatments. Internal hemorrhoids do not have cutaneous innervations and can therefore be destroyed without anesthetic.

Because it is believed that straining and a low-fiber diet cause hemorrhoidal disease, conservative treatment includes increasing fiber and liquid intake and retraining in toilet habit. Decreasing straining and constipation shrinks internal hemorrhoids and decreases their symptoms; therefore, first-line treatment of all first- and second-degree internal hemorrhoids should include measures to decrease straining and constipation. Dietary supplementation with micronised semi-synthetic flavonoids is a common alternative treatment. These drugs act to improve venous tone and inhibit the release of prostaglandins. The use of flavonoid in the treatment of hemorrhoids associated with pregnancy did not adversely affect pregnancy, fetal development, birth weight, infant growth, or infant feeding.

Today, modern as well as traditional drugs are being increasingly used in all grades of symptomatic hemorrhoids. These drugs either orally or topically are used as a part of conservative management or as an adjuvant to invasive outpatient procedures. Calcium dobesilate, nitrates and nifedipine have also been effective and well tolerated in the medical treatment of hemorrhoids. However, drug treatment is not aimed at curing hemorrhoids. The prime objective of drug therapy is to control the acute phase like bleeding, so that definitive therapy like banding, injection sclerotherapy, infrared photocoagulation, cryotherapy or surgery can be scheduled at a convenient time.

Many patients see improvement or complete resolution of their symptoms with the above conservative measures. Aggressive therapy is reserved for patients who have persistent symptoms after 1 month of conservative therapy. Treatment is directed solely at symptoms and not at the appearance of the hemorrhoids. Similarly, treatment of the underlying disease often relieves anal symptoms. Patients with ulcerative colitis can tolerate aggressive surgery if needed. Aggressive treatment is avoided in patients with Crohn's disease, especially if the rectal mucosa is acutely inflamed. Abscesses must be drained as soon as possible, despite active disease elsewhere.

Several methods to destroy internal hemorrhoids are available; they include rubber band ligation, sclerotherapy injection, infrared photocoagulation, laser ablation, radiowave ablation, carbon dioxide freezing, Lord dilatation, stapled hemorrhoidectomy, and surgical resection. All of these methods except stapled hemorrhoidectomy and surgical resection are considered nonoperative treatments and should be the first-line treatment of all first- and second-degree internal hemorrhoids that do not respond to conservative therapy. Cryotherapy and sclerotherapy are infrequently used today. Most experienced surgeons use 1 or 2 techniques exclusively. Some of the conventional approaches are not without potential complications. Injection sclerotherapy has resulted in cases of anaphylactic shock. Cryotherapy is cumbersome to perform and is associated with severe rectal pain and discharge. Manual dilation often requires general anesthetic and admission to the hospital. If dilation is not performed carefully the results may be disastrous. Septic complications including death have resulted from rubber band ligation.

The potential disadvantages of sclerotherapy, banding, manual dilation, and surgery had led to the development of another row of nonexcisional techniques for the treatment of hemorrhoidal disease. Infrared photocoagulation, bipolar diathermy, YAG and CO₂ lasers, radiowaves and direct current electrotherapy have been added to the plethora of modalities to consider. These modalities aim to affect sclerosis of the vascular root and to fix the mucosa to the underlying submucosa and muscle.

None of the newer modalities except the infrared coagulation are as widely used, or have the demonstrated effectiveness, as the previously mentioned techniques.

Doppler-guided hemorrhoid arterial ligation or transanal hemorrhoidal dearterialisation represents a new approach to the treatment of internal hemorrhoids. With this device selective ligation of the arteries supplying the hemorrhoids can be done after identifying them using an ul-

trasound sensor (Fig. 7). The procedure can be performed on ambulatory patients under local anesthesia. An anoscope is used which incorporates a Doppler head. The superior hemorrhoidal arteries are identified under guidance of the arterial Doppler sound and ligated through a window located just above the Doppler head. The procedure requires about 30 minutes. This procedure is less painful with earlier return to work. But as it has high recurrences in prolapsing hemorrhoids, it is now supplemented with hemorrhoidal mucopexy where few transfixing sutures are applied over the hemorrhoidal cushion to control prolapse.

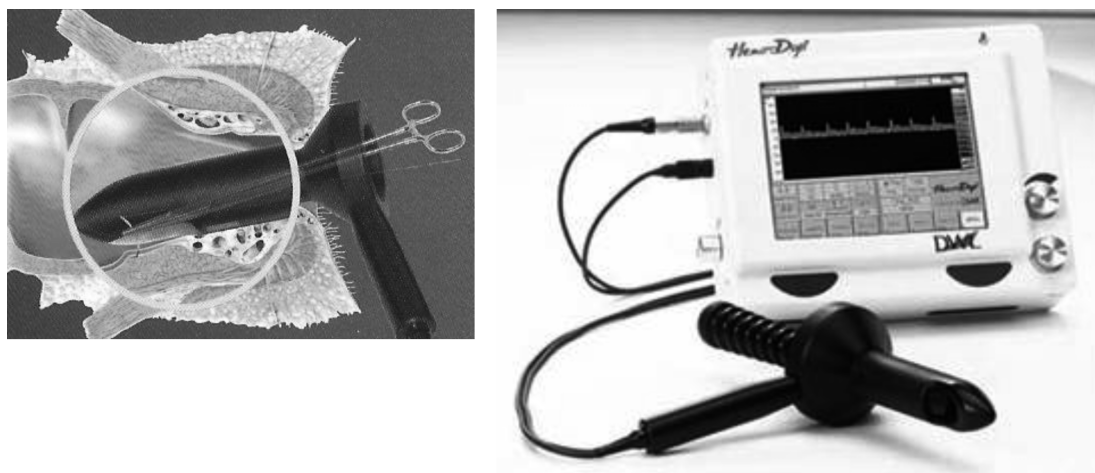


Fig. 7 - Doppler-guided hemorrhoidal artery ligation procedure and the device.

Surgical therapy

Operative resection is reserved for patients with third- and fourth-degree hemorrhoids, patients who fail nonoperative therapy, and patients who also have significant symptoms from external hemorrhoids or skin tags. Several operative techniques have been described. Milligan-Morgan's open hemorrhoidectomy is most commonly used and is widely considered to be the most effective surgical technique for treating hemorrhoids. Other techniques, such as Ferguson's closed hemorrhoidectomy and Parks' submucosal hemorrhoidectomy, are technically more complex.

Use of alternate energy sources like radiofrequency (Ligasure) and harmonic ultrasonic waves are emerging as quicker and less painful tools for performance of hemorrhoidectomy. Laser hemorrhoidectomy, as opposed to conventional scalpel and electrocautery techniques, is associated with many myths. This technique is proposed as a painless or with decreased pain and shortened healing times, however, no documented studies support these claims. It has no advantages over standard techniques; it is also quite expensive.

The surgeon's choice of technique is primarily based on personal experience and technical training, and only a competently performed technique produces satisfying results. If technical guidelines are rigorously followed, the feared complications associated with surgical procedures, such as anal stricture and sphincteric injuries, are largely reduced.

Stapled hemorrhoid surgery, or procedure for prolapsing hemorrhoids (PPH), has become popular these days. The technique involves placing a suture in the mucosal and submucosal layers circumferentially, approximately 3-4 cm above the dentate line. The stapler is placed and slowly closed around the purse string. Care is taken to draw excess internal hemorrhoidal tissue into the stapler. The stapler is fired, resecting the excess tissue and placing a circular staple line above the dentate line (Fig. 8). This results in resection of excessive internal hemorrhoidal tissue, pexy of the internal hemorrhoidal tissue left behind, and interruption of the blood supply from above. PPH can be done as an outpatient procedure, using local anesthesia with intravenous (IV) sedation.

PPH does not directly affect the external tissue. Reports have described shrinking of external hemorrhoidal tissue after PPH, probably from decreased blood flow. Good results from PPH

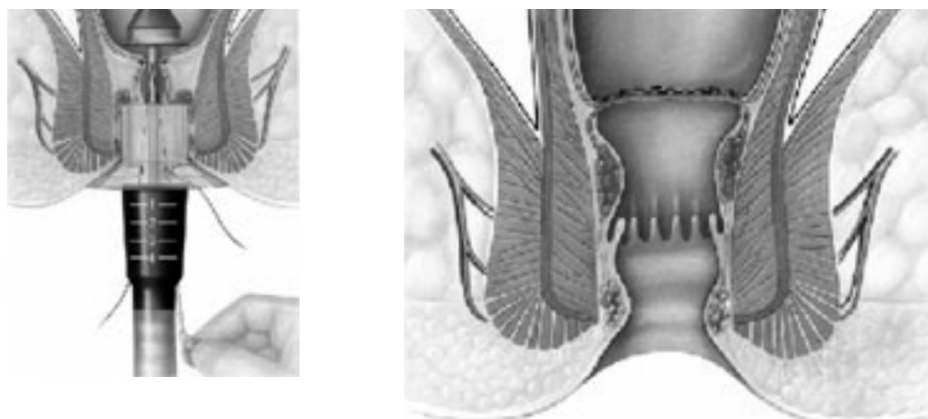


Fig. 8 - Procedure for prolapse and hemorrhoids.

combined with judicious excision of occasional skin tags also have been reported. However, stapling increases operative costs; advanced surgical skills are necessary; and there is a learning curve. Stapled hemorrhoidectomy may cause a full thickness excision of the rectal wall and injuries to the anal sphincter, and it does not allow for simultaneous treatment of concomitant anal disease.

In the postoperative course, attention to regular and soft bowel movements is important. Bulk agents and oral fluids are important. Bathing in tubs for comfort and hygiene is part of the routine. Judicious narcotic administration relieves pain. External hemorrhoid symptoms are generally divided into problems with acute thrombosis and hygiene/skin tag complaints. The former respond well to office excision, while operative resection is reserved for the latter. It is to be remembered that therapy is directed solely at the symptoms, not at aesthetics.

When performed well, operative hemorrhoidectomy should have a 2-5% recurrence rate. Nonoperative techniques, such as rubber band ligation, produce recurrence rates of 30-50% within 5-10 years. However, these recurrences can usually be addressed with further nonoperative treatments. Long-term results from PPH are unavailable at this time.

Hemorrhoids in HIV-positive patients

Anorectal disease is now widely recognized as one of the most common problems occurring in patients infected with human immunodeficiency virus. Hemorrhoidal disease is common in these patients, often resulting from chronic diarrhea brought on by medications.

There seems to be a common belief that anorectal surgery in an HIV positive patient is an invitation to disaster. Early reports describing outcomes of HIV positive patients undergoing anorectal procedures uncovered significant problems in wound healing and excessive perioperative morbidity. Recent reports, however, have demonstrated that selective management will result in high rates of symptomatic relief and complete wound healing after hemorrhoid surgery without excessive morbidity and mortality.

Because many investigators have suggested that HIV positive patients frequently have a sub-clinical coagulopathy, one might expect post hemorrhoidectomy hemorrhage to be more common in HIV positive patients than HIV- patients. However, this was not noticed in reports of many workers operating on hemorrhoids.

Another reason for the colorectal surgeons to be reluctant to perform anorectal operations in HIV positive patients is the reportedly high incidence of impaired wound healing. Wound healing is a significant problem after anorectal operations in patients infected with HIV, especially when the CD4 count is <50 , L.

Besides better patient selection, use of antiviral agents in HIV positive patients may promote healing of anorectal wounds. Malnourishment could be another cause for delay in wound healing. It is observed that healthy, asymptomatic HIV positive individuals may be treated exactly as HIV-negative patients would be for hemorrhoidal disease.

Points to ponder

- Only a third of patients with symptomatic hemorrhoids seek medical help.
- Hemorrhoids can cause bleeding, pain and itching but other anorectal diseases need to be ruled out.
- Current guidelines recommend a minimum of anoscopy and flexible sigmoidoscopy for bright-red rectal bleeding.
- There is still no consensus on optimal treatment.
- Symptoms have historically been treated with dietary modifications, incantations, voodoo, quackery, and application of a hot poker.
- The adverse effects of these treatments have a direct relationship to whether patients relay persistent or recurrent complaints to the clinician or return for further treatment.
- Improvements in the understanding of the anatomy of hemorrhoids have prompted the development of new and innovative methods of treatment.
- The most appropriate treatment is tailored to the individual patient.
- Using a therapeutical regime orientated to the classification of hemorrhoidal disease offers high healing rates with a low rate of complications and recurrences.
- Conservative treatment consists of dietary and lifestyle modifications.
- Standard interventional procedures in outpatient treatment are rubber band ligation and infra-red coagulation.
- Among the surgical options for prolapsed hemorrhoids, formal hemorrhoidectomy using newer devices like radiofrequency and ultrasonic waves now competes with stapled hemorrhoidopexy, which professed as less painful with shorter convalescence period but may have a higher recurrence rate and needs further long term evaluation.

* * *

References

- Tankova L, Yoncheva K, Kovatchki D, Doytchinova I. Topical anal fissure treatment: placebo-controlled study of mononitrate and trinitrate therapies. *Int J Colorectal Dis* 2009; 24:461-4.
- Cross KL, Massey EJ, Fowler AL, Monson JR. The management of anal fissure: ACPGBI position statement. *Colorectal Dis* 2008; 10:1-7.
- Wray D, Ijaz S, Lidder S. Anal fissure: a review. *Br J Hosp Med (Lond)* 2008; 69:455-8.
- Nicholls J. Anal fissure; surgery is the most effective treatment. *Colorectal Dis* 2008; 10:529-30.
- Lubowski D. Topical therapy is first line treatment for chronic anal fissure because of the risk of incontinence with sphincterotomy. *Dis Colon Rectum* 2008; 51:1157-8.
- Skricka T, Vedra P. New approaches in ambulatory proctology. *Acta Chir Iugosl* 2002; 49:57-61.
- Middleton SB, Lovegrove RE, Reece-Smith H. Management of haemorrhoids: Symptoms govern treatment. *BMJ* 2008; 336:461.
- Tamelis A, Latkauskas T, Pavalkis D, Saladinskas Z, Vagdys S. Evidence based treatment of hemorrhoids. *Acta Chir Iugosl* 2008; 55:127-32.
- Ohning GV, Machicado GA, Jensen DM. Definitive therapy for internal hemorrhoids--new opportunities and options. *Rev Gastroenterol Disord* 2009; 9:16-26.
- Herold A. [Therapy of hemorrhoidal disease]. *Chirurg* 2006; 77:737-47.