

*G Chir Vol. 30 - n. 10 - pp. 426-428
Ottobre 2009*

Parasitic infestation as cause of acute appendicitis

O. KARATEPE¹, G. ADAS¹, M. TUKENMEZ², M. BATTAL², M. ALTIOK², S. KARAHAN²

SUMMARY: Parasitic infestation as cause of acute appendicitis.

O. KARATEPE, G. ADAS, M. TUKENMEZ, M. BATTAL, M. ALTIOK, S. KARAHAN

Aim. The role of parasitic infestation in the cause of acute appendicitis has been long time discussed. The aim of this study is to evaluate the role of parasitic infestation in the etiology of acute appendicitis.

Patients and methods. This retrospective study includes 5.100 patients undergoing surgical therapy for acute appendicitis between 1996 and 2005. Patients were divided into two groups according to the presence of the parasites in the appendix lumen: in Group 1 (n=24) we observed parasitic infestation, whereas in patients of the Group 2 (n=5.076) no parasitic infestation was present.

Results. Parasitic infestation was detected in 24 (0.5%). Of 24 parasitic infestation, 12 (50%) were enterobiasis, 6 (25%) were schistosomiasis, 4 (17%) were Ascaris lumbricoides, and 2 (8%) were Taenia saginata. The ratios of the patients with suppurative, gangrenous or perforative appendicitis were similar in both groups. The ratio of the normal histological findings in the Group 1 patients (25%) was significantly higher than that in the Group 2 patients (4.8%, p=0.001)

Conclusion. Although parasitic infestation may result in symptoms resembling acute appendicitis, parasitic infestation can't be considered in the etiology of acute appendicitis.

RIASSUNTO: Infestazione parassitaria come causa di appendicite acuta.

O. KARATEPE, G. ADAS, M. TUKENMEZ, M. BATTAL, M. ALTIOK, S. KARAHAN

Scopo. Scopo dello studio è di verificare il ruolo, tuttora controverso, delle infestazioni parassitarie come possibile causa di appendicite acuta.

Pazienti e metodi. Nello studio retrospettivo sono stati inclusi 5.100 pazienti operati per appendicite acuta tra il 1998 e il 2005. I pazienti sono stati divisi in due gruppi, a seconda della presenza (gruppo I, n = 24) o meno (gruppo II, n = 5.076) di parassiti nel lume appendicolare.

Risultati. In 24 pazienti (0,5%) l'esame istologico ha dimostrato la presenza di infestazione parassitaria: in 12 casi (50%) da Enterobius vermicularis, in 6 (25%) da schistostomi, in 4 (17%) da Ascaris lumbricoides, in 2 (8%) da Taenia saginata. Le percentuali di pzienti con appendicite flemmonosa, gangrenosa o perforata sono risultate sovrapponibili nei due gruppi, mentre la percentuale di esami istologici del pezzo operatorio negativi è risultata significativamente maggiore nel gruppo I (25% vs 4,8%, p 0.001).

Conclusioni. Pur potendo l'infestazione parassitaria dare sintomi simili a quelli dell'appendicite acuta, raramente ne è causa.

KEY WORDS: Parasites - Infestation - Acute appendicitis - Surgery.
Parassiti - Infestazione - Appendicite acuta - Chirurgia.

Introduction

Appendicitis is the most common abdominal surgical emergency (1). There is an approximately 6% to 7% lifetime risk of appendicitis. Appendicitis is primarily a

disease of adolescents and young adults with a peak incidence in the second and third decades of life (1-3). Appendicitis is relatively more common in industrialized countries where a highly refined, low-fiber diet is typically consumed (4).

The cause of acute appendicitis is unknown but is probably multifactorial. Fecal stasis and fecaliths are the most common cause of appendiceal obstruction, followed by lymphoid hyperplasia, vegetable matter and fruit seeds, inspissated barium from previous radiographic studies, intestinal parasites, and tumors (2-6).

The aims of this clinical trial are to evaluate the in-

¹ Okmeydanı Training and Research Hospital, Istanbul, Turkey
Department of General Surgery

² Istanbul University, Istanbul Medical Faculty, Turkey
Department of General Surgery

© Copyright 2009, CIC Edizioni Internazionali, Roma

cidence between acute appendicitis and parasitic infestation and to evaluate the role of parasitic infestation in the etiology of acute appendicitis.

Patients and methods

Patients

This retrospective study included 5100 patients undergoing surgical therapy for acute appendicitis at Okmeydanı Teaching and Research Hospital of Istanbul, between 1996 and 2005. The diagnosis of acute appendicitis was based on history and clinical examination, elevated white blood cell count, and imaging studies such as ultrasonography. Patients were divided into two groups according to the presence or absence of parasites in the appendix lumen. In Group 1 (n=24) parasitic infestation was observed, whereas in Group 2 (n=5.076) parasitic infestation was absent.

Histopathological evaluation

All appendices were examined by histopathology. Pathological findings, possible presence of parasites and type of parasites were analyzed. The diagnosis of acute appendicitis was investigated when a polymorphonuclear neutrophil infiltrate was observed in the mucosa or deep layers. Histopathological classification of appendicitis was suppurative, gangrenous, and perforative. Demographic and pathological findings were assessed in both groups.

Statistical analysis

Data are reported as the mean \pm SD. Analysis was performed with the statistical package SPSS 10.1 (SPSS, Chicago, IL). Differences between parameters were compared with the *t*-test, and chi-square test.

Results

Patients

The mean age of the whole group was 24.9 \pm 21 years (range: 6-84 years). The male/female ratio was 1.8/1 (n=3331/1769). Of 5.100 patients, in 1.374 (27%) suppurative appendicitis was found, in 3.018 (59%) gangrenous appendicitis, in 462 (9%) perforative appendicitis, in 246 patients (4.8%) the histologic findings were normal. Table 1 shows demographic and histopathologic features of the patients with acute appendicitis.

Parasitic infestation was detected in 24 patients (0.05%). Of 24 parasitic infestations, 12 (50%) were enterobiasis (Fig. 1), 6 (25%) schistosomiasis, 4 (17%) ascaris lumbricoides, and 2 (8%) taenia saginata (Fig. 2). The parasites did not obstruct the lumen of the appendix in any patient.

Evaluation of patients with or without parasitic infestation

The mean ages were 17.5 \pm 10 years in Group 1 and 24.3 \pm 11 years in Group 2. The male/female ratios were 14:10 and 3321:1755 in Groups 1 and 2, respectively. There was not a significant difference between age and gender between Groups 1 and 2. The ratios of the patients with suppurative, gangrenous perforative ap-

TABLE 1 - DEMOGRAPHIC AND PATHOLOGIC FINDINGS IN PATIENTS WITH ACUTE APPENDICITIS.

Acute appendicitis (n = 5,100)	
Age, years (mean \pm SD)	24.9 \pm 21
Male:Female, n	3.331:1.769
Suppurative appendicitis, n (%)	1.373 (26,9%)
Gangrenous appendicitis, n (%)	3.014 (59%)
Perforative appendicitis, n (%)	461 (9%)
Normal histology n (%)	252 (4,9%)

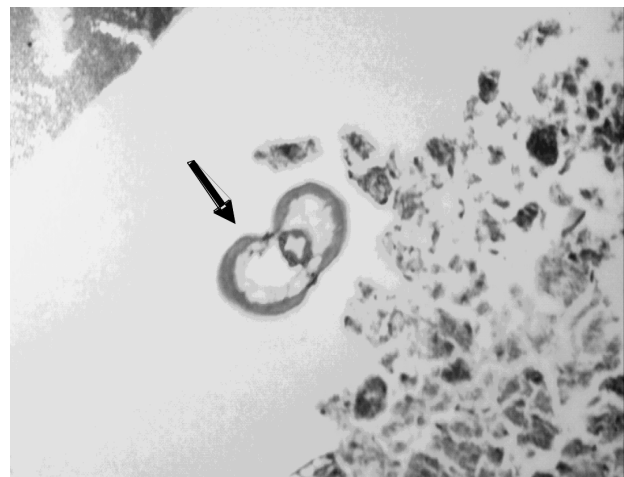

Fig. 1 - Ova of *Enterobius vermicularis* within the lumen of the appendix (H&E, 40x).

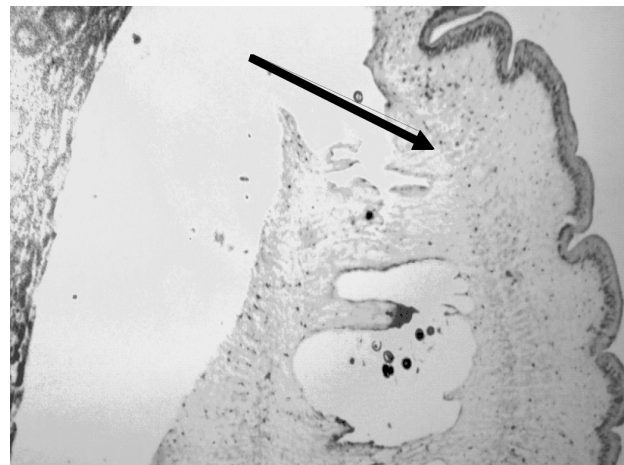


Fig. 2 - *Taenia saginata* within the lumen of the appendix (H&E, 40x).

pendicitis were similar in both groups. The ratio of the normal histological findings in Group 1 (25%) was significantly higher than that of the Group 2 (4.8%, *p*=0.001) (Tab. 2).

TABLE 2 - CORRELATION OF DEMOGRAPHIC AND PATHOLOGIC FINDINGS IN PATIENTS WITH OR WITHOUT PARASITIC INFESTATION.

Acute appendicitis (n=5100)	Group 1 (n=24)	Group 2 (n=5076)	P
Age, years (mean \pm SD)	17.5 \pm 10	24.3 \pm 11	NS
Male:Female, n	14:10	3.321:1.755	NS
Suppurative appendicitis, n (%)	6 (25%)	1.367 (27%)	NS
Gangrenous appendicitis, n (%)	10 (41.6%)	3.004 (59%)	NS
Perforative appendicitis, n(%)	2 (8.3%)	459 (9%)	NS
Normal histology, n (%)	6 (25%)	246 (4.8%)	0.01

NS = not significant

Discussion

Acute appendicitis is the most common cause of acute abdominal pain that requires surgical treatment (1, 2). The cause of acute appendicitis is unknown but is probably multifactorial; luminal obstruction and dietary and familial factors have all been suggested (3, 4). Appendicitis is more common in urban, industrialized societies and relatively rare in developing countries where a less-refined, high-fiber diet is typically consumed. Presumably, the diet in industrialized countries leads to hard stool, higher intracolonic pressure, and formation of fecaliths that can serve as obstructing agents in the appendiceal lumen (7, 8). Fecal stasis and fecaliths are the most common cause of appendiceal obstruction. Luminal obstruction leads to the development of acute ap-

pendicitis. As luminal pressure increases, mucosal ischemia develops. With vascular congestion, the appendiceal mucosa becomes hypoxic and begins to ulcerate, resulting in compromise of the mucosal barrier and leading to invasion of the appendiceal wall by intraluminal bacteria. Furthermore, stasis of intraluminal contents leads to bacterial overgrowth in the inspissated mucus (1, 4).

A very rare cause of appendicitis is parasitic infestation. The actual role of parasitic infestation as co-factor in appendicitis is still to debate. There is little evidence regarding the relationship between parasites and acute appendicitis (9-11). In even tropical countries, where intestinal parasitic infestation is quite common, appendiceal disease is not unusual (9, 10). Acute appendicitis might depend by obstruction of the lumen by parasites or secondary inflammation by the presence of parasite and/or its ova in the lumen (9-11). The presence of parasitic infestation may create acute infection by obstructing the lumen or leading to a secondary inflammation.

In our study, parasitic infestation was found 0.05% and the ratio of the normal histologic findings in the patients with parasitic infestation was significantly higher than that of the patients without parasitic infestation. We think that the diagnosis of appendicitis in case of normal histology (negative appendectomy) is high due to symptoms of infestation mimicking acute appendicitis. Intestinal parasites may produce symptoms which resemble acute appendicitis but parasitic infestation rarely causes it.

In conclusion, the low incidence of parasites among the appendectomy specimens and the high rate of negative appendectomy support the hypothesis that parasites are not a cause of appendicitis. Parasitic infestation must take place in the differential diagnosis of appendicitis in patients with doubtful clinical findings.

References

- Humes DJ, Simpson J. Acute appendicitis. *Br Med J.* 2006; 333: 530-4.
- Singh I, Collins RE. Right iliac fossa pain. *Br J Hosp Med.* 2005;66:76-8.
- Flasar MH, Goldberg E. Acute abdominal pain. *Med Clin North Am.* 2006;90:481-503.
- Kelly AOJ. The pathogenesis of appendicitis. *Phil Med J* 1899;21:119-37.
- Nordback I, Harju E. Inflammation parameters in the diagnosis of acute appendicitis. *Acta Chir Scand* 1988;154:43-48.
- Prystowsky JB, Pugh CM, Nagle AP. Current problems in surgery. Appendicitis. *Curr Probl Surg.* 2005;42:688-742.
- Addiss DG, Shaffer N, Fowler BS, Tauxe RV. The Epidemiology of appendicitis and appendectomy in the United States. *Am J Epidemiol* 1990;135:910-25.
- Barker DJ, Morris J, Nelson M. Vegetable consumption and acute appendicitis in 59 areas in England and Wales. *BMJ* 1986;292:927-30.
- Dorfman S, Cardozo J, Dorfman D, Villar DA. The role of parasites in acute appendicitis of pediatric patients. *Invest Clin* 2003; 44:337-40.
- Gupta SC, Gupta AK, Keswani NK, Singh PA, Tripathi AK, Krishna V. Pathology of tropical appendicitis. *J Clin Pathol* 1989;42:1169-72.
- Dorfman S, Talbot IC, Torres R, Cardozo J, Sanchez M. Parasitic infestation in acute appendicitis. *Ann Tro Med Parasitol* 1995; 89:99-101.