

*G Chir* Vol. 30 - n. 8/9 - pp. 374-376  
 Agosto-Settembre 2009

## Laparoscopic treatment of sigmoid colon intussusception by large malignant tumor. Case report

P. DELL'ABATE, P. DEL RIO, L. SOMMARUGA, M.F. ARCURI, M. SIANESI

**SUMMARY:** Laparoscopic treatment of sigmoid colon intussusception by large malignant tumor. Case report.

P. DELL'ABATE, P. DEL RIO, L. SOMMARUGA, M.F. ARCURI, M. SIANESI

*Intestinal intussusception is rare in adults, but common in children. The ileocolic or appendiceal types are more frequent compared to the colo-colic one.*

*We report successful laparoscopic left hemicolectomy in a patient with intussusception caused by a sigmoid tumor. Abdominal CT demonstrated a colo-colic intussusception at the level of the tumoral lesion with dilation of the proximal colon.*

*The patient underwent urgent laparoscopic oncologically radical left hemicolectomy. A 10 cm Pfannenstiel incision allowed the removal of the resected segment. The laparoscopic approach was feasible because the dilation was moderate; however in intussusception due to cancer laparoscopy can be safely performed following oncologic criteria if a correct and prompt diagnosis is achieved.*

**RIASSUNTO:** Trattamento laparoscopico di intussuscezione sigmoidea da carcinoma di grandi dimensioni. Case report.

P. DELL'ABATE, P. DEL RIO, L. SOMMARUGA, M.F. ARCURI, M. SIANESI

*L'intussuscezione intestinale è un'evenienza rara negli adulti, più comune in età pediatrica. Le sedi ileale e ileo-ciecale sono più frequenti rispetto alla sede colica.*

*Riportiamo il caso di un paziente affetto da intussuscezione da carcinoma del sigma. La TC addominale pre-operatoria dimostrava la presenza di intussuscezione colo-colica a livello della lesione tumorale con dilatazione del colon a monte. Il paziente è stato sottoposto in urgenza a emicolectomia sinistra laparoscopica. Si è proceduto a estrazione del pezzo operatorio tramite incisione di Pfannenstiel di 10 cm. Il trattamento laparoscopico è risultato sicuro poiché la dilatazione a monte era di grado moderato.*

*Nel caso di intussuscezione colica da carcinoma l'approccio laparoscopico può essere condotto in sicurezza secondo criteri oncologici se è stata posta preoperatoriamente una corretta diagnosi.*

**KEY WORDS:** Bowel obstruction - Colon intussusception - Laparoscopic colectomy.  
 Ostruzione intestinale - Intussuscezione colica - Colectomia laparoscopica.

### Introduction

Intestinal intussusception is more frequent in children (95%), among which it is mostly idiopathic than in adults (1). In the adult an organic cause is more often identified (90% of the cases). Among intussusceptions, the colo-colic type is rare compared to entero-enteric and entero-colic, and may be caused by benign or malignant tumor.

We report a case of successful laparoscopic left hemicolectomy for intussusception due to a sigmoid tu-

mor without preoperative reduction. If complete bowel obstruction is present and bowel dilatation is severe, i.e. if the diagnosis is delayed and reduction is not possible, laparoscopy and primary anastomosis may be difficult.

### Case report

A 66 years old male has been admitted to our Unit for bowel obstruction. The patient, affected by a sigmoid neoplasia (mucinous adenocarcinoma), recently diagnosed in another hospital, complained of abdominal pain localised to the lower quadrants not associated with nausea or vomiting.

The abdominal X-ray demonstrated obstruction of the sigmoid and a few air-fluid levels. The abdominal ultrasonography was limited by the extensive meteorism and not able to identify the sigmoid tumor and intussusception. The abdominal CT, with intravenous and rectal contrast, showed a neoplastic mass, located at 25

University of Parma  
 Surgical Department  
 Unit of General Surgery and Organ Transplantation  
 © Copyright 2009, CIC Edizioni Internazionali, Roma

cm from the anal verge, and a colo-colic intussusception at that level with proximal colon dilation. The malignant nature of the mass, had been already confirmed by endoscopic biopsies performed elsewhere, although it was impossible to proceed beyond the tumor during the exam and the intussusception had not been diagnosed. No local or distant metastases were detected on CT (Fig. 1). The imaging suggesting a localised neoplasm and mild bowel distension, encouraged to attempt a laparoscopic approach.

An urgent laparoscopy with radical left hemicolectomy following oncologic criteria was performed. Despite the difficult mobilisation of the splenic flexure, a radical excision was achieved. The colonic segment was then exteriorised and resected through a Pfannenstiel incision and a colo-rectal end-to-end anastomosis (Knight-Griffen) was performed (Fig. 2).

The postoperative course was unremarkable and the patient was discharged on postoperative 6<sup>th</sup> day. The postoperative staging of colon was mucoid adenocarcinoma (10x6x7 cm) T2, N2, M0, G3, with 22 positive lymphonodes out of 64 retrieved.

## Discussion

Only 5-10% of all the intussusception are located in the large bowel (2-4) and are responsible of 1% of all the colonic obstructions (1). While in the children they are mainly idiopathic, in the adult underlying neoplastic causes are often identified. Adenocarcinomas of the large bowel are responsible of 70% of malignant (3-6), while 30% are benign. The most representative of these latter lesions are: lipomas, enteric duplication cysts, leiomyomas, cavernous angiomas, adenomatous polyps and lymphangiomas (1, 3, 5, 7).

In the pathogenesis of intussusception, peristalsis and ingested food push the lesion with the adjacent bowel which telescopes into the distal segment (3).

Rarely intussusception is identified preoperatively. This may be attributed to the non specificity of the clinical findings and the limited diagnostic power of colonoscopy and ultrasonography in hospitals were CT scan is not always available. If bowel obstruction is present, surgeons often decide an urgent laparotomy omitting further investigations, such as CT, in order to operate when dilation is not severe, reducing the risk of vascular stress and increasing the possibilities to perform an anastomosis. Half of the cases of intussusception are operated for intestinal obstruction, without a preoperative diagnosis of the cause of obstruction (1, 3, 11).

Some authors report a good sensitivity of ultrasonography in identifying intussusception. Images described as "pseudokidney" in the longitudinal view or as "target" and "doughnut" on the transversal view are suspicious (8-10). The known limit of ultrasound in urgency is the poor quality of the images if significant abdominal meteorism is present. The gold standard for the diagnosis of invagination is multislice CT (1, 4, 11-14) because it is able to demonstrate not only the presence of a mass but also to identify invagination, whereas colonoscopy alone may not be sufficient, especial-

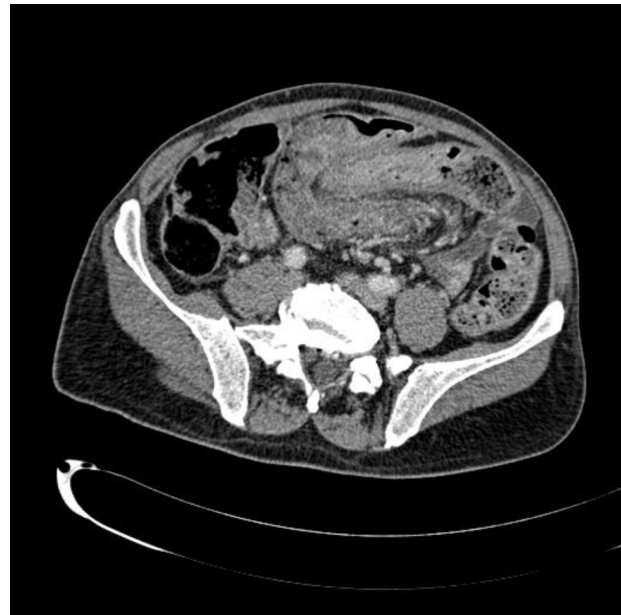

Fig. 1 - TC. Intussusception of sigma by carcinoma.

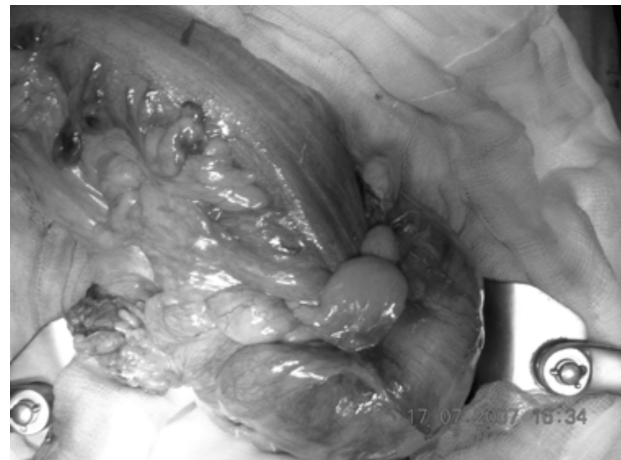


Fig. 2 - Intraoperative intussusception of the sigma.

ly if there is a stenosis that cannot be overpassed (15-19).

The treatment of this pathology has not been standardised and needs to be correlated to the time of diagnosis both of the tumor and invagination and to the clinical situation. Some authors reported a successful reduction of invagination with the use of a transanal drainage tube (19-20). However this procedure sometimes cannot be performed and is not complication-free such as iatrogenic perforation, endoluminal or transperitoneal seeding of the tumor, mucosal necrosis and venous embolization.

Prompt surgical treatment, as in our experience, is indicated to avoid vascular stress of the bowel wall and

further distension that could compromise the possibility of primary one-stage resection.

Like other authors, we prefer to perform *en bloc* the resection of the neoplastic lesion (1, 3, 17, 18, 21) and reduction of invagination. Some authors make the reduction to preserve the sphincter function (17), others

prefer a two-stage procedure, performing first a stoma (15) and the anastomosis in a second procedure.

Our experience, like that of Ki-Jae et al. (17), suggests that a prompt diagnosis is fundamental to pursue a laparoscopic approach, following oncological criteria and performing a primary anastomosis.

## References

1. Azar T, Berger DL. Adult intussusception. *Ann Surg* 1997; 226:134-8.
2. Singh S, Baboo ML, Pathak IC. Cystic lymphangioma in children: report of 32 cases including lesions at rare sites. *Surgery* 1971;69:947-951.
3. Begos DG, Sandor A, Modlin IM. The diagnosis and management of adult intussusception. *Am J Surg* 1997; 173:88-94.
4. Warshauer DM, Lee JKT. Adult intussusception detected at CT or MR imaging: clinical-imaging correlation. *Radiology* 1999; 212:853-860.
5. Nagorney DM, Sarr MG, McIlrath DC. Surgical management of intussusception in the adult. *Ann Surg* 1981;193:230-6.
6. Rosière A, Cannière L, Frangi R, Michel LA. Early diagnosis of adult intussusception at four different locations. *Acta Chir Belg* 1994; 94:314-7.
7. Carter CR, Morton AL. Adult intussusception in Glasgow, UK. *Br J Surg* 1989;76:727.
8. Weissberg DL, Scheible W, Leopold GR. Ultrasonic appearance of adult intussusception. *Radiology* 1977; 124:791-2.
9. Swischuk LE, Hayden CK, Boulden T. Intussusception: indications for ultrasonography and an explanation of doughnut and pseudokidney signs. *Pediatr Radiol* 1985;15:388-91.
10. Boyle MJ, Arkell LJ, Williams JT. Ultrasonic diagnosis of adult intussusception (Letter). *Am J Gastroenterol* 1993;88:617-8.
11. Eisen LK, Cunningham JD, Aufses AH Jr. Intussusception in adults: institutional review. *J Am Coll Surg* 1999; 188: 390-395.
12. Bar-Ziv J, Solomon A. Computed tomography in adult intussusception. *Gastrointest Radiol* 1991;16:264-6.
13. Takeuchi K, Tsuzuki Y, Ando T, Sekihara M, Hara T, Kori T, Kuwano H. The diagnosis and treatment of adult intussusception. *J Clin Gastroenterol* 2003; 36: 18-21.
14. Gayer G, Apter S, Hofmann C, Nass S, Amitai M, Zissin R, Hertz M. Intussusception in adults: CT diagnosis. *Clin Radiol* 1998; 53: 53-57.
15. Matsuda K, Suda K, Tamura K, Deguchi T, Yamazaki E, Yago H, Inaba T, Takeshima T, Adachi M, Okinaga K. Surgical management of adult sigmoid colon intussusception caused by a malignant tumor: report of a case. *Surg Today* 2003;33:768-771.
16. Tae OK, Jung HL, Gwang HK, Jeong H, Dae HK, Geung AS, Mong C. Adult intussusception caused by cystic lymphangioma of the colon: a rare case report. *World J Gastroenterol* 2006;12 (13):2130-2132.
17. Ki-Jae P, Hong-Jo C, Sung-Heun K, Sang-Young H, Sook-Hee H, Jin-Han C, Hyung-Ho K. Sigmoidrectal intussusception of adenoma of sigmoid colon treated by laparoscopic anterior resection after sponge-on-the-stick-assisted manual reduction. *World J Gastroenterol* 2006;12(1): 146-149.
18. Brozzetti S, Papa o, Polistena A, Mosiello G, Annessi P, Alessi G, Cavallaro A. Recurrent intussusception of the sigmoid colon caused by a transanal protruding sessile tubulo-villous malignant polyp. *Anticancer Res.* 2000; 20(6C):4697-4700.
19. Kitahara H, Horiuchi A, Nakayama Y, Yokoyama T, Koyama Y, Morikawa A, Miyazawa K, Hayashi K. Retrograde intussusception caused by a sigmoid colonic tumor: reduction by a use of a transanal drainage tube. *Gastrointest endosc* 2005; 61(3); 482-4.
20. Horiuchi A, Maeyama H, Ochi Y, Morikawa A, Miyazawa K. Usefulness of Dennis Colorectal Tube in endoscopic decompression of acute, malignant colonic obstruction. *Gastroint Endosc* 2001;54:229-32.
21. Weillbaecher D, Bolin JA, Hearn D, Ogden W. Intussusception in adults: review of 160 cases. *Am J Surg* 1971; 121:531-35.