

*G Chir Vol. 28 - n. 11/12 - pp. 425-427  
Novembre-Dicembre 2007*

**casistica clinica**

## Spontaneous ruptured pheochromocytoma: a case report

A. ROSSI, M. PICCHIO<sup>1</sup>, D. PALIMENTO, B. CALÌ<sup>1</sup>, A. CALIENDO

**SUMMARY: Spontaneous ruptured pheochromocytoma: a case report.**

A. ROSSI, M. PICCHIO, D. PALIMENTO, B. CALÌ, A. CALIENDO

*We present a rare case of intra-abdominal hemorrhage due to a ruptured pheochromocytoma. Our patient presented with signs of shock. By emergency surgery, an hemorrhagic pheochromocytoma of the left adrenal gland was removed. The recover was uneventful. In cases of suspected hemorrhagic pheochromocytoma with severe shock, prompt surgery is mandatory and catecholamines administration may be crucial to resolve hypotension and guarantee an uneventful recovery.*

**RIASSUNTO: Rottura spontanea di feocromocitoma: a proposito di un caso.**

A. ROSSI, M. PICCHIO, D. PALIMENTO, B. CALÌ, A. CALIENDO

*Presentiamo un caso di emorragia addominale secondaria a rottura di un feocromocitoma. Il paziente è giunto alla nostra osservazione con segni di shock ed è stato sottoposto ad intervento chirurgico in urgenza. Si è proceduto all'asportazione di un feocromocitoma emorragico della ghiandola surrenale sinistra. Il decorso postoperatorio è stato regolare. In caso di sospetto di feocromocitoma emorragico con shock, l'intervento chirurgico di emergenza e il ricorso all'infusione di catecholamine per risolvere l'ipotensione sono cruciali per garantire la risoluzione del quadro patologico.*

**KEY WORDS:** Pheochromocytoma - Abdominal hemorrhage - Emergency surgery.  
Feocromocitoma - Emorragia addominale - Chirurgia d'emergenza.

### Introduction

Pheochromocytoma is a rare neuroendocrine tumor, originating from chromaffin cells of the sympathetic nervous system. The classical presentation of pheochromocytoma is persistent or paroxysmal hypertension, associated with adrenergic symptoms such as sweating, palpitations, anxiety, representing less than 1% of all cases of secondary hypertension. Although many other symptoms and signs have been described to be associated with this tumour, presentation as an acute abdominal emergency is exceptional.

We present a case of abdominal hemorrhage due to a ruptured pheochromocytoma.

### Case report

A 65-year old man was admitted in the Emergency Department of our Hospital in poor general conditions and decreased level of consciousness. A history of sudden and severe left sided lumbar pain, irradiated to the omolateral flank was referred. His blood pressure was 95/50 mmHg, with a heart rate of 110 beats per minute. Red cell count was  $3 \times 10^3/100$  ml, haemoglobin concentration was 7 g/100 ml, haematocrit was 23%. Blood gas analysis indicated hypoxaemia and metabolic acidosis. Prompt volume replacement with parenteral saline solution and two packed red cell units was undertaken. Bedside ultrasonographic examination of the abdomen showed a retroperitoneal mass with solid and cystic areas and undefined margins. The mass dislocated the left kidney inferiorly and was associated with an evident perirenal hematoma and intraperitoneal free fluid collection. At urgent laparotomy one litre free intra-abdominal blood collection and a ruptured tumour, 18 cm in diameter, of the left adrenal gland were detected. The tumour adhered to the spleen. En-bloc resection of the left adrenal gland and spleen was performed. During surgery, persisting hypotension was treated with noradrenaline tartrate.

The recovery was uneventful and the patient was discharged 7 days after operation.

Histological examination showed the presence of a hemorrhagic pheochromocytoma of the left adrenal gland (Fig. 1).

Hospital "S. Paolo", Napoli  
Division of Surgery  
<sup>1</sup> Hospital "A. Fiorini", Terracina (Latina)  
Division of Surgery

© Copyright 2007, CIC Edizioni Internazionali, Roma

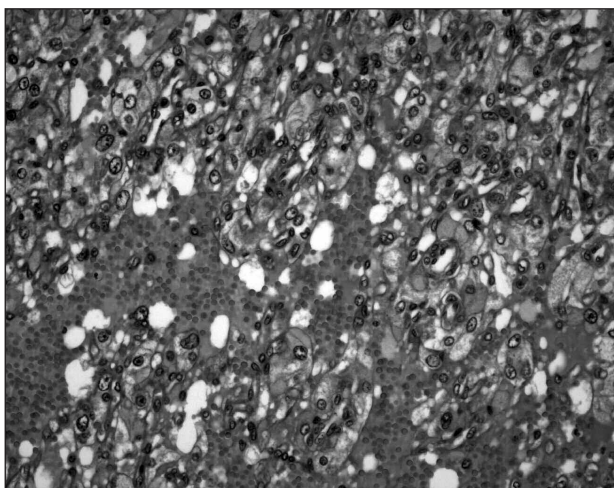


Fig. 1 - Photomicrograph showing hemorrhage in the context of pheochromocytoma (Hematoxylin and Eosin; original magnification 20x).

## Discussion

Pheochromocytoma, presenting with spontaneous tumour rupture and hemorrhage, is rare, but can be lethal because of the low index of suspicion and the dramatic clinical course. The mortality in these cases is high. Forty et al. (1) described 13 cases of death out of 22 patients with ruptured pheochromocytoma from 1944 to 1989. In a recent review of 50 cases of hemorrhagic pheochromocytoma, 17 (34%) patients died of the disease (2).

A correct diagnosis of pheochromocytoma is fundamental to reduce both mortality and morbidity. Suspicion may arise when a previous history of pheochromocytoma-related symptoms such as hypertensive attacks, headache, palpitation or hidrosis is present. Some cases of hemorrhagic pheochromocytoma were described in patients receiving anticoagulants (3-5). It is likely that stress hyperplasia of the adrenal gland, due to the pathology necessitating anticoagulant therapy, favours haemorrhagic rupture, more than the direct effect of anticoagulants (6). In the emergency set-

ting labile blood pressure, associated with intense vasoconstriction and tachycardia is the key feature (1). Tumour rupture causes severe hypertension due to release of catecholamines; subsequent hypoperfusion and necrosis of the adrenal gland causes a drop in the production of catecholamines, which leads to severe hypotension, similar to that observed after surgical removal of pheochromocytoma (7).

Hemorrhagic pheochromocytoma, presenting as an abdominal emergency is difficult to discriminate from other acute pathologies such as ruptured aortic aneurysm, mesenteric infarction, acute pancreatitis and cholecystitis. In the acute setting, plasmatic catecholamine dosage is not useful and 24-hour urine testing cannot provide results in time to be of help.

Ultrasound abdominal examination is generally unhelpful to diagnose the nature of the retroperitoneal haemorrhagic mass. On the contrary, angio-CT allows to discriminate the adrenal mass from adjacent structures and it is the gold-standard examination in order to exclude a ruptured aortic aneurysm (8,9).

Our patient presented with signs of shock, resistant to treatment with liquid and blood infusion, so that emergency surgery was necessary. Presenting shock status is strictly related to poor clinical outcome (2). Similarly, emergent surgery leads to a significant mortality rate of 44.7%. (2). Proper preoperative and intraoperative medical treatment, when feasible, can reduce both mortality and morbidity. In particular shock should be treated with catecholamine infusion, together with adequate fluid and blood replacement (10, 11).

In conclusion, spontaneous retroperitoneal hemorrhage secondary to ruptured pheochromocytoma is a rare and serious event that requires a high index of suspicion to be diagnosed promptly and treated successfully. In the frequent cases with severe shock, due to catecholamine deficiency, suspicion of ruptured pheochromocytoma may be crucial to save the patient, as catecholamine administration can resolve hypotension and guarantee an uneventful recovery.

## References

1. Forty J, Dale RF. Ruptured phaeochromocytoma: a case report. *J R Coll Surg Edinb* 1989; 34:109-10.
2. Kobayashi T, Iwai A, Takahashi R, Ide Y, Nishizawa K, Mitsumori K. Spontaneous rupture of adrenal pheochromocytoma: Review and analysis of prognostic factors. *J Surg Oncol* 2005; 90:31-5.
3. O'Connell TX, Aston SJ. Acute adrenal haemorrhage complicating anticoagulant therapy. *Surg Gynecol Obstet* 1974; 139:355-7.
4. Xarli VP, Steele AA, Davis PJ, Buescher ES, Rios CN, Garcia-Bunuel R. Adrenal hemorrhage in the adult. *Medicine* 1978; 57:211-21.
5. Ejerblad S, Hemmingsson A. Haemorrhage into a phaeochromocytoma in an anti-coagulant treated patient. *Acta Chir Scand* 1981; 147:497-500.
6. Ling D, Korobkin M, Silvermann PM, Dunnick NR. CT demonstration of bilateral adrenal hemorrhage. *Am J Radiol* 1983; 141:307-8.

*Spontaneous ruptured pheochromocytoma: a case report*

7. Van Way CW 3rd, Faraci RP, Cleveland HC, Foster JF, Scott HW Jr. Hemorrhagic necrosis of phaeochromocytoma associated with phentolamine administration. *Ann Surg* 1976;184: 26-30.
  8. Ong KL, Tan TH. Ruptured phaeochromocytoma - a rare differential diagnosis of acute abdomen. *Sing Med J* 1996; 37:113-4.
  9. Tanaka K, Noguchi S, Shuin T, et al. Spontaneous rupture of adrenal phaeochromocytoma: case report. *Urol J* 1994; 151:120-1.
  10. Suzuki K. Surgical management of pheochromocytoma. *Biomed Pharmacother* 2000;54(Suppl 1):150S-6S.
  11. Prys-Roberts C. Phaeochromocytoma-recent progress in its management. *Br J Anaesth* 2000;85:44-57.
-