

G Chir Vol. 27 - n. 3 - pp. 119-122  
Marzo 2006

How I do it

## Management of acute lower limb ischemia following percutaneous arterial closure device application: our experience

A. SIANI, A. SCHIOPPA, I. FLAISHMAN, A. ROSSI and A. ZACCARIA

**SUMMARY:** Management of acute lower limb ischemia following percutaneous arterial closure device application: our experience.

A. SIANI, A. SCHIOPPA, I. FLAISHMAN, A. ROSSI and A. ZACCARIA

**Introduction:** *The Authors reports their experience in the management of acute lower limb ischemia following percutaneous arterial closure device application.*

**Patient and methods:** *Five patients required an emergency vascular operations for acute lower limb ischemia. The symptoms onset was < 1 hour in 1 case, 4-12 hours in 2 cases and > 24-36 hours in 2 cases. A preoperative angiography was performed in all the cases. A transfemoral embolectomy was carried out. Direct suture repair were performed in three cases, vein patch angioplasty was carried out in two cases. In one case, a common femoral artery endarterectomy was performed.*

**Results:** *No post-operative mortality and limb loss occurred.*

**Conclusions:** *Acute lower limb ischemia due to closure devices required an extensive approach with reconstruction in high risk septic area. Angiography is mandatory for surgical strategies. We prefer direct suture repair and vein path angioplasty for vascular reconstruction.*

**RIASSUNTO:** *Trattamento dell'ischemia acuta degli arti inferiori secondaria all'impiego dei sistemi d'emostasi percutanea: nostra esperienza.*

A. SIANI, A. SCHIOPPA, I. FLAISHMAN, A. ROSSI, A. ZACCARIA

**Introduzione:** *Gli Autori riportano la propria esperienza nel trattamento dell'ischemia acuta degli arti inferiori secondaria all'impiego dei sistemi di emostasi percutanea.*

**Pazienti e metodi:** *Cinque pazienti sono stati sottoposti ad intervento chirurgico in urgenza per ischemia acuta. L'ischemia è comparsa meno di un'ora dalla procedura in un paziente, dopo 4-12 ore in due pazienti, oltre 24-36 ore in due pazienti. In tutti i casi sono state eseguite angiografia preoperatoria ed embolectomia femorale. In tre casi si è eseguita una sutura diretta, in due una ricostruzione con patch venoso. In un caso è stata eseguita endoarterectomia della femorale comune.*

**Risultati:** *Non si è osservata mortalità operatoria e si è ottenuto in tutti i casi il salvataggio dell'arto.*

**Conclusioni:** *Il trattamento dell'ischemia acuta da sistemi d'emostasi percutanea richiede un approccio chirurgico esteso con necessità di ricostruzione in ambiente a rischio settico. Riteniamo che l'angiografia preoperatoria sia essenziale, preferendo sempre la sutura diretta o l'impiego di patch venoso.*

**KEY WORDS:** Angioseal - Postoperative complications - Leg ischemia.  
Angioseal - Complicanze postoperatorie - Ischemia arti inferiori.

### Introduction

Iatrogenic femoral artery lesions following diagnostic or interventional angiography and coronarography procedures are becoming more frequent for the considerable increased number of the procedures performed worldwide. In fact, different reports during the last years showed an incidence of these lesions that ranged between 1 and 15% (1).

The increasing number of iatrogenic femoral artery lesions, mainly represented by hemorrhagic or thromboembolic complications, is due on the one

hand to the enormous increase of the number of the procedures, and on the other hand to the particular pathological conditions of the arterial wall (diffuse atherosclerosis) and the associated antiplatelet or anti-coagulant therapy. As a consequence, during the last years, many Authors reports an increased incidence of emergency operations on high risk patients with a huge increase of costs and hospital staying.

During the last years different types of percutaneous arterial closure devices (Angioseal, Prostar, Techstar, Vasoseal) were developed in order to reduce the incidence of these complications (2/3). At the present, the frequent employment of these arterial closure devices was followed by increased observation of complications due to the device utilization itself.

Frequently the vascular surgeon decision of how to treat these complications (ischemic, hemorrhagic or

Ospedale "S. Pietro - Fatebenefratelli", Roma  
U.O.C. Chirurgia Vascolare  
(Primario: Dr. A. Zaccaria)

© Copyright 2006, CIC Edizioni Internazionali, Roma

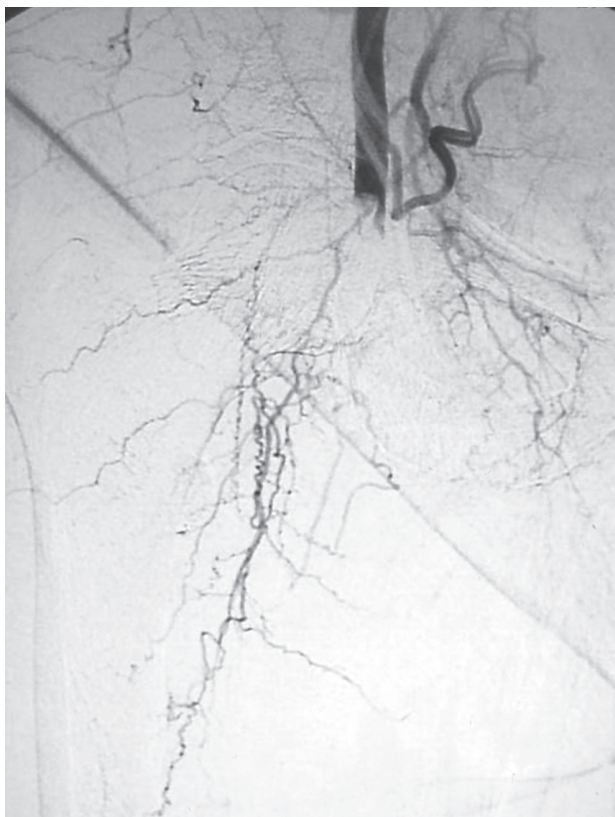


Fig. 1 - The angiography showed an occlusion of the right common femoral artery with profunda and superficial femoral arteries revascularization.

infective) is not easy because of small experience with these devices on the one hand, and the only few reports regarding the treatment of choice on the other hand.

Aim of our study was to evaluate the treatment of choice during acute lower limb ischemia following the employment of percutaneous arterial closure device and to review the literature.

## Patients and methods

Between January 2003 and May 2005, 2500 diagnostic and interventional angiographic and coronarographic procedures through a femoral artery approach were performed at our Hospital. In 270 cases (10.8%) an Angioseal percutaneous suturing devices have been used. In 180 cases (66.6%) a interventional coronary procedures were performed, while in 90 cases (33.4%) the procedure was only diagnostic.

In five cases (1.8%, 3 male and 2 female) the application of Angioseal arterial closure device was followed by the onset of an acute lower limb ischemic. In 2 cases stage II obstructive arteriopathy was present prior to the procedure. The clinical presentation was characterized in all patients by acute ischemia of the right lower limb. The time interval between the application of the arterial closure device and the symptoms onset was < 1 hour in 1 case, 4-12 hours in 2 cases and > 24-36 hours in 2 cases.

Prior to the operation, all patients underwent a diagnostic angiographic exam at the operating room through the contra-lat-

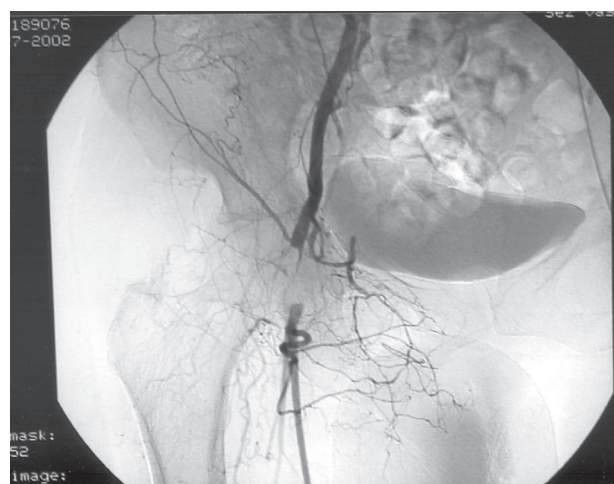

Fig. 2 - The angiography showed a complete occlusion of the right common femoral artery.

eral femoral artery. The angiography findings showed a complete occlusion on the common femoral artery in 2 cases (Figs. 1 and 2), a complete occlusion of the superficial femoral artery in 2 cases and a popliteal artery embolization in 1 case.

All the operations were carried out under local anesthesia. After the isolation of the femoral arteries we observed in 3 cases the presence of subadventitial hematoma of the superficial femoral artery at the point of the arterial closure device application. In additional 2 cases, with major interval time between the application and the clinical onset, the findings were characterized by the presence of intensive reaction of the periarterial tissues with a common femoral artery involved by a huge subadventitial hematoma. In this patient the hematoma extended for about 2 cm involving the femoral bifurcation and producing a "clepsidra" deformation of the artery.

In 3 cases in which there were no intense parietal calcifications we performed a transverse arteriotomy at the point of the closure device application. The exploration of the arterial lumen showed the presence of thrombus adherent to the device itself. After the thrombus removal, a thromboembolectomy according Fogarty of the superficial and profunda femoral arteries was carried out with the extraction of thrombotic material and the restoration of good backflow. In other 2 cases, because of the existence of intense parietal atherosclerosis and a severe arteriopathy, a longitudinal arteriotomy was carried out. In 1 patient, in addition to the thrombotic material at the site of the device application, we found a wide dissection of the posterior arterial wall due to a atherosclerosis plaque rupture. In this case we performed an endarterectomy of the common femoral artery extended to the end of the plaque and associated to the application of 6/0 Kunlin suture. The arteriotomy was sutured with autologous saphena vein (ASV) patch using a 5/0 monofilament suture. In 1 patient we observed a small flap of the posterior wall that was sutured with 6/0 Kunlin stitches. An ASV patch was applied also in this patient. In both cases a thromboembolectomy according Fogarty of the profound femoral artery was carried out previous to the arterial wall suture.

No patient required a decompression fasciotomy.

## Results

There were no case of post-operative death. Limb salvage was achieved in all cases with no need for second revascularization procedures. In 1 case a post-

operative groin hematoma, managed by conservative treatment, was present for a peri-operative minor complication rate of 20%. There were no case of major complications and no infection were observed at the side of the artery closer device application.

Follow-up was carried out for a mean period of 16 months. A color-duplex scan was performed at 1, 3, 6 and 12 months post-operatively and showed a complete patency of the artery at the arterial closure device application with no hyperplastic reaction of the arterial wall.

## **Discussion**

During the last decades a considerable increase in the number of invasive diagnostic and interventional angiographic procedures was registered in part because of their low morbidity and mortality rates and because of extended indications. In parallel, several authors reported an increased complications rate following these procedures. These complications are represented mainly by hemorrhagic disorders, pseudoaneurysms and arteriovenous fistula formation and thromboembolic events with acute lower limb ischemia. Currently, most series reports a complications rate between 1% and 15%. In the USA Wong et. al. reported the need for surgery because of complications following angiography of 75.000 operations/year (4, 5).

During the last years, the introduction of percutaneous arterial closure devices, by improving the hemostasis quality at the arterial puncture site, offered the possibility to achieve a more rapid mobilization of the patients, to reduce hospital staying costs, and the possibility to use more efficient anticoagulant therapy following these procedures.

Angioseal is actually one of the most frequently employed percutaneous arterial closure device. The device is made out of 3 parts: a flat anchor of 2x10 mm size of polylactic acid and polyglycolic acid, a collagen plug and a connection system of polyglycolic acid. The anchor is introduced to the arterial lumen through a catheter while the collagen plug is positioned on the subadventitial surface. In succession, the collagen plug is pushed against the arterial wall and permits the hemostasis.

The introduction of these hemostatic systems is actually responsible to the occurrence of new group of complications following diagnostic or interventional angiography. These complications are represented mainly by hemorrhagic, ischemic and infective events and may be due in part to the learning curve, to the poor patients selection and to the dysfunction of the device itself. The hemorrhagic complication rate reported by several Authors is actually between 2%

and 9% (6, 7) and they mainly cause the formation of pseudoaneurysms. In our series we never observed this complication; Sprouse et al. (8) reported that this kind of complication is not easy to manage. In fact, these pseudoaneurysms are generally of big dimensions, frequently with a diameter > 6 cm, with intensive peri-arterial fibrosis and a high potential of infection. According to Sprouse experience a proximal iliac artery control is often required and frequently a simple arteriography to close the arterial wall interruption is non appropriate. In most cases a more complex arterial reconstruction is necessary with increased blood lose and increased post-operative morbidity due to the cutaneous tissue damage (9).

Similar difficulties are often present when managing the ischemic complications. There are two mechanisms through which the Angioseal device can cause ischemia. The first one, which was present in 3 of our patients, is represented by thrombosis or distal embolization without arterial wall lesions. In the second one there is a thrombosis due to the anchorage of a lateral plaque (formation of a clepsydra stenosis) or a posterior plaque with occlusion or arterial wall dissection. It is of fundamental importance to make a correct differential diagnosis between these two mechanisms in order to select the appropriate surgical technique.

The management of ischemic complications without arterial wall lesions appears to be less difficult. In fact, in these instances, through a transverse arteriotomy it is possible to carry out an embolectomy according Fogarty to remove of the Angioseal anchorage system and to control the posterior arterial intimal layer. In this way, by avoiding a longitudinal arteriotomy, there is no need to apply a prosthetic or autologous material for the arterial reconstruction. Since most of the devices are applied on the superficial femoral artery, with a reduce diameter as compared to the common femoral artery, the risk of stenosis caused by a direct suture of a longitudinal arteriotomy is high. Neheler et al. (10) in their experience showed that arterial closure devices often create a potential septic habitat. Similar conditions were observed by Sprouse et al. (8) who reported cases of autologous saphenous vein patch infection treated by transobturator bypass or hip disarticulation, both procedures carried out with high mortality rates.

Therefore, it is essential to performe the transverse arteriotomy exactly above the anchorage position in order to achieve a perfect control of the posterior arterial intimal layer. In fact, these intimal lesions are always to be controlled before closing the artery and in case of lesion a Kunlin sutures can be applied. In cases with posterior intimal lesions more distal to the arteriotomy point it is possible to access them through the extension of the transverse arteriotomy.

Other prefers to approach the lesion through a primary longitudinal arteriotomy. One of the reasons is that in the point of the closure device often there is a chronic endarteritis which can cause late bleeding. The second motivation is that the posterior extension of the transverse arteriotomy may cause an arterial wall rupture because of the presence of posterior atherosclerotic plaques. In addition, because most groups do not perform an arteriography of the femoral vessels, seldom there is a need to convert a transverse arteriotomy into a longitudinal arteriotomy in the presence of severe arterial wall lesions and consequently artery reconstruction difficulties. Therefore, according to our experience and the literature review this surgical approach represents the most advantageous, rapid and less traumatic choice from the technical point of view.

About the pre-operative arteriography, although it is not performed routinely in patients with acute lower limb ischemia, we consider it very helpful by giving information regarding the physiopathological mechanism of the ischemia and helping the surgical strategies to choose. In fact, it is of fundamental importance to know if the ischemia is caused by steno-occlusion or thrombo-embolization mechanisms.

In our experience we had two cases of acute femoral artery thrombosis both in patients with atherosclerotic arteriopathy due to a parietal lesion caused by the internal anchorage system and a posterior wall plaque. In these two cases we used a longitudinal arteriotomy in order to achieve a better control of the

posterior artery wall. In one case we applied a Kunlin suture to secure the intimal flaps. In the second case we performed a common femoral artery endarterectomy because of the severe lesions of the arterial wall and in order to achieve a better control of the distal endpoint. In both cases the arterial closure was carried out with an ASV patch.

Because of the possible infective complications, often caused by meticolin-resistant *Staphylococcus aureus*, we prefer to use autologous materials even if they may cause degenerative alterations in the long term follow-up. This approach reduces the high morbidity and mortality rates associated with groin graft infections (11-13).

## Conclusion

It is our opinion that percutaneous arterial closure devices represent advantageous and reliable systems to be applied in selected patients.

The management of the complications following the use of these systems is often difficult because of the frequent presence of severe atherosclerotic lesions and the high risk of infections. In patients with acute lower limb ischemia it is mandatory to understand the etiologic mechanism by performing a pre-operative arteriography. From the technical point of view we prefer, when possible, a transverse arteriotomy and an autologous vein graft when an arterial reconstruction is needed.

## References

1. Wyman RM, Safian RD, et al. Current complications of diagnostic and therapeutic cardiac catheterization. *J Am Coll Cardiol* 1988;12:1400-1406.
2. Meyers SL, Feldman T, Desai TR, Leef J, Schwarz LB et al. Angiographic access site complications in the era of arterial closure devices. *Vasc Endovascular Surg* 2002; 36(2):137-44.
3. Carey D, Martin LR, Moore CA, Valentine MC, Nygaard TW. Complications of femoral artery closure devices. *Catheter Cardiovasc. Interv* 2002; 57(3):297-302.
4. Johnson LW, Lozner EC, Johnson S, et al. Coronary arteriography 1984-1987: a report of the registry of the Society for Cardiac Angiography and Interventions. Results and Complications. *Cathet Cardiovasc Diagn* 1989;17:5-10.
5. Wong P, Harding S, Walters D, Hull ML, Jang IK. Vascular complications after haemostatic puncture closure devices (AngioSeal) are not higher in overweight patients. *J Invasive Cardiol* 2001;13:623-5.
6. Eidt JF, Habibipour S, Saucedo JF, McKee J, Southern F, Barone GW, Talley JD et al. Surgical complications from hemostatic puncture closure devices. *Am J Surg* 1999;178:511-16.
7. Gonze MD, Sternbergh WC, Salartash K, Money SR. Complications associated with percutaneous closure devices. *Am J Surg* 1999;178:209-11.
8. Sprouse LR, Botta DM, Hamilton in. The management of peripheral vascular complications associated with use of percutaneous suture-mediated closure devices. *J Vasc Surg* 2001; 33:688-93.
9. Franco CD, Goldsmith J, Veith FJ, Calligaro KD, Gupta SK, Wengerter KR. Management of arterial injuries produced by percutaneous femoral procedures. *Surgery* 1993;113:419-25.
10. Nehler MR, Lawrence WA, Charette SD, Jones DN, Krupski WC. Iatrogenic vascular injuries from percutaneous vascular suturing devices. *J Vasc Surg* 2001; 33:943-7.
11. Skillman JJ, Ducksoo K, Baim DS. Vascular complications of percutaneous femoral cardiac interventions. *Arch Surg* 1988; 123:1207-12.
12. Calligaro KD, Veith FJ, Gupta SK, et al. A modified method for management of prosthetic graft infection involving an anastomosis to the femoral common artery. *J Vasc Surg* 1990; 11: 485-92.
13. Baste JC, Diard N, Sassoust G, Dobourguet L, Midy D. What is the best treatment for infections in femoral triangle grafts? In: Becquemin JP, Loisançe D, Watlet J, *Controversies an Update in Vascular and Cardiovascular Surg*, 8-12.