

*G Chir Vol. 27 - n. 1/2 - pp. 27-30
Gennaio-Febbraio 2006*

Traumatic avulsion of the intrapancreatic common bile duct: case report

G. D'AMATA, A. RAHILI, J. HABRE, B. KARIMDJEE, F. SANCHEZ BUENO, A. BOURGEON

SUMMARY: Traumatic avulsion of the intrapancreatic common bile duct: case report.

G. D'AMATA, A. RAHILI, J. HABRE, B. KARIMADJEE,
F. SANCHEZ BUENO, A. BOURGEON

Injuries of the extra hepatic biliary tree following blunt trauma to the abdomen are rare. We present a case of avulsion of the intrapancreatic common bile duct.

Very often the lesion is not identifiable until the signs of jaundice and biliary ascites occur. Intraoperative cholangiography is mandatory for the diagnosis, but the noninvasive magnetic resonance cholangiopancreatography could readily depict the injury of the extrahepatic bile duct preoperatively. When the diagnosis is late the corner stone of treatment is biliary diversion and definitive repair after complete resolution of sepsis with a choledochojunostomy.

RIASSUNTO: Avulsione traumatica del coledoco intrapancreatico: caso clinico.

G. D'AMATA, A. RAHILI, J. HABRE, B. KARIMADJEE,
F. SANCHEZ BUENO, A. BOURGEON

Le lesioni dell'albero biliare extraepatico per trauma addominale chiuso sono rare. Presentiamo un caso di avulsione del coledoco intrapancreatico.

Molto spesso le lesioni non è identificabile fino a quando non compaiono i segni di ittero e ascite biliare. La colangiografia intraoperatoria è fondamentale per la diagnosi, ma la meno invasiva colangiografia-RMN è efficace nell'individuare preoperatoriamente una lesione del coledoco. Quando la diagnosi è tardiva gli obiettivi del trattamento sono la diversione biliare e la riparazione definitiva con una coledocodigiunostomia dopo completa risoluzione della sepsi.

KEY WORDS: Common bile duct injury - Abdominal blunt trauma.
Lesione del coledoco - Trauma addominale chiuso.

Introduction

Extrahepatic common bile duct injury due to blunt injury is a rare entity. Avulsion of the intrapancreatic common bile duct is even less common.

A patient sustaining complete avulsion of the intrapancreatic common bile duct after a blunt abdominal trauma is described. A review of diagnostic techniques and therapeutic management is summarized.

Case report

A 24 year-old-man was admitted on March 4, 2003 after a blunt abdominal injury. His abdomen had been hit by a slab of marble of 100 kg two hours previously. Physical examination on admission showed an hemodynamically stable patient with abrasions across his upper abdomen. Abdominal tenderness was not

present. Computed tomography (CT) of his abdomen at admission revealed a little amount of free liquid in the abdominal cavity. The spleen and liver were intact.

Two days after admission, appeared an increase in amylase serum levels with a normalization after 48 hours. A follow-up CT on 10 march showed that the amount of free liquid in the peritoneal cavity was increased. Simultaneously it was noted an increase in serum bilirubin levels and the appearance of jaundice, diffuse tenderness, fever and ascites. On March 13 a MRI-cholangiography showed an area around the distal common bile duct (CBD) suspected for hemobilia or avulsion of CBD (Fig.1). A diagnostic paracentesis yielded bile-stained fluid. A follow-up CT on March 14 showed a marked amount of free liquid in peritoneal cavity and a probable disinsertion of the papilla of Vater.

Surgical exploration was performed on March 14, 10 days after admission. An explorative laparoscopy found a diffuse biliary peritonitis. The exposition and dissection of the hepatoduodenal ligament was very difficult and so a converted laparotomy was performed. The reported findings were a biliary peritonitis with contusion of hepatoduodenal ligament. Intraoperative cholangiography through the cystic duct after cholecystectomy revealed a leak at the intrapancreatic portion of the common bile duct and a leak of the proximal portion (Fig. 2). At dissection the CBD was found to be completely avulsed from its junction with the pancreas. It was visible a lateral tear at the posterior face of the proximal portion of the CBD near the origin of the left

Centro Ospedaliero Universitario di Nizza, Francia
Ospedale "L'Archet 2"
Servizio di Chirurgia Generale ed Oncologia Digestiva
(Direttore: Prof. A. Bourgeon)

© Copyright 2006, CIC Edizioni Internazionali, Roma

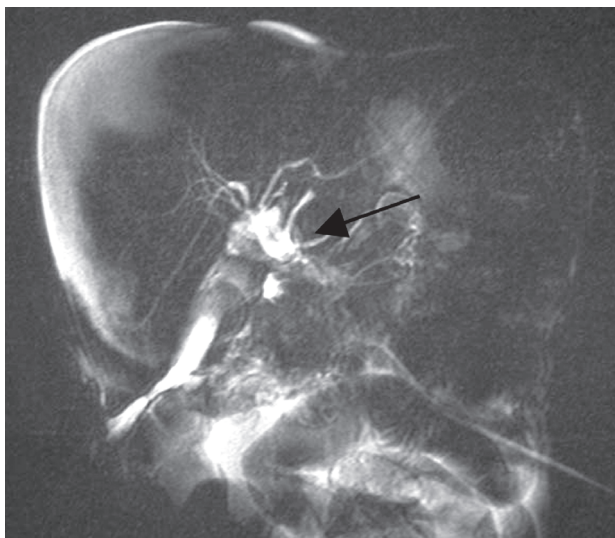


Fig. 1 - MRI cholangiography doesn't show the distal portion of the common bile duct which is folded back the duodenum and not opacified. Arrow: hepatic duct confluence.

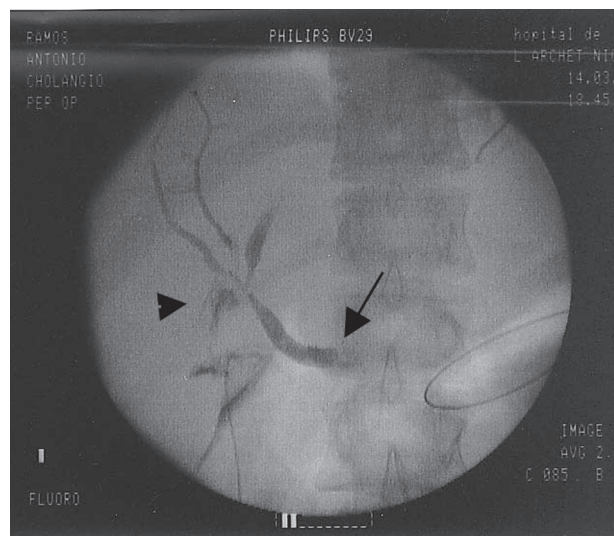


Fig. 2 - Intraoperative cholangiography showed an interruption of the common bile duct at the projection of the area of the first duodenum near the gastric tube (arrow). The leak of contrast at the hepatic duct confluence (arrowhead).

hepatic duct. Because of the biliary peritonitis and the small diameter of the duct, it was considered inadvisable to attempt anastomosis. The lesions of the bile duct were treated by a tube drainage of the common hepatic duct and a drainage of the sub-hepatic area.

On April 1, 2003 the patient was discharged with an externe biliary drainage of 1 liter by day. He returned 3 months later for a biliary reconstruction with a Roux-en-Y choledochojejunostomy. At the follow-up visit two years after the operation the patient is well.

Discussion

Injury to common bile duct is uncommon. It represents about 0,5% of all the patients undergoing laparotomy for acute trauma (1). Intrapaneatic rupture or avulsion of the common bile duct is an even less common occurrence that presents unique challenges. The exact mechanism of rupture of biliary tree is still unknown. However, injury tends to occur at three areas of relative fixation of the biliary tract (2): (a) the origin of the left hepatic duct, (b) the bifurcation of the hepatic ducts, and (c) the pancreaticoduodenal junction.

A number of mechanisms, either alone or in combination, may produce rupture of the common bile duct, which most often occurs at the junction of the common bile duct with the pancreas, but in some instances may occur at the papilla of Vater. The three most important are: compression of the ductal system against the vertebral column (3), sudden increase of intraluminal pression in the gallbladder with a short and permeable cystic duct (4), and a "shearing force" producing avulsion of the common duct where it has a fixed part at its junction with the pancreas (5). A

direct blow to the anterior abdominal wall and simultaneous costal arch compression cause the liver to be driven cephalad, while excessive traction on the common bile duct gainst a relatively fixed duodenum and pancreas would cause shearing at the point where the common bile duct enters the pancreas. Avulsion of the intrapancreatic bile duct can be rarely associated with duodenal rupture (6) or avulsion of gastroduodenal artery (7).

Most recorded cases follow a characteristic clinical pattern. The initial injury may be followed by shock of varying degrees. The period of shock and pain may last for only a few hours and is often followed by a symptom-free interval. This interval may vary from several hours to 60 days (8). Sometimes neither during explorative laparotomy the lesion can be identified if bile leakage is contained and there is no bile present at exploration (9). In our patient the lesion was not identifiable until the signs of jaundice, biliary ascites, low grade fever, bile in the urine and acholic stools occurred. Thus, in patient without associated injuries leading to an "acute abdomen", the diagnosis is often delayed and even overlooked at the time of surgery.

The "silent" nature of this injury may account for the finding of Michelassi et al. who, in their review of published reports, found that operation was delayed for more than 24 hours in 53% of patients presented with a ruptured common bile ducts (10). The difficult in making diagnosis underscores the importance of mantaining a high index of suspicion for ductal injury in blunt abdominal trauma especially when there is a notion of pancreatic head trauma.

Several authors have described diagnostic tools to shed light on this elusive lesion. When biliary injuries are suspected but there are no definite indications for laparotomy, the first diagnostic maneuver is abdominal ultrasonography or CT to document the presence of ascites or intra-abdominal fluid collections, followed by a diagnostic peritoneal tap. The presence of fluid collection in the perihepatic area, even without pneumoperitoneum, makes necessary to consider lesions of hollow viscus (duodenum, small bowel) or a biliary tract injury. HIDA (hydroxy iminodiacetic acid) scan is a noninvasive and highly sensitive test for identifying biliary leaks. However, in trauma patients the results are often inconclusive and HIDA is limited by hepatic function and the availability of nuclear imaging (11).

ERCP is useful in patients with common bile duct injury and has the additional benefit of serving as a therapeutic tool when there is no interruption or rupture of the extra hepatic bile duct (12).

In this selected group of patients, ERCP and stenting offers an attractive alternative to operative management (13, 14). Stent placement early in the course of the disease may prove more successful than attempted placement later on. Combined surgical and endoscopic treatment is possible. Early laparoscopy or laparotomy treat the abdominal peritonitis by complete abdominal toilet and the operative cholangiography make the diagnosing. Lateral extrahepatic tears in a non dilated proximal bile duct, especially the left or right hepatic duct, could be treated by endoscopic stenting because the surgical repair of this kind of lesion is difficult even with insertion of T tube with possible failure and ductal stricture (13, 14). The impossibility to obtain a cholangiography during the ERCP must sensibilize to the possibility of occlusion or avulsion of the intrapancreatic portion of the CBD that would hinder opacification and hence the assessment of proximal bile ducts (15).

The magnetic resonance cholangiography (MRCP) is not only not invasive but offers a diagnostic value approaching that of ERCP. In our case, MRCP helped us to reveal active bile extravasation and no opacification of the distal portion of the CBD. The diagnosis of avulsion could be evocated when MRI cholangiography doesn't show the distal portion of the common bile duct which is folded back the duodenum and not opacified, because MRI cholangiography is done without hyperpression. An intraoperative cholangiogram is easily obtainable through the gallbladder and presents minimal risk to the patient.

Cholangiography through the gallbladder or the cystic duct after cholecystectomy should be routinely done in case in the event of an intraoperatory suspicion of injury of biliary tree. Anatomically biliary

tract injuries can be multiples and concern the areas of relative fixation of biliary tree, as in our patient. In this situation intraoperative cholangiography, which is performed under pressure, is more able to detect multiple injuries when they are presents. A complete intraoperative cholangiography is mandatory because multiples injuries are possibles and their underestimation could be the cause of postoperative complications and the need for a reintervention with increased morbidity and mortality.

Management should be tailored to the anatomy of the injury and hemodynamic status of the patient. Feliciano (2) consider five factors affecting the choice of operative repair: the hemodynamic stability of the patient, the presence of associated injuries in the right upper quadrant, the location and extent of the injury, the small size of the ducts in patients who have sustained trauma, and the tenuous blood supply of the common bile duct. We believe that one of the more important factors is the timing of diagnosis. The immediate diagnosis makes possible an immediate repair if the patient is stable and associated lesions allow it. If the diagnosis is delayed the repair must be postponed and it's mandatory a biliary drainage.

Several options short of formal repair are possible to control the leakage of bile. Included among these are insertion of a closed drain near the ductal injury, insertion of a red rubber tube into the proximal end of a transected hepatic or common bile duct, or insertion of a T tube (2). In our case, because of the existing chemical peritonitis and the existence of multiple damage to biliary tract we decided to bring the duct out with tube drainage. Definitive repair is performed in patients whose condition is stable and the diagnosis is not delayed, with the option chosen based on the extent of the ductal injury. In cases with transection without loss of tissue treatment options include end-to-end anastomosis, choledochoduodenostomy and Roux-en-Y choledochojejunostomy. The treatment by an end-to-end anastomosis has given poor results with well over 55% of cases presenting with stricture of the duct with subsequent cholangitis and cirrhosis (16, 17). This is in part because of the ischemic damage secondary to trauma, the compromise to the axial blood supply of the bile duct which is especially precarious in the middle third of the common bile duct and after transection, and the difficulty of creating a tension-free anastomosis, even after thorough pancreatoduodenal dissection (18). We prefer and recommend Roux-en-Y duct-jejunal anastomosis because it provides the best long-term drainage, allows a tension-free anastomosis, and eliminates the risk of duodenal fistula (19). The Whipple procedure is reserved for the injury to the distal bile duct associated with a macerated, devascularized or actively bleeding pancreatoduodenal complex trauma (7).

Conclusions

Intrapancreatic avulsion of the common bile duct due to a blunt trauma is a rare lesion described only anecdotally in the literature. As for the other lesions of this type, the corner stone of treatment, when the diagnosis is delayed or the patient is unstable, is immediate biliary diversion and definitive repair after complete resolution of biliary peritonitis, pancreatitis

and sepsis. (20). The role of the magnetic resonance cholangiography in diagnosing extrahepatic bile duct injury is promising because is a non invasive technique which can succesfully delineate the biliary tree and depict an avulsion of the intrapancreatic portion of common bile duct (15). However a complete intraoperative cholangiography remains mandatory for detecting multiples injuries of the extrahepatic biliary tract in blunt abdominal trauma.

References

1. Posner MC, Moore EE. Extrahepatic biliary tract injury: operative management plan. *J Trauma* 1985; 25:833-7.
2. Feliciano DV. Biliary injuries as a result of blunt and penetrating trauma. *Surg Clin North Am* 1994;74:897-907.
3. Lee D, Zacher J, Vogel TT. Primary repair in transection of duodenum with avulsion of the common duct. *Arch Surg* 1976;111:592-3.
4. Fletcher WS. Non penetrating trauma to the gallbladder and extrahepatic bile ducts. *Surg Clin North Am* 1972;52:711-7.
5. Maier WP, Lightfoot WP, Rosemond GP. Extrahepatic biliary ductal injury in closed trauma. *Am J Surg* 1968;116:103-8.
6. Barry K, Waldron D, Horgan PG, Quill DS. Duodenal rupture with avulsion of the bile duct: an unusual injury. *Ir Med J* 1992;85:69-70.
7. Ito T, Yamamoto M, Machida H, Hashiguchi Y, Yatsuda N, Yasud M. Complete avulsion of the papilla of Vater and gastroduodenal artery due to blunt abdominal trauma: report of a case. *Surg Today* 1993;23:172-5.
8. Khodadadi J, Mihich M, Finally F, Milleritzky M. Avulsion of common bile duct after blunt abdominal injury: a review of the literature. *Injury* 1983;14:447-50.
9. Kaul S, Homnick A, Livingston D: Intrapancreatic bile duct injury: case report. *J Trauma* 2002;52:786-8.
10. Michelassi F, Ranson JH. Bile duct disruption by blunt trauma. *J Trauma* 1985; 25:454-7.
11. Gartman DM, Zeman RK, Cahow CE, Baker CC. The value of hepatobiliary scanning in complex liver trauma. *J Trauma* 1994;36:186-90.
12. Harrel D, Vitale G, Larson G. Selective role for ERCP in abdominal trauma. *Surg Endosc* 1998;12:400-4.
13. Nathan M, Gates J, Ferzoco SJ. Hepatic duct confluence injury in blunt abdominal trauma: case report and synopsis on management. *Surg Laparosc Endosc Percutan Tech* 2003;13:350-2.
14. Nuzzo G, Clemente G, Cadeddu F, Mutignani M. Complete trauma disruption of the left hepatic duct: endoscopic treatment after failure of surgical repair. *J Trauma* 2001;51:159-61.
15. Wong YC, Wang LJ, Chen RJ, Chen CJ. Magnetic resonance imaging of extrahepatic bile duct disruption. *Eur Radiol* 2002;12:2488-90.
16. Carmichael DH. Avulsion of the common bile duct by blunt trauma. *South Med J* 1980;73:166-8.
17. Chappuis JP, Cochet P, Takvorian P, Floret D. Isolated rupture of the choledochus in closed injury of the abdomen in children. *Chir Pediatr* 1987;28:325-8.
18. Terblanchen J, Allison HF, Northover JMA. An ischemic basis for biliary strictures. *Surg* 1983;94:52-7.
19. Rodriguez-Montes JA, Rojo E, Garcia-Sancho Martin L. Complication following repair of extrahepatic bile duct injuries after blunt abdominal trauma. *World J Surg* 2001;25:1313-6.
20. Soffer D, Pamoukian VN, Minski Z, Aladgem D, Kluger Y. Traumatic transection of the intrapancreatic common bile duct due to blunt injury: case report and literature review. *Injury* 1996;27:672-4.