

# Case control study to assess the possibility of decrease the risk of osteoradionecrosis in relation to the dose of radiation absorbed by the jaw

Fabrizio Carini, MD, DMD<sup>1</sup>  
 Concetta Bucalo, BDS<sup>2</sup>  
 Vito Saggese, MDS<sup>3</sup>  
 Dario Monai, MDS<sup>3</sup>  
 Gianluca Porcaro, MDS<sup>3</sup>

<sup>1</sup> Research Professor, University of Milan-Bicocca, Monza (MB), Italy;

<sup>2</sup> Postgraduate student, School of Oral Surgery, University of Milan-Bicocca, Monza (MB), Italy

<sup>3</sup> Oral Surgery specialist, School of Oral Surgery, University of Milan-Bicocca, Monza (MB), Italy

## Corresponding author:

Gianluca Porcaro  
 Oral Surgery specialist, School of Oral Surgery,  
 University of Milan-Bicocca  
 Monza (MB), Italy  
 Phone and Fax: +39 (0) 2333482  
 E-mail: porcarogianluca@libero.it

## Summary

**Aims:** the assessment of the limit dose for the organs at risk in external radiotherapy is a fundamental step to guarantee an optimal risk-benefit ratio. The aim of this study was to assess, through contouring the single dental cavities, the absorbed radiation dose on irradiated alveolar bones during the treatment of cervico-facial tumours, so as to test the correlation between the absorbed dose of radiation at alveolar level and the level of individual surgical risk for osteonecrosis. **Materials and methods:** we selected 45 out of 89 patients on the basis of different exclusion criteria. Nine of these patients showed evidence of osteoradionecrosis. The patients were treated either with 3D conformational radiation therapy (3D-CRT) or with intensity-modulated radiation therapy (IMRT), there after alveolar bones were contoured using computed axial tomography (CAT scans) carried out following oncological and dental treatment. The dose-volume histograms (DVH) were obtained on the basis of such data, which included those relating to the dental cavities in addition to those inherent to the tumours and the organs at risk. **Results:** all patients, irrespective of type of treatment, received an average of 60 to 70 grays in 30/35 sittings. The patients treated with IMRT showed higher variation in absorbed radiation dose than those treated with 3D-CRT. The alveolar encirclement allowed the assessment of the absorbed radiation dose, and consequently it also allowed to assess the individual surgical risk for osteonecrosis in patients with head and neck tumours who underwent radiography treatment.

**Conclusions:** the study of DVH allows the assessment of limit dose and the detection of the areas at greater risk for osteoradionecrosis before dental surgery.

**Key words:** osteoradionecrosis, contouring, IMRT.

## Introduction

In the treatment of head and neck cancers with radiotherapy, the proximity of the target volumes to important anatomical structures poses a problem: high radiation doses have to be aimed as near as possible towards the target tumors, so as to reach the best local-regional control, whereas at the same time toxicity has to be diminished (1). Thanks to recent innovations for the treatment of such tumors, two conformational radiotherapy techniques are used, which allow a conformation of the radiation band to the anatomy of the organs (or to a part of them) affected by cancer:

- 3D conformational radiation therapy (3D-CRT);
- Intensity-modulated radiation therapy (IMRT).

Conformational radiotherapy provides the acquisition of the 3D image through the CAT scan, which contains morphological and densitometric data concerning various tissues to define and contour the target volumes. The latter is carried out by a radiotherapist and includes GTV (gross tumor volume: tumor), CTV (clinical target volume: area at risk for dissemination) and the organs at risk (healthy organs). This allows to assess how the dose is distributed across all the irradiated tissues using a dedicated software (3D) and to conform it, thus defining dose-volume histograms (DVH). DVH graphically illustrate the radiation doses received by the various structures and represents an useful instrument to assess 3D-CRT and IMRT plans.

Both techniques have been designed to maximize the dose aimed at the target and at the same time to minimize the involvement of the surrounding structures.

A difference between 3D-CRT and IMRT is in the treatment planning. The former allows a "direct planning", a process by which the operator can modify continuously the set-up of the plan searching for the dose distribution pattern that better conforms to the type of anatomical relationship between target volume and organs at risk. Conversely, IMRT relies on an "inverse planning" computer program in order to optimize the treatment plan the operator. This method lets a choice of the parameters of treatment (choice of fields, orientation of fascicles, flow profiles) taking into account the dosimetric and volumetric constraints of the organs at risk and starting from doses distribution considered to be optimal and clinically effective (2-4).

The organs at risk, or critical structures, are healthy tissues whose radio-sensitivity can significantly influence the structure of a radiation treatment and therefore the prescription of the total dosage. In the work of Emami (5) the tolerance dosage is defined as the gray dosage beyond which a specific and serious complication can occur. Moreover, the maximum and the minimum tolerance doses are defined as the dosages (in Grays) that after five years from radiation produce specific toxicity in no more than 50%, and in no more than 5% of the irradiated patients respectively (Tab. 1).

Chiasm	D1% ≤ 55 Gy
Optic nerves	D1% ≤ 55 Gy
Brainstem	D1% ≤ 55 Gy
Eyeball	Md ≤ 35 Gy
Crystalline	D1 ≤ 6 Gy
Temporal lobe	D1% ≤ 60 Gy
Cochlea	Md ≤ 45 Gy
Spinal cord	D1% ≤ 45 Gy
Parotid	Md ≤ 26 Gy o V30Gy≤50%
Masseter muscle	Md ≤ 50 Gy
External mucous membranes	Md ≤ 35-40 Gy
Mandible	D1% ≤ 70 Gy; Md ≤ 60-65 Gy
Larynx	V 60 Gy < 50%
Pharyngeal constrictor muscle	D1% ≤ 70 Gy; Md ≤ 60-65 Gy
Temporomandibular joints	D1% ≤ 70 Gy; Md ≤ 60-65 Gy
Thyroid	V 30 Gy < 50%
Brachial plexus	D1% ≤ 60-63 Gy

Table 1. D1%: maximum dose which includes a percentage of volume equal to or less than 1%; Md: mean dose.

The lower jaw is in general a radio-resistant structure but the radio therapy involves the risk of developing a particular complication called the osteoradionecrosis (ORN) (Fig. 1).

ORN (6-8) represents a damage emerging at a later stage, characterized by both bone exposure and low probability of spontaneous recovery. In a Mark's Work (7), about the physiopathology of the ORN, he defined this complication as an area greater than 1 cm of exposed bone, present in an irradiated field, which has not showed recovery for at least 6 months. As a consequence, phenomena of cellulitis and suppuration, fetid smell, cutaneous fistula, pulsating pain, exposition and/or bone sequestration, haemorrhaging, pathological fractures, difficulty in mastication, swallowing, phonation and trismus can occur.

In a recent study was observed that most spontaneous presentations of ORN occurred between 6 months and 2 years after RT, whereas the risk of developing trauma induced ORN lasts indefinitely. This observation explains the occurrence of ORN even 10 years after RT (9).

One review cited that incidence increased from 0.4% to 56% than in the past. However, more recent studies have reported incidences of 10% or less with the advent of conformal techniques, as showed in the Ben-David et al. and the Studer et al. (10,11).

According to some studies ORN is improbable when the absorbed radiation dose is lower than 70 Grays with standard division, whereas other studies report an in-

creased incidence of ORN in patients who have received doses greater than 65-70 Grays (12). Finally, in the study by Goldwasser et al. (13) patients who received a dosage of 66 Grays showed a 11 times greater risk of developing ORN. Therefore, as some patients with ORN have received doses lower than 66 Grays, while patients who did not show signs of ORN have undergone doses of 66 Grays, or greater, it is clear that the risk for ORN cannot be predicted on the basis of radiation dosage only.

For this reason all the previously mentioned variables associated with this complication have to be taken into account, including the type of response of the patients themselves and thereby the individual surgical risk.

Some studies have assessed the maximum dosage that a lower jaw can receive. However, these data have not been quantified for the alveolar bone, as this implies a detailed study of the plan of the patient.

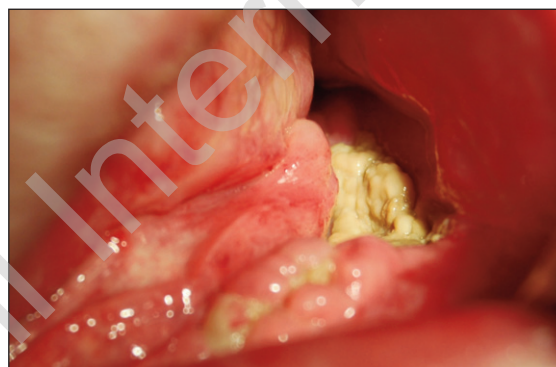

Figure 1. A case of mandibular osteonecrosis.

## Materials and methods

From February 2010 to September 2010, 89 patients were selected at the Oral Oncological Centre of the University of Milan Bicocca. They presented oral and oropharyngeal: cancer in different areas and had undergone radiotherapy and successive dental treatment. Of these, 45 patients were included in the study. Exclusion criteria were: dental treatment was not surgical, oncological complications of the patient that did not allow the follow up, and radiotherapy treatment carried out in other hospitals. Indeed, the discharge letters and the patients' DVH were supplied by the Radiotherapy Department of the San Gerardo Hospital where the study was carried out. All the patients' letters of discharge were examined reporting some data as gender and age (between 38 and 82) of patients, type of tumor (Fig. 2), type of radiotherapy treatment, maximum and minimum scores of radiation dose and irradiated area.

Of the total cross-section, 9 patients showed evidence of ORN, while the remaining 36 were included in a control group. Of these, 6 patients were treated for oropharyngeal tumours.

Alveolar bones were contoured using computed axial tomography (CAT scans), carried out following oncological and dental treatment of patients. In particular, we contoured: teeth sockets in the presence of dental elements,

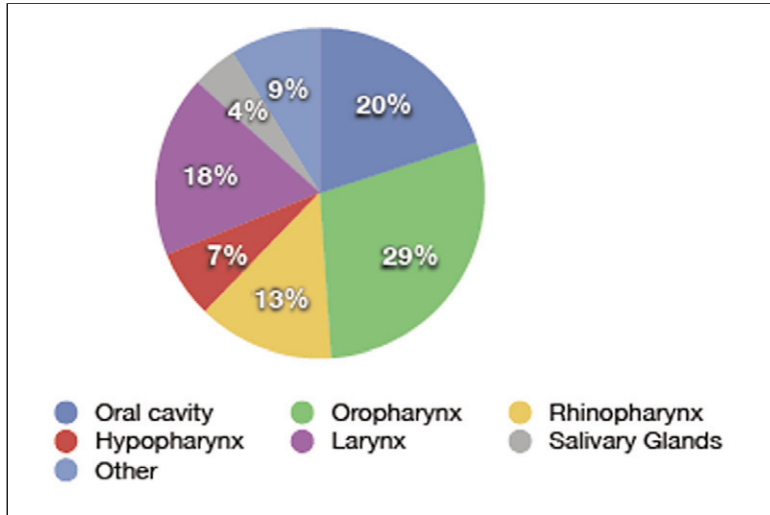


Figure 2. Incidence of cancer by site in the sample.

post-extractive teeth sockets or, in case of edentulous, the whole bone base. We assessed both the maxilla and the mandible because both structures were affected by ORN. Then, we obtained DVH, which, apart from showing data concerning both the tumors and the organs at risk, included those related to the dental alveoli (Fig. 3).

From the study of DVH we obtained:

- average: average dose received by the volume considered
- minimum
- maximum
- D 95%: dose received by the 95% of the volume
- D 90%: dose received by the 90% of the volume
- V 100%: percentage of the volume that receives the prescribed dose
- V95%: percentage of the volume that receives 95% of the prescribed dose.

Finally, the software developed 3D representations of the structures (Fig.4).

This study allowed to assess the amount of radiation

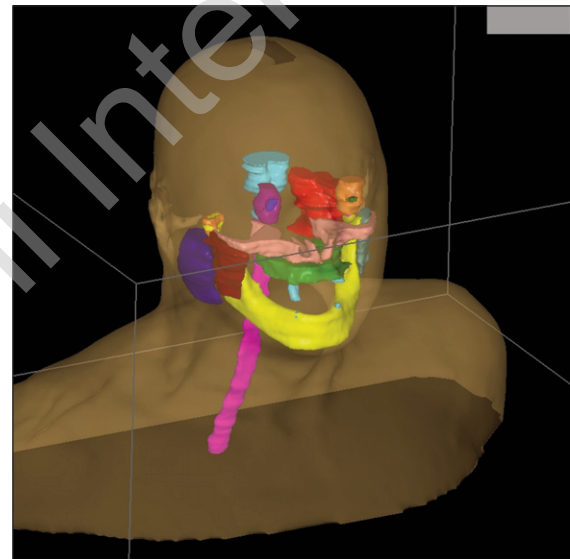


Figure 4. 3D representation.

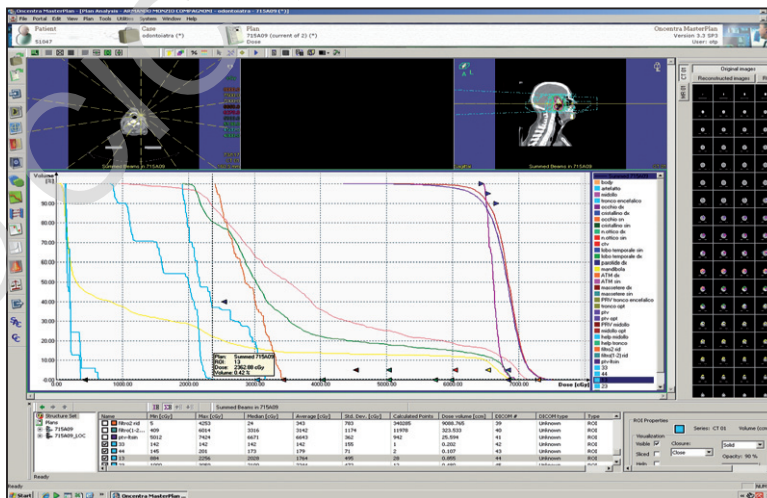


Figure 3. DVH.

absorbed by dental alveoli: doses varied depending on the type of treatment carried out. Indeed, in the case of 3D-CRT the amount of radiation absorbed by the whole bone base varied little irrespective of lesion areas, whereas in patients treated with IMRT it was possible to assess the dosage absorbed by each single dental sockets.

## Results

Irrespective of type of treatment all patients received an average of 60 to 70 grays in 30/35 sittings. In the case of IMRT some areas received the total dosage, while others received

minor doses or were completely excluded from radiation.

Due to the considerable amount of data, the values concerning the patients with ORN were considered with particular attention with respect to the controls (Tabs. 2 and 3).

Among the patients with ORN, 8 were treated with 3D-CRT and only one with IMRT. The latter (patient n. 6) underwent extraction where he had received the largest radiation dosage, 6955 grays, whereas he had received 2544 grays in the less affected areas.

Only one patient showed a spontaneous ORN, whereas in all other patients ORN appeared after dental extraction.

Tab 2. Extracted teeth and necrosis areas.

	Extracted teeth	Necrosis area
1	37	palate (spontaneous necrosis)
2	21-22-25-11-12-16-34-35-38	38
3	11-12-14-15-16-17-21-22-25-26-31-32-33-34-35-36-41-42-43-45	35
4	11-16-17-18-22-35-36-37-44-48	34
5 (IMRT)	11-17-18-19-20-21-22-23-24-25-26-27-28-3-32-33-34-41-42-43-44-45	mandible (from 36 to 42)
6	11-12-13-14-15-16-21-22-23-24-33-34-35-36-37-43-47	45-35
7	31-32-33-45-46	38-31-41
8	11-12-13-14-15-21-22-25-26-27-34-35-36-37-38	34-35
9	36-37-38 3	7-38

Tab 3. Absorbed doses.

Average total absorbed dose (cGray)	Absorbed dose in the necrosis area (cGray)	maximum dose (cGray)
6932	6927	6969
6845	7153	7319
5432	6608	7140
2987	5056	6202
6692	7024	7169
5506	6955	7506
3909	5541	5981
4709	5377	5393
1097	5988	5988

Table 3 shows that in patients with osteonecrosis the average total absorbed dosage was not always particularly high at the level of the contoured alveolar bones, at the level of the contoured alveolar bones. the average total absorbed dosage was not always particularly high. This held true also for the 36 patients of the control group. DVH was variable mainly in the case of treatment plans with IMRT. As previously mentioned, when 3D-CRT was used the whole bone base received similar radiation doses in the various areas, whereas with IMRT some areas received different doses of radiation depending on their proximity to the tumor and on other variables related to radiotherapy treatment.

ORN always developed in those areas, which had received a high radiation dose: in some cases the intervention was carried out in areas that had absorbed the highest dose, especially when the 3D-CRT technique was used.

### Discussion

Radiotherapy, on its own, does not allow to predict the absolute risk for osteonecrosis but it is simply one of the fac-

tors predisposing patients to develop such lesions, together with proximity of tumor to the bone, type of irradiated bone, presence of local traumas etc.

The factors that contribute to increase such probability are:

- tabagism;
- alcohol abuse;
- scant oral hygiene;
- compromised nutritional state;
- time elapsed between radiotherapy and surgical procedure;
- different fractionation (hypo division increases the risk for ORN);
- receipt of the total radiation dose. Accelerated fractionation with dose reduction is associated with a reduced risk, whereas hyperfractionation shows elevated risk of developing osteoradionecrosis (9).

Moreover, the risk for osteonecrosis increases when both radiation dose and the extent of the radiation field increase. With respect to the latter variable, the development of conformational radiotherapy has allowed to



glimpse the possibility of increasing local-regional tumor control without causing parallel toxicity as well as to overcome some limitations linked to the bi-dimensional planning of treatment.

In a recent study showed that the rate of ORN after IMRT for head-and-neck cancer, although very low (1%), did occur at our institution in patients receiving a significant dose to the mandible in oral cavity tumors, in contrast to previously published studies that reported no incidences of this toxicity with inverse planning. In addition, they have provided further evidence that the mechanisms for radiation induced dental caries and dental extractions differ, with the incidence of dental caries being more related to the dose to the salivary glands, and dental extractions being a consequence of radiation directly to the mandible (14).

Both contouring of the mandible and the tri-dimensional planning of treatment allow to assess the radiation dose for the whole bone base. Moreover, contouring of the single dental sockets allows the assessment of the individual surgical risk of patients. This makes the operator able to carry out a preventive protocol and to study those areas in which the surgical intervention must be excluded.

Various studies have already found a significant association between ORN and amount of radiation absorbed. These studies suggest that a radiation dosage higher than 50 grays would increase the risk of developing the complication. More recent studies demonstrated that such a threshold is about 66 grays (1).

The study of DVH allows the assessment of such doses, as well as to detect the main areas at risk before carrying out the dental surgical treatment as a prevention of ORN. This can be important both from a deontological and medical-legal point of view, because it can provide useful data for the choice of the most correct professional conduct.

Anyway, in order to prevent ORN it is always appropriate to eliminate all possible sources of dental infection before initiating the radiation therapy. Furthermore, it is always a good rule to postpone dental extractions for at least 12 months after the end of the radiation therapy.

Holistic management in the context of a core multidisciplinary team is essential in optimizing outcomes. Effective communication between healthcare professionals in the care and extended teams and with the patient is essential (15).

#### Patient consent

The authors declare that the informed consent was obtained from all participants before their enrollment in the study.

#### Ethics

The authors declare that the presented study was carried out in accordance with the ethical standards established in the declaration of Helsinki.

The authors state that they do not have any conflict of interest. All authors declare that they do not have any actual or potential conflict of interest including any financial, personal or other relationships with people or organiza-

tions that could inappropriately influence (bias) their work. The authors state that they have not received institutional funds for this study.

The authors declare that the informed consent was obtained from all participants before their enrollment in the study.

#### Acknowledgements

We thank all the contributors who made possible the execution of this clinical case.

#### Bibliography

1. Maingon P, Truc G, Peignaux K, Crèhange G, Lagneau F. Radiothérapie par modulation d'intensité. *Oncologie* 2007; 9:417-421.
2. Jones B, Aird E, Colyer H, Dobbs J, Harris R, Hoskin P, McKenzie A, West C. United Kingdom Radiation Oncology 1 Conference (UKRO 1): accuracy and uncertainty in radiotherapy. *Br J Radiol* 2002; 75(892):297-306.
3. Stermick Es, Carol MP, Grant W. Intensity Modulated Radiotherapy. *Treatment Planning in Radiation Oncology*, cap 9; Meriland 1998.
4. Bortiflled TR. Optimised planning using physical objective and constraints. *Semin Radiat Oncol* 1999; 9:20-34.
5. Emami B, Lyman J, Brown A et al. Tolerance of normal tissue of therapeutic irradiation. *Int J Radiat Oncol Biol Phys* 2003; 56:384-390.
6. Ramos Cracanovic B, Peter Reher, Andrade Sousa A, Malcolm Harris. ORN of the jaws - a current overview - part 1. *Physiopathology and risk and predisposing factors. Oral Maxillofac Surg* 2010; 14:3-16.
7. O'Dell K, Sinha U. Osteoradionecrosis. *Oral Maxillofac Surg Clin North Am.* 2011 Aug;23(3):455-648.
8. Scully C, Kumor N, Dias PD. Hot topics in special care dentistry - 10 Osteoradio necrosis/radio therapy. *Dent Update.* 2010 Mar; 37(2):127.
9. Nabil S, Nabil S. Risk factors for osteoradionecrosis after head and neck radiation: a systematic review. *Oral Surg Oral Med Oral Pathol Oral Radiol* 2012;113:54-69.
10. Ben-David MA, Diamante M, Radawski JD et al. Lack of osteoradionecrosis of the mandible after intensity-modulated radiotherapy for head and neck cancer: Likely contributions of both dental care and improved dose distributions. *Int J Radiat Oncol Biol Phys* 2007;68:396-402.
11. Studer G, Graetz KW, Glanzmann C. In response to Dr. Merav A. Ben-David et al. ("Lack of osteoradionecrosis of the mandible after IMRT,") *Int J Radiat Oncol Biol Phys* 2007;68:1583-1584.
12. Morrish RB Jr, Chan E, Silverman S Jr, Meyer J, Fu KK, Greenspan D, 1981. Osteonecrosis in patients irradiated for head and neck cancer.
13. Goldwaser BR, Chuang SK; Kaban LB; August M, 2007. Risk factor assessment for the development of ORN. *J Oral Maxillofac Surg* 65:2311-2316.
14. Gomez DR, Estilo CL, Wolden SL, Zelefsky MJ, Kraus DH, Wong RJ, Shaha AR, Shah JP, Mechalakos JG, Lee NY. Correlation of osteoradionecrosis and dental events with dosimetric parameters in intensity-modulated radiation therapy for head-and-neck cancer. *Int J Radiat Oncol Biol Phys.* 2011 Nov 15; 81(4):e207-213.
15. McCaul LK. Oral and dental management for head and neck cancer patients treated by chemotherapy and radiotherapy. *Dent Update.* 2012 Mar; 39(2):135-8,140.