

# Iniencephaly with mediastinal bronchogenic cyst: A case report

Yeşim Akdemir<sup>1</sup>  
Habibe Ayvaci<sup>1</sup>  
Oya Demirci<sup>1</sup>  
Davut Sahin<sup>2</sup>  
Ersan Demirağ<sup>1</sup>  
Hamdullah Sözen<sup>1</sup>  
Mehmet Uludoğan<sup>1</sup>

<sup>1</sup> Zeynep Kamil Gynecologic and Pediatric Training and Research Hospital, Department of Obstetrics and Gynecology, Istanbul, Turkey, 34668

<sup>2</sup> Zeynep Kamil Gynecologic and Pediatric Training and Research Hospital, Department of Pathology, Istanbul, Turkey, 34668

## Corresponding author:

Corresponding Author: Oya Demirci  
E-Mail: demircioya@gmail.com  
Phone: 00905058241417

## Summary

**Objective.** Iniencephaly is a rare neural tube defect with consisting of a defect in the occipital bone, spina bifida of many vertebrae, and retroflexion of the head on the spine. In majority of cases it is a lethal condition.

**Methods.** We present the first case of iniencephaly with large bronchogenic cyst diagnosed prenatally.

**Results.** At 19 week's gestation showed that fetal cardiac activity was present with normal placenta and amniotic fluid, fetus had occipital bone defect, anencephaly, retroflexion of the head, abnormally short cervicothoracic spine and posterior mediastinal unilocular anechoic cyst. Therapeutic abortion was induced.

**Conclusion.** Iniencephaly is a rare condition during prenatal life. When diagnosed early in pregnancy a multidisciplinary approach is firmly suggested.

**Key Words:** bronchogenic cyst, iniencephaly, prenatal ultrasound.

## Introduction

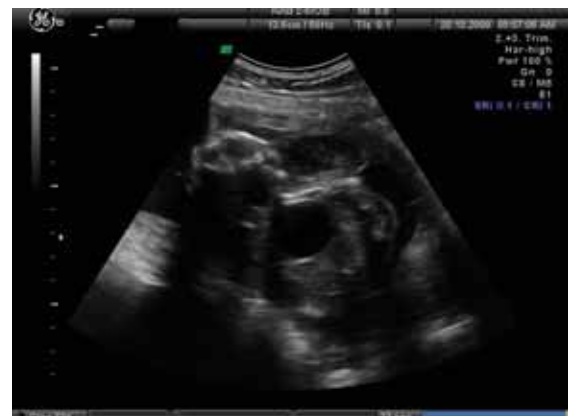Iniencephaly is an uncommon malformation consisting of defect in the occipital bone involving the foramen magnum, spina bifida of many vertebrae, and retroflexion of the head on the spine (1). The first description of iniencephaly is attributed to Saint-Hilare in 1836 (2) In-

iencephaly is a quite rare developmental anomaly, its incidence varies from 1 in 1000 to less than 1 in 100 000 deliveries (3). Although females are more affected than males, its etiology is still unclear, and no single causative agent has been defined. Most cases of iniencephaly are sporadic and are probably secondary to multifactorial inheritance (4). Chromosomal abnormalities is rarely reported with iniencephaly. We present a case of iniencephaly with mediastinal bronchogenic cyst diagnosed prenatally by ultrasound in the second trimester.

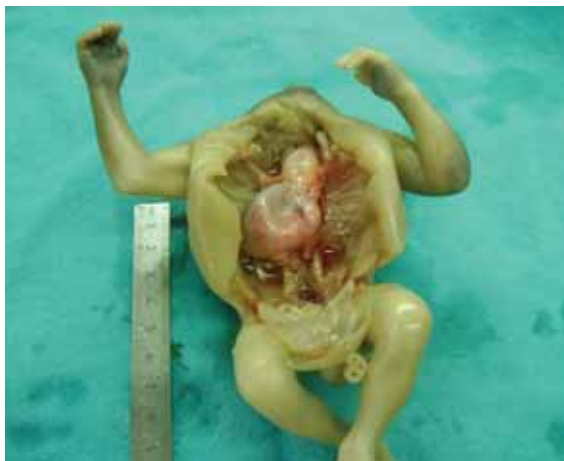## Case report

A 19 week-old male fetus was the second sibling of non-consanguineous parents aged 23 (mother) and 27 (father) years. The first child was a 2-year-old female. Prenatal and perinatal history was unremarkable. The perinatal laboratory tests revealed that the maternal serum alpha-fetoprotein level was elevated at 1042 IU/mL (31,72 MoM) and serum folic acid level was 3.31 ng/mL evaluated as normal (normal range 3-17 ng/mL). Sonography performed at 19 week's gestation showed that fetal cardiac activity was present with normal placenta and amniotic fluid, fetus had occipital bone defect, anencephaly, retroflexion of the head, abnormally short cervicothoracic spine and posterior mediastinal unilocular anechoic cyst (Fig. 1). After extensive counselling the patient opted for termination of pregnancy, pregnancy was terminated by labor induction.

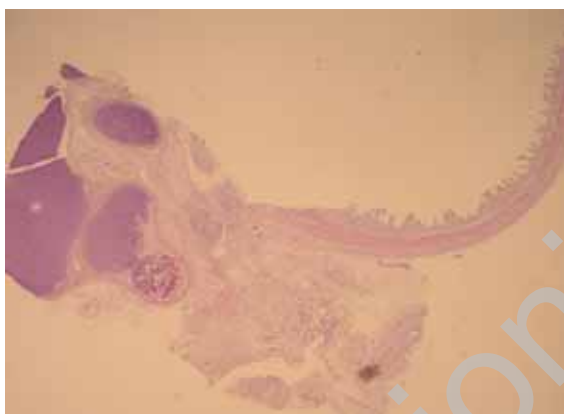
Necropsy revealed a 180 g, 18-week-old male fetus, the crown-heel length was 21 cm. The head was retroflexed with cervical vertebrae agenesis, anencephaly with iniencephaly, the cranial skin was continuous with lumbar skin and spina bifida extending from cervical to lumbar region



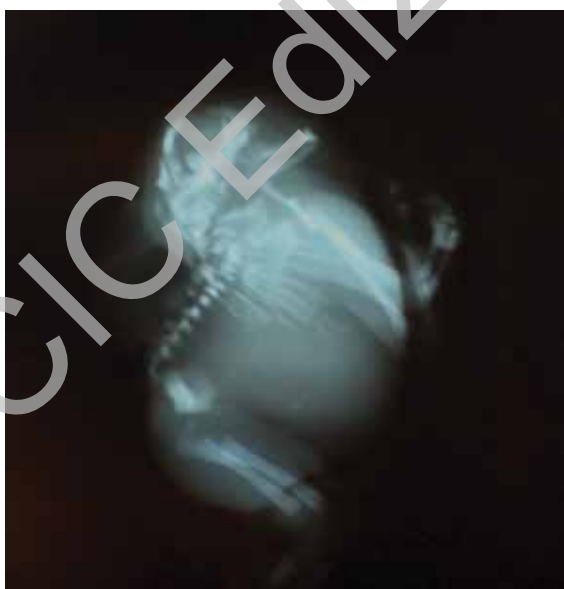**Figure 1** Ultrasonographic image of the fetus with posterior mediastinal unilocular anechoic cyst.



**Figure 2** Posterior mediastinal cyst between diaphragm and lingua.



**Figure 3** The cyst wall composed ciliated columnar lining epithelium, smooth muscle and fragments of cartilage (H.E x 20).



**Figure 4** Post-abortion X-ray of fetus showed severely deformed spinal vertebrae and costae, absence of cervical vertebrae and fusion of occipital bone and back.

was observed. One millimeter interventricular septal defect was present and he had an interesting bronchogenic cyst (4x1 cm) extending from diaphragm to lingua in the posterior mediastinum (Fig. 2). Bronchogenic cyst had ciliated columnar epithelial lining and wall composed of smooth muscle and fragments of cartilage (Fig. 3).

There was no mass effect in the mediastinum. The right lung had three lobes and left lung had two lobes. The kidneys were normal. The adrenal gland and urinary bladder were normal. Postmortem X-ray film examination showed severely deformed thoracic vertebrae and costae, absence of cervical vertebrae and fusion of occipital bone and back (Fig. 4).

### Discussion

Iniencephaly is a rare congenital malformation resulting from a defective neurodevelopmental process occurring in early pregnancy. The developmental pathogenesis is not known. It has been suggested that iniencephaly is probably an extreme form of Klippel-Feil syndrome (5) or may belong to a spectrum of central nervous system (CNS) anomalies that includes anencephaly and spina bifida. The recurrence risk is less than 1% and this rate may be higher in families with a history of neural tube defects (4). In Turkey the incidence of neural tube defect was found to be 3 in 10 000 (6).

In etiology, congenital syphilis and maternal use of teratogenic chemicals (streptogramin, triparanol and vincoblastine), and antibiotics (sulfonamide, tetracyclin), antihistamines, cigarette smoking, alcohol use, and substance abuse were reported (7-9). In our case there had been no risk factors.

Sonography can provide an early diagnosis of iniencephaly based on characteristic features of marked lordosis in the region of the cervicothoracic vertebrae, deformed and usually shortened trunk, closing disorders of vertebral arches, abnormal fusion and splitting of the cervical and thoracic vertebrae, partial/complete absence of the occipital squama in association with occipital encephalocele and head in a severe dorsiflexion position (10). Although there have been cases of iniencephaly reported as an isolated anomaly, it is very rarely occurs alone. Associated malformations involving CNS include anencephaly, encephalocele, microcephaly, hydrocephaly, holoprosencephaly, posterior fossa defects and spinal defects (7,11,12). The associated non-CNS anomalies proved to be frequent: diaphragmatic hernia, omphalocele, thoracic cage deformities, genitourinary malformations, cyclopia, cleft lip and palate, clubfoot, congenital heart diseases, imperforated anus and single umbilical artery (11,12).

In our case we observed anencephaly, spina bifida, interventricular septal defect and interestingly a bronchogenic cyst extending from diaphragm to lingua in posterior mediastinum. To our knowledge bronchogenic cyst has not been reported in iniencephaly cases in the literature previously.

Bronchogenic cysts are congenital lesions thought to result from abnormal budding of the ventral foregut. When abnormal budding occurs early in bronchial development, the cysts occur in the mediastinum (30%); if they occur later the cysts are pulmonary (70%) (13). Bronchogenic cysts have ciliated columnar epithelial lining

and wall composed of smooth muscle and fragments of cartilage (1). Antenatal sonographic diagnosis of a bronchogenic cyst is made by identifying an anechoic or hypoechoic well-defined unilocular and rounded mass. The differential diagnosis of bronchogenic cyst by prenatal sonographic examination are enteric cysts, cystic hygromas, cystic adenomatoid malformations and congenital diaphragmatic hernias (14,15).

We could not make a definitive diagnosis of the bronchogenic cyst and interventricular septal defect based on the antenatal sonographic findings because of the severely deformed thorax. Although it has been shown that diaphragmatic herniation found to be the most frequently associated non-CNS anomaly by several authors (12,16), bronchogenic cyst must be considered when antenatal sonography revealed an anechoic unilocular rounded mass.

Iniencephaly is usually fatal but rare cases with long term survival have been reported (17). Whether or not iniencephaly is compatible with life seems to depend on the severity of associated anomalies and the degree of retroflexion.

Although, it has been shown that the 677CT mutation on the methylenetetrahydrofolate reductase gene is not implicated in the etiology of neural tube defects in Turkey, we studied the genotypes of the parents (18,19). The mother was found to have a 677CT genotype, heterozygous for this mutation. She was recommended folic acid supplementation for future pregnancies.

## References

1. Gilbert-Barnes E. *Potter's Pathology of the Fetus, Infant and Child* 2nd ed. Mosby-Elsevier, 2007.
2. Stark AM. A report of two cases of iniencephaly. *J Obstet Gynaecol British Emp* 1951; 58: 462-464.
3. Lewis HF. Iniencephalus. *Am J Obstet Gynecol* 1987; 35:11.
4. Casbay L, Szabo I, Papp C, Toth-Pal E, Papp Z. Central nervous system anomalies. *Ann N Y Acad Sci* 1998; 847: 21-45.
5. Gilmour JR. The essential identity of the Klippel-Feil syndrome and iniencephaly. *J Pathol Bacteriol* 1941; 53: 117-31.
6. Tuncbilek E, Boduroglu K, Alikasifoglu M. Neural tube defects in Turkey: prevalence, distribution and risk factors. *Turk J Pediatr* 1999; 41: 299-305.
7. Aleksic S, Budzilovich G, Greco MA, Feigin I, Epstein F, Pearson J. Iniencephaly: a neuropathologic study *Clin Neuropathol* 1983; 2: 55-61.
8. Bowden RA, Stephens TD, Lemire RJ. The association of spinal retroflexion with limb anomalies *Teratology* 1980; 21: 53.
9. Myriantopulos NC, Melnick M. Studies in neural tube defects: epidemiologic and etiologic agents *Am J Med Genet* 1987; 18: 404-405.
10. Joo JG, Beke A, Papp C, Szigeti Z, Csaba A, Papp Z. Major Diagnostic and Pathological Features of Iniencephaly Based on Twenty-Four Cases *Fetal Diagn Ther* 2008; 24:1-6.
11. Morocz I, Szeifert GT, Molnar P, Toth Z, Csecsei K, Papp Z. Prenatal diagnosis and pathoanatomy of iniencephaly *Clin Genet* 1986; 30: 81-86.
12. Dogan MM, Ekici E, Yapar EG, Soysal ME, Soysal SK, Gokmen O. Iniencephaly: a sonographic pathologic correlation of 19 cases. *J Perinat Med* 1996; 24: 501-511.
13. Rogers LF, Osmer JC. Bronchogenic cysts. A review of 46 cases *AJR* 1964; 91: 273-283
14. Newman JP, Crues JV, Vinstein AL, Medearis AL. Sonographic diagnosis of thoracic gastroenteric cyst in utero *Prenat Diagn* 1984; 4:467.
15. Graham D, Winn K, Dex W, Sanders RC. Prenatal diagnosis of cystic adenomatoid malformations of the lung *J Ultrasound Med* 1982; 1:9-12.
16. Chaurasia BD, Wagh KV, Goyal J. Spinal retroflexion in craniorachischisis: its classification and limitation *Acta Anat* 1976; 94: 626-632.
17. Gartman JJ, Melin TE, Lawrence WT, Powers SK. Deformity correction and long-term survival in an infant with iniencephaly. *Case Report J Neurosurg* 1991; 75: 126-30.
18. Boduroglu K, Alikasifoglu M, Anar B, Tuncbilek E. Association of the 677CT mutation on the methylenetetrahydrofolate reductase gene in Turkish patients with neural tube defects *J Child Neurol* 1999; 14: 159-161.
19. Tugrul S, Uludogan M, Pekin O, Uslu H, Celik C, Ersan F. Iniencephaly: Prenatal diagnosis with post-mortem findings *J Obstet Gynaecol Res* 2007; 33:566-569.