

SURGICAL TREATMENT OF SEVERE ATROPHIC MAXILLA BY MEANS OF MULTIPLE EXTRAORAL HARVESTING

M. CLEMENTINI¹, R. BONIELLO², G. GASPARINI², A. MORO², S. PELO²

University of Rome, Tor Vergata, Rome, Italy

¹Department of Dentistry,

²O.U. Maxillo-Facial Surgery, Complesso Integrato Columbus, Catholic University Sacred Heart, Rome, Italy

SUMMARY

Surgical treatment of severe atrophic maxilla by means of multiple extraoral harvesting.

Aim. The aim of the present clinical study is to evaluate the efficacy of autologous bone multiple harvesting in the surgery of the severe atrophic maxilla, in term of quantity and quality of the grafts for the following implant-supported prosthesis treatment.

Material and Method. For 5 patients a combined onlay bone grafting and bilateral sinus lift elevation procedure was performed under general anesthesia. Harvesting site was anterior iliac crest and calvaria. Clinical and radiographic (Rx-OPT and CT Dentascan) examinations were performed to evaluate the bone defects and to programme surgical treatment and during the follow up.

Results. Postoperative complications' evaluation showed no significative problems. Radiographic controls at 4 months showed a minimum or no resorption of calvaria harvesting.

Conclusion. In the reconstruction of the severe atrophies of the alveolar edentulous crests, a multiple extraoral harvesting seems to improve quality and quantity of bone graft, so that the following implant-supported prosthesis treatment is facilitated.

Key words: autologous bone, extraoral multiple harvesting, atrophic maxilla.

RIASSUNTO

Trattamento chirurgico del mascellare superiore severamente atrofico mediante prelievo multiplo extraorale.

Obiettivi. Scopo del presente lavoro è valutare l'efficacia del prelievo multiplo di osso autologo nelle ricostruzioni dei mascellari severamente atrofici, con la finalità di avere a disposizione sia la maggiore quantità che la migliore qualità di osso, per una sicura predicibilità del risultato implanto-protetico.

Metodi. Cinque pazienti sono stati sottoposti, in anestesia generale, ad intervento chirurgico che prevedeva grande rialzo di seno mascellare bilaterale ed innesti di tipo "onlay", per aumentare la dimensione verticale e orizzontale del mascellare superiore atrofico. Il prelievo di osso autologo è stato effettuato da sedi multiple (cresta iliaca anteriore e teca cranica). I risultati clinici e radiologici sono stati valutati nel tempo.

Risultati. Ai controlli clinici post-operatori non si è evidenziata nessuna grande complicanza post-operatoria. I controlli radiografici effettuati a 4 mesi hanno evidenziato un minimo o nessun riassorbimento per gli innesti di tipo "onlay", che erano stati prelevati dalla teca cranica.

Conclusioni. Nelle ricostruzioni delle creste alveolari edentule severamente atrofiche, l'esecuzione di un prelievo multiplo extraorale migliora la qualità del tessuto osseo innestato; in ragione della diminuita percentuale di riassorbimento degli innesti di tipo "onlay" e la maggiore quantità dei "chips" ossei, la ricostruzione ottenuta per soddisfare il progetto implanto-protetico viene mantenuta stabile nel tempo.

Parole chiave: osso autologo, prelievo multiplo extraorale, atrofia mascellare.

Introduction

Ridge resorption secondary to tooth loss sometimes make an prosthodontically driven implant position impossible. An adequate volume and a good quality of the bone represent necessary conditions for a long-term predicibility of an implant-supported prosthesis. Autologous bone is the only material with the principal characteristic for bone regeneration, as osteogenicity, osteoinduction and osteoconduction, so it represents the gold standard in the repair of alveolar atrophy and bone defects. In the last years, many surgical techniques have been adopted to improve the volume of alveolar atrophic crest: block bone graft, sinus or nasal lift elevation, guided bone regeneration or interpositional bone graft and osteotomy. In the literature different autologous bone donor site are described: iliac crest, fibula, calvaria, mandibular ramus and chin. Because of this big number of harvesting sites, it was noticed how different can be the quantity and the quality of bone, and the post-operative morbidity in relationship to the quantity of bone harvested (Table 1).

The aim of the present clinical study is to evaluate the efficacy of autologous bone extraoral multiple harvesting in the surgery of the severe atrophic maxilla, so that a good quality and quantity of bone graft is available for the success of the implant-supported prosthesis procedure.

Material and methods

This retrospective study reviewed 5 patients - 2 male and 3 female, mean age 57 years; range 48-65 years - subjected to surgical treatment for the resolution of severe atrophic maxilla in a period between January 2005 and January 2006 at the Operative Division of Oral and Maxillo-Facial Surgery of the "Università Cattolica Sacro Cuore" in Rome.

All five subjects were affected of severe atrophic maxilla - Cawood & Howell's class V, with a inadequate crest in width and length - and exhibited no systematic contraindications for the osseointegrated-implant treatment.

Clinical and radiographic (Rx-OPT and CT Dentascan) examinations were performed to evaluate the bone defects and to programme surgical treatment (40-41). For the resolution of the atrophic maxilla all patients needed the same quantity of autologous bone. Under general anesthesia a combined onlay bone grafting and bilateral sinus lift elevation procedure was performed and extraoral multiple harvesting (anterior iliac crest and calvaria) was conducted. The same maxillofacial surgeon performed all harvestings and graftings using the same operational protocol. At least 1h prior the surgery, piperacillin + tazobactam 2,250 mg. and desossimetason 4 mg intravenous was administered to the patients. Antibiotic coverage was continued post-operatively with piperacillin + tazobactam 5 mg/die for 10 days, matched with desossimetason 4-mg/die for 2

Table 1 - Autologous bone's donor sites.

| | Iliac crest | Calvaria | Chin | Ramus/Angle mandible |
|--------------------------|---|------------------|---|----------------------|
| Embriological origin | endochondral | membranous | membranous | membranous |
| Structure | Cortical/trabecolar | cortical | Cortical/Trabecolar | cortical |
| Quantity harvesting | 70 mL | 50 mL | 5-10 mL | 5-10 mL |
| Resorption | Moderate | Minimum | Minimum | Minimum |
| Surgical acces | good | good | good | Fair to good |
| Utility | "onlay", "inlay", bilateral sinus lifting | "onlay", "inlay" | "onlay","inlay", unilateral sinus lifting | "onlay", "inlay" |
| Anesthesia | General | General | Local | Local |
| Patient's worry | moderate | high | high | low |
| Post-operative morbidity | moderate | low | moderate | low |

days and 1.5. mg/die for 1 day and ketorolac when needed. At the dismissal, oral hygiene instructions (meticulous brushing with handbrush and rinses with clorexidine 0,2%) and soft diet for 15 days were recommended to the patients. In all subjects deambulation with an orthopaedic auxilium for 10 days were recommended. All patients were recalled 1 week, 2 weeks, 1 month, 3 months and 4 months after the surgery for a clinical and anamnestic evaluation of the donor site in order to explore the presence of post-operative complications and to value oral hygiene and eventually dehiscences.

In order to quantify an eventual resorption of “onlay” graft, a radiographical evaluation was made after 4 months. The quantity of the resorption was analysed by using Rx-OPT and CT-Dentascan developed with a radiological technique standardized for each patient: Width (w: distance in mm. between vestibular and palatal cortical) and height (h: distance between alveolar crest and sinus floor) of remaining alveolar bone was estimated at T0 . Bone graft thickness was measured during the surgery (T1) with a millimetric calibre, and on CT-Dentascan (T1) as the distance between the cortical portion of the graft and cortical portion of atrophic bone on a perpendicular axis on the coronal and axial cuts. For the comparison on Rx-OPT it was considered as a reference the screws set for primary stabilization of the grafts. On post-operative Rx-OPT and CT-Dentascan (T2) a morphometric comparison with the radiographs done before the surgery (T0) and measurement of bone block (T1) was done.

At 4 months titanium plates and screws were removed and a prosthodontically-driven implant placement was conducted. After 4 months prosthodontic phase started. One of study group's patient is presented in Figure 1-11.

Results

At baseline patients presented poor maxillary bone volume: horizontally a range of 3 mm-4,2 mm (mean: 3,5 mm) were available and vertically, for the presence of the sinus, a range of 2 mm-3 mm (mean: 2,3 mm) were available. At 4 months, we observed radiologically a good bony consolidation and a mi-

nimum or no resorption.

Comparison of the bone thickness between T0 and T2 (4 months after the surgery) showed a mean gain of 2.9 mm-3.7 mm (mean: 3,28 mm) and a resorption of 0.3 mm- 1.4 mm (mean: 0,72 mm).

In both patients' groups, mean gain in height was of 10.5 mm (range 9.5-12 mm).

Postoperative complications' evaluation showed no significative problems except for the presence of claudicatio during the first week post-operative. From a clinical point of view all the bony grafts showed a good stability (Table 2).

Discussions

The use of grafts for the atrophic alveolar crests rehabilitation is broadly well-known and reported in literature. Many biomaterials are described: autologous bone, homologous bone, heterologous bone, alloplastic materials and growth factors.

The autologous bone still represents the gold standard in the repair of the atrophic crests of the maxilla, because of its peculiarities: the medullary component, with osteogenetic ability linked to its capability in transporting osteoblast; the cortical component, with osteoconductive characteristics, due to its matrix role for the birth of new plotted bone and, finally, the osteoinductive peculiarity, due to its release of growth factors as the BMPs, the PDGF, the TGF and the IGF. Moreover, it does not introduce any antigenicity form, and the inexpensiveness and the retrieval facility makes this biomaterial the first choice in the reconstructive surgery.

In the past the embryological classification gave the chance to hypothesize influences in the graft behaviour . Although the mechanism of bone resorption is not yet clear, experimental studies on animals showed that intramembranous bone type was better than endochondral bone type in order of histology and graft volume In the past the embryological classification gave the chance to hypothesize influences in the graft behaviour. Although the mechanism of bone resorption is not yet clear, experimental studies on animals showed that intramembranous bone type was better than endochondral bone type in order of histology and graft volume.

Table 2 - Study group: descriptive analysis.

| patient | gender | age | T0 (mm) | T1 (mm) | T2 (mm) | Relative gain (mm) | Resorption (%) |
|---------|--------|------|--------------------|------------|--------------------|-----------------------|-------------------|
| 1 | M | 54 | h=2 w=4,2 | w=8,2 | h=12 w=7.1 | w=2,9 | 17,5% |
| 2 | F | 62 | h=3 w=3 | w=7 | h=14 w= 6,7 | w=3,7 | 7,5% |
| 3 | M | 48 | h=2,5 w=3,8 | w=7,8 | h=12 w=6,8 | w=3,0 | 25% |
| 4 | F | 65 | h=2 w=3,5 | w=7,5 | h=14 w= 7,1 | w=3,6 | 10% |
| 5 | F | 56 | h=2 w=3 | w=7 | h=12 w= 6,5 | w=3,5 | 12,5% |
| media | - | 57aa | h=2,3mm w=3,5mm | w=7,5mm | h=10,5mm w=6,84 | w=3,28mm | 14,5% |

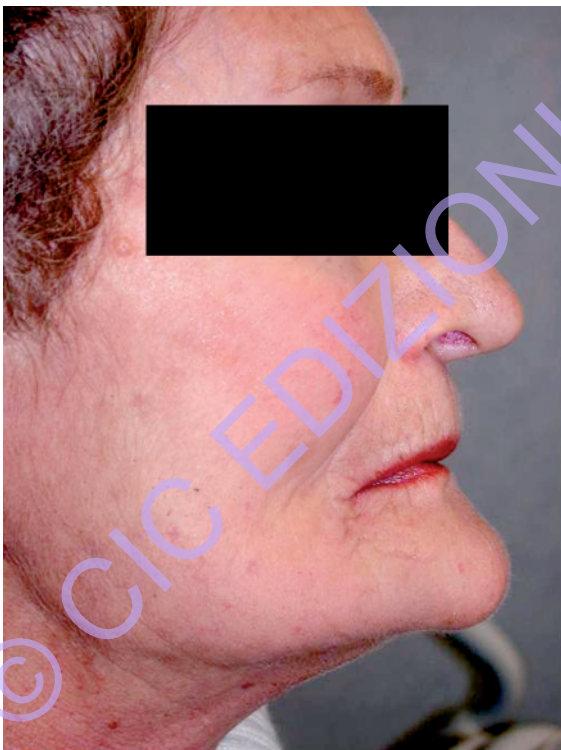

Figure 1
Patient's profile. Pre-operative.

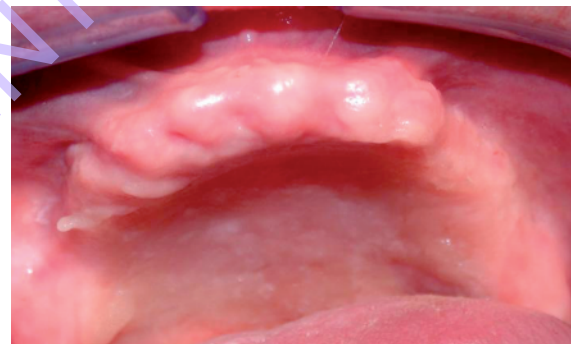


Figure 2
Maxilla edentulous ridge. Pre-operative.

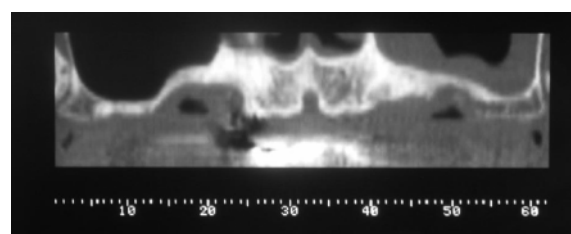


Figure 3
CT dentaScan. Coronal view. Pre-operative.

Jhoannson et al. 19 showed after six months a reduction in volume of iliac harvested bone equal to 47% in case of inlay grafts and 49.5% in case of on-

lay grafts. On the other hand, Smolka et al. 20 underlined a low percentage of resorption of calvaria bone (19.2% after 1 year) after reconstruction of bony defects of maxilla or mandible. The early revasco-

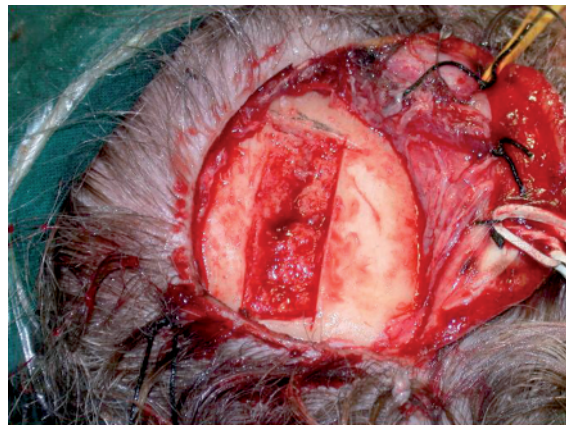


Figure 4
Calvaria harvesting. Intra-operative.

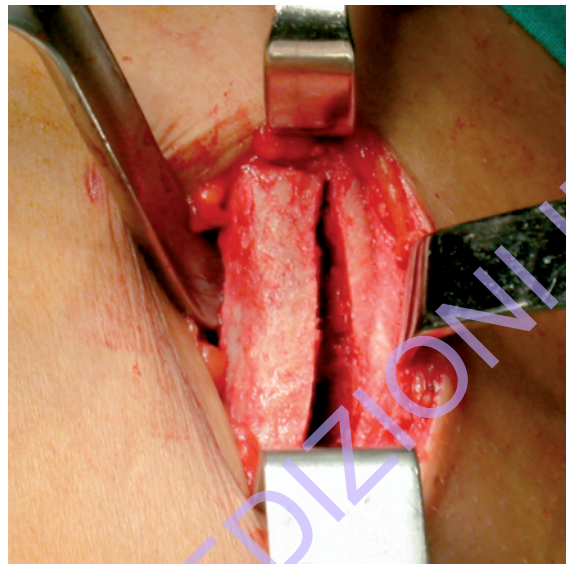


Figure 5
Iliac crest harvesting. Intra-operative.

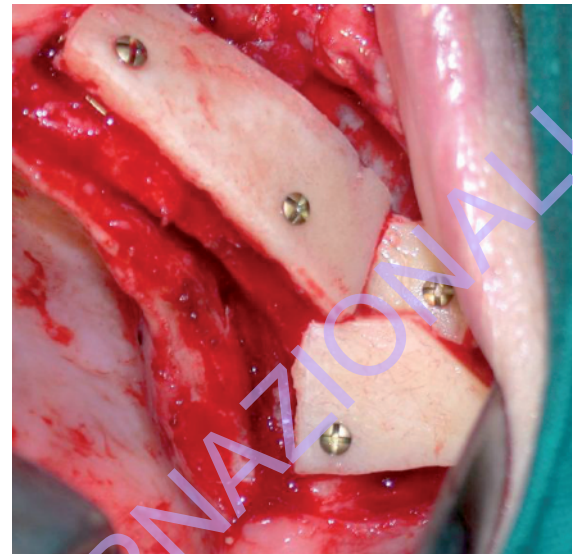


Figure 6
Onlay autologous bone graft. Intra-operative.

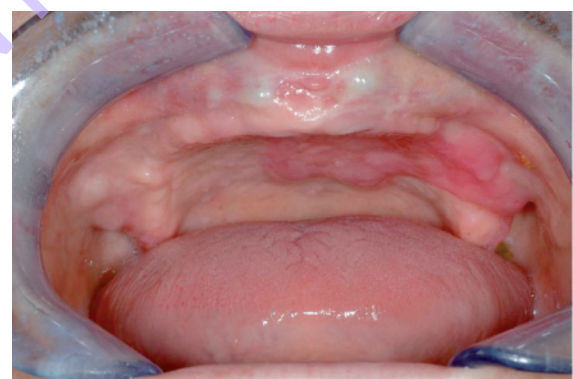

Figure 7
Maxilla edentulus ridge. Post-operative.

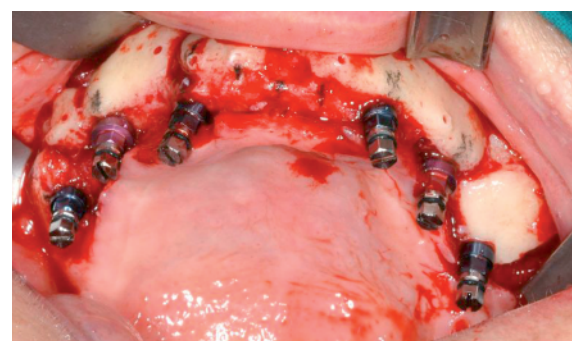


Figure 8
Implant placement at 4 months. Intra-operative

larization or the biochemical characteristics of membranous bone graft could explain volume maintenance during the follow up.

The harvesting sites that has been studied were the iliac crest (endochondral origin) and the calvaria (intramembranous origin). According to biological characteristics we choose intramembranous bone to perform “onlay” grafts type, while endochondral bone (iliac crest, especially in the medullary component or spongiosa) was used to perform “inlay” grafts type and bilateral sinus floor lifting.

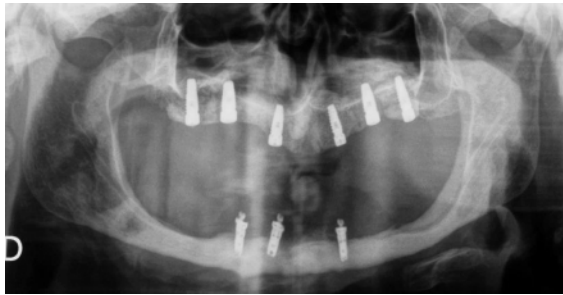


Figure 9
OPT. Post-operative.

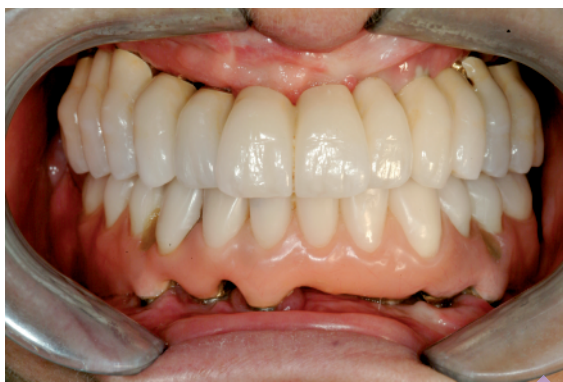

Figure 10
Final implant supported prosthesis.

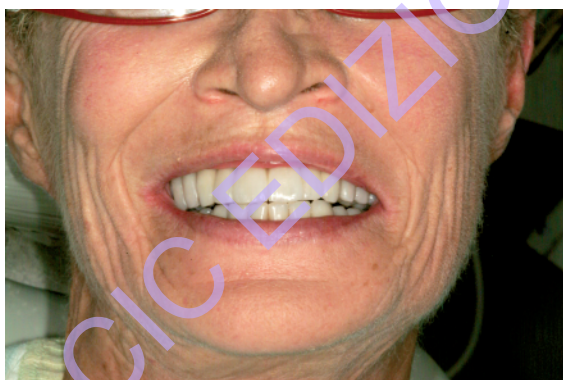

Figure 11
Patient's smile.

Conclusions

In the reconstruction of the severe atrophies of the alveolar edentulous crests, a multiple harvesting se-

ems to improve the quality of bone graft. Minor resorption of onlay bone grafts and a good quantity of particulate bone graft for sinus elevation the three-dimensional reconstruction of the maxilla is guaranteed for a prosthetic driven implant placement.

References

1. Cawood JI, Howell RA. A classification of the edentulous jaws. *Int J Oral Maxillofac Surg.* 1988 Aug; 17(4):232-6.
2. Albrektsson T. A multicenter report on osseointegrated oral implants. *J Prosthet Dent* 1988;59:287-296.
3. Burchardt H. Biology of bone transplantation. *Orthop Clin North Am.* 1987Apr;18(2):187-96.
4. Marx RE. Biology of bone grafts. In: Kelly JPW (ed). *OMS Knowledge Update. Vol 1.* Rosemont, IL: American Association of Oral and Maxillofacial Surgeons, 1994;1:RCN3-17.
5. Tolman DE. Reconstructive procedures with endosseous implants in grafted bone: a review of the literature. *Int J Oral Maxillofac Implants* 1995;10:275-294.
6. Schwartz-Arad D, Levin L. Intraoral autogenous block onlay bone grafting for extensive reconstruction of atrophic maxillary alveolar ridges. *J Periodontol.* 2005 Apr;76(4):636-41.
7. Geurs NC, Wang IC, Shulman LB, Jeffcoat MK. Retrospective radiographic analysis of sinus graft and implant placement procedures from the Academy of Osseointegration Consensus Conference on Sinus Grafts. *Int J Periodontics Restorative Dent.* 2001 Oct;21(5):517-23.
8. Buser D, Bragger U, Lang NP, Nymann S. Regeneration and enlargement of jaw bone using guided tissue regeneration. *Clin Oral Implant Res* 1990;1:22-32.
9. Chiapasco M., Brusati R., Ronchi P. Le Fort I osteotomy with interpositional bone grafts and delayed dental implants for rehabilitation of extremely atrophied maxilla: a 1 to 10 years clinical follow up study on humans. *Clin Oral Implant Res* 2007 18(1): 74-85
10. Verhoeven, J.W., Cune, M.S., Terlou, M., Zoon, M.A. & de Putter, C. The combined use of endosteal implants and iliac crest onlay grafts in the severely atrophic mandible: a longitudinal study. *International Journal of Oral and Maxillofacial Surgery* 26: 351-357 1997
11. Frodel JL, Quatela VC, Weinstein GS: Calvarial bone graft harvesting techniques, considerations and morbidity. *Otolaryngol Head Neck Surg* 1993;119:17.
12. Mish CM. Ridge augmentation using mandibular ramus bone grafts for the placement of dental implants: Presentation of a technique. *Pract Periodontics aesthet Dent* 1996; 8:127-135.
13. Hunt DR, Jovanovic SA. Autogenous bone harvesting: a chin graft technique for particulate and monocortical bone blocks. *Int J Periodontics Restorative Dent.* 1999 Apr;19(2):165-73.
14. Becker W, Becker BE, Caffese R. A comparison of de-

- mineralised freeze-dried bone and autologous bone to induce bone formation in human extraction sockets. *J Periodont Rest Dent* 1994;14:167-180.
15. Simion M, Fontana F, Rasperini G, Maiorana C. Vertical ridge augmentation by expanded-polytetrafluoroethylene membrane and a combination of intraoral autogenous bone graft and deproteinized anorganic bovinebone (Bio Oss). *Clin Oral Implants Res.* 2007 Oct;18(5):620-9.
 16. Schopper C, Moser D, Sabbas A, Lagogiannis G, Spassova E, König F, Donath K, Ewers R. The fluorohydroxyapatite (FHA) FRIOS Algipore is a suitable biomaterial for the reconstruction of severely atrophic human maxillae. *Clin Oral Implants Res.* 2003 Dec; 14(6):743-9.
 17. Boyne PJ. Application of bone morphogenetic proteins in the treatment of clinical oral and maxillofacial osseous defects. *J Bone Joint Surg Am.* 2001;83-A Suppl 1(Pt 2):S146-50.
 18. Rabie ABM, Dan Z, Samman N. Ultrastructural identification of cells involved in the healing of intramembranous and endochondral bones. *Int J Oral Maxillofac Surg* 1996;25:383-388.
 19. Johansson, B., Grepe, A., Wabffors, K. & Hirsch, J.M A clinical study of changes in the volume of bone grafts in the atrophic maxilla. *Dentomaxillofac Rad* 2001; 30: 157-161.
 20. Smolka W, Eggenperger N, Carollo V, Ozdoba C and Iizuka T: Changes in the volume and density of calvarial split bone grafts after alveolar ridge augmentation *Clin Oral Impl Res* 2006;17:149
 21. Kusiak JF, Zins JE, Whitacker LA. The early revascularization of membranous bone. *Plast Reconstruct Surg* 1985;76:510.
 22. Koole R, Bosker H, Noorman van der Dussen F. Secondary autogenous bone grafting in cleft patients comparing mandibular (ectomesenchymal) and iliac crest (mesenchymal) grafts. *J Craniomaxillofac Surg* 1989; 17:28-30.
 23. Keller EE, van Roekel NB, Desjardinis RP, Tolman DE. Prosthetic-surgical reconstruction of the severely resorbed maxilla with iliac bone grafting and tissue-integrated prostheses. *Int J Oral Maxillofac Implants* 1987;2:155-165.
 24. Al-Sebaei MO, Papageorge MB, Woo T. Technique for in-office cranial bone harvesting. *J Oral Maxillofac Surg.* 2004 Sep;62(9 Suppl 2):120-2.

Correspondence to:

Dott. Marco Clementini
Department of Dentistry
University Tor Vergata
Viale Oxford 188 - 00133 Roma
E-mail: mclementini@hotmail.com