

AUTOLOGUS PARIETAL GRAFTS IN PREPROSTHETHIC SURGERY

E.F. GHERLONE, R. VINCI, L. D'AVERSA*

Vita Salute University, San Raffaele Hospital, Milan
Department of Dentistry - Director: Prof E.F. Gherlone

* Campus Biomedico University, Roma

SUMMARY

Autologus parietal grafts in preprosthetic surgery
Edentulous patients usually request implant supported/ fixed rehabilitation. Ridge resorption after teeth loss usually affect three-dimensional implant position. Vertical and/or horizontal bone augmentation procedures are often the only choice the clinician has to deliver prosthetic guided restoration. Gold standard for augmentation procedures such as sinus lift, onlay or inlay grafts, is still autologous bone. The patient in this report underwent a pre-prosthetic reconstruction of the jaws with parietal bone, followed by fixtures insertion and fixed prosthetic rehabilitation. This clinical report aims to underline the importance of multidisciplinary treatment to optimize the results of the rehabilitation.

Key words: maxillary atrophy, calvarial grafts, oral rehabilitation.

RIASSUNTO

L'impiego della teca cranica a scopo implantoprotetico

L'imporsi dell'implantologia osteointegrata come soluzione di prima scelta nel trattamento degli edentulismi comporta spesso il suo utilizzo in situazioni anatomico-cliniche di volumetria ossea insufficiente per il posizionamento corretto degli impianti. In ottemperanza ai concetti d'implantologia protesicamente guidata, si rendono spesso necessarie tecniche di incremento trasversale e verticale. Alcune di queste tecniche (*sinus lifting*, innesti *onlay-inlay*) richiedono la disponibilità di un quantitativo più o meno abbondante di osso autologo, che rappresenta il *gold standard* di riferimento per queste tecniche. Il caso che viene presentato è stato trattato mediante ricostruzione delle sedi atrofiche con innesto di teca parietale cui è seguita riabilitazione impianto-protesica di entrambi i mascellari. La finalità di quanto presentato è sottolineare l'importanza del trattamento multidisciplinare, unica e vera garanzia per l'ottimizzazione dei risultati.

Parole chiave: atrofie mascellari, innesto di teca cranica, riabilitazione impianto-protesica.



Introduction

Bone quality and quantity is a mandatory condition to obtain fixture primary stability and to consent biomechanical remodeling following occlusal loading.

Modern implantology understresses the importance to use residual bone volume as well as prosthodontic guided fixture insertion. The aim is to obtain a successful fixture position to reach function, aesthetic and long lasting rehabilitation (1).

Short implants represent a predictable procedure in atrophic mandible; otherwise, this doesn't guarantee the same results in posterior atrophic maxilla, where the poor bone quality (Bränemark class D3/D4) suggests to have a wider contact surface, by wide implants. Edentulism can hesitate in different type of bone resorption:

- **horizontal discrepancy** with crestal wideness reduction; in upper maxilla, together with centripetal atrophy, leads to insertion of angulated implants. Prosthodontically, this reduces the chance to get a correct emergency profile (1, 2);

– **vertical atrophy:** height of crestal bone left and intermaxillary discrepancy impairs fixtures insertion to avoid prosthetic manufacture with unfavorable crown/fixture ratio with aesthetic defect and difficult daily maintenance.

Many preprothetic reconstruction techniques to increase bone volume have been developed: horizontal, vertical or a combination of both (1).

If fixed implant restoration is requested in patients with severe maxillary atrophy, our School chooses calvarial autologous graft as preferred treatment choice.

Patients and methods

Different complications and unpredictable results are main problems in bone reconstructions (3). Cawood and Howell class V and VI defects need autologous bone grafts, site donor being intraoral, if the quantity of bone is reasonable small, or extra-oral, in the other cases.

Usually, iliac crest graft is the most common, nevertheless different grade of early grafts resorption are described as well as donor site problems (pain, function impairment) (5).

Alternatively, Paul Tessier first described the calvarial grafts, with two different techniques, bicortical (*splitting on table calvarial graft*), monocortical (*splitting in situ calvarial graft*). Last one to be preferred in order to reduce intraoperative or postoperative complications. Monocortical calvarial grafts represent a predictable and easy technique due to intrinsic bone property (8).

Donor site is limited anteriorly to the coronoid suture, 2 cm from the medial line to avoid sagittal sinus, laterally to temporalis fascia; theoretically no limit is described posteriorly, usually lambda suture is the border (9).

Osteotomy lines can be made by a rotating bur or by a piezoelectric terminal tool reducing dura mater lesion (10). The size of the grafts depends on the extension of the atrophic area to regenerate.

A drainage can be placed if a large amount of calvarial graft is requested and a compressive dressing is placed afterwards, for a couple of days. A wide range antibiotic therapy can be prescribed; prophylactic dexamethasone is administered prior to surgery to reduce postoperative edema (9).

Case report

A well being 50 yrs no smoking woman, presented with diffuse chronic parodontitis and partial edentulism (Figs. 1 a, b, c; 2 a, b, c).

A wax up model was taken and the final program consisted in preservation of natural teeth from 13 to 23; all remaining elements, included 47, were dismissed two months before the bony reconstruction, to consent entire soft tissue to recovery; contextually a temporary reinforced metallic prosthesis was placed.

The surgical regenerative procedures expected in:

- bilateral sinus lifts;
- correction of vertical discrepancy by alveoplasty procedure and occlusal onlay, in the left maxilla;
- left mandibular onlay graft by tunnel technique (to correct a Cawood Class IV atrophy, not susceptible of horizontal expansion).

Bilateral sinus lift with lateral approach was performed as originally described by Boyne. The bony window was reflected in the sinus and raised superiorly together with Schneider membrane (Figs. 3 a, b). After measuring height and depth of sinus cavity, adequate quantity of calvarial grafts sticks and bone chips were obtained (Figs. 4 a, b; 5 a, b, c, d; 6 a).

Two slots were performed in the nasal and zygomatic pillars by maxillary vestibular wall to support and stabilize the new sinus floor (Fig. 6 b). By piezoelectric tool a small osteotomy on the side nasal wall was performed to give further stability to Schneider membrane. The graft itself, positioned with the upper cortical surface, gives an adequate support to the membrane (11). The

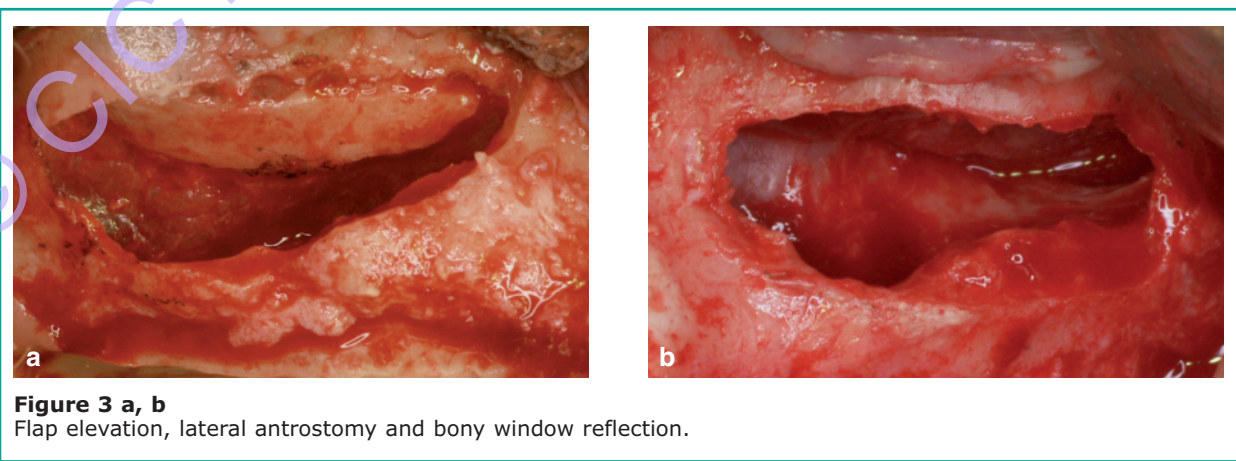
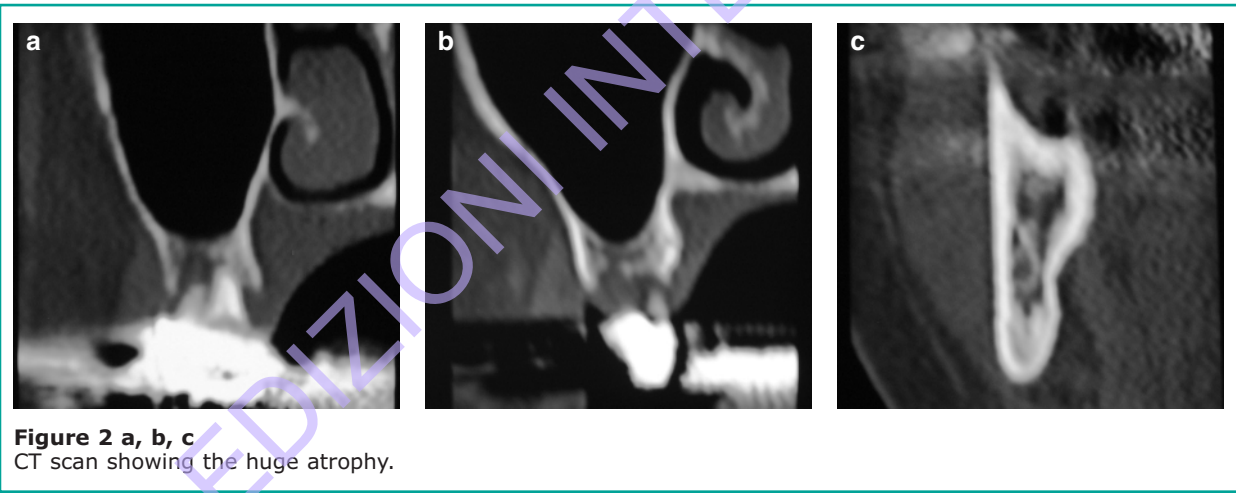
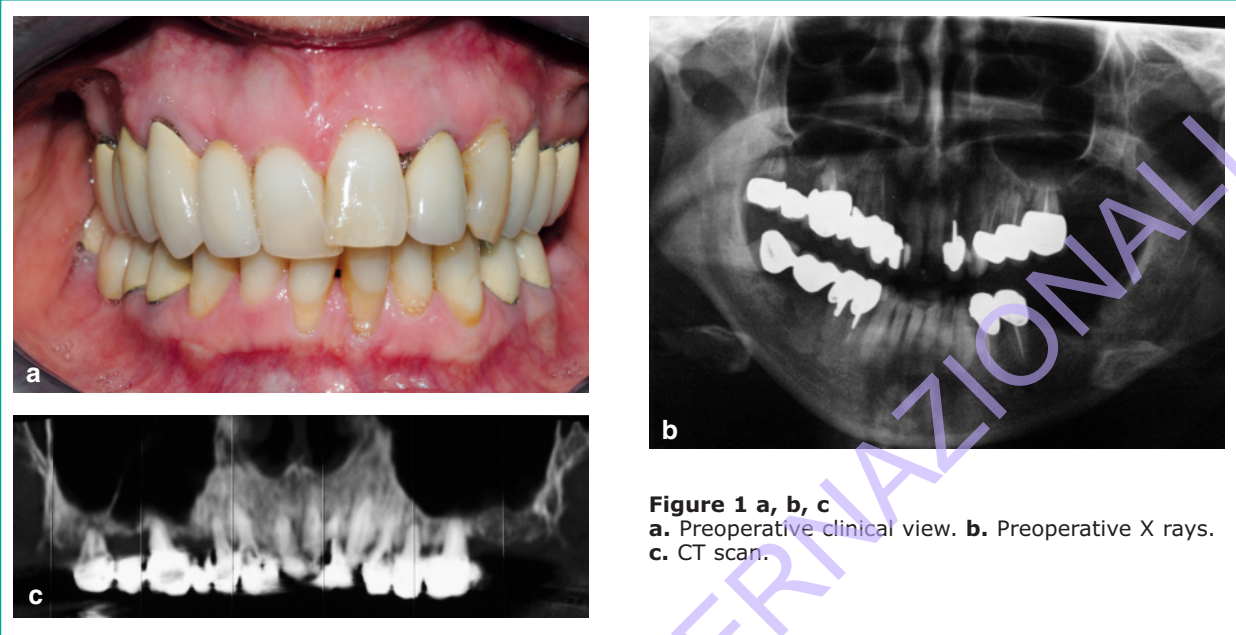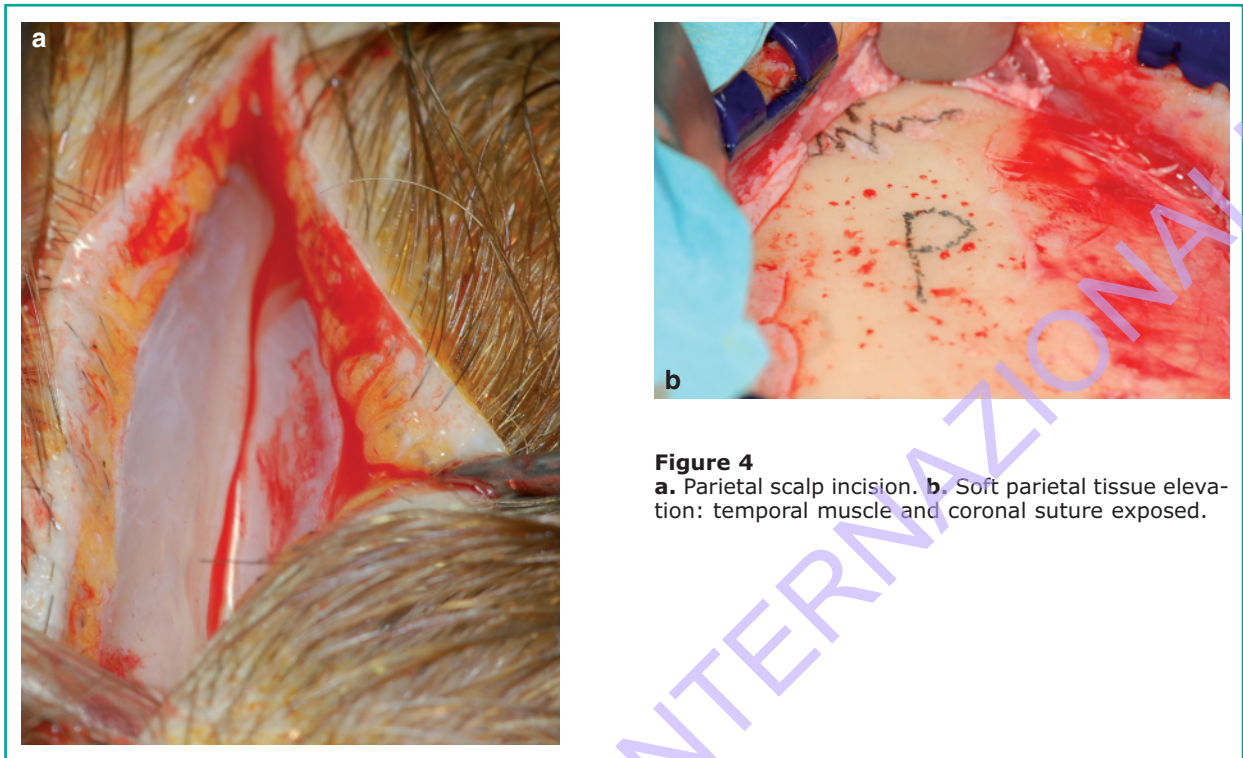




Figure 4
a. Parietal scalp incision. **b.** Soft parietal tissue elevation: temporal muscle and coronal suture exposed.

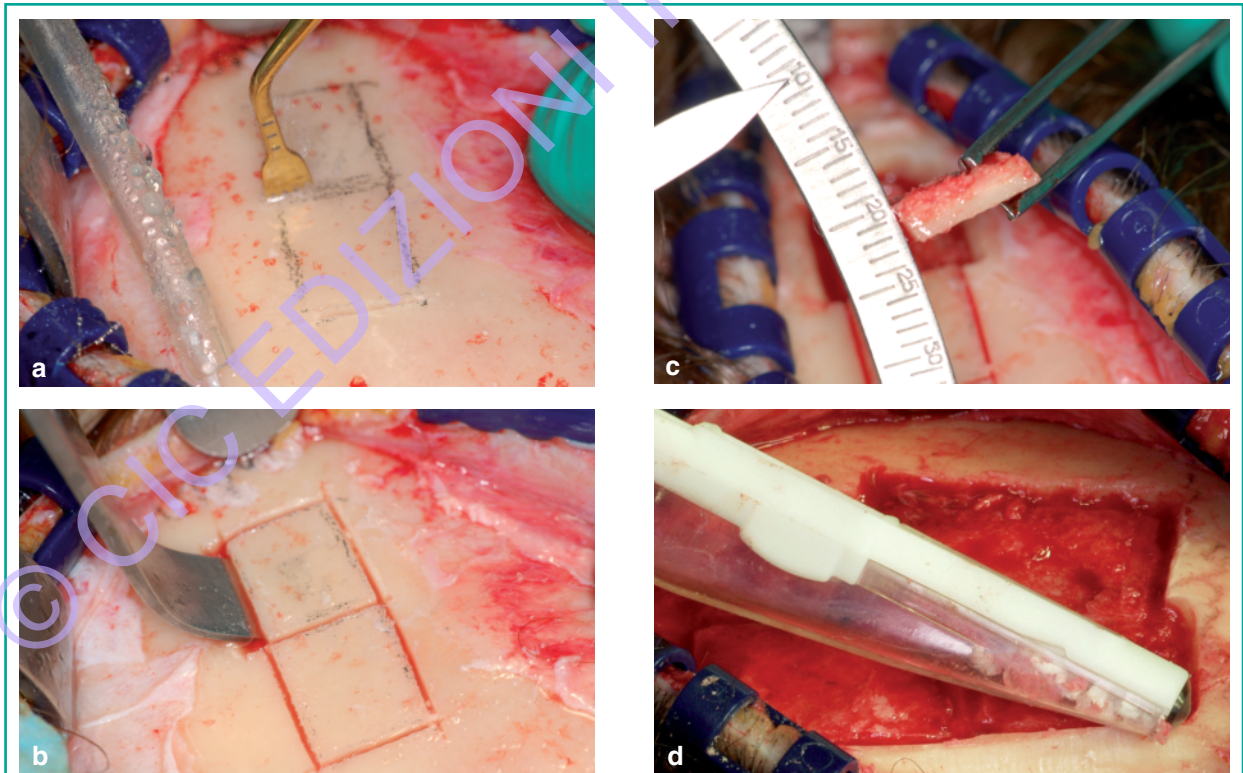


Figure 5 a, b, c, d
a. Osteotomies are performed with piezoelectric device. **b.** Harvesting of the first bone block. **c.** Particular of the first block (splitting in situ calvarial graft): graft thickness. **d.** Donor site margins beveling: bone chips are collected.

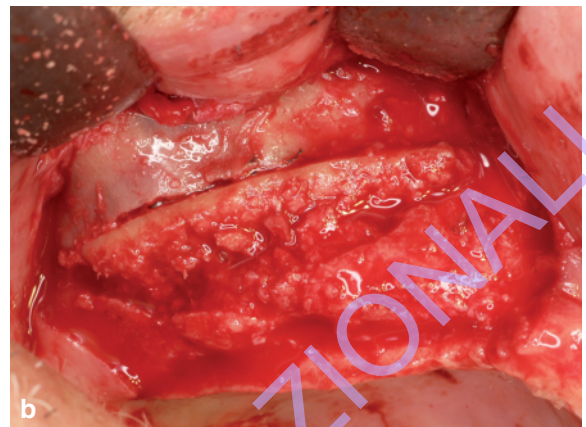
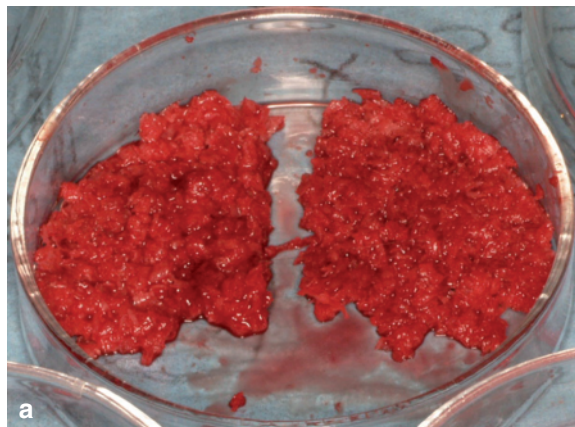


Figure 6 a, b
a. Bone chips magnification. **b.** Sinus lift performed with modified Tulasne technique.

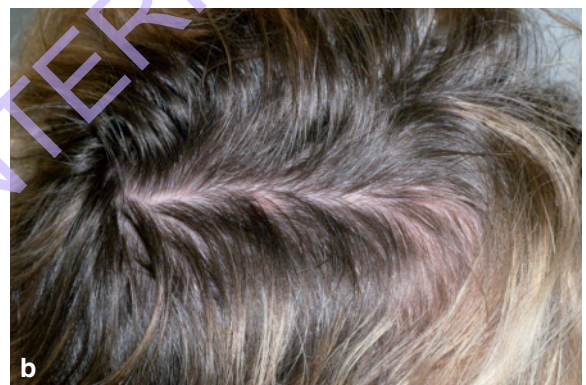
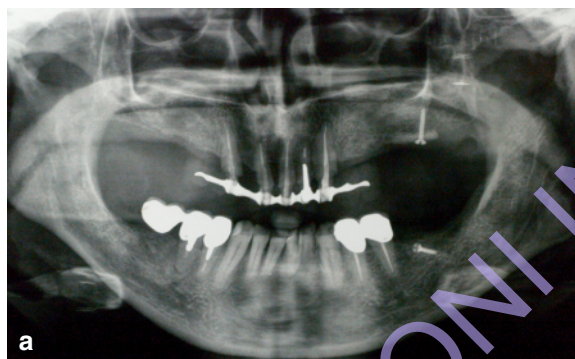
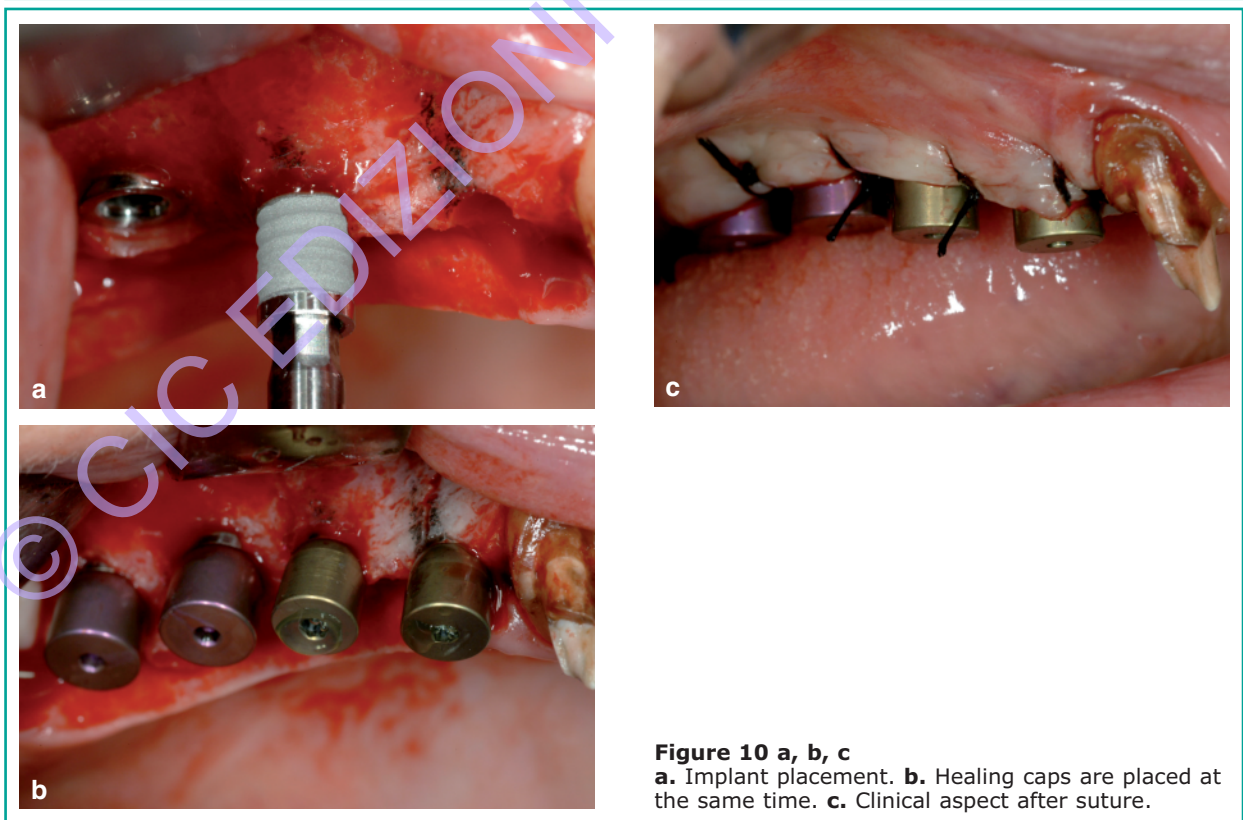
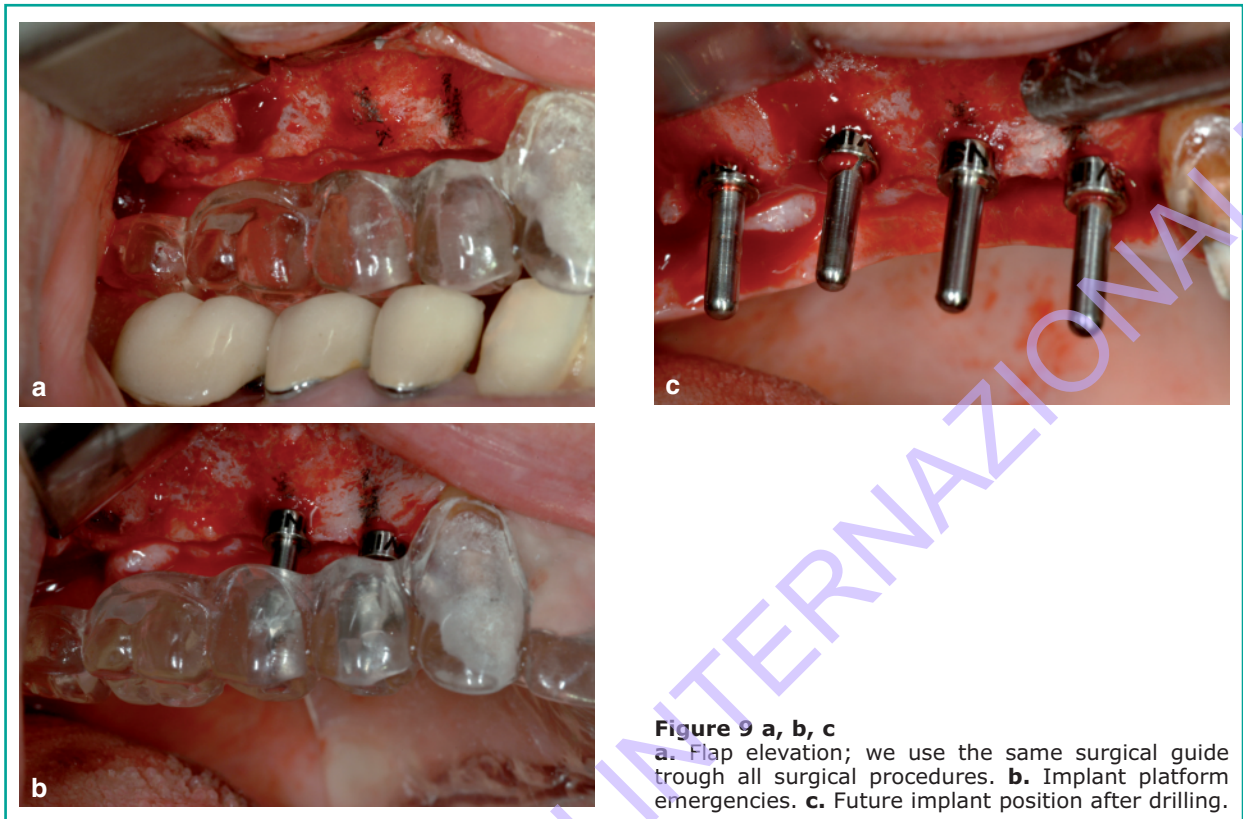


Figure 7 a, b
a. 4 months x ray control: evidence of bilateral sinus lift and good shape of bone blocks. **b.** Absence of surgical scars and alopecia.

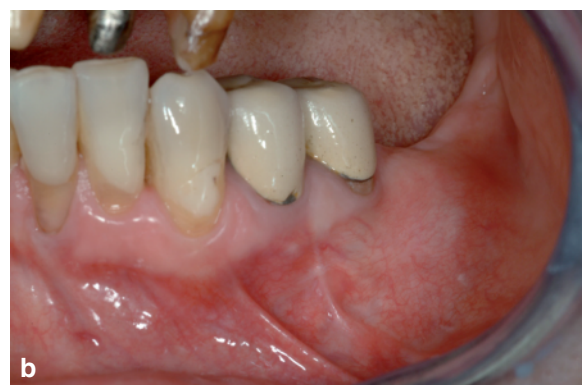
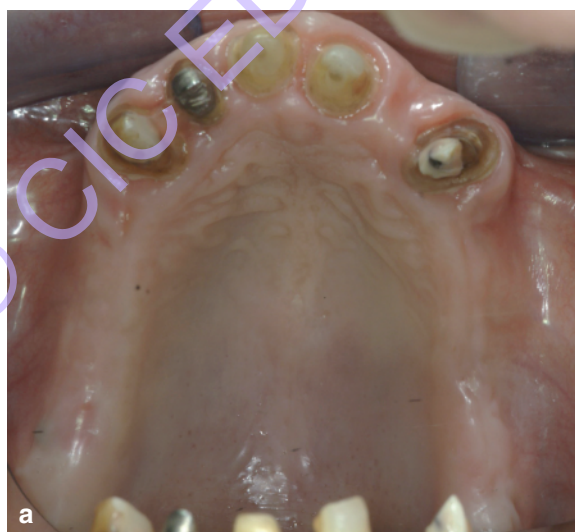
Figure 8 a, b
a. Ridge crest aspect at the time of second surgery. **b.** Mandibular ridge aspect after bone reconstruction with tunnel technique (see the vertical scar near 3.4 element).



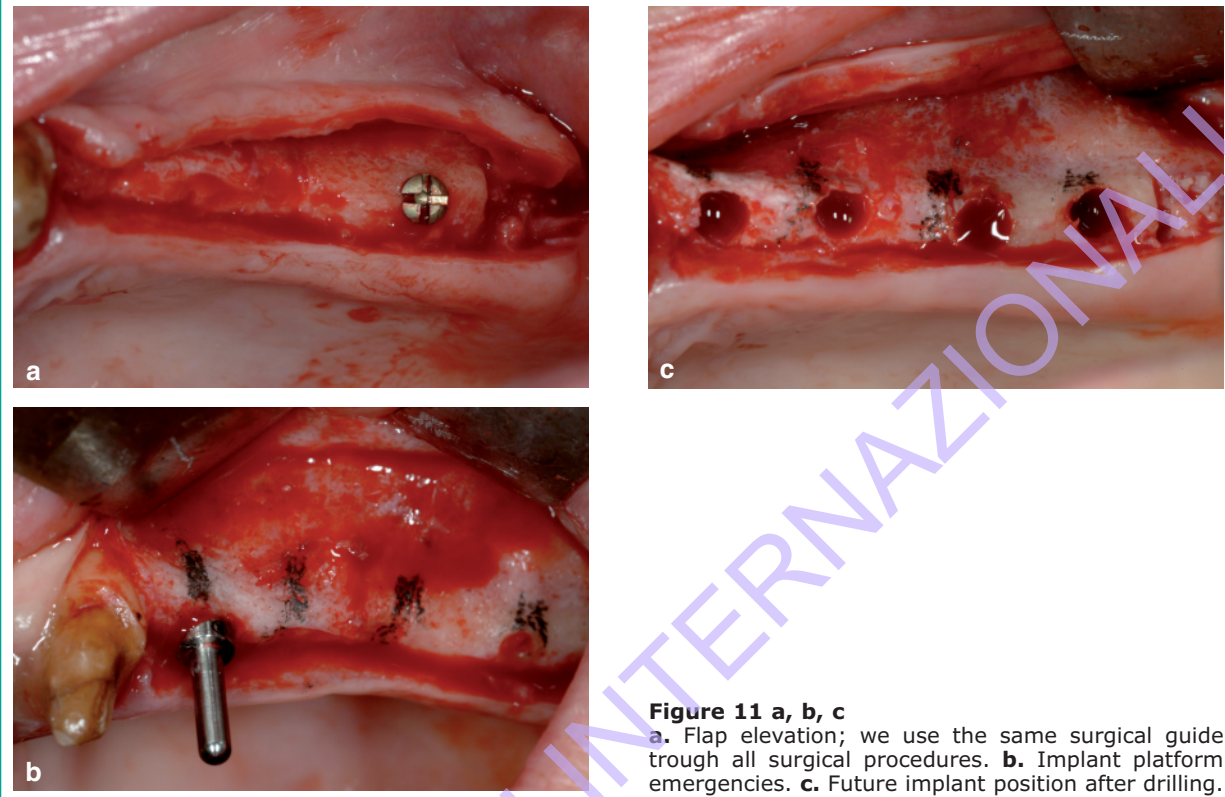


Figure 11 a, b, c
a. Flap elevation; we use the same surgical guide trough all surgical procedures. **b.** Implant platform emergencies. **c.** Future implant position after drilling.

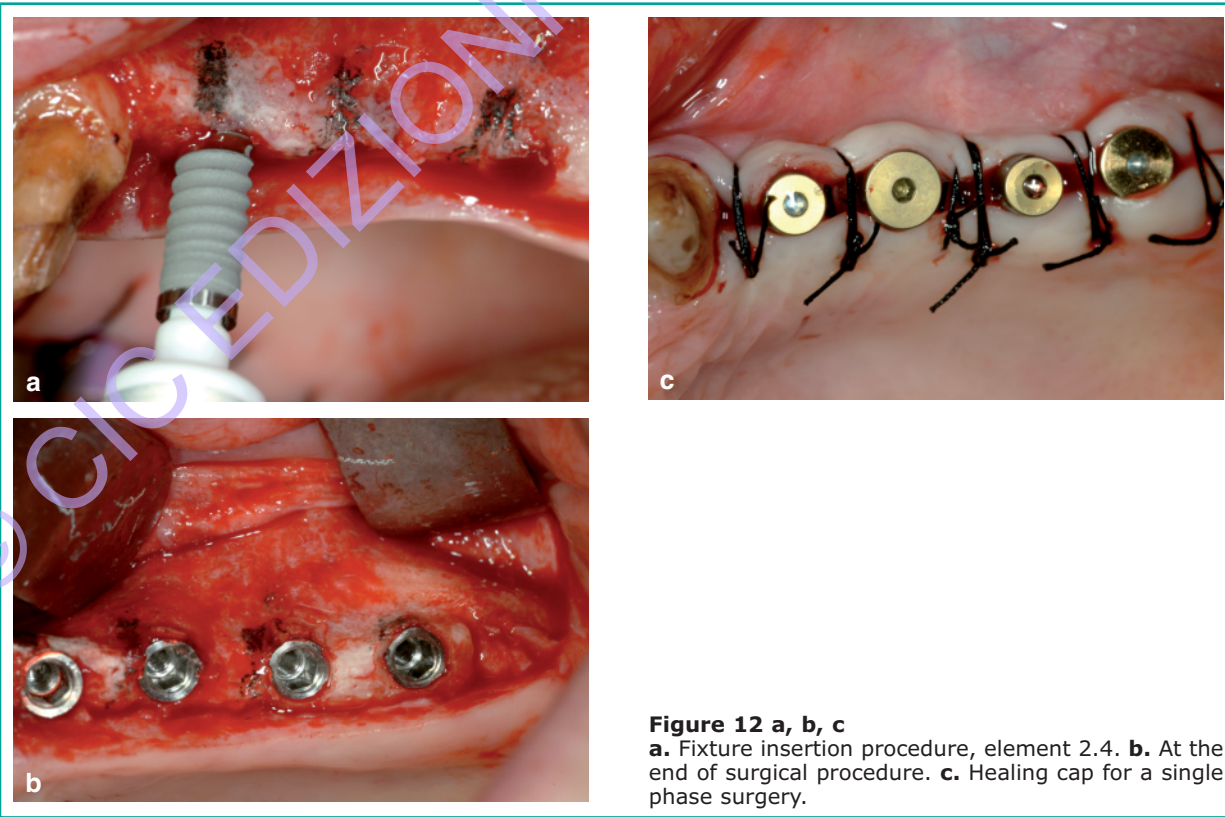


Figure 12 a, b, c
a. Fixture insertion procedure, element 2.4. **b.** At the end of surgical procedure. **c.** Healing cap for a single phase surgery.

new bony box created was replenished with bone chips, that provides better angiogenesis than block insert (12, 13).

The new bony recovery happens with a struggle between osteogenesis and fibrosis. The more you increase the space between the surface, the more you can have fibrous tissue in between. Lag screw fixation among opposite bony surfaces gives a quicker recovery, reducing neo-osteogenesis needs (14-16) (Figs. 8 a, b).

Winsix implants (by BIOSAF), with SLA surface, were placed after 4 months, by two-stage procedure (17) (Figs. 9 a, b, c; 10 a, b, c; 11 a, b, c; 12 a, b, c).

The surgical mask, previously manufactured, is the same used during the reconstruction phase. After 3 months, healing caps are placed and the patient is ready to finalize the work.

In the first outpatient appointment with the

prosthodontist, preparation of abutments and insertion of temporary crowns is performed. The crowns are obtained by transfer of fixtures position on a master model (Figs. 13 a, b, c, d).

A silicone mask, derived by wax up, consented an individual milling of abutments, outside the patient mouth (Figs. 14 a, b, c, d, e).

Remodelled fixtures abutments were experienced in the oral cavity, with particular regards to inter-abutments distance and intermaxillary discrepancy. A new precision impression on natural teeth was taken to transfer tridimensional position, by precision copings. Metallic structure of both natural and implanted elements were optimized and experienced in the oral cavity, with a new positioning taken to realize crude ceramic manufacture. A second test was performed with special regards to function congruity and aesthetic.

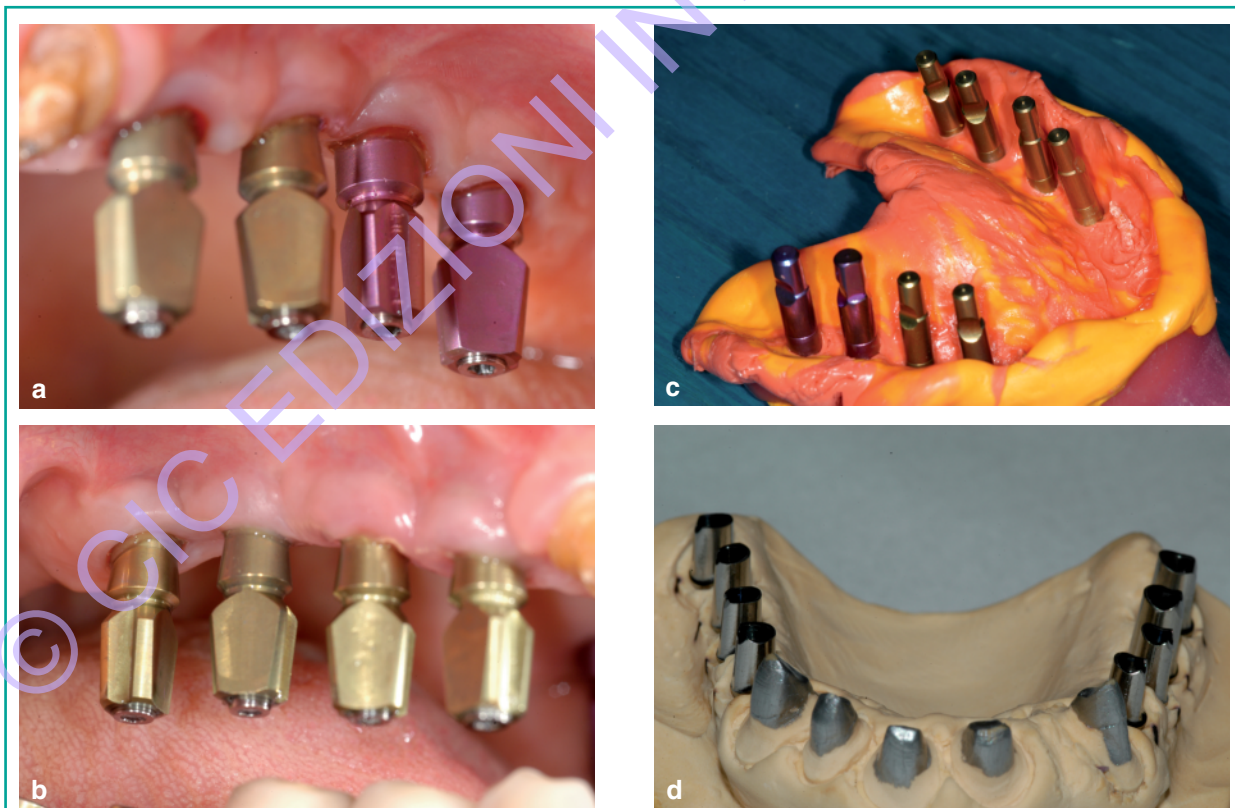


Figure 13 a, b, c, d
a, b. Transfer positioning for impression. **c.** Impression. **d.** Wax model with metal abutments both for natural teeth and implants.

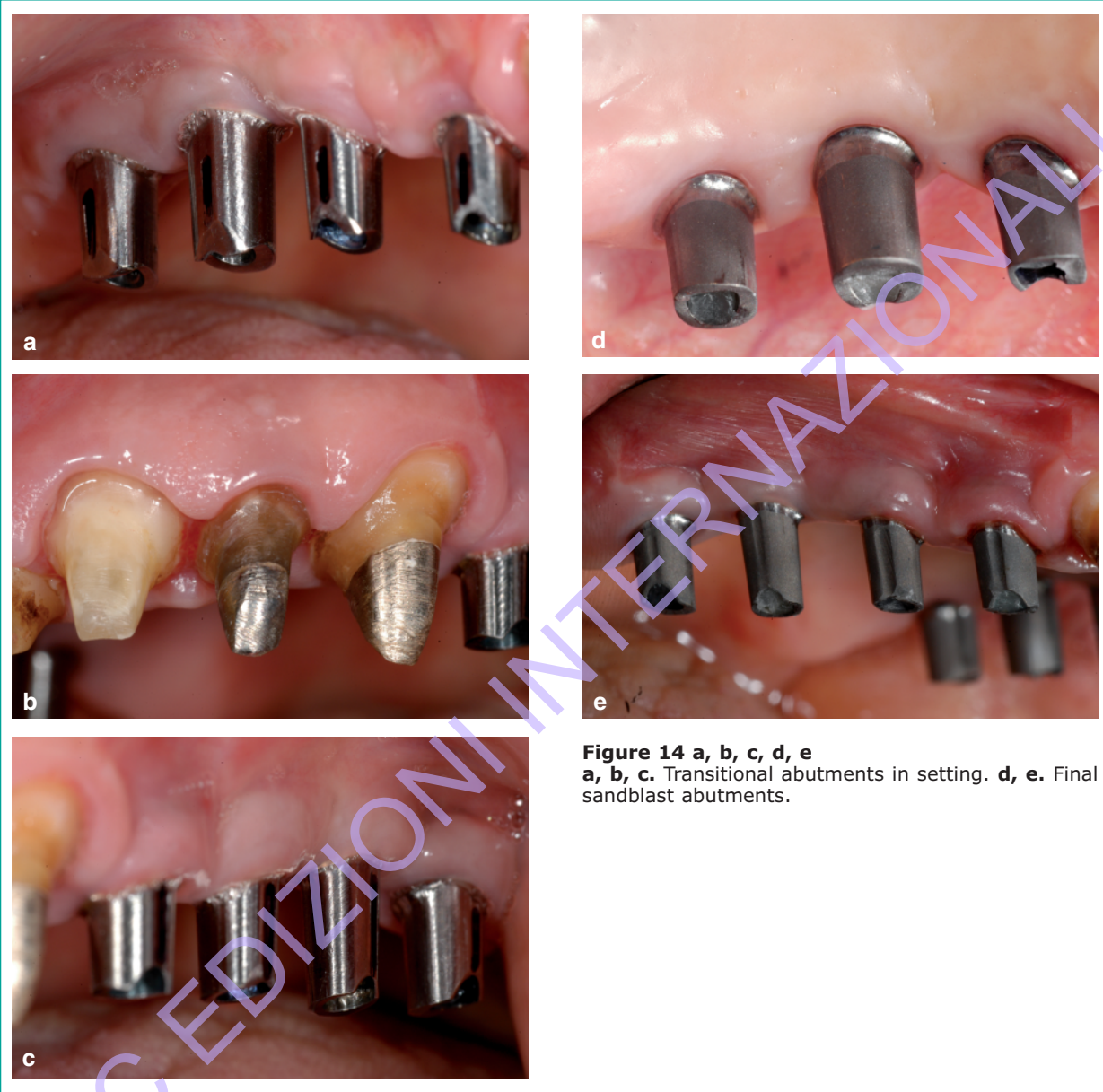

Figure 14 a, b, c, d, e
a, b, c. Transitional abutments in setting. **d, e.** Final sandblast abutments.

Because of the presence of natural elements to the canine level, after blockage and static control, a lateral canine guide was realized, as prescribed in implant-supported prosthesis protocols. Once the manufacture is finished, it is positioned previous fixation with intermediate cement (Figs. 15 a, b; 16 a, b, c).

Conclusions

Prosthetic fixed rehabilitation of severe maxillary atrophy can be obtained previous bone volume reconstruction: autologous graft is still considered the “gold standard” (2).

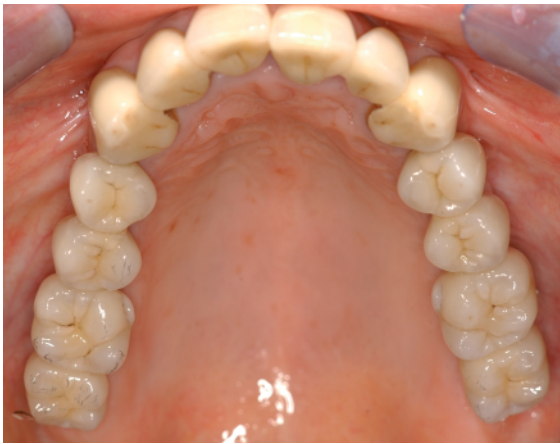

Figure 15
Positioned Prosthetic manufacture.

Among different extra oral withdrawal sites, our experience suggests that calvarial monocortical grafts (*splitting in situ calvarial graft*) provide best middle and long lasting results.

Cellular and structural features of the graft and the large available quantity of bone makes autologous membranous bone grafts, positioned with lag screw technique, the overall best solution to tridimensional maxillary reconstruction. Well vascularized site and primary soft tissue closure is mandatory (14, 18, 19).

Prosthetic protocol for the final manufacture must be meticulous. Particular attention must be given to precision, emergence profile, static and dynamical occlusal loading distribution.

An accurate treatment planning is mandatory;

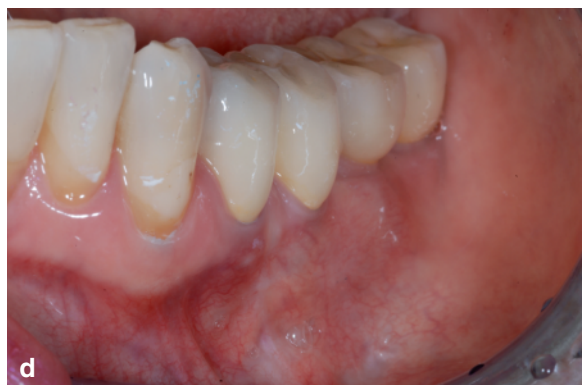
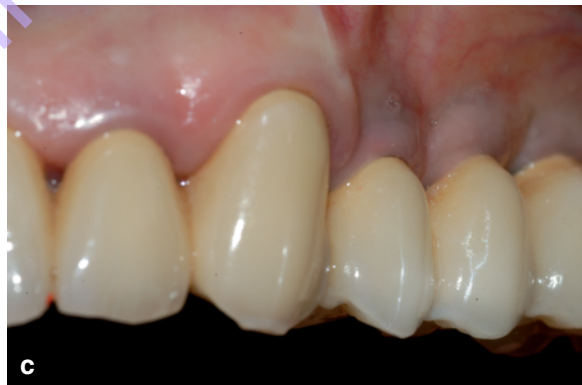
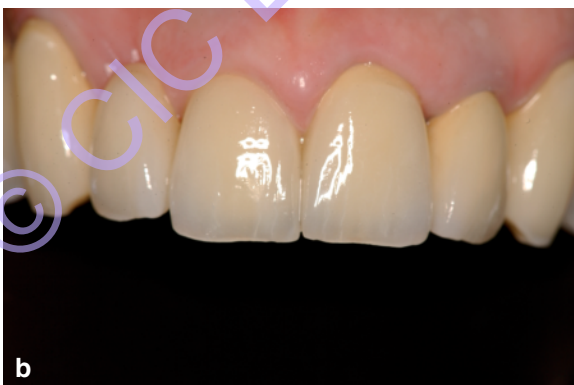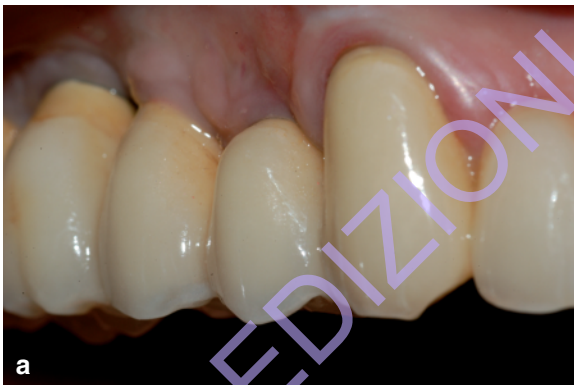Figure 16 a,b,c,d
1 Year Follow -up.

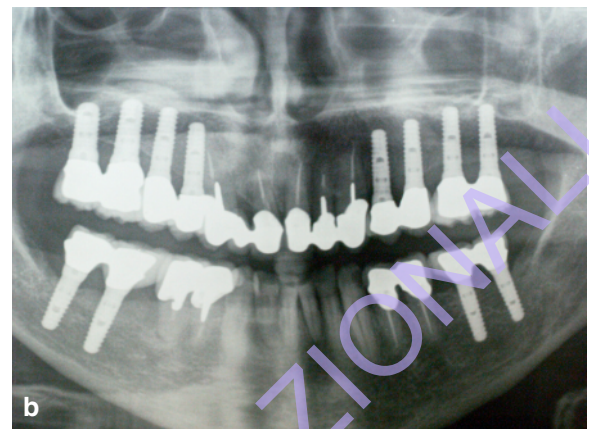
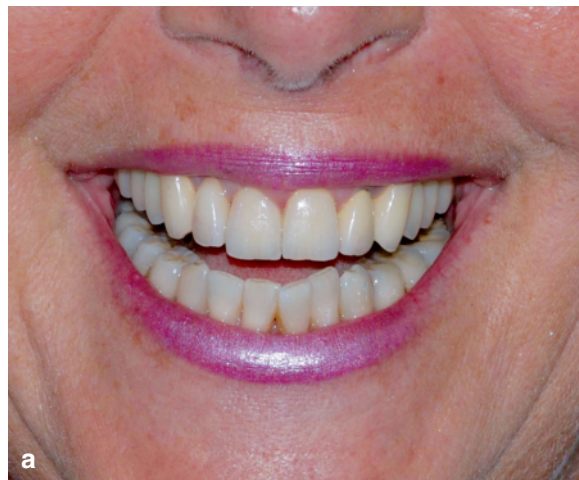

Figure 17 a, b
a. 3 Years clinical and radiographic. **b.** Follow up.

successful rehabilitation depends on the ability of the surgeon, prosthodontist and dental technician to work together always keeping in mind what the final result should be.



References

- Gherlone EF. La protesi su impianti osteointegrati – procedure cliniche. Masson 2004.
- Gherlone EF. L'impronta in protesi dentaria. Seconda ed. Masson 2005.
- Tong L, Buchman SR. Facial bone grafts: contemporary science and thought. *J Craniomaxillofac Trauma* 2000; 6: 31-36.
- Cawood JL, Howell RA. A classification of the edentulous jaws. *Int J Oral Maxillofac Surg* 1998; 17(4): 232-236.
- Carinci F, Farina A, Zanetti U, Vinci R, Negrini S, Calura G, Laino G, Piattelli A. Alveolar ridge augmentation: a comparative longitudinal study between calvaria and iliac crest bone grafts. *J Oral Implantology* Vol. XXXI, No. 1, 2005.
- Hwang K, Hollinger JO, Chung RS, Lee SI. Histomorphometry of parietal bones vs age and race. *J Craniomaxillofac Surg* 2000; 11 (1): 17-23.
- Tessier P. Autogenous bone grafts taken from the calvarium for facial and cranial applications. *Clin Plast Surg* 1982; 9: 531-538.
- Tessier P, Kawamoto H, Matthews D, Posnick J, Raulo Y, Tulasne JF, Wolfe SA. Taking calvarial grafts, either split in situ or splitting of the parietal bone flap ex vivo-tools and techniques: V. A 9650-Case experience in Maxillofacial and Craniomaxillofacial Surgery. *Plast Reconstr Surg* 2005; 116 (5 suppl): 54S-71S.
- Vinci R, Di Stefano D, Gherlone EF. Il prelievo della teca cranica. *Italian Oral Surgery* 4/2005, 37-43.
- Labanca M, Vinci R, Azzola F, Rodella LF. Piezoelectric surgery: twenty years of use. *Br J Oral Maxillofac Surg* 2008 Jun; 46(4): 265-9.
- Le Lorc'h-Bukiet I, Tulasne JF, Llorens A, Lesclous P. Parietal bone as graft material for maxillary sinus floor elevation: structure and remodelling of the donor and of recipient sites. *Clin Oral Impl Res* 2005; 16: 244-249.
- Pallesen L, Schou S, Aaboe M, Hjorting-Hansen E, Nattestad A, Melsen F. Influence of particle size of autogenous bone grafts on the early stages of bone regeneration: a histologic and stereologic study in rabbit calvarium. *Int J Oral Maxillofacial Imp* 2002; 17: 498-506.
- Orsini G, Bianchi AE, Vinci R, Piattelli A. Histologic evaluation of calvarial bone in maxillary onlay bone grafts: a report of 2 cases. *Int J Oral and Maxillofac Implants* 2003; 18(4): 594-8.
- Vinci R. Bone grafts from the calvaria: Diagnosis, instrumentation, harvesting techniques and surgical procedures. In: *Bone augmentation in oral implantology*. Quintessence books 2007; 7: 213-240.
- Bianchi AE, Vinci R, Sanfilippo F, Torti S. Possibil-

- ità terapeutiche e risultati a lungo termine di innesti di apposizione verticale. *Implantologia Orale* 2003; 4: 61-65.
16. Bianchi AE, Vinci R, Torti S, Sanfilippo F. Atrophic mandible reconstruction using calvarial bone grafts and implant-supported overdentures: radiographic assessment of autograft healing and adaptation. *Int J Period Restor Dent* 2004; 24(4): 335-43.
 17. Tetè S, Mastrangelo F, Traini T, Vinci R, Sammartino G, Marenzi G, Gherlone E. A macro- and nanostructure evaluation of a novel dental implant. *Implant Dent* 2008 Sep; 17(3): 309-20.
 18. Raghoobar GM, Batenburg RH, Vissink A, Reintsema H. Morbidity and complications of bone grafting of the floor of the maxillary sinus for the placement of endosseous implants. *Mund Kiefer Gesichtschir* 1999; 3 (1): 65-69.
 19. Crespi R, Vinci R, Capparè P, Gherlone E, Romanos GE. Calvarial vs iliac crest autologous bone grafted material for sinus lift procedure. A histomorphologic study. *Int J Oral Maxillofacial Implants* 2007; 22: 527-532.

Correspondence to:

Raffaele Vinci MD, DMD
Dip. di Odontoiatria
IRCCS H San Raffaele
Via Olgettina, 48 MI
E-mail: vinci.raffaele@hrs.it

© CIC EDIZIONI INTERNAZIONALI