

# Leiomyoma of oral cavity: case report and literature review

Sfasciotti Gianluca, MD, PhD, DDS  
 Roberta Marini, DDS  
 Federica Tonoli, DDS  
 Maria Paola Cristalli, DDS, PhD

"Sapienza" University of Rome, Rome, Italy  
 Department of Odontostomatological  
 and Maxillofacial Sciences

Corresponding author:  
 Gian Luca Sfasciotti  
 Via Famiano Nardini 1/e  
 00162 Rome, Italy  
 Ph/Fax +39068610788

## Summary

**Leiomyoma of oral cavity: case report and literature review.**

*Leiomyoma is a benign smooth muscle tumour, that occurs most frequently in the uterine myometrium, gastrointestinal tract, skin and lower extremities of middle-aged women. Leiomyomas are uncommon in the oral cavity, but in this location are usually localized on the tongue, lips and palate. Most lesions are asymptomatic, although occasional tumours can be painful. The diagnosis is mainly determined by histological studies due to its unspecific clinical appearance. The purpose of this article is to present a case report of 49-year-old male patient with a lesion of the lower lip. After surgical resection hematoxylin-eosin staining confirmed the diagnosis of leiomyoma.*

**Key words:** leiomyoma, solid leiomyoma, differential diagnosis, oral neoplasms.

## Introduction

Leiomyoma is a smooth muscle benign tumour that can appear at any location, being the most frequent site the female genital tract (95%), followed by skin (3%), gastrointestinal and food intrake tract (1,5%). Less than 1% occur in head and neck structure (1). Only 0.065% of the leiomyomas had an intraoral location, caused by the lack of smooth muscle at this site (2,3).

Smooth muscle is scarce in the oral cavity so it was assumed that the formation of leiomyoma resulting from media layer of blood vessels and smooth muscle of excretory ducts of salivary glands (4,5).

Clinically the oral leiomyoma is characterized by a small (<2cm) and solitary nodular mass, slow growth located principally in the tongue, lips, palate and buccal mucosa: fre-

quently it is asymptomatic but there may be symptoms such as pain, teeth mobility or difficulty in chewing (6,7,8).

Histologically there are three types of leiomyomas: leiomyoma (solid), angiomyoma (vascular leiomyoma), and the rare form of epitheloid leiomyoma (leioblastoma). In tumours of the solid type blood vessels are large in number but usually small in size and slit-like. Tumours of the venous type have venous blood vessels with thick muscular walls. The outer layers of the smooth muscle in the vascular walls blend with intervascular smooth muscle bundles. Tumours of the cavernous type are composed of dilated vascular vessels with small amounts of smooth muscle, and the muscular walls of these vessels are difficult to distinguish from smooth muscle bundles (9).

From the clinical presentation is very difficult to differentiate a leiomyoma from other mesenchymal tumours: the diagnosis is mainly determinate histologically

At present, surgical resection is the main treatment of leiomyoma and recurrences are extremely unfrequent.

We hereby present a case of leiomyoma, its treatment and literature review.

## Case report

A 49-year-old Italian man presented with a 8-year history of a well circumscribed, asymptomatic and mobile mass in the lower lip. On macroscopy, the mass presented an irregular oval shape, a brownish colour, a smooth surface and a resilient consistency (Fig. 1).

The mass was surgically excised under local anesthesia (mepivacaine 2% with adrenalin 1:100.000 - Carboplyina, Dentsply) with the scalpel. An elliptic incision was made to fully enucleate the lesion along with the overlying mucosa (Figs. 2,3). It's important to obtain a complete resection in order to avoid recurrences. Usually easily due to its characteristics as a well-circumscribed tumour. Finally, a 5.0-reabsorbable suture (Monocryl - Ethicon) was performed (Fig. 4).

After surgery, patient was given ibuprofen 600 mg (Brufen 600, Abbott) as analgesic and was instructed to apply chlorhexidine digluconate 0.1% (Corsodyl Gel Dent 30 g 1g/100) as a gel to the surgical zone.

The specimens (Fig. 5) obtained were fixed in 10% formalin solution. Histological examination gave the diagnosis of solid leiomyoma (Fig. 6).

The postoperative course of the patient was uneventful with a 10 days follow-up. The tissue is completely healed and there is no sign of scar (Fig. 7a). There was no recurrence at 24 months follow-up (Fig. 7b).

## Discussion

Oral leiomyomas can appear at any age, but the greatest

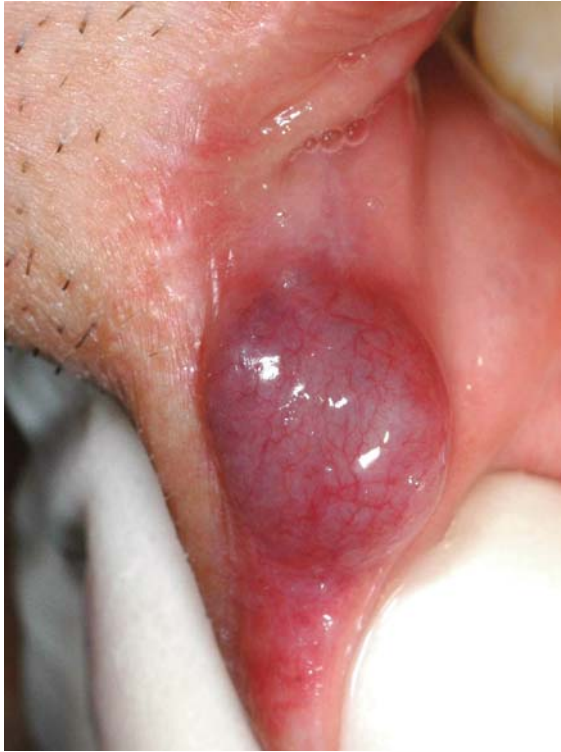

Figure 1 - Clinical presentation of the lesion.

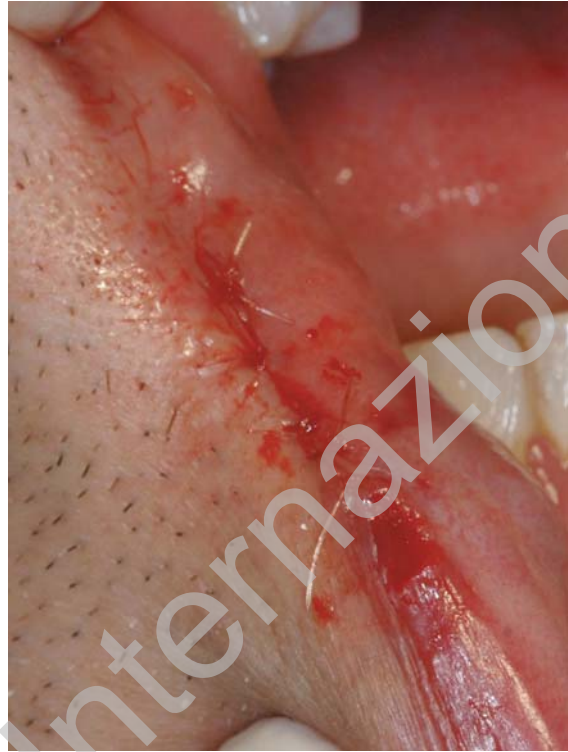

Figure 4 - Suture of the wound.

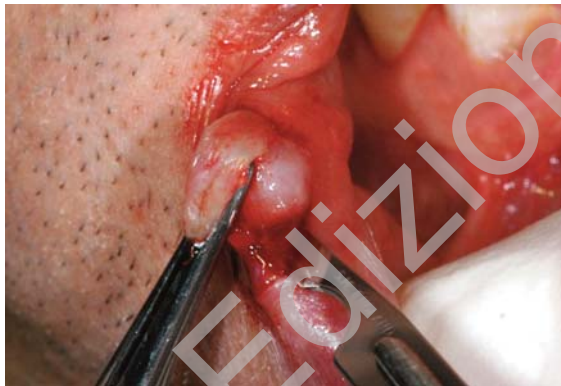

Figure 2 - Surgical excision.

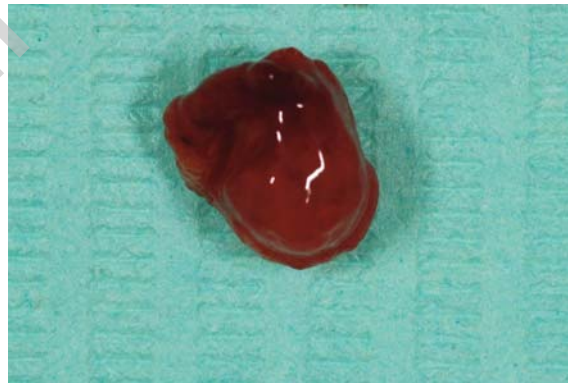


Figure 5 - Lesion removed.

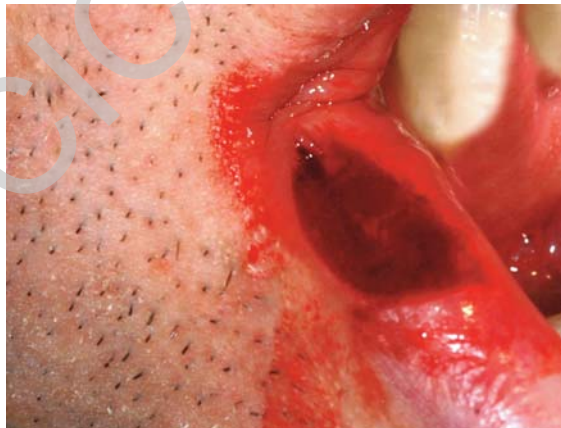


Figure 3 - Post-surgical view.

prevalence is in the 40-59 years age groups with gender preference for female, being the most frequent locations the lips, tongue, hard and soft palate, and much less frequently in the cheeks (10,11): in this case the age is 49 years old and the site is the lower lip.

The leiomyoma was included in the World Health Organization classification of tumors of soft tissue (WHO 2002) in the group of tumors arising from smooth muscle. The WHO also distinguished three types of leiomyoma: the most frequent type is angiomyoma with a 74%, followed by solid leiomyomas with a 25% and there is only one case of an epitheloid leiomyoma described in the literature (12). The vascular leiomyoma is the most frequent in the oral cavity; smooth muscle is scarce in the oral cavity, however



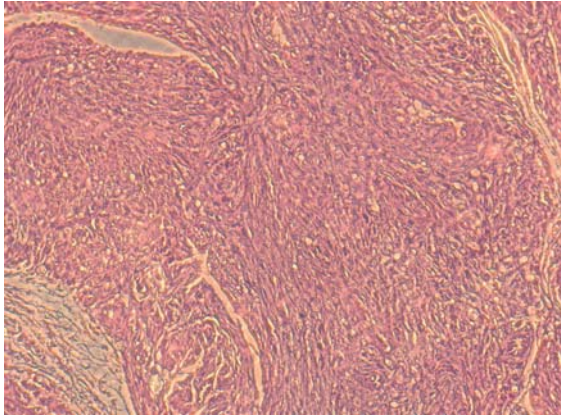


Figure 6 - Histologic findings shows muscle cells with areas of sclerosis and dystrophic calcification; the cells were small and fusiform, and the nucleus was uniform, monochromatic and spindles, with blunt ends, no mitotic figures were found (Hematoxylin-Eosin stain, original magnification x10).

this region is rich in blood vessels. Therefore it has been proposed that media layer of blood vessels may be the origin of oral cavity vascular leiomyoma (6).

The histological exam of the case report diagnosed that the tumour was solid, rare type for the oral site. Solid leiomyomas are smaller than the vascular type and the neoformation of the case is 0.8 x 0.5 x 0.4 cm. Histologically the solid leiomyoma is comprised of interlacing bundles of spindle-shaped or stellate smooth muscle cells with elongated, blunt-ended, pale-staining nuclei: lesions are rather cellular, but collagenic strands often separate the streaming bundles of tumor cells, and occasional leiomyomas have a prominent fibroblastic or myxoid component. All the histological characteristic were present in our histological analysis (13).

From the clinical appearance is very difficult to differentiate a leiomyoma from other mesenchymal tumours such

as, fibroma, neurofibroma, lipoma, or the leiomyosarcoma. The differential diagnosis is also more problematic with fusocellular tumours like solitary myofibroma and myopericytoma. The differential diagnosis must include salivary gland neoplasms (mucocele, pleomorphic adenoma, etc.), vascular tumors (lymphangioma, hemangioma, pyogenic granuloma, etc.), and soft tissue cysts such as dermoid cysts. When located in the region of the hard palate, adjacent to teeth the tumor can be confused with a periodontal lesion.

Our case had prompted us to assume that the tumor was a hemangioma: macroscopically there were all the characteristics of the vascular lesion such as color, texture, absence of pain. Therefore the final diagnosis of oral leiomyoma is mainly determined by a histological study (6-13).

The exclusive treatment option in benign smooth muscle tumours appears to be a surgical excision. Surgery has been used as the only option for treatment in all leiomyomas described in literature. There are no reports of recurrence after total excision, and this result confirms the need for careful total excision of the lesion. In our case we did a total resection of the mass under local anaesthesia and the patient did not present complication and recurrences pathological at two years follow-up.

### Conclusion

In conclusion, the oral cavity leiomyoma is a benign neoplasm characterized by a small, solitary, asymptomatic, nodular mass, located more frequently in the lower lip. The highest prevalence of head and neck leiomyoma is observed in the 4<sup>th</sup> and 5<sup>th</sup> decade of life with gender preference for female. Histological features include small cells with eosinophilic cytoplasm and basophilic nucleus. Not mitotic figures, cellular atypia and areas of necrosis were observed.

Oral leiomyoma was frequently asymptomatic and required the complete surgical excision.

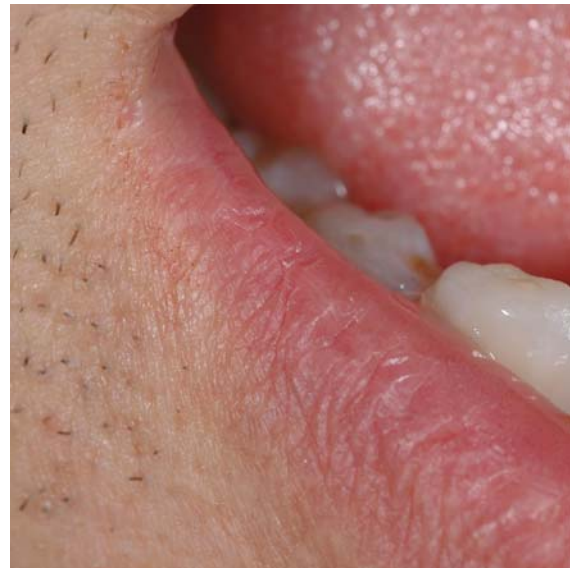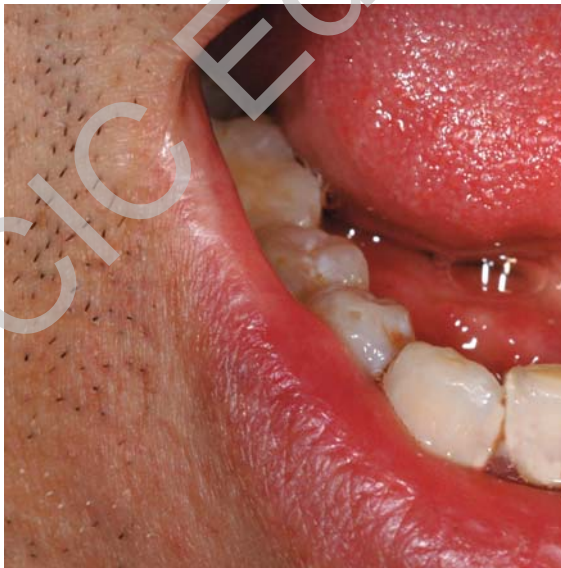


Figure 7 - Clinical follow-up after 10 days (a) and 24 months (b) from the operation.

## References

1. Campelo VES, Neves MC, Nakanishi M, Voegels RL. Nasal cavity vascular leiomyoma: a case report and literature review. *Rev. Bras. Otorrinolaringol.* 2008;74(1):147-50.
2. Farman AG. Benign smooth muscle tumors. *S Afr Med J.* 1975;49:1333. En: Farman AG, Kay S 1977;43:402.
3. Lloria-Benet M, Bagà JV, Lloria de Miguel E, Borja-Morant A, Alonso S. Oral leiomyoma: a case report. *Med Oral.* 2003;8(3):215-9.
4. Stout AP. Solitary cutaneous and subcutaneous leiomyoma. *Am J Cancer* 1937;29:435.
5. Glas E. Beiträge zur pathologie der zungengrudtumoren. *Wein Klin Wochenshr* 1905;18:747.
6. Guitan Cepeda LA, Quezada Rivera D, Rocha FT, Leyva Huerta ER, Mendez Sánchez ER. Vascular leiomyoma of the oral cavity. Clinical, histopathological and immunohistochemical characteristics. Presentation of five cases and review of the literature. *Med Oral Patol Oral Cir Bucal.* 2008;13(8):E483-8.
7. Cherrick H, Dunlap C, King O. Leiomyomas of the oral cavity. Review of the literature and clinicopathologic study of seven new cases. *Oral Surg* 1973;35:54.
8. Kelly D, Harrigan W. Leiomyoma of the tongue: report of a case. *J Oral Surg* 1977;35:316.
9. WHO Pathology and Genetics of Tumours of Soft Tissue and Bone Edited by Christopher D.M. Fletcher, K. Krishnan Unni, Fredrik Mertens (2002) pag. 128-34.
10. Luaces Rey R, Lorenzo Franco F, Gomez Oliveira G, Patino Seijas B, Guitià D, Lòpez-Cedrùn Cembranos JL. Oral leiomyoma in retro molar trigone. A case report. *Med Oral Patol Oral Cir Bucal.* 2007;12(1):E53-5.
11. González Sánchez MA, Colorado Bonnin M, Berini Aytès L, Gay Escoda C. Leiomyoma of the hard palate: a case report. *Med Oral Patol Oral Cir Bucal.* 2007;12(3):E221-4.
12. Leung K, Wong DY, Li W. Oral leiomyoma: report of a case. *Maxillofac Surg* 1990;48:735-8.
13. Baden E, Doyle JL, Lederman DA. Leiomyoma of the oral cavity: a light microscopic and immunohistochemical study with review of the literature from 1984 to 1992. *Eur J Cancer B Oral Oncol.* 1994 Jan;30B(1):1-7.