

Hyperplasia of parathyroid gland in a five-year old child affected by MEN 2A

Tommaso Marcucci¹
 Geri Fratini¹
 Gabriella Nesi²
 Vania Vezzosi²
 Francesca Marini³
 Maria Luisa Brandi^{3,4}
 Francesco Tonelli¹

¹ General Surgery Unit, Department of Clinical Physiopathology, ² Department of Human Pathology and Oncology, ³ Regional Center for Hereditary Endocrine Tumors, Department of Internal Medicine, and ⁴ DeGene Spin-off, University of Florence, Florence, Italy

Address for correspondence:

Francesco Tonelli, M.D.
 Department of Clinical Physiopathology
 General Surgery Unit
 Viale Morgagni 85, I-50134 Firenze, Italy
 Ph. +39 055 4277449
 Fax +39 055 4361770
 E-mail: f.tonelli@dfc.unifi.it

Summary

Primary hyperparathyroidism (HPT) is observed in 20-30% of patients with multiple endocrine neoplasia type 2A (MEN 2A). The age of diagnosis ranges from seven to seventy one year old (with median of thirty eight years) in patients affected by HPT in MEN 2A. We diagnosed primary HPT in a 5 year old boy carrier of *RET* gene mutation associated with MEN 2A, submitted to prophylactic total thyroidectomy (TT).

The *RET* mutated gene carriers are submitted to prophylactic TT at different ages. Recent studies demonstrated that based on the type of *RET* gene mutation the timing of TT varies, as the transforming potential of *RET*-mutations are codon-dependent with significant correlations between genotype and clinical phenotype in MEN 2A patients. In particular, the medullary thyroid carcinoma (MTC) occurs earlier in the patients with codon 634 mutations than in those with other mutations, and these patients have also a higher frequency of pheochromocytoma and hyperparathyroidism.

This genotype-phenotype correlation is confirmed in the patient described in this report, who was carrier of a germline mutation in the 634 codon (Cys→Trp) and showed early expression of MTC and parathyroid pathology. The young age of this patient represents an exception, as other Authors report the absence of parathyroid pathology in children or in adolescents submitted to prophylactic TT.

The patient underwent a partial parathyroidectomy in agreement with the preferred surgical treatment of HPT in MEN 2A, which consists in removing only the parathyroid(s) with increased volume. Indeed, the experiences with subtotal or total parathyroidectomy associated to autograft are very limited, with results supporting lack of major differences and, therefore, suggesting a more conservative surgical approach.

KEY WORDS: medullary thyroid carcinoma, multiple endocrine neoplasia

type 2A, preclinical genetic test, hyperparathyroidism.

Introduction

Primary hyperparathyroidism (HPT) is observed in 20-30% of patients with multiple endocrine neoplasia type 2A (MEN 2A) (1). The age of diagnosis in patients affected by HPT ranges from seven to seventy one year old (with median of 38 years) (2-4). The diagnosis of HPT is often made at the moment of the total thyroidectomy (TT) performed for the cure or the prevention of medullary thyroid carcinoma (MTC).

We diagnosed primary HPT in a 5 year old child affected by MEN 2A, who has been submitted to prophylactic TT.

Case report

A 5-year-old child of male sex was admitted to our observation in November 2002, since genetically diagnosed as MEN 2A carrier. The mother was affected by pheochromocytoma, medullary thyroid carcinoma and carrier of an activating mutation of the *RET* gene. The child had a silent clinic picture and underwent genetic analysis. The exam showed that he was carrying the same (TGC→TGG) mutation of the *RET* gene on the 634 codon of exon 11, with consequent aminoacidic substitution Cys→Trp in the encoded protein.

Ultrasound exam of the superior abdomen and of the neck (April 2003) did not identify significant alterations, with the absence of lesions at bilateral suprarenal level and regular thyroid as regard size and structure.

Biochemical exams showed abnormal levels (20.3 pg/ml; n.v.: male • 15.9 pg/ml, female • 8.5 pg/ml) of circulating calcitonin. Also non specific enolase (NSE) was higher than normal (16.7 ng/ml; n.v.: 0.0-13.0 ng/ml), urinary excretion of the principal adrenergic hormones (vanilylmandelic acid, metanephrine and normetanephrine) was within the normal range (1.82 mg/24h, 55 mcg/24h, 135 mcg/24h respectively; n.v.: 1.80-6.70 mg/24h, 52-341 µg/24h, 88-440 µg/24h), as also chromogranin A (CgA) (62 ng/ml; n.v.: • 123 ng/ml). Surprisingly, serum concentrations of ionized calcium and PTH were respectively 4.72 mg/dl (n.v.:4.10-5.30 mg/dl) and 44.4 pg/ml (n.v.:10-68 pg/ml).

On July 2003 the child was admitted to our Surgery Unit and underwent various diagnostic exams including pentagastrin test that resulted positive showing an abnormal response of calcitonin with a peak of 166 pg/ml after one min.

Both the genetic test and the biochemical profile of the patient were indicative for surgery. For this reason on July 2003 the child underwent total thyroidectomy with lymphadenectomy of the central compartment and transcervical thymectomy. During surgery all the parathyroid glands were identified. The superior right and inferior left parathyroid were found enlarged (7x3.5x3.8 mm, 6x4x3 mm, respectively) and, therefore, both parathyroids were excised. The intraoperative histological exam showed hyperplastic tissue at the superior right parathyroid level (Fig. 1).

The postoperative histopathological diagnosis was of multifocal medullary thyroid carcinoma with a major nodule measuring 3 mm in diameter, of hyperplastic lymphadenitis in the perithyroid lymphonodes and of hyperplasia of the parathyroid glands

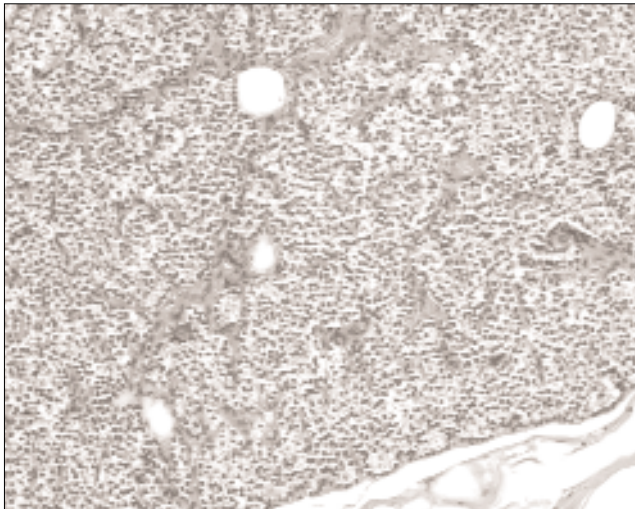


Figure 1 - Primary chief cell hyperplasia, with predominantly diffuse pattern of growth.

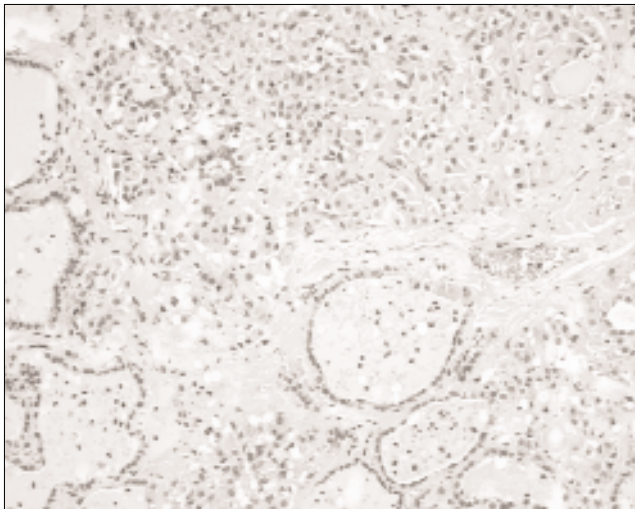


Figure 2 - Low-power view of medullary carcinoma showing nests of cells and deposition of amyloid.

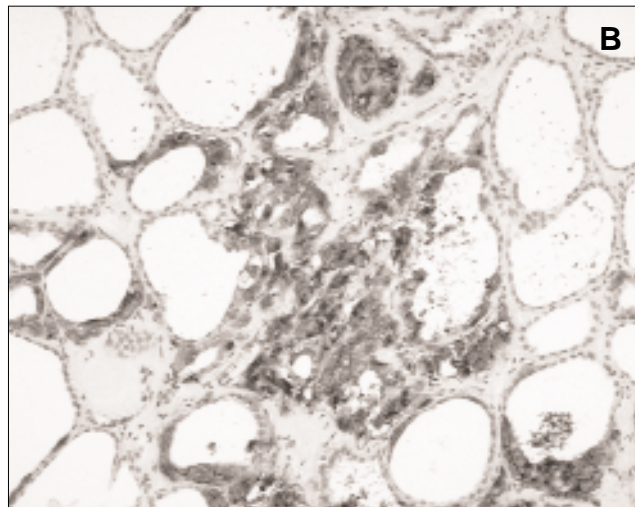
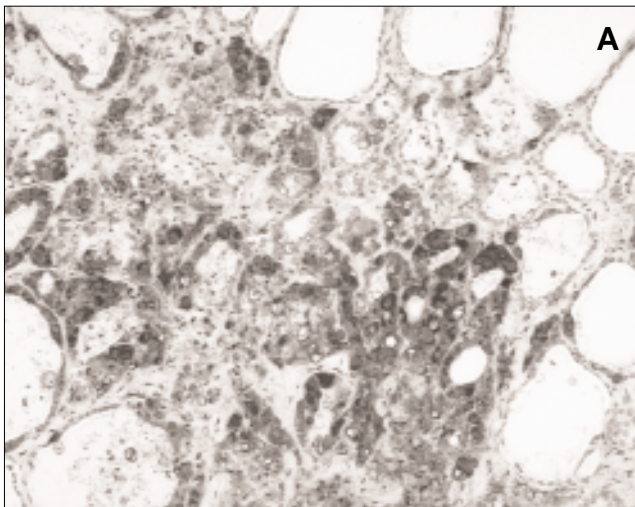


Figure 3 - Medullary carcinoma showing strong positive immunostaining for calcitonin (A) and CEA (B).

(Figs. 1, 2 and 3A,B). The child was discharged with thyroid substitutive therapy and a well controlled calcemia. At 17 months after surgery, he is in good health with normal calcium and PTH levels and a negative pentagastrin test.

Discussion

The *RET* mutated gene carriers are submitted to prophylactic TT at different ages. Some Authors recommend TT at 5 years of age in mutated gene carriers (5-7). Other Authors suggest that TT at the age of 2 years (8-9) or between 3 and 5 years (10) is necessary to obtain optimal cure rates. Recent studies demonstrated that based on the type of *RET* gene mutation the timing of TT varies, as the transforming potential of *RET*-mutations is codon-dependent (11), with a significant correlation between genotype and clinical phenotype in MEN 2A patients (12-15). In particular the risk to develop MTC and metastatic MTC (MMTC) is genotype-dependent, with higher age-independent risk of MTC and MMTC in c634 mutation carriers (81%) than in c618 (34%) and c620 (7%) mutation carriers (16). "In vitro" transfection studies confirmed these findings with variable codon specific neoplastic transforming capacity of c609, c611, c618, c620, c630, and c634 mutations in C-cells and with the highest values for the c634 mutation (11). These results were confirmed by the clinical observation that MTC occurs earlier in patients with c634 mutation, whereas patients with c611 and c804 mutations display a late expression of MTC (12, 17-19). Moreover, in a recent review it has been reported that the youngest patient with MTC, a one year old, carried out the c634 *RET* mutation, while mutations in codons c618, c804, and c620 have as earliest age of expression respectively 7, 15, and 15 years (16). Therefore, the codon analysis has prognostic value and the knowledge of specific malignant potential of each codon may make possible to select the timing of TT based on genotype (16).

Interestingly, patients with codon 634 mutations have a higher frequency of pheochromocytoma and hyperparathyroidism than those with other mutations (14,15). These phenotypic characteristics are confirmed in the patient described in this report, who showed early expression of MTC and parathyroid pathology and who is carrier of a germline mutation in the 634 codon (Cys→Trp).

Epidemiological data on the incidence of HPT in MEN 2A patients showed that HPT is observed more frequently in some

families, whereas in others it is not present also after a long follow-up from TT (20). These results have been explained on the basis of a decreased risk of HPT due either by the excision or by the damage of the parathyroids or by the possible elimination of a parathyroid stimulating factor produced by the C cells (20, 21). On the basis of these observations and of the low risk of onset of HPT in MEN2A, at present, the operation of prophylactic parathyroidectomy does not seem indicated when surgery for MTC is performed.

The young age of the patient described in this report represents an exception, as other Authors report the absence of parathyroid pathology in patients submitted to prophylactic TT in children's or in adolescents (22, 23). The clinical and biochemical features of our patient was entirely silent, in agreement with the described lack of symptoms in MEN 2A hyperparathyroid patients (3, 4, 24). Furthermore, MEN 2A patients can exhibit normal calcium and PTH serum values even if enlarged parathyroid gland(s) were found at surgery and histologically confirmed at pathology (4).

In the natural history of HPT in MEN 2A patients, in the majority (75-80%) of subjects the diagnosis of HPT is synchronous with that of MTC or pheochromocitoma, in the remaining cases HPT arises after many years from TT (1). HPT precedes the diagnosis of MTC or pheochromocitoma in less than 5% of the cases (4). As in our patient the two enlarged parathyroids were both hyperplastic, this case can be included in the 48% of cases with diffuse hyperplasia of the parathyroids (3, 25). Conversely, the presence of only one pathologic parathyroid gland (usually referred as single adenoma) at the surgical exploration is reported in a variable percentage from 27 to 48% of MEN 2A cases (2, 4, 25, 26) and the double adenoma in about 8% (3, 25).

Concerning the surgical treatment the experience reported in literature is scarce. The preferred surgical treatment is to limit the removal to the enlarged parathyroid glands. The results of the partial parathyroidectomy showed relapses of HPT in 20.9% of the cases, (mean variable follow-up from 3.5 to 11.4 years) (Table I). However, given that in a large part of the cases (about 3/4) the treatment of HPT occurs during surgery for MTC, it is not clear how many glands are effectively removed. In fact, the TT and the frequent need for lymphadenectomy of the central section of the neck (including often the thymectomy) can cause the extirpation or the devascularization of some or all residual parathyroid glands. This is also confirmed by the fact that in these experiences a high number of permanent hypoparathyroidism (10-19%) is present (Table I). Therefore, the apparently favourable results of a partial parathyroidectomy limited to the resection of the increased in volume glands should be better evaluated and analyzed by prospective clinical studies. Finally, the experience with subtotal or total

parathyroidectomy associated to autograft is very limited, even though the accumulated data do not show major differences, suggesting a more conservative surgical approach (Table I).

References

1. Brandi ML, Gagel RF, Angeli A et al. Guidelines for diagnosis and therapy of MEN type 1 and type 2. *J Clin Endocrinol Metab.* 2001; 86:5658-71.
2. Kraimps JL, Quan-Yang Duh, Demeure M et al. Hyperparathyroidism in multiple endocrine neoplasia syndrome. *Surgery.* 1992; 112:1080-88.
3. Herfarth KKF, Bartsch D, Doherty GM et al. Surgical management of hyperparathyroidism in patients with multiple endocrine neoplasia type 2A. *Surgery.* 1996;120:966-74.
4. Raue F, Kraimps JL, Dralle H et al. Primary hyperparathyroidism in multiple endocrine neoplasia type 2A. *J Int Med.* 1995;238:369-73.
5. Gill JR, Reyes-Mugica M, Iyengar S et al. Early presentation of metastatic medullary carcinoma in multiple endocrine neoplasia, type IIA: implications for therapy. *J Pediatr.* 1996;129:459-64.
6. Skinner MA, DeBenedetti MK, Moley JF et al. Medullary thyroid carcinoma in children with multiple endocrine neoplasia types 2A and 2B. *J Pediatr Surg.* 1996;31:177-82.
7. Decker RA, Geiger JD, Cox CE et al. Prophylactic surgery for multiple endocrine neoplasia type IIA after genetic diagnosis: is parathyroid transplantation indicated? *World J Surg.* 1996;20:814-21.
8. Van Heurn ELW, Schaap C, Sie G et al. Predictive DNA testing for multiple endocrine neoplasia 2: a therapeutic challenge of prophylactic thyroidectomy in very young children. *J Pediatr Surg.* 1999; 34:568-71.
9. Nicoli-Sire P, Murat A, Baudin E et al. Early or prophylactic thyroidectomy in MEN 2/FMTC gene carriers: results in 71 thyroidectomized patients. *Eur J Endocrinol.* 1999;141:468-74.
10. Iler MA, King DR, Ginn-Pease ME et al. Multiple endocrine neoplasia type 2A: a 25-year review. *J Pediatr Surg.* 1999;34:92-97.
11. Ito S, Iwashita T, Asai N et al. Biological properties of RET with cysteine mutations correlate with multiple endocrine neoplasia type 2A, familial medullary thyroid carcinoma, and Hirschsprung's disease phenotype. *Cancer Res.* 1997;57:2870-72.
12. Machens A, Gimm O, Hinze R et al. Genotype-Phenotype correlations in hereditary medullary thyroid carcinoma: oncological features and biochemical properties. *J Clin Endocrinol Metab.* 2001; 86:1104-109.
13. Hassan M Heshmati, Hossein Gharib, Jon A Van Heerden et al. Advances and controversies in the diagnosis and management of medullary thyroid carcinoma. *Am J Med.* 1997;103:60-69.
14. Mulligan LM, Eng C, Healey CS et al. Specific mutations of the RET protooncogene are related to disease phenotype in MEN 2A

Table I - Surgical approach to HPT in MEN 2A*°.

	Parathyroidectomy		
	Partial (86)	Subtotal (49)	Total with autotransplantation (30)
Hyperparathyroidism (%)			
Persistent	5.8	8.1	3.3
Recurrent	15.1	10.2	6.6
Recurrent + Persistent	20.9	18.3	16.0
Permanent hypoparathyroidism (%)	17.4	30.0	13.6

* Data selected from Ref. 3, 4, 24, 25, 27; ° Follow-up (years): mean 7, range 3.5-11.4.

- and FMTC. *Nat Genet.* 1994;6:70-74.
15. Schuffenecker I, Billaud M, Calender A et al. RET proto-oncogene mutations in French MEN 2A and FMTC families. *Hum Mol Genet.* 1994;3:1939-43.
 16. Gabor Szinnai, Christian Meier, Paul Komminoth et al. Review of multiple endocrine neoplasia type 2A in children: therapeutic results of early thyroidectomy and prognostic value of codon analysis. *Pediatrics.* 2003;111:e132-e139.
 17. Egawa SI, Futami H, Takasaki K et al. Genotype-phenotype correlation of patients with multiple endocrine neoplasia type 2 in Japan. *Jpn J Clin Oncol.* 1998;28:590-596.
 18. Hansen HS, Torring H, Godballe C et al. Is thyroidectomy necessary in RET mutations carriers of the familial medullary thyroid carcinoma syndrome? *Cancer.* 2000;89:863-867.
 19. Lombardo F, Baudin E, Chiefari E et al. Familial medullary thyroid carcinoma: clinical variability and low aggressiveness associated with RET mutation at codon 804. *J Clin Endocrinol Metab.* 2002; 87:1674-1680.
 20. Gagel RF, Tashjian AHJ, Cummings T et al. The clinical outcome of prospective screening for multiple endocrine neoplasia type 2A: an 18-age year experience. *New Engl J Med.* 1988;318:478-484.
 21. Mallette LE. Management of hyperparathyroidism in the multiple endocrine neoplasia syndromes and other familial endocrinopathies. *Endocrinol Metab Clin North Am.* 1994;23:19-36.
 22. Wells SA, Chi DD, Toshima K et al. Predictive DNA testing and prophylactic thyroidectomy in patients at risk for multiple endocrine neoplasia type 2A. *Ann Surg.* 1994;220:237-250.
 23. Decker RA, Geiger JD, Cox CE et al. Prophylactic surgery for multiple endocrine neoplasia type IIa after genetic diagnosis: is parathyroid transplantation indicated? *World J Surg.* 1996;20: 814-821.
 24. O'Riordain DS, O'Brien T, Grant CS et al. Surgical management of primary hyperparathyroidism in multiple endocrine neoplasia types 1 and 2. *Surgery.* 1993;114:1031-1039.
 25. Kraimps JL, Denizot A, Carnaille B et al. Primary hyperparathyroidism in multiple endocrine neoplasia type IIa: retrospective french multicentric study. *World J Surg.* 1996;20:808-813.
 26. Van Heerden JA, Kent RB, Sizemore GW et al. Primary hyperparathyroidism in patients with multiple endocrine neoplasia syndromes. Surgical experience. *Arch Surg.* 1983;118:533-536.
 27. Dotzenrath C, Cupisti K, Goretzki PE et al. Long-term biochemical results after operative treatment of primary hyperparathyroidism associated with multiple endocrine neoplasia types I and IIa: is a more or less extended operation essential? *Eur J Surg.* 2001;167: 173-178.