



UNIL | Université de Lausanne

Unicentre

CH-1015 Lausanne

<http://serval.unil.ch>

Year : 2014

Use of combined suspension laryngoscopy, flexible bronchoscopy and high frequency jet ventilation for Y-shaped airway stents delivery

LOVIS Alban

LOVIS Alban, 2014, Use of combined suspension laryngoscopy, flexible bronchoscopy and high frequency jet ventilation for Y-shaped airway stents delivery

Originally published at : Thesis, University of Lausanne

Posted at the University of Lausanne Open Archive <http://serval.unil.ch>

Document URN : urn:nbn:ch:serval-BIB_21D7F24B0C8E5

Droits d'auteur

L'Université de Lausanne attire expressément l'attention des utilisateurs sur le fait que tous les documents publiés dans l'Archive SERVAL sont protégés par le droit d'auteur, conformément à la loi fédérale sur le droit d'auteur et les droits voisins (LDA). A ce titre, il est indispensable d'obtenir le consentement préalable de l'auteur et/ou de l'éditeur avant toute utilisation d'une oeuvre ou d'une partie d'une oeuvre ne relevant pas d'une utilisation à des fins personnelles au sens de la LDA (art. 19, al. 1 lettre a). A défaut, tout contrevenant s'expose aux sanctions prévues par cette loi. Nous déclinons toute responsabilité en la matière.

Copyright

The University of Lausanne expressly draws the attention of users to the fact that all documents published in the SERVAL Archive are protected by copyright in accordance with federal law on copyright and similar rights (LDA). Accordingly it is indispensable to obtain prior consent from the author and/or publisher before any use of a work or part of a work for purposes other than personal use within the meaning of LDA (art. 19, para. 1 letter a). Failure to do so will expose offenders to the sanctions laid down by this law. We accept no liability in this respect.

UNIVERSITE DE LAUSANNE- FACULTE DE BIOLOGIE ET MEDECINE

Département de Médecine Interne
Service de Pneumologie

**Use of combined suspension laryngoscopy, flexible
bronchoscopy and high frequency jet ventilation for Y-shaped
airway stents delivery**

THESE

Préparée sous la direction du Professeur Laurent Nicod

Et présentée à la Faculté de Biologie et Médecine de
l'Université de Lausanne pour l'obtention du grade de

DOCTEUR EN MEDECINE

par

Alban LOVIS

Médecin diplômé de la Confédération Suisse

Originaire de Saulcy (JU)

Lausanne

2014

UNIVERSITE DE LAUSANNE- FACULTE DE BIOLOGIE ET MEDECINE

Département de Médecine Interne
Service de Pneumologie

**Use of combined suspension laryngoscopy, flexible
bronchoscopy and high frequency jet ventilation for Y-shaped
airway stents delivery**

THESE

Préparée sous la direction du Professeur Laurent Nicod

Et présentée à la Faculté de Biologie et Médecine de
l'université de Lausanne pour l'obtention du grade de

DOCTEUR EN MEDECINE

par

Alban LOVIS

Médecin diplômé de la Confédération Suisse

Originaire de Saulcy (JU)

Lausanne

2014



UNIL | Université de Lausanne

Faculté de biologie
et de médecine

*Ecole Doctorale
Doctorat en médecine*

Imprimatur

Vu le rapport présenté par le jury d'examen, composé de

Directeur de thèse *Monsieur le Professeur Laurent Nicod*

Co-Directeur de thèse

Expert *Monsieur le Professeur Hans-Beat Ris*

*Directrice de l'Ecole
doctorale* *Madame le Professeur Stephanie Clarke*

la Commission MD de l'Ecole doctorale autorise l'impression de la thèse de

Monsieur Alban Lovis

intitulée

***Use of combined suspension laryngoscopy, flexible
bronchoscopy and high frequency jet ventilation
for Y-shaped stent delivery***

Lausanne, le 2 septembre 2014

*pour Le Doyen
de la Faculté de Biologie et de Médecine*

*Madame le Professeur Stephanie Clarke
Directrice de l'Ecole doctorale*

« Rapport de synthèse »

Résumé, enjeux et contexte de la recherche : La trachée et les bronches proximales sont de fins conduits subtils, ingénieusement structurés par une partie cartilagineuse antérieure résistante aux variations de pression et une partie membraneuse postérieure souple. Par leurs faibles volumes (espace mort) ils délivrent un grand pourcentage de l'air inspiré aux voies distales, puis au parenchyme pulmonaire, permettant les échanges de gaz.

Cette belle harmonie respiratoire peut être rapidement mise à mal dès qu'un processus atteint ces voies respiratoires proximales, soit en les comprimant, processus sténosant, soit en affaiblissant leur structure, trachéo-bronchomalacie, soit en ouvrant leur paroi sur les structures médiastinales, fistule trachéo/broncho-médiastinales, pleurales ou autres.

Le pronostic vital est alors rapidement engagé au vu de l'absolue nécessité du bon fonctionnement de ces fins conduits, une petite diminution du calibre de leurs fines lumières provoquant une baisse importante de leurs surfaces.

Dans ces situations à haut potentiel de complication majeure les interventions endoscopiques pour restaurer l'intégrité de ces conduits sont alors fort risquées, et il est primordial de pouvoir les effectuer dans un cadre sécurisé au maximum.

La réalisation de ces gestes par la technique décrite dans notre article « *Use of combined suspension laryngoscopy, flexible bronchoscopy and high frequency jet ventilation for Y-shaped airway stents delivery* » permet la sécurité nécessaire à ces situations instable, en effet

- la laryngoscopie en suspension expose les voies proximales en offrant un accès le plus large possible à l'arbre trachéobronchique ce qui permet l'insertion de multiples instruments parfois volumineux,
- la Jet ventilation assure une oxygénation et une ventilation adéquate par un fin cathéter placé soit dans le poumon sain, soit en distalité de la lésion
- la bronchoscopie souple, passant au travers d'endroits exigus et courbes permet le déploiement sous vision direct, au millimètre près, de divers dispositifs.

Cette association remplace avantageusement la technique traditionnelle qui insère les stents à l'aveugle, et en apnée, ce qui représente de haut risque de mauvais positionnement des stents avec des conséquences immédiates sur l'oxygénation et la ventilation souvent déjà bien altérées.

Perspective et conclusion : cette technique est utile pour l'insertion des stents en Y, centraux, comme décrit dans notre article, et les indications peuvent être étendues aux stents distaux pour lesquels l'accès n'est parfois pas aisé avec le bronchoscope rigide, et pour d'autres interventions endoscopiques, laser, cryothérapie, radiofréquence ou l'insertion de nouveaux dispositifs.

Use of Combined Suspension Laryngoscopy and Jet Ventilation for Y-Shaped Airway Stents Delivery

Yan Monnier, MD, PhD, Madeleine Chollet-Rivier, MD, Michel Gonzalez, MD, Laurent Nicod, MD, Christian Simon, MD, and Alban Lovis, MD

Services of Otolaryngology, Head and Neck Surgery, Anesthesiology, and Thoracic Surgery, Department of Surgery and Anesthesiology, and Service of Respiratory Medicine, Department of Medicine, Lausanne University Hospital, Lausanne, Switzerland

Airway stenting is a common endoscopic procedure that is used to treat a variety of central airway lesions. Obstructions or fistulas involving the carina or nearby tracheobronchial structures require the use of specially designed stents, commonly referred to as Y-stents. Conventional methods of endobronchial Y-stent delivery are all characterized by a blind and apneic period during the procedure that carries the risk of stent misplacement or ventilation/

oxygenation problems or both. Using combined suspension laryngoscopy, flexible bronchoscopy, and jet ventilation, we describe a technique that makes challenging bronchoscopic interventions—such as self-expandable Y-shaped airway stent delivery—easy, precise, and safe.

(Ann Thorac Surg 2014;97:2208–10)

© 2014 by The Society of Thoracic Surgeons

Airway stenting is a common endoscopic procedure used to treat a variety of central airway lesions [1]. Malignant tracheobronchial lesions requiring airway stenting to assure functional airway support occur in palliative situations as well as during external beam radiation or chemotherapy settings. Less frequent indications encompass a variety of benign conditions such as cicatricial stenosis, tracheobronchomalacia in patients not eligible for surgical repair, anastomotic strictures or dehiscences after central airway surgery, and tracheoesophageal or bronchoesophageal fistulas.

Central airway lesions involving the carina or nearby tracheobronchial structures require the use of specially designed stents, commonly referred to as Y-stents [2]. These devices are made of a tracheal portion that divides into two main stem bronchus limbs, forming an inverted Y-shape. Two types of Y-shaped airway stents are available on the market. These are the nonexpandable silicone-based prosthesis and the self-expandable fully or partially coated stents. The delivery of all these prosthesis is technically challenging. Expertise of rigid bronchoscopy or direct laryngoscopy is required for non-expandable silicone stents, and the phase of blind delivery into the tracheobronchial tree under apneic condition can be hazardous [3]. If the new self-expandable metallic Y-stents overcome some of these issues by providing a delivery system that is easier to use, the technique of stent placement still has some drawbacks. Given the wide diameter of the introducer sheath, ventilation is seriously limited during stent delivery. Furthermore, the necessity of indirect fluoroscopic

guidance significantly limits the precise positioning of the prosthesis, especially after tumor debulking procedures or for fistula coverage where the risk of stent misplacement is high with potential serious complications [2, 3].

Owing to the central location of the airway lesions requiring Y-shaped stents, these procedures are performed most often in difficult respiratory situations calling for continuous effective ventilation/oxygenation as well as easy-to-use and reliable delivery systems. Using combined suspension laryngoscopy, flexible bronchoscopy, and jet ventilation, we developed a technique that overcomes those limitations and makes self-expandable Y-shaped airway stent delivery easy, precise, and safe.

Technique

Endoscopic Procedure

We describe a four-step endoscopic procedure that was used to treat 6 consecutive patients with various central airway lesions (Fig 1). The endoscopic intervention was performed as follows: (1) Diagnostic or interventional rigid bronchoscopy is performed. Endobronchial patency is obtained by interventional endoscopic procedures. The proper stent model is chosen according to location, diameter, and length of the lesion. (2) The larynx is exposed by means of a Lindholm suspension laryngoscope (Karl Storz, Tuttlingen, Germany). A 2-mm-diameter jet catheter (Acutronic Medical System AG, Zurich, Switzerland) is inserted between the vocal cords and placed precisely under endoscopic visualization beyond the pathologic area. (3) The 8-mm-diameter stent loader of a self-expandable Nitinol Y-carina stent (Leufen Medical GmbH, Aachen, Germany) and a 3.8-mm flexible bronchoscope (Evis-EXERA II; Olympus, Zurich, Switzerland) are then introduced in parallel through the laryngoscope, next to the jet catheter, which is then

Accepted for publication Nov 11, 2013.

Address correspondence to Dr Monnier, Service of Otolaryngology, Head and Neck Surgery, University Hospital of Lausanne, Rue du Bugnon 46, Lausanne 1011, Switzerland; e-mail: yan.monnier@chuv.ch.

© 2014 by The Society of Thoracic Surgeons
Published by Elsevier Inc

0003-4975/\$36.00

<http://dx.doi.org/10.1016/j.athoracsur.2013.11.024>

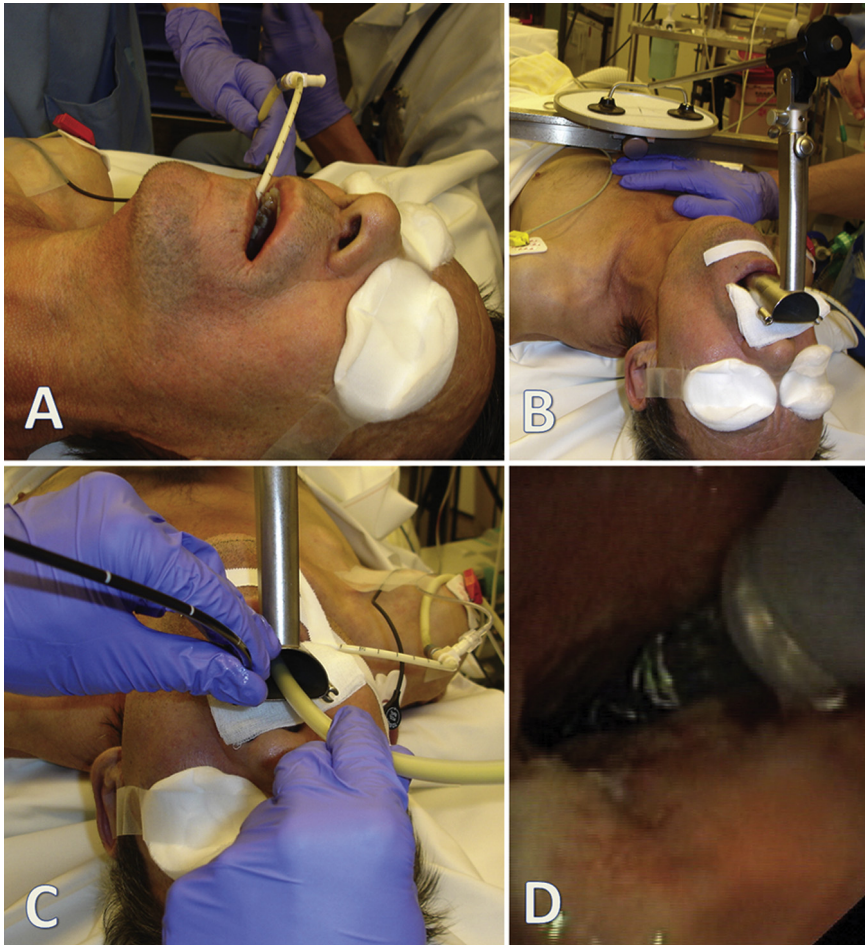


Fig 1. (A) A jet catheter is inserted between the vocal cords and placed precisely under endoscopic visualization beyond the lesion in the distal airway. (B) The larynx is exposed by the mean of a suspension laryngoscope. (C) The stent loader and a flexible bronchoscope are introduced parallel through the suspension laryngoscope next to the jet catheter that is repositioned proximal to the stent. (D) Precise delivery of the stent under direct endoscopic control and constant ventilation is undertaken.

repositioned proximal to the stent [4]. Precise delivery of the stent under direct endoscopic control and constant ventilation then takes place.

Anesthesia Protocol

Anesthesia is maintained by a total intravenous technique with propofol (0.15 to $0.2 \text{ mg} \cdot \text{kg}^{-1} \cdot \text{min}^{-1}$) and remifentanyl (0.2 to $0.3 \text{ } \mu\text{g} \cdot \text{kg}^{-1} \cdot \text{min}^{-1}$). Tracheal intubation is performed under curare (rocuronium 0.6 mg/kg), and jet ventilation initiated through the side port of the rigid bronchoscope during step 1 of the procedure and by means of the jet catheter during steps 2, 3, and 4. Automatic high-frequency jet ventilation is initiated at a frequency of 150 per min with variable driving pressure of 0.2 to 2 bars using a Monsoon Jet Ventilator (Acutronic Medical System AG) with specific monitoring consisting of transcutaneous CO_2 recording, alarm pressure cutoff, and inspection of chest movements, including expiratory drive.

Patients

Six patients with an American Society of Anesthesiologists physical status classes III or IV were treated using this technique. Two patients presented with TNM stage

IIIb non-small cell lung carcinoma involving the carina and mainstem bronchi. Three patients presented with esophageal fistula secondary to end-stage esophageal squamous cell carcinoma or mediastinal irradiation. One patient had subocclusive extrinsic tracheobronchial compression by end-stage squamous cell carcinoma of the esophagus.

Results

The four-step procedure proved to be easy to perform and allowed perfect positioning of each stent the first time, while avoiding ventilation issues. No complication related to mispositioning of the stent was encountered. Every stent provided excellent repermeabilization results as well as fistula coverage. Every patient reported immediate, substantial symptomatic relief after the procedure. Altogether, the mean duration time for stent delivery, including both suspension laryngoscopy and jet ventilation setup, was 8 minutes (SD 3). The overall duration time of the endoscopic intervention, including dilation and debulking procedures, was 111 minutes (SD 43).

For all 6 cases, the jet ventilation technique allowed working under constant endoscopic control without an

apneic period at any time during the procedure. Notably, no episode of oxygen desaturation was encountered in any case during the time of suspension laryngoscopy setup and stent delivery.

Comment

The first advantage of our technique relies on the use of suspension laryngoscopy, which allows free-hand, wide access to the entire tracheobronchial tree, offering the possibility of working with flexible instruments regardless of the quality of glottic exposure. Inability to obtain adequate glottic exposure using traditional laryngoscopes or even rigid bronchoscopes has been reported to be as high as 8%, even in experimented hands [4]. That makes the completion of the endoscopic procedures sometimes impossible. Using the commercially available GlideScope for video-guided laryngoscopy and dynamic Y-stent delivery, Yarmus and colleagues [5] recently addressed these issues. However, their technique only solves the limitation of glottic exposure and does not address the absence of visualization into the trachea and mainstem bronchi.

The second advantage of our technique relies on the constant oxygenation/ventilation of the patient using jet ventilation. The main risk of this technique is barotrauma linked to inadvertent upper airway obstruction during jet ventilation [6]. The combination of suspension laryngoscopy and constant visualization of the jet catheter assures a patent upper airway and guarantees a continuous outflow of the expired gases. Setting low cutoff pressure limits on the jet ventilator precludes the risk of upper

airway overpressure and tension pneumothorax. In case of tracheoesophageal fistula, precisely positioning the jet catheter distal to the fistula prevents the risk of gastric overinflation. Jet ventilation has proved to be safe in experienced hands [7]. Of note, we did not experience any complication using jet ventilation in our series.

Finally, given the increasing availability of flexible instrumentation for various indications in interventional bronchoscopy, we believe this technique can be advantageously extended to other endoscopic procedures.

References

1. Wahidi MM, Herth FJ, Ernst A. State of the art: interventional pulmonology. *Chest* 2007;131:261–74.
2. Ranu H, Madden BP. Endobronchial stenting in the management of large airway pathology. *Postgrad Med J* 2009;85:682–7.
3. Zakaluzny SA, Lane JD, Mair EA. Complications of tracheobronchial airway stents. *Otolaryngol Head Neck Surg* 2003;128:478–88.
4. Burkle CM, Walsh MT, Harrison BA, Curry TB, Rose SH. Airway management after failure to intubate by direct laryngoscopy: outcomes in a large teaching hospital. *Can J Anaesth* 2005;52:634–40.
5. Yarmus L, Gilbert C, Akulian J, Feller-Kopman D. Novel use of the GlideScope for rigid bronchoscopic placement of a dynamic (Y) stent. *Ann Thorac Surg* 2012;94:308–10.
6. Bourgain JL, Desruennes E, Fischler M, Ravussin P. Transtracheal high frequency jet ventilation for endoscopic airway surgery: a multicenter study. *J Anaesth* 2001;87:870–5.
7. Jaquet Y, Monnier P, VanMelle G, Ravussin P, Spahn DR, Chollet-Rivier M. Complications of different ventilation strategies in endoscopic laryngeal surgery: a 10-year review. *Anesthesiology* 2006;104:52–9.