

REFERENCES

1. Niewold TB, Harrison MJ, Paget SA. Anti-CCP antibody testing, as a diagnostic and prognostic tool in rheumatoid arthritis. *Q J Med* 2007; **100**:193–201.
2. Avouac J, Gossec L, Dougados M. Diagnostic and predictive value of anti-cyclic citrullinated protein antibodies in rheumatoid arthritis: a systematic review. *Ann Rheum Dis* 2006; **65**:845–51.
3. Sathi N, Whitehead E, Grennan DM. Can a rheumatologist accurately prioritize patients on the basis of information in the general practitioners referral letter? *Rheumatology* 2003; **42**:1270–1.

doi:10.1093/qjmed/hcm091

A basal variant form of the transient 'midventricular' and 'apical' ballooning syndrome

Sir,

A 30-year-old Caucasian woman was admitted for a scheduled caesarean delivery at 36 weeks of gestation after an uncomplicated pregnancy. She gave birth to a healthy baby under epidural anaesthesia. One hour post-operatively, she experienced acute substernal chest pain. There was no cardiac history or risk factors for atherosclerosis, and the patient was treated for anxiety disorders. Her blood pressure was 110/65 mmHg, and her heart rate was 80 bpm. Physical examination was unremarkable. The electrocardiogram revealed significant ST segment depression in leads V4 through V6, II and aVF. Serial cardiac enzymes revealed a moderate increase in cardiac troponin I (peak value 1.1 µg/l) and in creatine phosphokinase (peak value 219 U/l). The epicardial coronary arteries were angiographically normal. The left ventriculogram showed basal akinesis with hypercontractile midventricular segments and apex (Figure 1). The patient was managed with conservative medical therapy. A transthoracic echocardiogram obtained 4 weeks later showed complete recovery of the basal wall motion abnormalities (ejection fraction 65%) with minimal mitral regurgitation. The patient did not experience any subsequent cardiac events after >10 months of follow-up.

Apical ballooning syndrome (ABS), or *takotsubo* cardiomyopathy, is a well-described entity characterized by a typical transient contractile abnormality consisting of extensive apical and midventricular akinesis or dyskinesis with sparing of the basal systolic function. Patients with ABS typically do not have obstructive coronary artery

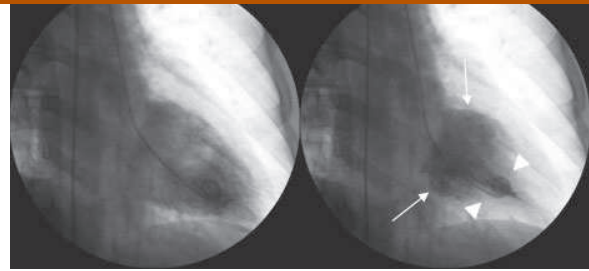


Figure 1. Left ventriculography in right anterior oblique view at end-diastolic phase (left) and end-systolic phase (right), showing apical and midventricular segment hypercontractility (arrowheads) and basal segment akinesis (arrows).

disease, and a unique feature is the occurrence of a preceding physical or mental stress.¹ Although wall motion abnormalities (WMA) were originally thought to invariably involve the ventricular apex, variants have also been recently described with akinesis and ballooning of the midventricular segments and hypercontractile apex and base.²

In this case, the presentation and trigger of the episode, the clinical features and the transient nature of the WMA are similar to the ABS, suggesting a common pathophysiological aetiology. This variant has however a unique feature that distinguishes it from the known variant of the 'classical' ABS, in that the apex and most of the midventricle were hypercontractile, whereas the base was akinetic.

The report of a variant form affecting the basal ventricular segments with sparing of more apical portions has implications in the appraisal of the proposed pathophysiological mechanisms underlying ABS. For instance, the distribution of the WMA in the present case would clearly argue against the hypothesis of a transient obstruction to left ventricular flow or a multivessel epicardial spasm, as proposed by some authors.^{3,4} The localization of the contractile abnormalities may have to be modified accordingly in future diagnostic criteria of the 'apical' ballooning syndrome.⁵

O. Muller
C. Roguelov
P. Pascale

Cardiology Service
Centre Hospitalier Universitaire, Vaudois
Lausanne
Switzerland
email: olivier.muller@chuv.ch

References

1. Akashi YJ, Nakazawa K, Sakakibara M, Miyake F, Koike H, Sasaka K. The clinical features of takotsubo cardiomyopathy. *Q J Med* 2003; **96**:563–73.
2. Hurst RT, Askew JW, Reuss CS, Lee RW, Sweeney JP, Fortuin FD, OH JK, Tajik AJ. Transient Midventricular Ballooning Syndrome. A new variant. *J Am Coll Cardiol* 2006; **48**:579–83.
3. Merli E, Sutcliffe S, Gori M, Sutherland GGR. Tako-Tsubo cardiomyopathy: new insights into the possible underlying pathophysiology. *Eur J Echocardiography* 2006; **7**:53–61.
4. Kurisu S, Sato H, Kawagoe T, Ishihara M, Shimatani Y, Nishioka K, Kono Y, Umemura T, Nakamura S. Tako-tsubo-like left ventricular dysfunction with ST-elevation: a novel cardiac syndrome mimicking acute myocardial infarction. *Am Heart J* 2002; **143**:448–55.
5. Prasad A. Apical Ballooning Syndrome: an important differential diagnosis of acute myocardial infarction. *Circulation* 2007; **115**:56–9.

doi:10.1093/qjmed/hcm092