



Harris, K. P., & Langley-Hobbs, S. J. (2013). Idiopathic ischemic necrosis of an accessory carpal bone in a dog. *Journal of the American Veterinary Medical Association*, 243(12), 1746-1750. 10.2460/javma.243.12.1746

Publisher's PDF, also known as Final Published Version

Link to published version (if available):  
[10.2460/javma.243.12.1746](https://doi.org/10.2460/javma.243.12.1746)

[Link to publication record in Explore Bristol Research](#)  
PDF-document

## University of Bristol - Explore Bristol Research

### General rights

This document is made available in accordance with publisher policies. Please cite only the published version using the reference above. Full terms of use are available:  
<http://www.bristol.ac.uk/pure/about/ebr-terms.html>

### Take down policy

Explore Bristol Research is a digital archive and the intention is that deposited content should not be removed. However, if you believe that this version of the work breaches copyright law please contact [open-access@bristol.ac.uk](mailto:open-access@bristol.ac.uk) and include the following information in your message:

- Your contact details
- Bibliographic details for the item, including a URL
- An outline of the nature of the complaint

On receipt of your message the Open Access Team will immediately investigate your claim, make an initial judgement of the validity of the claim and, where appropriate, withdraw the item in question from public view.

# Idiopathic ischemic necrosis of an accessory carpal bone in a dog

Karen P. Harris, BVetMed, and Sorrel J. Langley-Hobbs, BVetMed, MA

**Case Description**—A 6-year-old neutered female mixed-breed dog was evaluated because of a 6-week history of left forelimb lameness that varied in severity.

**Clinical Findings**—Radiography revealed expansile and lytic changes of the left accessory carpal bone (ACB). Results of histologic evaluation of ACB core biopsy specimens indicated areas of bone necrosis. The entire left ACB was excised and submitted for histologic evaluation; results confirmed a diagnosis of idiopathic ischemic necrosis.

**Treatment and Outcome**—Left pancarpal arthrodesis was performed to treat carpal hyperextension and persistent lameness. The dog had an excellent functional outcome with no other problems related to the carpus until its death 4 years later, further decreasing suspicion that the problem was attributable to an undetected neoplasm or bacterial or fungal osteomyelitis.

**Clinical Relevance**—The radiographic and histologic findings for the dog of this report were similar to previously reported findings for dogs with ischemic femoral head necrosis and humans with ischemic carpal (pisiform or lunate bone) necrosis. The etiology of the ischemic ACB necrosis in this dog was not determined. To the authors' knowledge, this is the first report of a dog with idiopathic ischemic ACB necrosis. Idiopathic ischemic necrosis should be included as a differential diagnosis for dogs with lameness and destructive and expansile ACB radiographic lesions. An excellent functional outcome may be attained by means of ACB excision and pancarpal arthrodesis. (*J Am Vet Med Assoc* 2013;243:1746–1750)

A 6-year-old 24-kg (53-lb) neutered female mixed-breed dog was brought to the referring veterinarian with a 1-week history of left forelimb lameness. The dog had no history of trauma preceding the onset of lameness. During physical examination, the dog seemed to resent flexion of the left carpus, but full range of motion of the carpus was detected. The dog was treated with carprofen (2 mg/kg [0.9 mg/lb], PO, q 12 h), and exercise was restricted to walks on a leash; improvement in the lameness was initially reported. During physical examination 2 weeks later, the veterinarian detected reduced range of motion of the left carpus in the dog. Clindamycin (9 mg/kg [4.1 mg/lb], PO, q 12 h) and prednisolone-cinchophen<sup>a</sup> (0.06 mg of prednisolone/kg [0.027 mg/lb] and 12.5 mg of cinchophen/kg [5.7 mg/lb], PO, q 12 h) were prescribed; no further improvement in lameness was reported. Approximately 6 weeks after the onset of the problem, the dog was referred to The Queen's Veterinary School Hospital of the University of Cambridge for further evaluation. Gait evaluation indicated moderate left forelimb lameness. Reduced range of motion of the left carpus was confirmed, and the dog seemed to resent flexion of the carpus. The left ACB was palpably larger than the right ACB. In addition, mild crepitus was palpable during manipulation of the right elbow joint, and mild signs of discomfort were elicited during extension of the right hip joint. All other physical examination findings were unremarkable.

From the Department of Veterinary Medicine, Cambridge Veterinary School, University of Cambridge, Cambridge, CB3 0ES, England. The authors thank Fernando Constantino Casas and Jesse Lee for assistance with interpretation of results of histologic evaluation of tissue samples.

Address correspondence to Ms. Harris (kh503@cam.ac.uk).

## ABBREVIATIONS

ACB	Accessory carpal bone
PCA	Pancarpal arthrodesis

Radiography of the left carpus revealed monostotic expansile changes of the ACB with periosteal new bone formation (Figure 1). The ACB did not have typical corticomedullary differentiation and had a mixed appearance: a moth-eaten appearance indicating osteolysis and an amorphous periosteal reaction with cortical thinning and possible disruption of the cortex of the distal aspect of the bone. Mild soft tissue swelling was observed adjacent to the carpus. The primary differential diagnoses were neoplasia and bacterial or fungal osteomyelitis. A soft tissue neoplasm invading the ACB was considered less likely because of the lack of a prominent soft tissue component and the appearance of the ACB lesion. Radiographic findings for the thorax and contralateral carpus were unremarkable. Results of serum biochemical and hematologic analyses were unremarkable.

Arthrocentesis of the left antebrachioacarpal joint yielded a very small volume of synovial fluid for cytologic evaluation. The dog was anesthetized, a palmarolateral surgical approach<sup>1</sup> was made to access the ACB, and a bone biopsy needle was used to obtain biopsy specimens of the ACB for bacteriologic and yeast cultures and histologic examination. The dog was discharged from the hospital 24 hours after the procedure; clavulanate-potentiated amoxicillin (15 mg/kg [6.8 mg/lb], PO, q 12 h) was prescribed, and treatment with carprofen was continued.

Results of bacteriologic and yeast cultures of the ACB biopsy specimens were negative. Cytologic

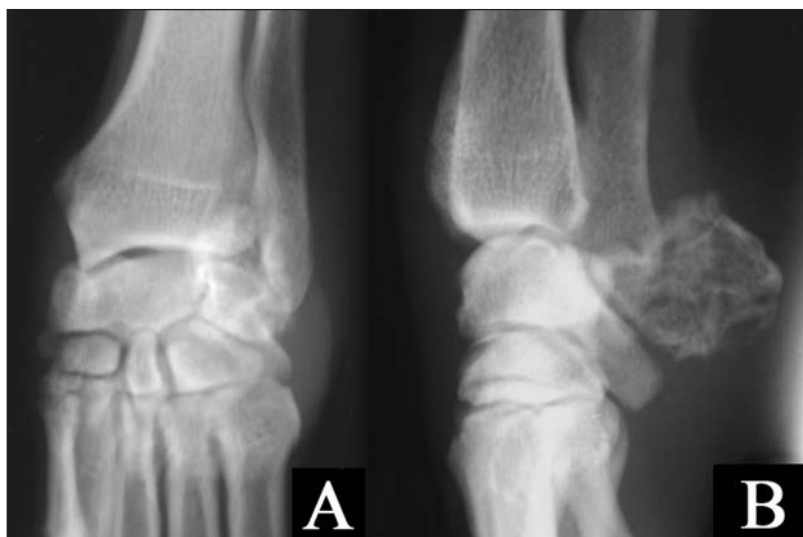

Figure 1—Dorsopalmar (A) and mediolateral (B) radiographic views of the left carpus of a 6-year-old mixed-breed dog with a 6-week history of left forelimb lameness. Notice the monostotic destructive and expansile changes in the left ACB with periosteal new bone formation.

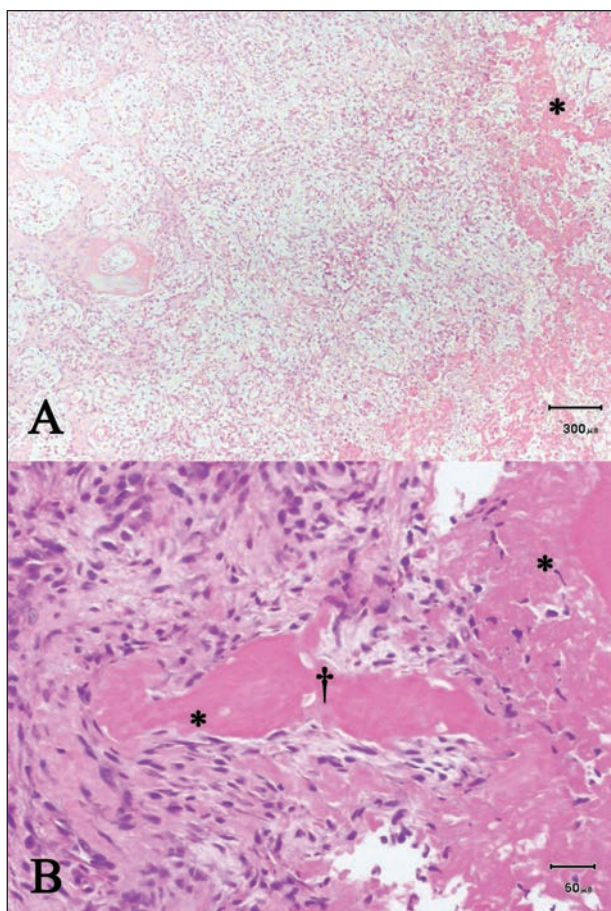


Figure 2—Representative photomicrographs of histologic sections of the left ACB of the dog in Figure 1. In panel A, notice the eosinophilic necrotic bone (asterisk) and granulation tissue formation with blood vessels. In panel B, notice the foci of eosinophilic-staining necrotic bone (asterisks) with empty osteocytic lacunae or lacunae containing eosinophilic-staining necrotic nuclei (dagger) surrounded by moderately dense granulation tissue. H&E stain; bar = 300  $\mu$ m (A) and 50  $\mu$ m (B).

evaluation of the synovial fluid sample revealed synovial lining cells and other atypical cells that were stellate shaped to spindle shaped and variable in size. These cells were thought to be highly reactive synovial lining cells. Histologic examination of bone biopsy specimens stained with H&E revealed foci of bone necrosis characterized by empty osteocytic lacunae or lacunae containing eosinophilic-staining necrotic nuclei, amorphous eosinophilic bone matrix, and multiple spicules of bone undergoing osteoclastic resorption. Moderate to large numbers of collagen fibers and large fibroblasts were identified; these findings were interpreted as reactive changes. Few mononuclear inflammatory cells were identified, and no evidence of osteomyelitis was detected.

Because of the marked changes detected in the ACB specimens suggestive of widespread bone necrosis and the continued left forelimb lameness, the dog was anesthetized and the entire ACB was excised and submitted for histologic analysis. Carpal arthrodesis was not performed at that time because of the suspicion of neoplasia. Had such a diagnosis been confirmed, an alternative treatment such as radiotherapy or amputation may have instead been indicated. Grossly, the ACB appeared intact with an irregular surface, discolored cortex, and a deep fissure on 1 side. The dog was discharged 24 hours after surgery with the left forelimb in a splinted bandage; administration of carprofen was continued.

Results of histologic examination of the entire decalcified ACB revealed multifocal areas of coagulative bone necrosis that appeared to be along the line of the fissure and surrounded by granulation tissue (Figure 2) and medullary and periosteal new bone formation. No evidence of neoplasia was found in the multiple bone sections examined. On the basis of the histologic and radiographic findings, a diagnosis of idiopathic ischemic necrosis of the ACB was made.

Three weeks later, the dog was brought to the hospital for reevaluation. A palmigrade stance and marked carpal hyperextension were found. The range of motion of the carpus remained reduced; however, manipulation of the carpus was no longer resented by the dog. Left PCA surgery was performed to treat the abnormal left forelimb stance and gait. The dog was anesthetized, and PCA was performed by means of application of a hybrid 2.7- and 3.5-mm 8-hole dynamic compression plate<sup>b</sup> as previously described<sup>2</sup> (Figure 3). An autogenous cancellous bone graft was harvested from the greater tubercle of the left humerus and placed between the carpal bones prior to closure. Twenty-four hours after surgery, a bivalved fiberglass cast was placed on the limb from a level proximal to the elbow joint to the distal aspect of the phalanges. The dog was discharged 48 hours later; clavulanate-potentiated amoxicillin and carprofen were prescribed, and instructions included strict exercise restriction and

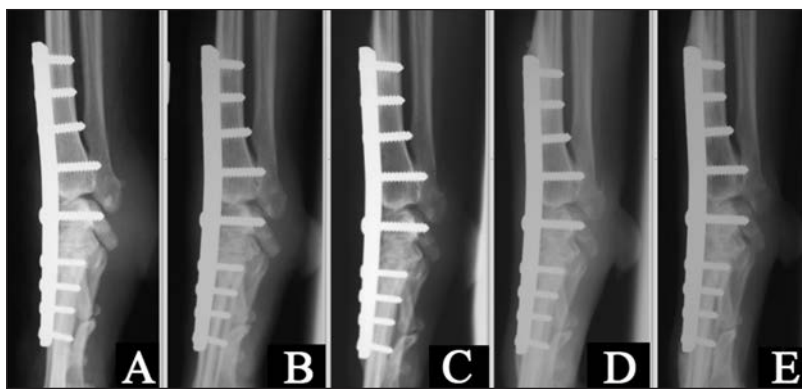

Figure 3—Mediolateral radiographic views of the left carpus of the dog in Figure 1 acquired immediately after (A) and 5 (B), 9 (C), 14 (D), and 30 (E) weeks after left PCA surgery following ACB excision.

weekly examination of the cast and reapplication of cast padding by the referring veterinarian.

The dog was reexamined and radiography of its left carpus was repeated 3, 5, 9, 14, and 30 weeks after PCA was performed. The cast was removed 5 weeks after PCA, and the left forelimb was bandaged for a further 4 weeks. Results of gait evaluation performed 9 weeks after PCA revealed full weight bearing on the left forelimb with a mildly uneven forelimb gait attributed to mechanical lameness. The dog had a mildly palmigrade stance of the left forelimb at that time. Exercise was slowly reintroduced, and supervised off-leash activity was permitted starting 14 weeks after PCA. Thirty weeks after PCA, the owner reported that the dog had resumed normal types and amounts of activity including chasing a ball, with no signs of discomfort or lameness. Implant migration and loss of bone alignment were not detected in radiographic images of the left carpus of the dog at any time. Arthrodesis of the left carpus progressed satisfactorily, although fusion at the antebrachiocarpal joint was slower than that for the other carpal joints; 30 weeks after PCA, fusion of the antebrachiocarpal joint remained limited to the cranial aspect (Figure 3). Smooth remodelled new bone was present at the proximal, distal, and medial aspects of the plate. The owners were contacted 10 years after treatment; they reported that the dog had been euthanized because of hind limb lameness of undiagnosed etiology 4 years after the PCA surgery. They reported that the dog had seemed to be comfortable during use of the left forelimb for the duration of its life, and no further problems attributable to either carpus had been detected.

## Discussion

To the authors' knowledge, this is the first report of a dog with idiopathic ischemic ACB necrosis. Disorders of the ACB in dogs primarily include fractures, subluxation, luxation,<sup>3,4</sup> and, rarely, neoplasia.<sup>5</sup> Even highly comminuted type V extra-articular ACB fractures in dogs managed with external coaptation have good healing,<sup>3</sup> suggesting that the ACB has a good blood supply and is not predisposed to development of nonunion or ischemic necrosis. In dogs, ischemic bone necrosis is most frequently identified in the femoral head (Legg-Calvé-Perthes disease); however, it has also been reported in the humeral head,<sup>6</sup>

radial carpal bone,<sup>7</sup> and second carpal bone<sup>8</sup> (although not all diagnoses in those reports were confirmed by means of histologic examination of tissues specimens). Although the term avascular necrosis is widely used (as is the term aseptic necrosis), the authors consider the term ischemic necrosis a more accurate description of this disease process.

Prior to diagnosis and treatment at our facility, the dog of the present report had received various drugs for treatment of lameness. One of the medications<sup>a</sup> is not commercially available or approved for use in dogs in the United States.

The primary radiographic differential diagnosis for the ACB lesion in the dog of this report was neoplasia. One dog with ACB neoplasia (a giant cell tumor with secondary osteomyelitis) of another report<sup>5</sup> had several radiographic findings that were similar to those for the dog of the present report. These findings included a lytic and expansile lesion of the ACB with cortical thinning and soft tissue swelling but no involvement of adjacent bones. However, although giant cell tumors reportedly induce little or no periosteal reaction,<sup>5</sup> the dog of this report had marked periosteal new bone formation. In addition, abundant neoplastic cells were identified that were replacing bony trabeculae for the dog with a giant cell tumor,<sup>5</sup> whereas no neoplastic cells were identified in the ACB of the dog of the present report. One other report<sup>9</sup> of a dog with ACB neoplasia (a myxoma arising from the radiocarpal joint) has been published; the tumor in that dog induced mild periosteal reaction and indentation of the ventral aspect of the ACB, but no other bony changes such as lysis or cortical expansion were detected. Although the sensitivity of histologic evaluation for ruling out neoplasia should not be considered 100%, it remains the gold standard technique, particularly when the whole bone can be submitted for evaluation.

Another radiographic differential diagnosis for the ACB lesion was bacterial or fungal osteomyelitis. This condition can cause radiographic findings of cortical lysis, irregular periosteal reaction, increased medullary density, and soft tissue swelling<sup>10</sup> and has been reported affecting the carpus in a dog<sup>11</sup> and the ACB in a horse.<sup>12</sup> Although a definitive diagnosis is determined by means of bacteriologic or fungal culture,<sup>13</sup> the diagnosis cannot be ruled out on the basis of a single negative culture result for a bone biopsy specimen because organisms may fail to grow for various reasons such as exposure to air during sample handling (for anaerobic organisms<sup>14</sup>) or preoperative treatment with antimicrobials. In agreement with the negative results of microbial culture of the bone biopsy specimen of the dog of the present report, results of histologic examination of such tissue samples indicated no evidence of osteomyelitis (eg, an absence of neutrophil or plasma cell infiltration, which is typical for osteomyelitis<sup>15</sup>). Given the absence of a carpal wound or previous surgery, if the dog had bacterial or fungal osteomyelitis, then a hematogenous source of the organisms would be most likely. The dog

had no characteristics consistent with a hematogenous osteomyelitis such as pyrexia, lethargy, young age, localization to a metaphyseal location, discharge from sinus tracts, or polyostotic disease.<sup>13,14</sup> For these reasons, osteomyelitis was ruled out as a diagnosis.

Other nonneoplastic differential diagnoses for the ACB lesion included simple bone cysts, aneurysmal bone cysts, or fibrous dysplasia. The radiologic and histologic findings for the dog of the present report were considered to be dissimilar from those described<sup>16,17</sup> in reports of canine or non-canine accessory carpal cases of such conditions.

The histologic diagnosis of idiopathic ischemic necrosis was made after multiple sections of the entire ACB had been examined. The histologic hallmark of bone necrosis is cell death and loss of osteocytes from lacunae,<sup>18</sup> which were detected for the dog of this report. The fissure that was grossly visible on the ACB was suspected to be an incomplete fracture that occurred as a result of primary osteonecrosis, although the possibility that the fracture preceded and induced the ischemic necrosis cannot be completely ruled out. Regardless of whether the fracture was primary or secondary to the ischemic necrosis, the radiographic and histologic findings were not consistent with physiologically normal bone healing associated with a simple fracture.

Unfortunately, the 2 published reports<sup>7,8</sup> of carpal ischemic necrosis in dogs contain insufficient detail to allow comparison with the radiographic and histologic findings for the dog of the present report. Of the 2 humans with pisiform (the human ACB equivalent) ischemic necrosis for which reports have been published in the English language, 1 had concomitant problems of a ganglion cyst and pisotriquetral joint arthritis<sup>19</sup>; therefore, it is uncertain whether the radiographic abnormalities for the pisiform bone of that person (subchondral sclerosis, bone fragmentation, and pisotriquetral joint effusion) were solely attributable to ischemic necrosis. The other report<sup>20</sup> of pisiform ischemic necrosis in a human indicated an enlarged pisiform bone with no irregularities of the joint, similar to findings for the dog of the present report. Grossly, the pisiform bone in the person of that other report<sup>20</sup> was firm and discolored, and results of histologic evaluation indicated fibroblastic tissue proliferation associated with sclerotic thickening of adjacent bone trabeculae.

Ischemic necrosis of the femoral head in dogs is radiographically characterized by detection of patchy demineralization causing a moth-eaten appearance, loss of cortical bone, and collapse of the femoral head.<sup>8,21</sup> This irregular radiopacity is attributable to microfracture of necrotic trabeculae, which leads to both subchondral cavity formation and regions of impacted fragmented trabeculae. As the disease progresses, increasing volumes of granulation tissue are histologically identified, particularly at the junction of necrotic and live bone, with evidence of active revascularization and new bone formation.<sup>22</sup> Similarly, the ACB in the dog of the present report had a moth-eaten radiographic appearance with cortical thinning. Also, histologic findings for the ACB in the dog included necrotic bone, fibroblastic tissue proliferation, and granulation tissue. The finding of granulation tissue was consistent with

ischemic necrosis of a long duration; at least 7 weeks had elapsed between the onset of clinical signs and ACB excision for this dog.

Limited information is available regarding the etiology of the carpal ischemic necrosis in the 2 dogs of other reports.<sup>7,8</sup> One of these dogs had severe soft tissue injuries, bone exposure, and infection at the distal aspect of the antebrachium and carpus after it was caught in a trap. Although radial carpal ischemic necrosis and a fracture of the distal aspect of the ulna were not visible in the initial radiographic images acquired after injury of that dog, those findings were detected in radiographic images acquired 4 weeks later.<sup>7</sup> The other dog was 12 years old and had been receiving corticosteroids for 2 years.<sup>8</sup>

The term Kienböck's disease refers specifically to ischemic necrosis of the lunate bone of the carpus in humans. Although the etiology of Kienböck's disease is not known, results of a report<sup>23</sup> published in 1928 indicated that 78% of humans in that study with Kienböck's disease had ulnar minus variance (abnormally short ulna relative to the length of the radius), whereas only 23% of people in the general population had that finding. The author of that study postulated that compression of the lunate bone by the radius would predispose people with that finding to ischemic necrosis. Other authors<sup>24</sup> have proposed that the small carpal bones in humans have limited arterial blood supply and venous blood outflow because a large portion of the surface of such bones is covered by articular cartilage, making them susceptible to ischemia during changes in blood circulation. Results of a study<sup>25</sup> of vascular distribution in humans indicate how transverse compression fractures across the proximal aspect of the lunate bone can deprive the proximal aspect of that bone of a blood supply. Conversely, the highly anastomosing vascular anatomy of the human pisiform bone does not indicate an explanation for why ischemic necrosis also occurs in this bone.<sup>19,20,26</sup> To the authors' knowledge, studies of the vascular anatomy of canine carpal bones have not been conducted.

It was only possible to speculate regarding the etiology of ACB ischemic necrosis in the dog of this report. Ischemic necrosis can result from short- or long-term corticosteroid administration, chemotherapy protocols including corticosteroids, or combination chemotherapy protocols without corticosteroids.<sup>8,27</sup> Fat emboli (possibly as a result of altered lipid metabolism) and bone infarction (often associated with trauma) have also been associated with ischemic necrosis.<sup>8</sup> Soft tissue avulsion or infection may have induced radial carpal bone ischemic necrosis in a dog of another study.<sup>7</sup> In humans with Kienböck's disease, compression fractures of the lunate bone might cause ischemic necrosis. For Legg-Calvé-Perthes disease, multiple factors including anatomic conformation, high intracapsular hip joint pressure, infarction of the femoral head, and hormone and genetic factors have been proposed as causes.<sup>21</sup> For the dog of the present report, corticosteroids were prescribed only after the onset of clinical signs. Corticosteroids may have exacerbated ischemic necrosis in the dog; however, the dose that was administered was low, and such drugs may not have the same association with osteonecrosis in domestic animals as they do for

that problem in humans.<sup>18</sup> It was possible that the dog may have had blunt carpal trauma that induced bone infarction or incomplete compression fracture followed by development of ischemic necrosis; however, such trauma was not observed by the owner.

As has been performed for humans, evaluation of the perfusion of carpal bones of healthy dogs is warranted to determine characteristics of the vascular anatomy of the ACB. Results of such a study would be useful for interpretation of findings of imaging modalities such as MRI for dogs with problems similar to that of the dog of the present report. Because such problems are rare, it may be difficult to determine the etiology or risk factors for idiopathic carpal ischemic necrosis in dogs.

- a. PLT Tablets, Novartis Animal Health UK Ltd, Camberley, Surrey, England.
- b. Hybrid 2.7- and 3.5-mm 8-hole dynamic compression plate, Veterinary Instrumentation, Sheffield, South Yorkshire, England.

## References

1. Piermattei DL, Johnson KA. The forelimb. In: *An atlas of surgical approaches to the bones and joints of the dog and cat*. 4th ed. Philadelphia: Saunders Elsevier, 2004;149–275.
2. Li A, Gibson N, Carmichael S, et al. Thirteen pancarpal arthrodeses using 2.7/3.5mm hybrid dynamic compression plates. *Vet Comp Orthop Traumatol* 1999;12:102–107.
3. Piermattei DL, Flo GL, DeCamp CE. Fractures and other orthopedic conditions of the carpus, metacarpus and phalanges. In: *Brinker, Piermattei and Flo's handbook of small animal orthopedics and fracture repair*. 4th ed. St Louis: Saunders Elsevier, 2006;382–428.
4. Guilliard MJ. Accessory carpal bone displacement in two dogs. *J Small Anim Pract* 2001;42:603–606.
5. Berg J, Gliatto JM, Wallace MK. Giant cell tumor of the accessory carpal bone in a dog. *J Am Vet Med Assoc* 1990;197:883–885.
6. Brunnberg L, Waibl H, Nagel ML. Aseptic bone necrosis of the humeral head in the dog [in German]. *Berl Munch Tierarztl Wochenschr* 1978;91:418–423.
7. Diaz-Bertrana C, Darnaculleta F, Durall I, et al. The stepped hybrid plate for carpal panarthrodesis—part II: a multi-centre study of 52 arthrodeses (Erratum published in *Vet Comp Orthop Traumatol* 2009;22:516). *Vet Comp Orthop Traumatol* 2009;22:389–397.
8. Morgan JP. Radiographic diagnosis of bone disease. In: *Radiology of veterinary orthopedics: features of diagnosis*. 2nd ed. Napa, Calif: Venture Press, 1999;37–168.
9. Griffon DJ, Wallace LJ, Barnes DM, et al. Myxoma arising from the radiocarpal joint capsule in a dog. *J Am Anim Hosp Assoc* 1994;30:257–260.
10. Braden TD. Posttraumatic osteomyelitis. *Vet Clin North Am Small Anim Pract* 1991;21:781–811.
11. Brearley MJ, Jeffery N. Cryptococcal osteomyelitis in a dog. *J Small Anim Pract* 1992;33:601–604.
12. Witte S, Rodgerson DH. What is your diagnosis? Swelling of the soft tissue around the carpal joint. Osteomyelitis of the accessory carpal bone. *J Am Vet Med Assoc* 2005;227:551–552.
13. Johnson KA. Osteomyelitis in dogs and cats. *J Am Vet Med Assoc* 1994;204:1882–1887.
14. Rabillard M, Souchu L, Niebauer GW, et al. Haematogenous osteomyelitis: clinical presentation and outcome in three dogs. *Vet Comp Orthop Traumatol* 2011;24:146–150.
15. Thompson K. Bones and joints. In: Maxie GM, ed. *Jubb, Kennedy and Palmer's pathology of domestic animals*. 5th ed. Philadelphia: Elsevier, 2007;1–184.
16. Jones NY, Patterson-Kane JC. Fibrous dysplasia in the accessory carpal bone of a horse. *Equine Vet J* 2004;36:93–95.
17. Dernel WS, Ehrhart NP, Straw RC, et al. Tumors of the skeletal system. In: Withrow SJ, Vail DM, eds. *Withrow and MacEwen's small animal clinical oncology*. 4th ed. St Louis: Saunders Elsevier, 2007;540–582.
18. Weisbrode SE. Bones and joints. In: McGavin MD, Zachary JF, eds. *Pathologic basis of veterinary disease*. 4th ed. St Louis: Mosby Elsevier, 2007;1041–1106.
19. Garcia LA, Vaca JB. Avascular necrosis of the pisiform. *J Hand Surg Br* 2006;31:453–454.
20. Match RM. Nonspecific avascular necrosis of the pisiform bone: a case report. *J Hand Surg Am* 1980;5:341–342.
21. Towle HA, Breur GJ. Miscellaneous orthopedic conditions. In: Tobias KM, Johnston SA, eds. *Veterinary surgery small animal*. St Louis: Saunders Elsevier, 2012;1112–1126.
22. Lee R. A study of the radiographic and histological changes occurring in Legg-Calve-Perthes Disease (LCP) in the dog. *J Small Anim Pract* 1970;11:621–638.
23. Hultén O. Über anatomische Variationen der Handgelenkknochen. *Acta Radiol* 1928;9:155–168.
24. Imhof H, Breitenseher M, Trattnig S, et al. Imaging of avascular necrosis of bone. *Eur Radiol* 1997;7:180–186.
25. Lee MLH. The intraosseous arterial pattern of the carpal lunate bone and its relation to avascular necrosis. *Acta Orthop Scand* 1963;33:43–55.
26. Mestdagh H, Houcke M, Mairesse JL, et al. Vascular anatomy of the pisiformis bone. *Ann Chir Main* 1984;3:145–148.
27. Harper PG, Trask C, Souhami RL. Avascular necrosis of bone caused by combination chemotherapy without corticosteroids. *Br Med J (Clin Res Ed)* 1984;288:267–268.