

The comprehensiveness of the ESHRE/ESGE classification of female genital tract congenital anomalies: a systematic review of cases not classified by the AFS system

A. Di Spiezio Sardo¹, R. Campo¹, S. Gordts¹, M. Spinelli², C. Cosimato³, V. Tanos¹, S. Brucker¹, T. C. Li¹, M. Gergolet¹, C. De Angelis¹, L. Gianaroli¹, and G. Grimbizis^{1,*}

¹Congenital Uterine Malformations (CONUTA) Common ESHRE/ESGE Working Group, ESGE Central Office, Diestsevest 43/0001, 3000 Leuven, Belgium ²Department of Obstetrics and Gynecology, University of Naples 'Federico II', Naples, Italy ³Department of Obstetrics and Gynecology, University of Salerno, Fisciano (SA), Italy

*Correspondence address. 1st Department of Obstetrics & Gynecology, Aristotle University of Thessaloniki, Tsimiski 51 Street, 54623 Thessaloniki, Greece. E-mail: grigoris.grimbizis@gmail.com, grimbi@med.auth.gr

Submitted on August 3, 2014; resubmitted on January 30, 2015; accepted on February 11, 2015

STUDY QUESTION: How comprehensive is the recently published European Society of Human Reproduction and Embryology (ESHRE)/European Society for Gynaecological Endoscopy (ESGE) classification system of female genital anomalies?

SUMMARY ANSWER: The ESHRE/ESGE classification provides a comprehensive description and categorization of almost all of the currently known anomalies that could not be classified properly with the American Fertility Society (AFS) system.

WHAT IS KNOWN ALREADY: Until now, the more accepted classification system, namely that of the AFS, is associated with serious limitations in effective categorization of female genital anomalies. Many cases published in the literature could not be properly classified using the AFS system, yet a clear and accurate classification is a prerequisite for treatment.

STUDY DESIGN, SIZE AND DURATION: The CONUTA (CONgenital UTerine Anomalies) ESHRE/ESGE group conducted a systematic review of the literature to examine if those types of anomalies that could not be properly classified with the AFS system could be effectively classified with the use of the new ESHRE/ESGE system. An electronic literature search through Medline, Embase and Cochrane library was carried out from January 1988 to January 2014. Three participants independently screened, selected articles of potential interest and finally extracted data from all the included studies. Any disagreement was discussed and resolved after consultation with a fourth reviewer and the results were assessed independently and approved by all members of the CONUTA group.

PARTICIPANTS/MATERIALS, SETTING, METHODS: Among the 143 articles assessed in detail, 120 were finally selected reporting 140 cases that could not properly fit into a specific class of the AFS system. Those 140 cases were clustered in 39 different types of anomalies.

MAIN RESULTS AND THE ROLE OF CHANCE: The congenital anomaly involved a single organ in 12 (30.8%) out of the 39 types of anomalies, while multiple organs and/or segments of Müllerian ducts (complex anomaly) were involved in 27 (69.2%) types. Uterus was the organ most frequently involved (30/39: 76.9%), followed by cervix (26/39: 66.7%) and vagina (23/39: 59%). In all 39 types, the ESHRE/ESGE classification system provided a comprehensive description of each single or complex anomaly. A precise categorization was reached in 38 out of 39 types studied. Only one case of a bizarre uterine anomaly, with no clear embryological defect, could not be categorized and thus was placed in Class 6 (un-classified) of the ESHRE/ESGE system.

LIMITATIONS, REASONS FOR CAUTION: The review of the literature was thorough but we cannot rule out the possibility that other defects exist which will also require testing in the new ESHRE/ESGE system. These anomalies, however, must be rare.

WIDER IMPLICATIONS OF THE FINDINGS: The comprehensiveness of the ESHRE/ESGE classification adds objective scientific validity to its use. This may, therefore, promote its further dissemination and acceptance, which will have a positive outcome in clinical care and research.

STUDY FUNDING/COMPETING INTEREST(S): None.

Key words: ESHRE/ESGE system / Müllerian anomalies / complex anomaly / comprehensiveness / classification

Introduction

Congenital malformations of the female genital tract consist of a group of miscellaneous deviations from normal anatomy. Although certain types of congenital malformation are the result of a clear disturbance in one stage of embryologic development, others are the result of disturbances in more than one stage of normal formation. The combination of malformations, which occur at different stages of development, seems to be the reason for the extremely wide anatomical variations and the large number of combinations of congenital malformation of the female genital tract observed (Grimbizis and Campo, 2010).

At time of writing, three systems have been proposed for the classification of female genital tract anomalies: that of the American Fertility Society (AFS), now the American Society of Reproductive Medicine system (AFS, 1988); the embryological–clinical classification system of genito-urinary malformations (Acién *et al.*, 2004a; Acién and Acién, 2011); and the Vagina, Cervix, Uterus, Adnexa and associated Malformations (VCUAM) system, based on the Tumor, Nodes, Metastases principle in oncology (Oppelt *et al.*, 2005).

The AFS classification system has been successfully adopted as the main classification system for almost two decades as it is simple, user-friendly and clear enough. However this system has several limitations in terms of effective categorization of the anomalies; many congenital anomalies could not be classified in the main categories and sub-categories of the AFS system, the borders of arcuate and septate uterus are not clear, AFS class I groups an excessive number of anomalies with totally different clinical presentation, and obstructive anomalies are not adequately represented. A systematic re-evaluation of the all the existing proposals (i.e. the AFS, the embryological clinical and the VCUAM systems) has been already published, underlying the need for a new and updated clinical classification system (Grimbizis and Campo, 2010).

The new European Society of Human Reproduction and Embryology (ESHRE)/European Society for Gynaecological Endoscopy (ESGE) classification system of female genital anomalies is designed mainly for clinical orientation and it is based on the anatomy of the female genital tract (Grimbizis *et al.*, 2013a,b). This classification system seems to overcome the limits of the previous attempts; however its clinical value still needs to be proved (Grimbizis *et al.*, 2013a,b).

The aim of the present study is to evaluate the effectiveness and the comprehensiveness of the ESHRE/ESGE classification system focusing on those cases reported in the literature that could not be properly classified by the AFS system.

Materials and Methods

Literature search methodology, study selection and data extraction

We conducted an electronic literature search through Medline, EMBASE and Cochrane library from January 1988 (i.e. date of publication of AFS

classification system) to January 2014 using MESH combinations of the following key words: ‘female genital tract anomaly’, ‘müllerian anomaly’, ‘müllerian duct anomaly’, ‘uterine anomaly’ ‘cervical anomaly’, ‘vaginal anomaly’ AND ‘categorization’, ‘classification’, ‘diagnosis’, ‘case report’, ‘exceptional case’, ‘rare anomaly’, ‘rare case’. Only scientific publications in English, Italian, French and Spanish were included. The study was designed and approved by the Scientific Committee (SC) of the CONUTA Working Group.

Three participants in the systematic review (A.D.S.S., C.C., M.S.) screened independently titles and abstracts of studies obtained by the search strategy. All cross-references were hand-searched, as were relevant conference abstracts. All types of studies were selected and each potentially relevant study was obtained in full text and assessed for inclusion independently by the three authors.

The three authors independently extracted data from all included studies. The results were compared and any disagreement was discussed and resolved by consensus after consultation with a fourth reviewer (G.G.). Finally, the results were assessed independently and approved by all the members of the SC of the CONUTA Group.

Outcome measure

The primary outcome measure was the classifiability of all the identified anomalies reported as exceptional and ‘not classifiable’ according to the AFS classification system, into a specific class and/or subclass of the novel ESHRE/ESGE classification system.

Results

Search results

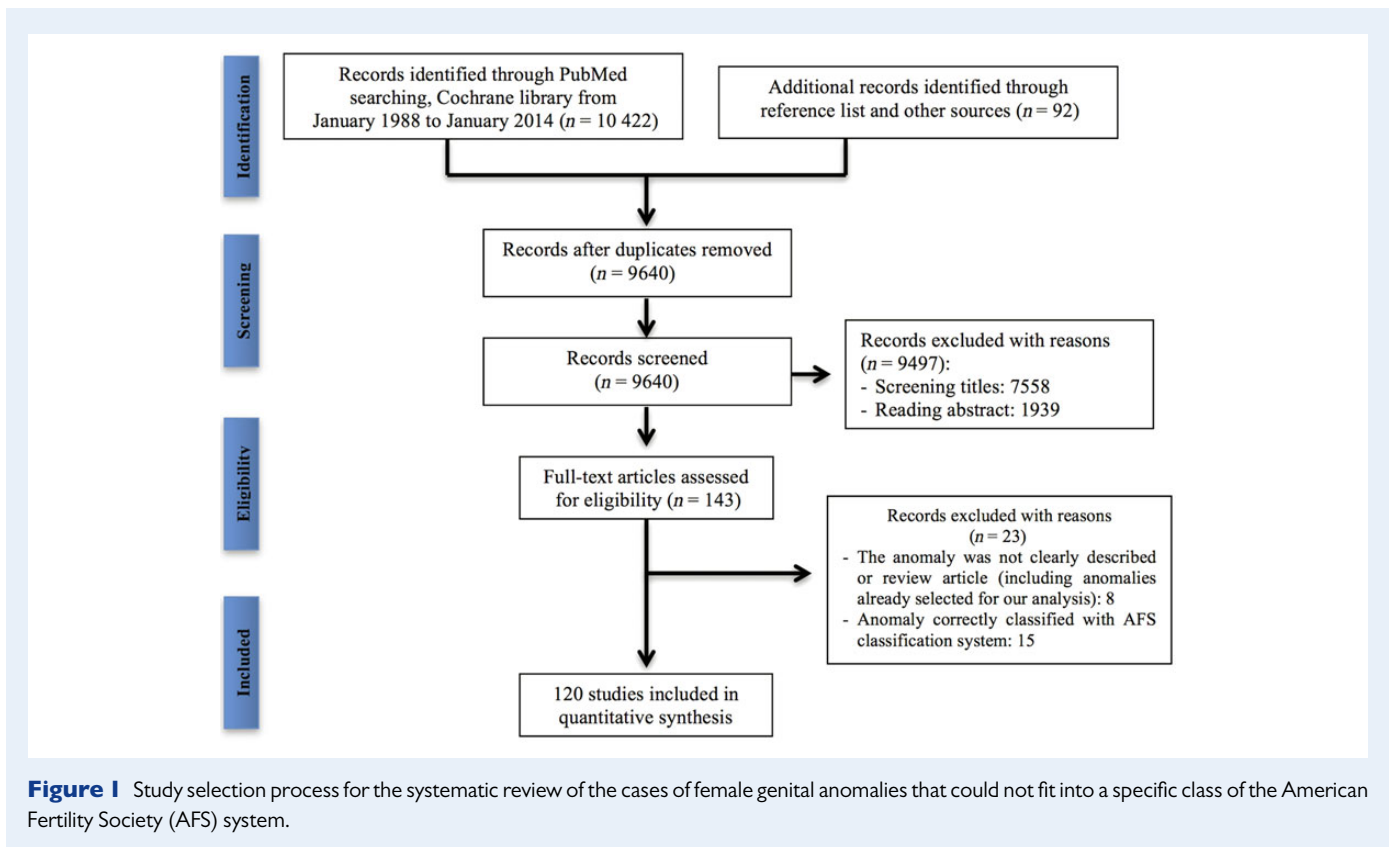
Of the 10 514 related papers, 874 were removed as duplicated articles. A total of 9497 were excluded after reading the abstracts or screening titles (Fig. 1).

Among the 143 remaining articles retrieved for detailed evaluation, 23 were excluded: 15 articles were excluded because the anomaly was described as ‘exceptional’ but could be easily classified with AFS classification system (i.e. unicornuate uterus with a non-communicating functional rudimentary horn) and 8 articles were excluded because the anomalies were not clearly described or they represented review articles or non-homogenous case series of anomalies already considered in our analysis (Fig. 1).

Classifiability of the included cases

The 120 papers included in the study reported on 140 cases, which could not properly fit into a specific class of the AFS system.

These 140 cases were clustered in 39 different types of anomalies (Table 1); the uterus was the organ most frequently involved (30/39: 76.9%), followed by cervix (26/39: 66.7%) and vagina (23/39: 59%). The congenital anomaly involved a single organ in 12 types of anomalies (12/39: 30.8%), while multiple organs and/or segments of Müllerian ducts in more than one stages of embryologic development (complex



anomalies) were simultaneously affected in 27 types of anomalies (27/39: 69.2%).

In all 39 types of anomalies, the ESHRE/ESGE classification system provided a comprehensive description of each single or complex anomaly (Table I). A precise categorization of single or complex anomalies was reached in 38 out of the 39 different types studied. In the following cases a consultation with the fourth reviewer was necessary before classification: [Capito and Sarnacki \(2009\)](#), [Gupta et al. \(2007\)](#) and [Singhal et al. \(2003\)](#) (Robert's uterus or Complete septate uterus/unilateral cervical aplasia/normal vagina ESHRE/ESGE Class U_{2b} C₃ V₀), [Nezhat and Smith \(1999\)](#) (Hemi-uterus with rudimentary cavities/ESHRE/ESGE Class U_{4a} C₀ V₀), [Wright et al. \(2011\)](#) (Aplastic uterus with bilateral rudimentary cavities ESHRE/ESGE Class U_{5a} C₀ V₀), [Sadik et al. \(2002\)](#) (Aplastic uterus/cervical aplasia/normal vagina/ESHRE/ESGE Class U_{5b} C₄ V₀), [Medema et al. \(2008\)](#) (Normal uterus with rudimentary horns/ESHRE/ESGE Class U₆). The case reported by [Nezhat and Smith \(1999\)](#) having a hemi-uterus with ipsilateral rudimentary horns with cavity could be classified as Hemi-uterus with rudimentary cavity (ESHRE/ESGE Class U_{4a} C₀ V₀) since the presence of the cavity and not the number is the clinically important parameter for the classification. The only anomaly that could not be perfectly categorized with the ESHRE/ESGE system was that reported by [Medema et al. \(2008\)](#), in which a 'tricavitated' uterus was described (Table I).

Discussion

Although several classification systems for female genital tract anomalies have been proposed ([AFS, 1988](#); [Acién et al., 2004a, 2011](#); [Oppelt et al., 2005](#)), the AFS classification is still the most widely used for categorizing

such abnormalities. The AFS system provides a description and classification of the main uterine anomalies appropriate for the vast majority of the patients. However, it is not comprehensive, which hampers precise description of each anomaly and prediction of feasibility and safety of surgical correction ([Mazouni et al., 2008](#); [Saravolos et al., 2008](#); [Grimbizis and Campo, 2010](#)).

Thus, 'obstructive' anomalies, as a result of cervical and/or vaginal aplasias and/or dysplasias in the presence of either a normal or deformed but functional uterus, are not represented in the AFS classification system. Malformations with anatomical characteristics included in more than one category cannot be classified individually and precisely. AFS class I, including cases with hypoplasia and/or dysgenesis of the vagina, cervix, uterus and/or adnexae, incorporates severe and complex types of congenital anomalies with serious clinical manifestations usually needing complex surgical treatments. A clear and accurate classification is a prerequisite for their treatment, which is not the case with the AFS system. It is noteworthy to mention that these limitations also gave rise to further subdivisions for these categories of anomaly ([Rock et al., 1995, 2010](#); [Joki-Erkkilä and Heinonen, 2003](#); [Troiano and McCarthy, 2004](#); [Strawbridge et al., 2007](#)).

In 38 out of 39 types of anomalies included in this study as previously un-classified, the ESHRE/ESGE classification provided a comprehensive description and categorization of each single or complex anomaly in all cases.

All these 39 types of anomalies could not be described and categorized previously with the AFS system; as a consequence the terminology used by the authors to describe them is often 'liberal' and mostly subjective. The ESHRE/ESGE classification system gives the opportunity to replace inappropriate descriptions within the AFS system (i.e. 'didelphys'

Table 1 Classification of the previously un-classified cases using the European Society of Human Reproduction and Embryology/European Society for Gynaecological Endoscopy (ESHRE/ESGE) Classification system of female genital anomalies: the terminology provided by the authors for the description of the anomaly is 'translated' to that of the new system before classification.

Publication	Uterus		Cervix		Vagina		ESHRE/ESGE Classification	'Associated anomalies' and comments
	Authors' description	ESHRE/ESGE terminology	Authors description	ESHRE/ESGE terminology	Authors description	ESHRE/ESGE terminology		
Rajamaheswari <i>et al.</i> (2009), Di Spiezio Sardo <i>et al.</i> (2007) and Demirci <i>et al.</i> (1995)	Normal	Normal	Normal	Normal	Longitudinal vaginal septum	Longitudinal non-obstructing vaginal septum	U ₀ C ₀ V ₁	
Cetinkaya <i>et al.</i> (2011) and Levy <i>et al.</i> (1997)	Normal	Normal	Normal	Normal	Perforated transverse vaginal septum	Transverse vaginal septum	U ₀ C ₀ V ₃	Non-obstructive transverse vaginal septum (partial failure of canalization/vertical fusion defect with incomplete unification of urogenital sinus and paramesonephric duct)
Sala Barangé <i>et al.</i> (1991)	Normal	Normal	Septate	Septate	Normal	Normal	U ₀ C ₁ V ₀	
Acién <i>et al.</i> (2009) (case 6)	Normal	Normal	Septate	Septate	Septate	Longitudinal non-obstructing vaginal septum	U ₀ C ₁ V ₁	
Morales-Roselló and Peralta Llorens (2011)	Normal	Normal	Bicervical	Double normal	Normal	Normal	U ₀ C ₂ V ₀	
Candiani <i>et al.</i> (1996)*, Dunn and Hantes (2004)*, Goldberg and Falcone (1996)* and Keltz <i>et al.</i> (1994)*	Normal	Normal	Double*	Double	Double or septate vagina	Longitudinal non-obstructing vaginal septum	U ₀ C ₂ V ₁	*One cervix is blind (not communicating with uterine cavity)
Shirota <i>et al.</i> (2009) and Varras <i>et al.</i> (2007)*§	Normal	Normal	Double*	Double normal	Double vagina§	Longitudinal non-obstructing vaginal septum	U ₀ C ₂ V ₁	*Double cervix communicating bilaterally with uterine cavity § The use of term 'double vagina' is not correct as in such case the vagina is single and divided by a septum
Deffarges <i>et al.</i> (2001), Fujimoto <i>et al.</i> (1997), Grimbizis <i>et al.</i> (2004) and Parsanezhad <i>et al.</i> (2013)	Normal	Normal	Isolated segmental cervical atresia	Cervical Aplasia	Normal	Normal	U ₀ C ₄ V ₀	
Casey and Laufer (1997)	Normal	Normal	Cervical Agenesis	Cervical Aplasia	Transverse vaginal septum	Transverse vaginal septum	U ₀ C ₄ V ₃	
Gurbuz <i>et al.</i> (2005) and Omurtag <i>et al.</i> (2009)	Normal	Normal	Cervical agenesis	Cervical Aplasia	Partial vaginal agenesis	Vaginal aplasia	U ₀ C ₄ V ₄	
Suh and Kalan (2008)	Septate	Complete septate uterus	Normal	Normal	Normal	Normal	U _{2b} C ₀ V ₀	Associated anomalies: unilateral fallopian tube hypoplasia and ipsilateral ovarian agenesis

Continued

Table I Continued

Publication	Uterus		Cervix		Vagina		ESHRE/ESGE Classification	'Associated anomalies' and comments
	Authors' description	ESHRE/ESGE terminology	Authors description	ESHRE/ESGE terminology	Authors description	ESHRE/ESGE terminology		
Shah and Laufer (2011) and Shavell et al. (2009)	Septate	Complete septate uterus	Two cervixes	Septate	Obstructed hemivagina	Longitudinal obstructing vaginal septum	U _{2b} C ₁ V ₂	The use of term 'two cervixes' is not correct as in such case the cervix is single and divided by a septum
Fedele et al. (2012)	Septate	Complete septate uterus	Septate	Septate	Imperforate hymen	Imperforate hymen	U _{2b} C ₁ V ₃	
Acién et al. (2009) (case 5) and Lev-Toaff et al. (1992)	Septate	Complete septate uterus	Bicervical	Double normal	Normal	Normal	U _{2b} C ₂ V ₀	
Balasz et al. (1996), Brown and Badawy (2013), Caliskan et al. (2008), Celik and Mulayim (2012), Chang et al. (2004), Duffy et al. (2004), Fatum et al. (2003), Guo et al. (2011), Heinonen (2006), Hundley et al. (2001), Ignatov et al. (2008), La Fianza et al. (1997), McBean and Brumsted (1994), Nigam et al. (2010), Oakes et al. (2010), Patton et al. (2004), Pavone et al. (2006), Ribeiro et al. (2010), Saygili-Yilmaz et al. (2004) and Wai et al. (2001)	Septate	Complete septate uterus	Cervical duplication or Double normal	Double normal	Septate	Longitudinal non-obstructing vaginal septum	U _{2b} C ₂ V ₁	
Hur et al. (2007), Fedele et al. (2013) (10/87 cases) and Acién et al. (2004c)*	Septate	Complete septate uterus	Double cervixes	Double normal	Unilaterally obstructed vaginal septum	Longitudinal obstructing vaginal septum	U _{2b} C ₂ V ₂	* In the case of Acién et al. (2004c) associated malformation: an ectopic ureter joined to ipsilateral hemi-cervix
Capito and Sarnacki (2009)*, Gupta et al. (2007)*, Hucke et al. (1992) (2/3 cases), Perino et al. (1995), Singhal et al. (2003)* and Spitzer et al. (2008)*	Asymmetric septate uterus (Robert's uterus)	Complete septate	Normal	Unilateral cervical aplasia	Normal	Normal	U _{2b} C ₃ V ₀	* The described 'obstructing' uterine septum is the result of unilateral cervical aplasia
Ziebarth et al. (2007) (case 2)	Bicornuate	Partial bicorporeal	Single	Normal	Obstructed hemivagina	Longitudinal obstructive vaginal septum	U _{3a} C ₀ V ₂	
Fedele et al. (2013) (1/87 case)	Bicornuate	Partial Bicorporeal	Septate	Septate	Unilateral obstructed hemivagina	Longitudinal obstructive vaginal septum	U _{3a} C ₁ V ₂	
Fedele et al. (2013) (9/87 cases)	Bicornuate	Partial Bicorporeal	Bicollis	Double normal	Obstructed hemivagina	Longitudinal obstructive vaginal septum	U _{3a} C ₂ V ₂	

Acién et al. (2009) (case 1), Fedder (1990) and Reddy and Laufer (2009)	Didelphys	Complete Bicorporeal	Single	Normal	Single	Normal	U _{3b} C ₀ V ₀	Probably the use of term 'didelphys' is not correct since according to AFS Didelphys is always associated with double cervix
Adair et al. (2011) and Altchek et al. (2009)	Didelphys	Complete Bicorporeal	Single	Normal	Unilateral distal vaginal agenesis	Vaginal aplasia	U _{3b} C ₀ V ₄	Probably the use of term 'didelphys' is not correct since according to AFS Didelphys is always associated with double cervix
Acién et al. (2009) (case 2) and Acién et al. (2010a,b)*	Didelphys	Complete Bicorporeal	Septate	Septate	Normal	Normal	U _{3b} C ₁ V ₀	* In the case of Acién et al. (2010a,b) associated malformations: Gardner's duct cyst, ipsilateral renal agenesis, blind hemibladder and ectopic ureterocele
Acién et al. (2009) (case 3 and 4)	Didelphys	Complete Bicorporeal	Septate	Septate	Septate	Longitudinal non-obstructing vaginal septum	U _{3b} C ₁ V ₁	
Al-Hakeem et al. (2002) , Altıntaş (1998) , Ankan et al. (2010)* , Asha and Manila (2008)* , Attar et al. (2013)* , Ballesio et al. (2003) , Broseta et al. (1991) , Burgis (2001) , Candiani et al. (1997) , Carlson and Garmel (1992) , Chaim et al. (1991) , Cicinelli et al. (1999) , Dhar et al. (2011)* , Donnez et al. (2007) , Fedele et al. (2013) (63/87), Erdoğan et al. (1992) , Frei et al. (1999) , Gholoum et al. (2006) , Hinckley and Milki (2003) , Hoeffel et al. (1997)* , Imai et al. (2004)* , Jindal et al. (2009) , Kim et al. (2007) , Kimble et al. (2009)* , Lin et al. (1991) , Madureira et al. (2006) , Mandava et al. (2012) , Pieroni et al. (2001) , Prada Arias et al. (2005) , Sardanelli et al. (1995) , Shibata et al. (1995) , Skondras et al. (1991) , Stassart et al. (1992) , Takagi et al. (2010) , Tanaka et al. (1998) , Tridenti et al. (1988) , Varras et al. (2008) , Vercellini et al. (2007) , Vergauwen et al. (1997) , Youssef (2013)* , Ziebarth et al. (2007) (case 1)* and Zurawin et al. (2004)	Didelphys	Complete Bicorporeal	Double	Double normal	Obstructed hemivagina	Longitudinal obstructive vaginal septum	U _{3b} C ₂ V ₂	* The blind hemivagina and ipsilateral renal agenesis define the OHVIRA syndrome
Coskun et al. (2008)	Didelphys	Complete Bicorporeal	Double	Double normal	Obstructed unilateral vagina by a transverse vaginal septum	Transverse vaginal septum	U _{3b} C ₂ V ₃	

Continued

Table I Continued

Publication	Uterus		Cervix		Vagina		ESHRE/ESGE Classification	'Associated anomalies' and comments
	Authors' description	ESHRE/ESGE terminology	Authors description	ESHRE/ESGE terminology	Authors description	ESHRE/ESGE terminology		
Moawad et al. (2009)	Didelphys	Complete Bicorporeal	Double normal	Double normal	Longitudinal Vaginal Septum Coincident with an Obstructive Transverse Vaginal Septum	Longitudinal non-obstructing and obstructive transverse vaginal septum	U _{3b} C ₂ V ₁₊₃	
Growdon and Laufer (2008) and Singhal et al. (2013)	Didelphys	Complete Bicorporeal	Double	Double normal	Lower vaginal agenesis	Vaginal aplasia	U _{3b} C ₂ V ₄	
Fedele et al. (2013) (4/87 cases), Acien et al. (2004b) and Acien et al. (2008)	Didelphys	Complete Bicorporeal	Unilateral cervical atresia	Unilateral cervical aplasia	Normal	Normal	U _{3b} C ₃ V ₀	
Singh and Sunita (2008) and Bakri et al. (1992)	Double	Complete Bicorporeal	Cervical agenesis	Cervix aplasia	Vaginal agenesis	Vaginal aplasia	U _{3b} C ₄ V ₄	
Jain et al. (2013)	Bicornuate septate uterus	Bicorporeal septate uterus	Single	Normal	Transverse vaginal septum	Transverse vaginal septum	U _{3c} C ₀ V ₃	
El Saman et al. (2011)	Hybrid septate and bicornuate uterus	Bicorporeal septate uterus	Single	Normal	Normal	Normal	U _{3c} C ₀ V ₀	
Nezhat and Smith (1999)	Unicornuate uterus with two rudimentary horns	Hemi-uterus with rudimentary cavities	Normal	Normal	Normal	Normal	U _{4a} C ₀ V ₀	Incomplete canalization of one Mullerian duct initiated from two distinct sites resulting in two cavitated horns Failure of lateral fusion
Engmann et al. (2004)*	Unicornuate uterus with normal external morphology	Hemi-uterus without rudimentary cavity with normal external morphology	Normal	Normal	Normal	Normal	U _{4b} C ₀ V ₀	
Deligeoroglou et al. (2007), Mais et al. (1994) and Heinonen (1997)	Unicornuate uterus without contralateral horn	Hemi-uterus without rudimentary cavity	Normal	Normal	Imperforate hymen and transverse vaginal septum	Imperforate hymen and transverse vaginal septum	U _{4b} C ₀ V ₃₊₃	
Wright et al. (2011)	Two hemi-uteri with endometrial cavities (no connection with normal cervix)	Aplastic Uterus with Bilateral rudimentary cavities	Normal	Normal	Normal	Normal	U _{5a} /C ₀ /V ₀	

Goluda et al. (2006)	Bicornuate rudimentary uterine horns	Aplastic uterus with rudimentary bilateral functional horns	Cervical agenesis	Cervix aplasia	Vaginal agenesis	Vaginal aplasia	U _{5a} C ₄ V ₄	
Christopoulos et al. (2009)	Didelphys uterus with noncanalized horns	Aplastic Uterus with Bilateral rudimentary horns without cavity	Double	Double normal	Normal	Normal	U _{5b} C ₂ V ₀	Probably the use of term 'didelphys' is not correct since according to AFS individual horns are not fully developed and have no cavity
Sadik et al. (2002)	'Middle' hypoplastic non-cavitated uterus/Two rudimentary horns—no endometrium	Aplastic uterus*	Sole cervix, small in size with non-patent lumen	Cervical aplasia*	Normal	Normal	U _{5b} /C ₄ /V ₀	*Cervical, uterine body and isthmus remnants. The described hypoplastic non-cavitated uterus is simply the hypoplastic isthmus without cavity attached to a 'cervix' without lumen
Medema et al. (2008)	Tricavitated	Normal uterus with two additional rudimentary functional horns	Not described clearly	Normal?	Normal?	Normal?	U ₆ C ₀ V ₀	There are two possible explanation of this anomaly: Mullerian 'duplication' at the level of uterine body responsible for the presence of the two functional rudimentary horns Aplasia of the mid part of the uterus combined with a fusion defect of the upper part

AFS, American Fertility Society; OHVIRA, Obstructed Hemivagina and Ipsilateral Renal Anomaly.

in presence of single cervix or 'two cervixes' in presence of single cervix with a septum) or subjective and mostly 'liberal' terms due to the absence of terminology (i.e. 'obstructive hemivagina' or 'hybrid septate and bicornuate uterus') with the more objective ones used for the classes and subclasses of the system such as 'complete bicornuate uterus with single cervix', 'septate cervix', 'longitudinal obstructing vaginal septum' and 'bicornuate septate', respectively. This is a 'proof' that with the use of the new ESHRE/ESGE system, a common terminology could be adopted for communication among clinicians to convey the exact anatomical status of the female genital tract, which is the primary basic characteristic in the design of the classes and sub-classes of the system.

The only anomaly that could not be perfectly categorized with the ESHRE/ESGE system was that of a reported 'tricavitated' uterus (Medema et al., 2008). According to the ESHRE/ESGE classification system this 'bizarre' uterine anomaly was clearly described as 'normal uterus with two additional rudimentary functional horns', but a precise categorization was not possible (i.e. U6C0V0). Two possible explanations of this complex uterine anomaly can be given: (i) Müllerian 'duplication' at the level of the uterine body responsible for the presence of the two functional rudimentary horns or (ii) aplasia of the mid part of the uterus combined with a fusion defect of the upper part. Indeed, potential duplication defects of Müllerian ducts like that of Medema et al. (2008), could not be categorized with the use of the new system by its design. In another case of 'perforated' vaginal septum, although it could be successfully classified with the ESHRE/ESGE system, the clinical importance of the existing perforation would have been underestimated without adding a proper comment.

An important characteristic of the ESHRE/ESGE classification system is the independent classification of uterine, cervical and vaginal anomalies. Thus, 22 out of the 39 types of anomalies (54.2%) were related to 'obstructive' anomalies that could not be described by the AFS classification system. All these cases could be easily and precisely classified into specific subclasses of the ESHRE/ESGE classification system due to this characteristic of the system. Furthermore, 7 out of the 39 (18%) types of anomalies identified referred to cases of hypoplasia and/or dysgenesis of the vagina, cervix and/or the uterus. All these malformations, otherwise nondescript or inappropriately grouped together into the same class I of the AFS classification system, could be properly and correctly classified into subclasses, expressing each one as a specific anatomical deviation. In other words, complex anomalies could be easily classified, due to the possibility to describe independently anomalies of different areas of the genital tract (uterus, cervix and vagina) and combine them case by case. However, it should be noted that, although some of these complex anomalies may be classified equally successfully by using other existing classifications (e.g. U2bC2 of the ESHRE/ESGE classification equates to CIUIc of the VCUAM classification), those systems have other disadvantages (Grimbizis and Campo, 2010), which would limit their use.

The new classification also 'promotes' the description of 'associated anomalies of non-Müllerian origin', which is so important particularly in the complex anomalies where a significant number will have associated renal tract malformations. This was not accounted for in the AFS classification and is a further advantage of the new classification.

Another important advantage of the ESHRE/ESGE classification system is that embryological origin has been adopted as the secondary basic characteristic in the design of the main classes. In fact, using this classification we could have an image of the embryological defect and, for example, such a rare anomaly as 'Robert's uterus' could be easily categorized as 'complete septate uterus with unilateral cervical aplasia' (U_{2b}C₃V0).

The system seems to be simple and functional because it has a direct and obvious association with the anatomy of the female genital system, without using complicated tables. As the AFS committee for the classification of congenital anomalies pointed out, the scheme of any classification system should be given in one page and this is fulfilled completely with the ESHRE/ESGE system. Furthermore, for cases where the anatomy is very difficult to be described only with the subclasses of the system (e.g. tricavitated uterus), an additional note could be made within the classification scheme (see 'Comments' in Table I). This may improve the skillful combination of simplicity and comprehensiveness.

From our analysis, uterine anomalies defined as 'arcuate' uterus with the AFS system are not included because this category no longer exists in the ESHRE/ESGE classification system and the patients should be categorized as normal or septate, depending on the degree of midline indentation; thus all these patients could be classified with the new system, albeit in a different way. Furthermore, accessory and cavitated uterine masses (ACUM) were excluded because their pathogenesis is still controversial. Although some authors consider them as a new type of Müllerian anomaly (probably related to a dysfunction of the female gubernaculum), others support the notion that they are simply adenomyotic cysts (Acién et al., 2010a, 2011, 2012; Bedaiwy et al., 2013).

Conclusions

An important characteristic of an 'ideal' classification system is to be comprehensive, incorporating all possible variations and offering a clear and distinct description and categorization for them. This facilitates enormously diagnosis and differential diagnosis, evaluation of their prognosis and planning their treatment. The new ESHRE/ESGE classification system may overcome the limits of the previous classification systems, providing an effective and comprehensive categorization of almost all the currently known anomalies of the female genital tract.

Suggestions for future research

The comprehensiveness of the ESHRE/ESGE classification adds objective scientific validity to its use. This may, therefore, promote its further dissemination and acceptance, which will have a positive outcome in clinical care and research. Offering a common language between the researchers, in the near future the ESHRE/ESGE classification system of female genital anomalies could be used as a tool for the development of guidelines for their diagnosis and treatment, further facilitating daily clinical practice.

Authors' roles

Conception and design: G.G., A.D.S.S., R.C. and S.G.; Literature search and data extraction: A.D.S.S., M.S and C.C.; Assessment of the quality of studies: A.D.S.S., M.S and C.C.; Analysis and interpretation of the data: A.D.S.S., M.S, C.C. and G.G.; Drafting the article: A.D.S.S. and G.G.; Critical revision of the article: all the authors (CONUTA Scientific Committee); Approval of results: CONUTA Scientific Committee.

Funding

The authors declare no source of funding or other financial support. Funding to pay the Open Access publication charges for this article was provided by the European Society of Human Reproduction and Embryology (ESHRE).

Conflict of interest

The authors report no conflict of interest. The authors alone are responsible for the content and writing of this paper.

References

- Ación P, Ación MI. The history of female genital tract malformation classifications and proposal of an updated system. *Hum Reprod Update* 2011;**17**:693–705.
- Ación P, Ación M, Sanchez-Ferrer M. Complex malformations of the female genital tract. New Types and revision of classification. *Hum Reprod* 2004a;**19**:2377–2384.
- Ación P, Sánchez-Ferrer M, Mayol-Belda MJ. Unilateral cervico-vaginal atresia with ipsilateral renal agenesis. *Eur J Obstet Gynecol Reprod Biol* 2004b;**117**:249–251.
- Ación P, Susarte F, Romero J, Galán J, Mayol MJ, Quereda FJ, Sánchez-Ferrer M. Complex genital malformation: ectopic ureter ending in a supposed mesonephric duct in a woman with renal agenesis and ipsilateral blind hemivagina. *Eur J Obstet Gynecol Reprod Biol* 2004c;**117**:105–108.
- Ación P, Ación M, Fernández S. Segmentary atresias in Müllerian malformations. *Eur J Obstet Gynecol Reprod Biol* 2008;**141**:186–191.
- Ación P, Ación M, Sánchez-Ferrer ML. Müllerian anomalies 'without a classification': from the didelphys-unicollis uterus to the bicervical uterus with or without septate vagina. *Fertil Steril* 2009;**91**:2369–2375.
- Ación P, Ación M, Fernández F, José Mayol M, Aranda I. The cavitated accessory uterine mass: a Müllerian anomaly in women with an otherwise normal uterus. *Obstet Gynecol* 2010a;**116**:1101–1109.
- Ación P, Ación M, Romero-Maroto J. Blind hemibladder, ectopic ureterocele, or Gartner's duct cyst in a woman with Müllerian malformation and supposed unilateral renal agenesis: a case report. *Int Urogynecol J* 2010b;**21**:365–369.
- Ación P, Sánchez del Campo F, Mayol MJ, Ación M. The female gubernaculum: role in the embryology and development of the genital tract and in the possible genesis of malformations. *Eur J Obstet Gynecol Reprod Biol* 2011;**159**:426–432.
- Ación P, Bataller A, Fernandez F, Acin MI, Rodriguez JM, Mayol MJ. New cases of accessory and cavitated uterine masses (ACUM): a significant cause of severe dysmenorrhea and recurrent pelvic pain in young women. *Hum Reprod* 2012;**27**:683–694.
- Adair L II, Georgiades M, Osborne R, Ng T. Uterus didelphys with unilateral distal vaginal agenesis and ipsilateral renal agenesis: common presentation of an unusual variation. *J Radiol Case Rep* 2011;**5**:1–8.
- Al-Hakeem MM, Ghourab SA, Gohar MR, Khashoggi TY. Uterine didelphys with obstructed hemivagina. *Saudi Med J* 2002;**23**:1402–1404.
- Altchek A, Brodman M, Schlosshauer P, Deligdisch L. Laparoscopic morcellation of didelphic uterus with cervical and renal aplasia. *JSL* 2009;**13**:620–624.
- Altıntaş A. Uterus didelphys with unilateral imperforate hemivagina and ipsilateral renal agenesis. *J Pediatr Adolesc Gynecol* 1998;**11**:25–27.
- American Fertility Society. The American Fertility Society classifications of adnexal adhesions, distal tubal occlusion, tubal occlusion secondary to tubal ligation, tubal pregnancies, müllerian anomalies and intrauterine adhesions. *Fertil Steril* 1988;**49**:944–955.
- Ankan İI, Harma M, Harma Mİ, Bayar U, Barut A. Herlyn-Werner-Wunderlich syndrome (uterus didelphys, blind hemivagina and ipsilateral renal agenesis)—a case report. *J Turk Ger Gynecol Assoc* 2010;**11**:107–109.
- Asha B, Manila K. An unusual presentation of uterus didelphys with obstructed hemivagina with ipsilateral renal agenesis. *Fertil Steril* 2008;**90**:849.e9–849.e10.
- Attar R, Yıldırım G, Inan Y, Küzilkale O, Karateke A. Uterus didelphys with an obstructed unilateral vagina and ipsilateral renal agenesis: a rare cause of dysmenorrhoea. *J Turk Ger Gynecol Assoc* 2013;**14**:242–245.
- Bakri YN, al-Sugair A, Hugosson C. Bicornuate nonfused rudimentary uterine horns with functioning endometria and complete cervical-vaginal agenesis: magnetic resonance diagnosis. *Fertil Steril* 1992;**58**:620–621.
- Balasz J, Moreno E, Martinez-Román S, Molini JL, Torné A, Sánchez-Martín F, Vanrell JA. Septate uterus with cervical duplication and longitudinal vaginal septum: a report of three new cases. *Eur J Obstet Gynecol Reprod Biol* 1996;**65**:241–243.
- Ballesio L, Andreoli C, De Cicco ML, Angeli ML, Manganaro L. Hematocolpos in double vagina associated with uterus didelphys: US and MR findings. *Eur J Radiol* 2003;**45**:150–153.
- Bedaiwy MA, Henry DN, Elguero S, Pickett S, Greenfield M. Accessory and cavitated uterine mass with functional endometrium in an adolescent: diagnosis and laparoscopic excision technique. *J Pediatr Adolesc Gynecol* 2013;**26**:89–91.
- Broseta E, Boronat F, Ruiz JL, Alonso M, Osca JM, Jiménez-Cruz JF. Urological complications associated to uterus didelphys with unilateral hematocolpos. A case report and review of the literature. *Eur Urol* 1991;**20**:85–88.
- Brown SJ, Badawy SZ. A rare müllerian duct anomaly not included in the classification system by the American society for reproductive medicine. *Case Rep Obstet Gynecol* 2013;**2013**:569480.
- Burgis J. Obstructive Müllerian anomalies: case report, diagnosis, and management. *Am J Obstet Gynecol* 2001;**185**:338–344.
- Caliskan E, Kakiroglu Y, Turkoz E, Corakci A. Leiomyoma on the septum of a septate uterus with double cervix and vaginal septum: a challenge to manage. *Fertil Steril* 2008;**89**:456.e3–456.e7.
- Candiani M, Busacca M, Natale A, Sambruni I. Bicervical uterus and septate vagina: report of a previously undescribed Müllerian anomaly. *Hum Reprod* 1996;**11**:218–219.
- Candiani GB, Fedele L, Candiani M. Double uterus, blind hemivagina, and ipsilateral renal agenesis: 36 cases and long-term follow-up. *Obstet Gynecol* 1997;**90**:26–32.
- Capito C, Sarnacki S. Menstrual retention in a Robert's uterus. *J Pediatr Adolesc Gynecol* 2009;**22**:e104–e106.
- Carlson RL, Garmel GM. Didelphic uterus and unilaterally imperforate double vagina as an unusual presentation of right lower-quadrant abdominal pain. *Ann Emerg Med* 1992;**21**:1006–1008.
- Casey AC, Laufer MR. Cervical agenesis: septic death after surgery. *Obstet Gynecol* 1997;**90**:706–707.
- Celik NY, Mulayim B. A müllerian anomaly 'without classification': septate uterus with double cervix and longitudinal vaginal septum. *Taiwan J Obstet Gynecol* 2012;**51**:649–650.
- Cetinkaya SE, Kahraman K, Sonmezer M, Atabekoglu C. Hysteroscopic management of vaginal septum in a virginal patient with uterus didelphys and obstructed hemivagina. *Fertil Steril* 2011;**96**:e16–e18.
- Chaim W, Kormmehl P, Kopernik G, Meizner I. Uterus didelphys with unilateral imperforate vagina and ipsilateral renal agenesis: the challenge of noninvasive diagnosis. *J Clin Ultrasound* 1991;**19**:583–585.
- Chang AS, Siegel CL, Moley KH, Ratts VS, Odem RR. Septate uterus with cervical duplication and longitudinal vaginal septum: a report of five new cases. *Fertil Steril* 2004;**81**:1133–1136.
- Christopoulos P, Deligeorgiou E, Liapis A, Agapitos E, Papadias K, Creatas G. Noncanalized horns of uterus didelphys with prolapse: a unique case in a young woman. *Gynecol Obstet Invest* 2009;**67**:183–186.
- Cicinelli E, Romano F, Didonna T, Schonauer LM, Galantino P, Di Naro E. Resectoscopic treatment of uterus didelphys with unilateral imperforate vagina complicated by hematocolpos and hematometra: case report. *Fertil Steril* 1999;**72**:553–555.

- Coskun A, Okur N, Ozdemir O, Kiran G, Arýkan DC. Uterus didelphys with an obstructed unilateral vagina by a transverse vaginal septum associated with ipsilateral renal agenesis, duplication of inferior vena cava, high-riding aortic bifurcation, and intestinal malrotation: a case report. *Fertil Steril* 2008;**90**:2006.e9–2006.e11.
- Deffarges JV, Haddad B, Musset R, Paniel BJ. Utero-vaginal anastomosis in women with uterine cervix atresia: long-term follow-up and reproductive performance. a study of 18 cases. *Hum Reprod* 2001;**16**:1722–1725.
- Deligeoroglou E, Deliveliotou A, Makrakis E, Creatsas G. Concurrent imperforate hymen, transverse vaginal septum, and unicornuate uterus: a case report. *J Pediatr Surg* 2007;**42**:1446–1448.
- Demirci F, Kuyumcuoglu U, Api M, Uludogan M. Longitudinal vaginal septum: an unusual cause of postpartum total uterine prolapse. *J Pak Med Assoc* 1995;**45**:221–222.
- Dhar H, Razek YA, Hamdi I. Uterus didelphys with obstructed right hemivagina, ipsilateral renal agenesis and right pyocolpos: a case report. *Oman Med J* 2011;**26**:447–450.
- Di Spiezio Sardo A, Bettocchi S, Bramante S, Guida M, Bifulco G, Nappi C. Office vaginoscopic treatment of an isolated longitudinal vaginal septum: a case report. *J Minim Invasive Gynecol* 2007;**14**:512–515.
- Donnez O, Jadoul P, Squifflet J, Donnez J. Didelphic uterus and obstructed hemivagina: recurrent hematometra in spite of appropriate classic surgical treatment. *Gynecol Obstet Invest* 2007;**63**:98–101.
- Duffy DA, Nulsen J, Maier D, Schmidt D, Benadiva C. Septate uterus with cervical duplication: a full-term delivery after resection of a vaginal septum. *Fertil Steril* 2004;**81**:1125–1126.
- Dunn R, Hantes J. Double cervix and vagina with a normal uterus and blind cervical pouch: a rare müllerian anomaly. *Fertil Steril* 2004;**82**:458–459.
- El Saman AM, Nasr A, Tawfik RM, Saadeldeen HS. Müllerian duct anomalies: successful endoscopic management of a hybrid bicornuate/septate variety. *J Pediatr Adolesc Gynecol* 2011;**24**:e89–e92.
- Engmann L, Schmidt D, Nulsen J, Maier D, Benadiva C. An unusual anatomic variation of a unicornuate uterus with normal external uterine morphology. *Fertil Steril* 2004;**82**:950–953.
- Erdoğan E, Okan G, Daragenli O. Uterus didelphys with unilateral obstructed hemivagina and renal agenesis on the same side. *Acta Obstet Gynecol Scand* 1992;**71**:76–77.
- Fatum M, Rojansky N, Shushan A. Septate uterus with cervical duplication: rethinking the development of müllerian anomalies. *Gynecol Obstet Invest* 2003;**55**:186–188.
- Fedder J. Uterus didelphys associated with duplex kidneys and ureters. *Acta Obstet Gynecol Scand* 1990;**69**:665–666.
- Fedele L, Frontino G, Motta F, Restelli E. A uterovaginal septum and imperforate hymen with a double pyocolpos. *Hum Reprod* 2012;**27**:1637–1639.
- Fedele L, Motta F, Frontino G, Restelli E, Bianchi S. Double uterus with obstructed hemivagina and ipsilateral renal agenesis: pelvic anatomic variants in 87 cases. *Hum Reprod* 2013;**28**:1580–1583.
- Frei KA, Bonel HM, Häberlin FC. Uterus didelphys, obstructed hemivagina and ipsilateral renal agenesis with excessive chronic vaginal discharge. *Acta Obstet Gynecol Scand* 1999;**78**:460–461.
- Fujimoto VY, Miller JH, Klein NA, Soules MR. Congenital cervical atresia: report of seven cases and review of the literature. *Am J Obstet Gynecol* 1997;**177**:1419–1425.
- Gholoum S, Pulgandla PS, Hui T, Su W, Quiros E, Laberge JM. Management and outcome of patients with combined vaginal septum, bifid uterus, and ipsilateral renal agenesis (Herlyn-Werner-Wunderlich syndrome). *J Pediatr Surg* 2006;**41**:987–992.
- Goldberg JM, Falcone T. Double cervix and vagina with a normal uterus: an unusual Müllerian anomaly. *Hum Reprod* 1996;**11**:1350–1351.
- Goluda M, St Gabrys M, Ujec M, Jedryka M, Goluda C. Bicornuate rudimentary uterine horns with functioning endometrium and complete cervical-vaginal agenesis coexisting with ovarian endometriosis: a case report. *Fertil Steril* 2006;**86**:462.e9–462.e11.
- Grimbizis GF, Campo R. Congenital malformations of the female genital tract: the need for a new classification system. *Fertil Steril* 2010;**94**:401–407.
- Grimbizis GF, Tsalikis T, Mikos T, Papadopoulos N, Tarlatzis BC, Bontis JN. Successful end-to-end cervico-cervical anastomosis in a patient with congenital cervical fragmentation: case report. *Hum Reprod* 2004;**19**:1204–1210.
- Grimbizis GF, Gordts S, Di Spiezio Sardo A, Brucker S, De Angelis C, Gergolet M, Li TC, Tanos V, Brölmann H, Gianaroli L et al. The ESHRE-ESGE consensus on the classification of female genital tract congenital anomalies. *Gynecol Surg* 2013a;**10**:199–212.
- Grimbizis GF, Gordts S, Di Spiezio Sardo A, Brucker S, De Angelis C, Gergolet M, Li TC, Tanos V, Brölmann H, Gianaroli L et al. The ESHRE/ESGE consensus on the classification of female genital tract congenital anomalies. *Hum Reprod* 2013b;**28**:2032–2044.
- Growdon WB, Laufer MR. Uterine didelphys with duplicated upper vagina and bilateral lower vaginal agenesis: a novel Müllerian anomaly with options for surgical management. *Fertil Steril* 2008;**89**:693–698.
- Guo LQ, Cheng AL, Bhayana D. Case of the month #169: septate uterus with cervical duplication and vaginal septum. *Can Assoc Radiol J* 2011;**62**:226–228.
- Gupta N, Mittal S, Dadhwal V, Misra R. A unique congenital müllerian anomaly: Robert's uterus. *Arch Gynecol Obstet* 2007;**276**:641–643.
- Gurbuz A, Karateke A, Haliloglu B. Abdominal surgical approach to a case of complete cervical and partial vaginal agenesis. *Fertil Steril* 2005;**84**:217.
- Heinonen PK. Unicornuate uterus and rudimentary horn. *Fertil Steril* 1997;**68**:224–230.
- Heinonen PK. Complete septate uterus with longitudinal vaginal septum. *Fertil Steril* 2006;**85**:700–705.
- Hinckley MD, Milki AA. Management of uterus didelphys, obstructed hemivagina and ipsilateral renal agenesis. A case report. *J Reprod Med* 2003;**48**:649–651.
- Hoeffel C, Olivier M, Scheffler C, Chelle C, Hoeffel JC. Uterus didelphys, obstructed hemivagina and ipsilateral renal agenesis. *Eur J Radiol* 1997;**25**:246–248.
- Hucke J, DeBruyne F, Campo RL, Freikha AA. Hysteroscopic treatment of congenital uterine malformations causing hemi-hematometra: a report of three cases. *Fertil Steril* 1992;**58**:823–825.
- Hundley AF, Fielding JR, Hoyte L. Double cervix and vagina with septate uterus: an uncommon müllerian malformation. *Obstet Gynecol* 2001;**98**:982–985.
- Hur JY, Shin JH, Lee JK, Oh MJ, Saw HS, Park YK, Lee KW. Septate uterus with double cervixes, unilaterally obstructed vaginal septum, and ipsilateral renal agenesis: a rare combination of müllerian and wolffian anomalies complicated by severe endometriosis in an adolescent. *J Minim Invasive Gynecol* 2007;**14**:128–131.
- Ignatov A, Costa SD, Kleinstein J. Reproductive outcome of women with rare Müllerian anomaly: report of 2 cases. *J Minim Invasive Gynecol* 2008;**15**:502–504.
- Imai A, Takagi H, Matsunami K. Double uterus associated with renal aplasia; magnetic resonance appearance and three-dimensional computed tomographic urogram. *Int J Gynaecol Obstet* 2004;**87**:169–171.
- Jain N, Gupta A, Kumar R, Minj A. Complete imperforate transverse vaginal septum with septate uterus: a rare anomaly. *J Hum Reprod Sci* 2013;**6**:74–76.
- Jindal G, Kachhawa S, Meena GL, Dhakar G. Uterus didelphys with unilateral obstructed hemivagina with hematometrocolpos and hematosalpinx with ipsilateral renal agenesis. *J Hum Reprod Sci* 2009;**2**:87–89.

- Joki-Erkkilä MM, Heinonen PK. Presenting and long-term clinical implications and fecundity in females with obstructing vaginal malformations. *J Pediatr Adolesc Gynecol* 2003;**16**:307–312.
- Keltz MD, Berger SB, Comite F, Olive DL. Duplicate cervix and vagina associated with infertility, endometriosis, and chronic pelvic pain. *Obstet Gynecol* 1994;**84**:701–703.
- Kim TE, Lee GH, Choi YM, Jee BC, Ku SY, Suh CS, Kim SH, Kim JG, Moon SY. Hysteroscopic resection of the vaginal septum in uterus didelphys with obstructed hemivagina: a case report. *J Korean Med Sci* 2007;**22**:766–769.
- Kimble RM, Khoo SK, Baartz D, Kimble RM. The obstructed hemivagina, ipsilateral renal anomaly, uterus didelphys triad. *Aust N Z J Obstet Gynaecol* 2009;**49**:554–557.
- La Fianza A, Campani R, Villa A, Dore R, Di Maggio EM, Preda L, Bertolotti GC. Communicating bicornuate uterus with double cervix and septate vagina: an uncommon malformation diagnosed with MR imaging. *Eur Radiol* 1997;**7**:235–237.
- Lev-Toaff AS, Kim SS, Toaff ME. Communicating septate uterus with double cervix: a rare malformation. *Obstet Gynecol* 1992;**79**:828–830.
- Levy G, Warren M, Maidman J. Transverse vaginal septum: case report and review of the literature. *Int Urogynecol J Pelvic Floor Dysfunct* 1997;**8**:173–176.
- Lin CC, Chen AC, Chen TY. Double uterus with an obstructed hemivagina and ipsilateral renal agenesis: report of 5 cases and a review of the literature. *J Formos Med Assoc* 1991;**90**:195–201.
- Madureira AJ, Mariz CM, Bernardes JC, Ramos IM. Case 94: Uterus didelphys with obstructing hemivaginal septum and ipsilateral renal agenesis. *Radiology* 2006;**239**:602–606.
- Mais V, Guerriero S, Ajossa S, Piras B, Melis GB. Endosonographic diagnosis, pre-operative treatment and laparoscopic removal with endoscopic stapler of a rudimentary horn in a woman with unicornuate uterus. *Hum Reprod* 1994;**9**:1297–1299.
- Mandava A, Prabhakar RR, Smitha S. OHVIRA syndrome (obstructed hemivagina and ipsilateral renal anomaly) with uterus didelphys, an unusual presentation. *J Pediatr Adolesc Gynecol* 2012;**25**:e23–e25.
- Mazouni C, Girard G, Deter R, Haumonte JB, Blanc B, Bretelle F. Diagnosis of Mullerian anomalies in adults: evaluation of practice. *Fertil Steril* 2008;**89**:219–222.
- McBean JH, Brumsted JR. Septate uterus with cervical duplication: a rare malformation. *Fertil Steril* 1994;**62**:415–417.
- Medema TJ, Dekker JJ, Mijatovic V, van de Velde WJ, Schats R, Hompes PG. A complex malformation of the uterus: report of a tricavitated uterus. *Fertil Steril* 2008;**90**:2012.e7–2012.e11.
- Moawad NS, Mahajan ST, Moawad SA, Greenfield M. Uterus didelphys and longitudinal vaginal septum coincident with an obstructive transverse vaginal septum. *J Pediatr Adolesc Gynecol* 2009;**22**:e163–e165.
- Morales-Roselló J, Peralta Llorens N. Bicervical normal uterus with normal vagina and anteroposterior disposition of the double cervix. *Case Rep Med* 2011;**2011**:303828.
- Nezhat CR, Smith KS. Laparoscopic management of a unicornuate uterus with two cavitated, non-communicating rudimentary horns: case report. *Hum Reprod* 1999;**14**:1965–1968.
- Nigam A, Puri M, Trivedi SS, Chattopadhyay B. Septate uterus with hypoplastic left adnexa with cervical duplication and longitudinal vaginal septum: rare Mullerian anomaly. *J Hum Reprod Sci* 2010;**3**:105–107.
- Oakes MB, Hussain HK, Smith YR, Quint EH. Concomitant resorptive defects of the reproductive tract: a uterocervicovaginal septum and imperforate hymen. *Fertil Steril* 2010;**93**:268.e3–268.e5.
- Omurtag K, Session D, Brahma P, Matlack A, Roberts C. Horizontal uterine torsion in the setting of complete cervical and partial vaginal agenesis: a case report. *Fertil Steril* 2009;**91**:1957.e13–1957.e15.
- Oppelt P, Renner SP, Brucker S, Strissel PL, Strick R, Oppelt PG, Doerr HG, Schott GE, Hucke J, Wallwiener D et al. The VCUAM (Vagina Cervix Uterus Adnex Associated Malformation) Classification: a new classification for genital malformations. *Fertil Steril* 2005;**84**:1493–1497.
- Parsanezhad ME, Namavar Jahromi B, Salarian L, Parsa-Nezhad M. Surgical management of a rare form of cervical dysgenesis with normal vagina, normal vaginal portion of the cervix and obstructed uterus. *Arch Iran Med* 2013;**16**:246–248.
- Patton PE, Novy MJ, Lee DM, Hickok LR. The diagnosis and reproductive outcome after surgical treatment of the complete septate uterus, duplicated cervix and vaginal septum. *Am J Obstet Gynecol* 2004;**190**:1669–1675; discussion 1675–8.
- Pavone ME, King JA, Vlahos N. Septate uterus with cervical duplication and a longitudinal vaginal septum: a müllerian anomaly without a classification. *Fertil Steril* 2006;**85**:494.e9–494.e10.
- Perino A, Chianchiano N, Simonaro C, Cittadini E. Endoscopic management of a case of 'complete septate uterus with unilateral haematometra'. *Hum Reprod* 1995;**10**:2171–2173.
- Pieroni C, Rosenfeld DL, Mokrzycki ML. Uterus didelphys with obstructed hemivagina and ipsilateral renal agenesis. A case report. *J Reprod Med* 2001;**46**:133–136.
- Prada Arias M, Mugerza Vellibre R, Montero Sánchez M, Vázquez Castelo JL, Arias González M, Rodríguez Costa A. Uterus didelphys with obstructed hemivagina and multicystic dysplastic kidney. *Eur J Pediatr Surg* 2005;**15**:441–445.
- Rajamaheswari N, Seethalakshmi K, Gayathri KB. Case of longitudinal vaginal septum with pelvic organ prolapse. *Int Urogynecol J Pelvic Floor Dysfunct* 2009;**20**:1509–1510.
- Reddy J, Laufer MR. Congenital anomalies of the female reproductive tract in a patient with Goltz syndrome. *J Pediatr Adolesc Gynecol* 2009;**22**:e71–e72.
- Ribeiro SC, Yamakami LY, Tormena RA, Pinheiro Wda S, Almeida JA, Baracat EC. Septate uterus with cervical duplication and longitudinal vaginal septum. *Rev Assoc Med Bras* 2010;**56**:254–256.
- Rock JA, Carpenter SE, Wheeler CR, Jones HWJ. The clinical management of maldevelopment of the uterine cervix. *J Pelv Surg* 1995;**1**:129–133.
- Rock JA, Roberts CP, Jones HW. Congenital anomalies of the uterine cervix: lessons from 30 cases managed clinically by a common protocol. *Fertil Steril* 2010;**94**:1858–1863.
- Sadik S, Taskin O, Sehirali S, Mendilcioglu I, Onoğlu AS, Kursun S, Wheeler JM. Complex Müllerian malformation: report of a case with a hypoplastic non-cavitated uterus and two rudimentary horns. *Hum Reprod* 2002;**17**:1343–1344.
- Sala Barangé X, Tomás Batlle X, Luburich Hernaiz P, Rodriguez Vernet A. Cervical uterine septus. Atypical malformation as a cause of sterility. *J Radiol* 1991;**72**:193–196.
- Saravelos SH, Cocksedge KA, Li T-C. Prevalence and diagnosis of congenital uterine anomalies in women with reproductive failure: a critical appraisal. *Hum Reprod Update* 2008;**14**:415–419.
- Sardanelli F, Renzetti P, Oddone M, Tomà P. Uterus didelphys with blind hemivagina and ipsilateral renal agenesis: MR findings before and after vaginal septum resection. *Eur J Radiol* 1995;**19**:164–170.
- Saygili-Yilmaz ES, Erman-Akar M, Bayar D, Yuksel B, Yilmaz Z. Septate uterus with a double cervix and longitudinal vaginal septum. *J Reprod Med* 2004;**49**:833–836.
- Shah DK, Laufer MR. Obstructed hemivagina and ipsilateral renal anomaly (OHVIRA) syndrome with a single uterus. *Fertil Steril* 2011;**96**:e39–e41.
- Shavell VI, Montgomery SE, Johnson SC, Diamond MP, Berman JM. Complete septate uterus, obstructed hemivagina, and ipsilateral renal anomaly: pregnancy course complicated by a rare urogenital anomaly. *Arch Gynecol Obstet* 2009;**280**:449–452.
- Shibata T, Nonomura K, Kakizaki H, Murayama M, Seki T, Koyanagi T. A case of unique communication between blind-ending ectopic ureter and

- ipsilateral hemi-hematocolpometra in uterus didelphys. *J Urol* 1995; **153**:1208–1210.
- Shirota K, Fukuoka M, Tsujioka H, Inoue Y, Kawarabayashi T. A normal uterus communicating with a double cervix and the vagina: a müllerian anomaly without any present classification. *Fertil Steril* 2009; **91**: 935.e1–935.e3.
- Singh G, Sunita V. Double uteri with cervicovaginal agenesis. *Fertil Steril* 2008; **90**:2016.e13–2016.e15.
- Singhal S, Agarwal U, Sharma D, Sirohiwal D. Pregnancy in asymmetric blind hemicavity of Robert's uterus—a previously unreported phenomenon. *Eur J Obstet Gynecol Reprod Biol* 2003; **107**:93–95.
- Singhal SR, Lakra P, Bishnoi P, Rohilla S, Dahiya P, Nanda S. Uterus didelphys with partial vaginal septum and distal vaginal agenesis: an unusual anomaly. *J Coll Physicians Surg Pak* 2013; **23**:149–151.
- Skondras KG, Moutsouris CC, Vaos GC, Barouchas GC, Demetriou LD. Uterus didelphys with an obstructed hemivagina and ipsilateral renal agenesis: a rare cause of acute abdomen in pubertal girls. *J Pediatr Surg* 1991; **26**:1200–1201.
- Spitzer RF, Caccia N, Kives S, Allen LM. Hysteroscopic unification of a complete obstructing uterine septum: case report and review of the literature. *Fertil Steril* 2008; **90**:2016.e17–2016.e20.
- Stassart JP, Nagel TC, Prem KA, Phipps WR. Uterus didelphys, obstructed hemivagina, and ipsilateral renal agenesis: the University of Minnesota experience. *Fertil Steril* 1992; **57**:756–761.
- Strawbridge LC, Crough NS, Cutner AS, Creighton SM. Obstructive Müllerian anomalies and modern laparoscopic management. *J Pediatr Adolesc Gynecol* 2007; **20**:195–200.
- Suh BY, Kalan MJ. Septate uterus with left fallopian tube hypoplasia and ipsilateral ovarian agenesis. *J Assist Reprod Genet* 2008; **25**: 567–569.
- Takagi H, Matsunami K, Imai A. Uterovaginal duplication with blind hemivagina and ipsilateral renal agenesis: review of unusual presentation. *J Obstet Gynaecol* 2010; **30**:350–353.
- Tanaka YO, Kurosaki Y, Kobayashi T, Eguchi N, Mori K, Satoh Y, Nishida M, Kubo T, Itai Y. Uterus didelphys associated with obstructed hemivagina and ipsilateral renal agenesis: MR findings in seven cases. *Abdom Imaging* 1998; **23**:437–441.
- Tridenti G, Armanetti M, Flisi M, Benassi L. Uterus didelphys with an obstructed hemivagina and ipsilateral renal agenesis in teenagers: report of three cases. *Am J Obstet Gynecol* 1988; **159**:882–883.
- Troiano RN, McCarthy SM. Müllerian duct anomalies: imaging and clinical issues. *Radiology* 2004; **233**:19–34.
- Varras M, Akrivis C, Demou A, Kitsiou E, Antoniou N. Double vagina and cervix communicating bilaterally with a single uterine cavity: report of a case with an unusual congenital uterine malformation. *J Reprod Med* 2007; **52**:238–240.
- Varras M, Akrivis Ch, Karadagliis S, Tsoukalos G, Plis Ch, Ladopoulos I. Uterus didelphys with blind hemivagina and ipsilateral renal agenesis complicated by pyocolpos and presenting as acute abdomen 11 years after menarche: presentation of a rare case with review of the literature. *Clin Exp Obstet Gynecol* 2008; **35**:156–160.
- Vercellini P, Daguati R, Somigliana E, Viganò P, Lanzani A, Fedele L. Asymmetric lateral distribution of obstructed hemivagina and renal agenesis in women with uterus didelphys: institutional case series and a systematic literature review. *Fertil Steril* 2007; **87**:719–724.
- Vergauwen S, De Schepper AM, Delbeke L. Unilateral intermittent occlusion of a bicornuate uterus in association with ipsilateral renal agenesis and vena cava inferior duplication. *Rofö* 1997; **166**:457–459.
- Wai CY, Zekam N, Sanz LE. Septate uterus with double cervix and longitudinal vaginal septum. A case report. *J Reprod Med* 2001; **46**:613–617.
- Wright KN, Okpala O, Laufer MR. Obstructed uteri with a cervix and vagina. *Fertil Steril* 2011; **95**:290.e17–290.e9.
- Youssef MAFM. Obstructed hemivagina and ipsilateral renal anomaly syndrome with uterus didelphys (OHVIRA). *Middle East Fertil Soc J* 2013; **18**:58–61.
- Ziebarth A, Eyster K, Hansen K. Delayed diagnosis of partially obstructed longitudinal vaginal septa. *Fertil Steril* 2007; **87**:697.e17–697.e20.
- Zurawin RK, Dietrich JE, Heard MJ, Edwards CL. Didelphic uterus and obstructed hemivagina with renal agenesis: case report and review of the literature. *J Pediatr Adolesc Gynecol* 2004; **17**:137–141.