

**Placental anastomoses in monochorionic diamniotic twin pregnancies: not
only a source of complications**

Bolla D ¹,

Favre D ¹,

Spinelli M¹,

Baud D. ^{2,3},

Baumann M.¹,

Raio L.^{1,3}

1. Department of Obstetrics and Gynaecology, University Hospital of Bern, Bern, Switzerland.
2. Department of Obstetrics and Gynecology, University Hospital of Lausanne CHUV, Lausanne, Switzerland.
3. Swiss Fetal Laser Group. University Hospital of Bern, Bern; University Hospital of Lausanne CHUV, Lausanne, Switzerland.

This article has been accepted for publication and undergone full peer review but has not been through the copyediting, typesetting, pagination and proofreading process, which may lead to differences between this version and the Version of Record. Please cite this article as doi: 10.1002/uog.15822

Corresponding author:

Raio Luigi, MD
Department of Obstetrics and Gynaecology
University hospital INSELSPITAL
Effingerstrasse 102
CH-3010 Bern
SWITZERLAND
Phone: 0041 31 632 10 10
Fax: 0041 31 632 16 46
Email: luigi.raio@insel.ch

We present 2 cases of monochorionic diamniotic (MCDA) twin pregnancies with severe fetal anemia, in which a transfusion was performed only in one fetus, allowing the successful treatment of both twins and a significant prolongation of the pregnancy.

Case 1: A 32-year-old gravida 4, para 2 with a MCDA twins was referred to our center at 22+3 weeks' gestation with hydrops fetalis and increased middle cerebral artery peak systolic velocities (MCA-PSV) in both fetuses. A Kleihauer-Betke test was positive (1.6%) and a feto-maternal haemorrhage was diagnosed. Fetal anemia was detected at cordocentesis and a total of 60ml blood volume was transfused through the placental insertion of the umbilical cord of fetus A at 22+4 weeks' gestation. The hemoglobin (Hb) level increased from 76 to 129g/L with a substantial drop of the MCA-PSV to normal ranges in both twins (figure 1A). Two days later, both MCA-PSV's raised again ($> 1.5\text{MoM}$) and a total of 80ml of blood was transfused to fetus A with normalization of the values (figure 1A). Nine weeks later a cesarean section was performed, due to the onset of placental insufficiency in one fetus.

Case 2: A 36-year-old primigravida with a MCDA twin pregnancy was referred at 27+6 weeks' gestation for maternal D and C alloimmunization. The MCA-PSV's of both twins were increased ($> 1.5\text{MoM}$). A transitory improvement of the MCA-PSV of

both twins was observed after fetal lung maturation at 28+0 weeks' gestation. However, two days later the MCA-PSVs increased again ($>1.5\text{MoM}$). A cordocentesis was performed at 28+2 weeks' gestation in the umbilical cord of fetus B. Thirty-three ml blood were transfused, with an increase of Hb from 66 to 145g/L. The MCA-PSV's dropped to normal ranges in both twins (figure 1B). A second transfusion of 60ml blood was necessary at 30 weeks' because of raising MCA PSV's in both twins ($>1.5\text{MoM}$ - Figure 1B). The MCA-PSV in both fetuses were uneventful until 32+0 weeks' gestation when, due to a rupture of membranes, a cesarean section was performed. Neonatal characteristics of both cases are summarized in table 1.

To our knowledge, this is the first paper that evaluated the advantage of using these vascular connections between both circulations for therapeutic purposes. Cordocentesis is nowadays a safe method with excellent perinatal outcome. However procedure-related fetal loss rates varies from 0.9 to 9% and a complication rate of 3.1% per intervention has been reported¹⁻³. Srisupundit et al. found a significant higher risk of complications in twins compared to singleton pregnancies⁴. Based on these considerations, reducing the number of cordocentesis may also decrease the risk of complications.

In conclusion, it seems possible to treat anemic MCDA fetuses due to alloimmunization or feto-maternal haemorrhage by intrauterine transfusion of only one fetus and to monitor them using MCA-PSV.

References

1. Lewi L, Deprest J, Hecher K. The vascular anastomoses in monochorionic **twin** pregnancies and their clinical consequences. *Am J Obstet Gynecol.* 2013 Jan;**208**(1):19-30.
2. Society for Maternal-Fetal Medicine (SMFM) Clinical Guideline #8: the fetus at risk for anemia--diagnosis and management. Society for Maternal-Fetal Medicine (SMFM). *Am J Obstet Gynecol.* 2015 Jun;**212**(6):697-710.
3. Van Kamp IL, Klumper FJ, Oepkes D, Meerman RH, Scherjon SA, Vandebussche FP, Kanhai HH. Complications of intrauterine intravascular transfusion for fetal anemia due to maternal red-cell alloimmunization. *Am J Obstet Gynecol.* 2005 Jan;**192**(1):171-7.
4. Srisupundit K, Wanapirak C, Piyamongkol W, Sirichotiyakul S, Tongsong T. Comparisons of outcomes after cordocentesis at mid-pregnancy between singleton and twin pregnancies. *Prenat Diagn.* 2011 Nov;**31**(11):1066-9.
5. Mari G, Deter RL, Carpenter RL, Rahman F, Zimmerman R, Moise KJ Jr, Dorman KF, Ludomirsky A, Gonzalez R, Gomez R, Oz U, Detti L, Copel JA, Bahado-Singh R, Berry S, Martinez-Poyer J, Blackwell SC. Noninvasive diagnosis by Doppler ultrasonography of fetal anemia due to maternal red-cell alloimmunization. Collaborative Group for Doppler Assessment of the Blood Velocity in Anemic Fetuses. *N Engl J Med.* 2000 Jan 6;**342**(1):9-14.

Conflict of interest

None of the authors of this manuscript have conflicts of interest with this case report.

Tables

Table 1: Neonatal characteristics of the two presented cases

	Case 1		Case 2	
	Fetus A	Fetus B	Fetus A	Fetus B
birth weight [g]	2200	1320	1540	1620
Apgar at 1/5/10 min	9/10/10	9/10/10	4/7/8	5/7/9
UC pH_{arterial}	7.37	7.29	7.33	7.4
UC pH_{venous}	7.38	7.32	7.32	7.4
Hemoglobin [g/L]	164	171	150	151
Hematocrit [L/L]	0.50	0.53	0.44	0.43

UC, umbilical cord.

Legends to Figures

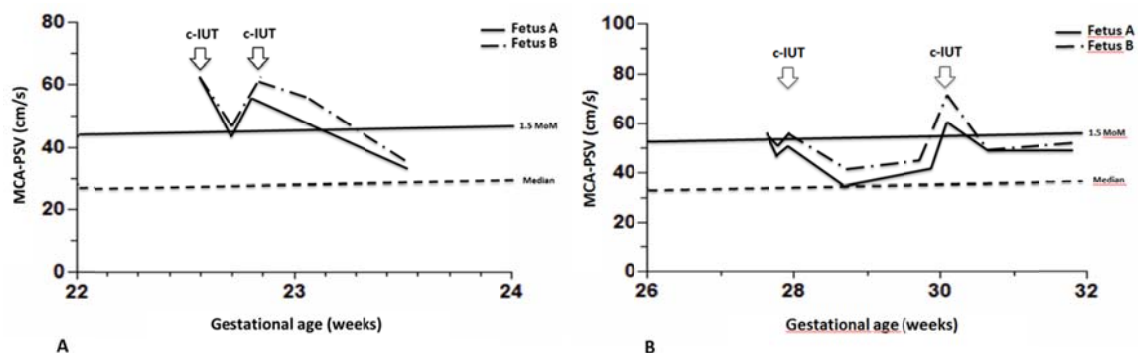


Figure 1

Consecutive MCA-PSV after intrauterine transfusion (reference ranges adapted from Mari et al.⁵)

Panel A: Case 1; Panel B: Case 2.

Abbreviations: MCA-PSV, middle cerebral artery peak systolic velocity; c-IUT, intrauterine transfusion by cordocentesis.