

## CASE REPORT

**Flare-up reactions in severe drug hypersensitivity: infection or ongoing T-cell hyperresponsiveness**Lukas Jörg-Walther<sup>1</sup>, Benno Schnyder<sup>1</sup>, Arthur Helbling<sup>1</sup>, Karin Helsing<sup>2</sup>, Alexandra Schüller<sup>2</sup>, Annette Wochner<sup>2</sup> & Werner Pichler<sup>3</sup><sup>1</sup>Department of Rheumatology, Immunology and Allergology, Inselspital, University Hospital of Bern, Bern, Switzerland<sup>2</sup>Department of Visceral Surgery and Medicine, Inselspital, University Hospital of Bern, Bern, Switzerland<sup>3</sup>ADR-AC GmbH, Adverse Drug Reactions, Analysis and Consulting, Bern, Switzerland**Correspondence**

Lukas Jörg-Walther, Department of Rheumatology, Immunology and Allergology, Inselspital, University Hospital of Bern, 3010 Bern, Switzerland.

Tel: +41 31 632 22 69; Fax: +41 31 632 42 08;

E-mail: [lukas.joerg@insel.ch](mailto:lukas.joerg@insel.ch)**Funding Information**

No sources of funding were declared for this study.

Received: 22 April 2015; Revised: 14 July 2015; Accepted: 29 July 2015

*Clinical Case Reports* 2015; 3(10): 798–801

doi: 10.1002/ccr3.346

**Introduction**

Drug rash with eosinophilia and systemic symptoms (DRESS), also named drug-induced hypersensitivity syndrome (DiHS) is a serious multiorgan disease, which is caused by a drug-induced specific immune reaction. It is a delayed-type hypersensitivity reaction mediated by T cells. Its symptoms include exanthema, fever, most often eosinophilia, lymphadenopathy, and hepatitis [1]. Occasionally other organs like kidney, heart, lung, pancreas or bone marrow are affected [1–4]. The drugs most often involved in these hypersensitivity reactions are anticonvulsants, allopurinol, and various antimicrobial drugs (e.g., sulfonamides, chinolones, minocycline, and anti-HIV drugs but also beta-lactams). The clinical diagnosis is difficult because the disease onset is slow, often many weeks after beginning of therapy, and fever and lymphadenopathy suggest an infectious or an autoimmune disease. Moreover, even after stopping the culprit drug DRESS symptoms can persist for weeks [5].

Flare-up reactions are late manifestations or more specifically relapses of drug-induced T-cell-mediated

**Key Clinical Message**

“Flare-up” reactions are late manifestations of severe T-cell-mediated drug hypersensitivity reactions. Management is anti-inflammatory treatment and avoiding unnecessary medicines. Symptoms like fever, lymph node swelling, and blood count abnormalities may lead to confusion with bacterial infections. For prompt recognition it is important to keep the differential diagnosis in mind.

**Keywords**

Drug hypersensitivity, drug rash with eosinophilia and systemic symptoms (DRESS), flare-up reaction, infection, relapse, T cell.

hypersensitivity reactions, in particular DRESS. The term “flare-up” reaction was coined for reappearance of clinical symptoms in severe drug allergies caused by anti-infective agents which are not due to relapse of the original infection [6]. However, “flare-up” reactions do not only occur in drug allergies to anti-infective agents, but also in the framework of DRESS due to anticonvulsants or other drugs. Here, we present a case with “flare-up” reactions during a DRESS (Fig. 1) and present a review of the literature.

**Case**

A 64-year-old white women was treated with piperacillin/tazobactam after perforation of the duodenum pars III as complication of an endoscopic retrograde cholangiopancreatography. 2 days later, she developed fever (T 38.1°C) with an elevated CRP (451 mg/L). Antibiotics were changed to meropenem and vancomycin. A CT scan showed a retroperitoneal abscess. The abscess was drained and general condition improved. 24 days after start of meropenem and vancomycin, a maculopapular rash appeared on

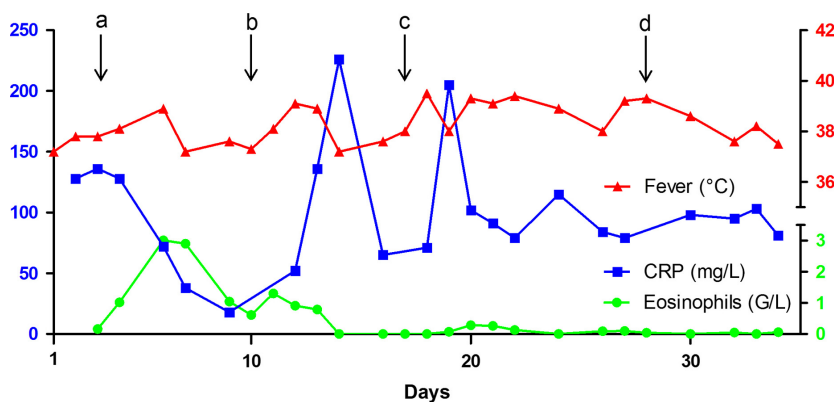
the trunk. Over the following days skin eruptions spread to the limbs and face, associated with axillary and inguinal lymphadenopathy as well as fever (38.8°C). Blood and urine cultures were taken, but were negative, a chest radiograph and a CT scan of the abdomen showed no signs of infection. A serologic search for mycoplasma, chlamydia trachomatis and hepatitis A, B, C, and D virus were negative. PCR for CMV, EBV, HHV-6, and HHV-7 showed no viral load at this timepoint. CMV IgG were, however, positive, IgM negative, indicating that the patient was already infected at an earlier timepoint. Antinuclear and anti-neutrophil cytoplasmic antibodies could not be detected. Antibiotic therapy was changed to ciprofloxacin and daptomycin. However, in spite of treatment with systemic glucocorticoids (80 mg methylprednisolone per day) the exanthema worsened and even some bullous skin lesions appeared. Skin biopsy revealed a perivascular lymphohistiocytic infiltrate with eosinophilic and neutrophilic granulocytes, consistent with drug hypersensitivity. Based on the skin eruption, presence of strong eosinophilia (3.01 G/L), elevated liver enzymes, CRP (72 mg/L), and high fever (39.2°C) a DRESS to meropenem and vancomycin with flare up on ciprofloxacin and daptomycin was suspected. Antibiotic therapy was stopped but glucocorticoids continued. After initial improvement, three additional, short-lived relapses with worsening exanthema, fever, a rise in CRP and signs of hepatitis were noticed (Fig. 1): The second “flare-up” was associated with temporary stopping of corticosteroids. The third episode occurred 24 h after beginning therapy with fluconazole and pantoprazole. The fourth “flare-up” reaction was temporally associated with a reactivation of cytomegalovirus (measured again by PCR, 4866 copies/mL). Serial blood, urine, and stool cultures were taken during all flare-up reactions and were all negative. PCR

**Table 1.** Patient characteristics.

Sex, age	Female, 64
Causal drug	Meropenem Vancomycin Confirmed
Time between first drug intake and manifestation of DRESS	24 days
Clinic	Exanthema Lymphadenopathy Eosinophilia Fever Hepatitis
Number of flares	4
Suspected drug as trigger for flare	Daptomycin Ciprofloxacin Pantoprazole Fluconazole
Treatment	Topical and systemic corticosteroids
Max. Eosinophilia (G/L)	3.01
Viral PCR	Positive for CMV (4866 copies/mL), negative for HHV-6, HHV-7, EBV

for EBV, HHV-6, and HHV-7 were measured again at the fourth flare-up and showed no viral reactivation. A second chest radiograph was unremarkable. Over the following weeks no new antibiotics were given and corticosteroids were tapered off. All symptoms disappeared (Table 1).

An allergy workup after recovery revealed sensitization to both initial drugs meropenem and vancomycin in patch- and lymphocyte transformation testing, but no sensitization to ciprofloxacin. The patient was treated several weeks later with a chinolone and tolerated this medication well. Several months after the hypersensitivity reaction, pantozole was reintroduced too without any problems.



**Figure 1.** Course of laboratory parameters and body temperature in the described case. Begin of the exanthema on day 1. Presumed trigger of flare-up reactions (arrows): new introduced ciprofloxacin and daptomycin on day 3 (a), temporary stopp of steroids on day 10 (b), new introduced fluconazole and pantoprazole on day 17 (c), CMV reactivation measured on the basis of PCR on day 28 (d).

In the suspected first flare-up symptoms worsened on ciprofloxacin and daptomycin without intermittent improvement though it was the first exposure for the patient. This time course suggests an unspecific stimulation and speaks against a T-cell-mediated allergy which needs usually at least several days to develop. The suspected third relapse developed within 24 h after exposure to pantoprazole and fluconazole and recovered very soon after stopping these drugs, which is also not consistent with a T-cell-mediated allergy. Thus, we have not performed an allergy workup for daptomycin, pantoprazole, and fluconazole.

## Review of the literature

We searched publications on drug rash with eosinophilia and systemic symptoms (DRESS) in Pub Med and analyzed articles pertaining to the clinical course of this disease and “flare-up” reactions. Flare-up reactions are relapses of severe T-cell-mediated drug hypersensitivity reactions. Only little is known about the risk to trigger them by exposure to new introduced drugs. DRESS literature about “flare-up” is mainly focused on reactivation of human herpes viruses [7–9]. There are only few data in the literature concerning the association between secondary administered xenobiotics and flare-up reactions in DRESS:

- Voltolini *et al.* described a case with phenobarbital-induced DRESS. In the course of DRESS, the patient was treated with ceftriaxone but developed a massive flare of symptoms a few days later. A later evaluation revealed sensitization to both drugs [10].
- Mennicke *et al.* published a fatal case of a sulfasalazine-induced DRESS. Because of fever and persistent exanthema, an infection was assumed and treatment with vancomycin was started. Two days later, the patient showed an increase in liver enzymes and rapidly developed a fulminant liver failure. [11].
- Mardivirin *et al.* examined 7 DRESS patients, who had “flare-up” 3–5 days after amoxicillin has been started. The authors hypothesize that amoxicillin increases the replication of HHV-6, which facilitates the development of a flare-up [12]. Indeed, it has been shown that high doses of penicillin may inhibit IFN $\gamma$  synthesis in T cells [13].
- There are three more case reports with sulfasalazine as a DRESS inducing drug. All three patients reacted with fever, lymphadenopathy, and pharyngitis when amoxicillin was given [14–16].
- In a study of seven patients who developed a multiple drug hypersensitivity, four patients with DRESS

or severe exanthema developed an additional drug allergy after introducing a second drug [17].

## Our case revisited and discussion

“Flare-up” reactions within the context of DRESS are in the literature mostly associated with reactivation of human herpes virus such as HHV-6, HHV-7, EBV, and CMV. However, this applies only partly to our case: 28 days after appearance of the hypersensitivity reaction, a CMV reactivation was found as a probable cause of the fourth flare-up. However, the initial DRESS reaction and the first three relapses were not associated with detectable viral activations. In addition, they were also only short lasting (2–3 days), which would not be expected if they had been due to herpes virus reactivations. This suggests that the “flare-ups” were triggered by the newly administered drugs.

Generalized drug allergies are accompanied by massive T-cell activations in the circulating blood – quite similar to T-cell activations in viral infections [18]. Such T-cell activations may lower the threshold of T-cell reactivity so that they can react to binding of drugs to HLA or TCR. The clinical consequence may be a “flare-up” reaction. Often this reactivity does not persist after recovery (as in our case). However, occasionally such reactions may result in new, additional sensitizations. There may be a link between “flare-ups” to drugs and multiple drug hypersensitivity [17].

In our patient the symptoms of lymphadenopathy and fever 24 days after start of antibiotic therapy because of retroperitoneal abscess were suggestive for a relapse of the infection. However, the pattern with increasing exanthema, eosinophilia, and elevated liver enzymes led us to the suspected diagnosis of a DRESS. Serial blood, urine, and stool cultures among other diagnostic modalities were all negative which supported the diagnosis of a DRESS. In spite of residual uncertainty, we decided to stop the antibiotic therapy and to administer systemic glucocorticoid under “waitful watching”. The further course with improvement and finally healing and the later allergy workup with demonstration of fitting sensitizations additionally backed the diagnosis of a DRESS.

The clinical diagnosis of a DRESS or flare-up in the acute phase is difficult. Differential diagnoses are infectious or autoimmune disease and there is no reliable diagnostic test for distinction. As in our case, the pattern of skin manifestations, blood eosinophilia, organ involvement, time course, and involvement of typical drugs sometimes may help. Important is to keep the differential diagnoses in mind.

## Conclusions

In our experience “flare-up” reactions occur mainly in severe delayed hypersensitivity reactions like DRESS and severe MPE. They appear hours to days after the administration of a new drug, and tend to be interpreted as infectious complication. However, they are probably attributable to stimulation of preactivated T cells by drugs binding to TCR and HLA. For the clinician it is important to know and consider this phenomenon and to avoid the use of drugs/xenobiotics, if not urgently needed. The wide use of antibiotics for prophylaxis or because of uncertainty [11] as widely used in clinical practice may do more harm than good during ongoing severe drug allergy.

## Conflict of Interest

None declared.

## References

- Bocquet, H., B. Martine, and J. C. Roujeau. 1996. Drug-induced pseudolymphoma and drug hypersensitivity syndrome (drug rash with eosinophilia and systemic symptoms: DRESS). *Sem. Cut Med. Surg.* 15:250–257.
- Sullivan, J. R., and N. H. Shear. 2001. The drug hypersensitivity syndrome: what is the pathogenesis? *Arch. Dermatol.* 137:357–364.
- Knowles, S. R., L. E. Shapiro, and N. H. Shear. 1999. Anticonvulsant hypersensitivity syndrome: incidence, prevention and management. *Drug Saf.* 21:489–501.
- Shiohara, T., M. Iijima, Z. Ikezawa, and K. Hashimoto. 2007. The diagnosis of a DRESS syndrome has been sufficiently established on the basis of typical clinical features and viral reactivations. *Br. J. Dermatol.* 156:1083–1084.
- Cacoub, P., P. Musette, V. Descamps, O. Meyer, C. Speirs, L. Finzi, et al. 2011. The DRESS syndrome: a literature review. *Am. J. Med.* 124:588.
- Pichler, W. J., B. Daubner, and T. Kawabata. 2011. Drug hypersensitivity: flare-up reactions, cross-reactivity and multiple drug hypersensitivity. *J. Dermatol.* 38:216–221.
- Tohyama, M., K. Hashimoto, M. Yasukawa, H. Kimura, T. Horikawa, K. Nakajima, et al. 2007. Association of human herpesvirus 6 reactivation with the flaring and severity of drug-induced hypersensitivity syndrome. *Br. J. Dermatol.* 157:934.
- Descamps, V., F. Bouscarat, S. Laglenne, E. Aslangul, B. Veber, D. Descamps, et al. 1997. Human herpesvirus 6 infection associated with anticonvulsant hypersensitivity syndrome and reactive haemophagocytic syndrome. *Br. J. Dermatol.* 137:605–608.
- Suzuki, Y., R. Inagi, T. Aono, K. Yamanishi, and T. Shiohara. 1998. Human herpesvirus 6 infection as a risk factor of the development of severe drug induced hypersensitivity syndrome. *Arch. Dermatol.* 134:1108–1112.
- Voltolini, S., D. Bignardi, P. Minale, S. Pellegrini, and C. Troise. 2009. Phenobarbital-induced DiHS and ceftriaxone hypersensitivity reaction: a case of multiple drug allergy. *Eur Ann Allergy Clin Immunol.* 41:62–63.
- Mennicke, M., A. Zawodniak, M. Keller, L. Wilkens, N. Yawalkar, F. Stickel, et al. 2009. Fulminant liver failure after vancomycin in a sulfasalazine-induced DRESS syndrome: fatal recurrence after liver transplantation. *Am. J. Transplant.* 9:2197–2202.
- Mardivirin, L., L. Valeyrie-Allanore, E. Branlant-Redon, N. Beneton, K. Jidar, A. Barbaud, et al. 2010. Amoxicillin-induced flare in patients with DRESS (Drug Reaction with Eosinophilia and Systemic Symptoms): report of seven cases and demonstration of a direct effect of amoxicillin on Human Herpesvirus 6 replication in vitro. *Eur J Dermatol.* 20:68–73.
- Padovan, E., S. von Greyerz, W. J. Pichler, and H. U. Weltzien. 1999. Antigen-dependent and independent IFN-gamma modulation by penicillins. *J Immunol.* 162:1171–1177.
- Girelli, F., S. Bernardi, L. Gardelli, B. Bassi, G. Parente, A. Dubini, et al. 2013. A New Case of DRESS Syndrome Induced by Sulfasalazine and Triggered by Amoxicillin. *Case Rep Rheumatol.* 2013:409152.
- Ben Fredj, N., K. Aouam, A. Chaabane, A. Toumi, F. Ben Rhomdhane, N. Boughattas, et al. 2010. Hypersensitivity to amoxicillin after drug rash with eosinophilia and systemic symptoms (DRESS) to carbamazepine and allopurinol: a possible co-sensitization. *Br. J. Clin. Pharmacol.* 70:273–276.
- Bahat, G., H. G. Celik, F. Tufan, and B. Saka. 2010. Drug rash with eosinophilia and systemic symptoms syndrome induced by sulfasalazine. *Joint Bone Spine.* 77:87–88.
- Daubner, B., M. Groux-Keller, O. V. Hausmann, T. Kawabata, D. J. Naisbitt, B. K. Park, et al. 2012. Multiple drug hypersensitivity: normal Treg cell function but enhanced in vivo activation of drug-specific T cells. *Allergy* 67:58–66.
- Hari, Y., K. Frutig-Schnyder, M. Hurni, N. Yawalkar, M. P. Zanni, B. Schnyder, et al. 2001. T cell involvement in cutaneous drug eruptions. *Clin. Exp. Allergy* 31:1398–1408.