

CASE REPORT/CASE SERIES

An Unusual Stroke-like Clinical Presentation of Creutzfeldt-Jakob Disease Acute Vestibular Syndrome

Georgios Mantokoudis, MD, Ali S. Saber Tehrani, MD, and
David E. Newman-Toker, MD, PhD

Introduction: Vertigo and dizziness are common neurological symptoms in general practice. Most patients have benign peripheral vestibular disorders, but some have dangerous central causes. Recent research has shown that bedside oculomotor examinations accurately discriminate central from peripheral lesions in those with new, acute, continuous vertigo/dizziness with nausea/vomiting, gait unsteadiness, and nystagmus, known as the acute vestibular syndrome.

Case Report: A 56-year-old man presented to the emergency department with acute vestibular syndrome for 1 week. The patient had no focal neurological symptoms or signs. The presence of direction-fixed, horizontal nystagmus suppressed by visual fixation without vertical ocular misalignment (skew deviation) was consistent with an acute peripheral vestibulopathy, but bilaterally normal vestibuloocular reflexes, confirmed by quantitative horizontal head impulse testing, strongly indicated a central localization. Because of a long delay in care, the patient left the emergency department without treatment. He returned 1 week later with progressive gait disturbance, limb ataxia, myoclonus, and new cognitive deficits. His subsequent course included a rapid neurological decline culminating in home hospice placement and death within 1 month. Magnetic resonance imaging revealed restricted diffusion involving the basal ganglia and cerebral cortex. Spinal fluid 14-3-3 protein was elevated. The rapidly progressive clinical course with dementia, ataxia, and myoclonus plus corroborative neuroimaging and spinal fluid findings confirmed a clinicoradiographic diagnosis of Creutzfeldt-Jacob disease.

Conclusions: To our knowledge, this is the first report of an initial presentation of Creutzfeldt-Jacob disease closely mimicking vestibular neuritis, expanding the known clinical spectrum of prion disease presentations. Despite the initial absence of neurological signs, the central lesion location was differentiated from a benign peripheral vestibulopathy at the first visit using simple bedside vestibular tests. Familiarity with these tests could help providers prevent initial misdiagnosis of important central disorders in patients presenting vertigo or dizziness.

Key Words: Creutzfeldt-Jakob syndrome, vertigo, dizziness, vestibular neuritis, neurological examination

(*The Neurologist* 2015;19:96–98)

From the Department of Neurology, Johns Hopkins University School of Medicine, The Johns Hopkins Hospital, Baltimore, MD.

Supported by the Swiss National Science Foundation (PBBEP2 136573). GN Otopetrics loaned the device to measure head impulses.

The authors declare no conflict of interest.

Reprints: David E. Newman-Toker, MD, PhD, Department of Neurology, The Johns Hopkins University School of Medicine, The Johns Hopkins Hospital, Meyer Building 8-154, 600 North Wolfe Street, Baltimore, MD 21287. E-mail: toker@jhu.edu.

Copyright © 2015 Wolters Kluwer Health, Inc. All rights reserved.

ISSN: 1074-7931/15/1904-0096

DOI: 10.1097/NRL.0000000000000019

Vertigo and dizziness are common neurological symptoms in general practice, leading to >12 million outpatient visits each year to ambulatory clinics and emergency departments around the United States.^{1,2} Most patients have benign peripheral vestibular disorders, but some have dangerous central causes, such as stroke or encephalitis. Those who present with acute, continuous vertigo or dizziness with nausea/vomiting, gait unsteadiness, and nystagmus have what is known as the acute vestibular syndrome.³ Symptoms generally last days to weeks and are most often due to benign inner ear disorders (vestibular neuritis or labyrinthitis).³ Roughly one fourth of acute vestibular syndrome patients have a underlying central cause, and ~80% of these are ischemic strokes.³ Less common neurological causes include posterior fossa hemorrhages,³ multiple sclerosis,⁴ Wernicke encephalopathy,⁵ and brainstem encephalitis.⁶

Recent research has proven that bedside oculomotor examinations known by the acronym “H.I.N.T.S.” (Head Impulse, Nystagmus, Test of Skew)⁷ discriminate central from peripheral vestibular causes of acute vestibular syndrome with greater accuracy than even magnetic resonance imaging.^{7,8} The most potent single bedside predictor is the horizontal head impulse test (h-HIT) of vestibuloocular reflex function.^{3,9} This test assesses the integrity of high-speed reflex connections between the inner ear and brainstem oculomotor nuclei.¹⁰ It is abnormal on the affected side in ~95% of patients with vestibular neuritis, but is normal in ~85% of those with central causes.³ Thus, the test serves as an important, evidence-based means of assessing central versus peripheral lesions in these patients at the bedside. Portable devices are now available that can measure the h-HIT quantitatively at the bedside.¹¹

CASE REPORT

A 56-year-old man presented to the emergency department with a chief complaint of acute dizziness. His past history was remarkable only for a history of deep venous thrombosis taking warfarin for 5 years and diabetes mellitus taking metformin for 1 year. He reported new, severe, continuous unsteadiness, dizziness, and vertigo with head motion intolerance and global weakness for 1 week.

General medical examination was unremarkable. On neurological examination, sensory and motor function was normal, but there was an unsteady gait with a tendency to fall rightward after a few steps. No limb ataxia was seen. No nystagmus was seen under conditions of visual fixation. With fixation blocked using Frenzel goggles, there was pathologic, horizontal nystagmus beating to the left evident on left gaze (first-degree nystagmus). Eye movements were otherwise normal, including ocular alignment (no skew deviation by alternate cover testing). The h-HIT of vestibuloocular reflex function was normal clinically and quantitatively on both sides (Fig. 1). The remaining cranial nerves, including hearing, were normal. The presence of unidirectional, horizontal nystagmus, suppressed by visual fixation, without vertical ocular misalignment (skew) was consistent with an

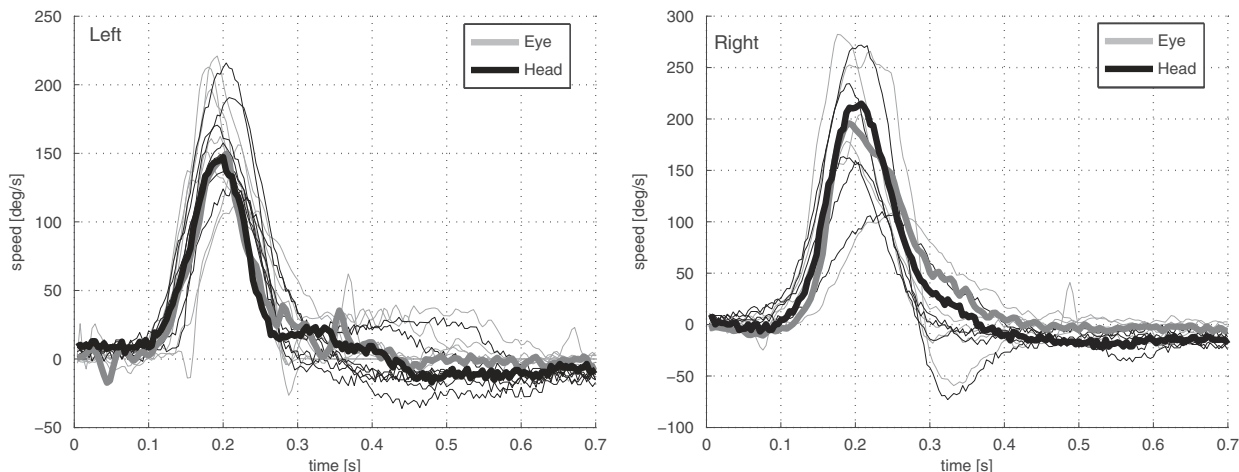


FIGURE 1. Bilaterally normal head impulse test results using a portable video-oculography device (ICS Impulse). Shown are multiple trials of the horizontal head impulse test of vestibuloocular reflex function (ie, a rapid head rotation to the left or right with the patient visually fixating on a stationary target straight ahead). Eye and head movement traces (gray and black curves) are proportional (overlapping), indicating normal, symmetric vestibuloocular reflexes. This finding, as opposed to a unilaterally abnormal vestibuloocular reflex (typically seen in vestibular neuritis), strongly indicates a central cause of the acute vestibular syndrome.

acute peripheral vestibulopathy, but the bilaterally normal horizontal vestibuloocular reflexes strongly indicated a central localization.^{3,7,8}

A computed tomography scan of the head was normal. The patient left the emergency department before being fully evaluated because of a long delay. He returned 1 week later with a progressive deterioration of balance function. Review of systems then revealed 30-pound weight loss over 6 months (initially intentional by the patient, but apparently less so as the weight loss progressed) and a decline of cognitive function since the prior visit according to his wife. His second neurological examination revealed limb ataxia and occasional myoclonus in his right arm.

The combination of weight loss, cognitive decline, ataxia, and myoclonus suggested either a paraneoplastic (or other immune-mediated) encephalitis or Creutzfeldt-Jacob disease (CJD). A magnetic resonance imaging study with diffusion-weighted images revealed multiple regions of restricted diffusion involving the basal ganglia and cerebral cortex (Fig. 2), a radiographic pattern consistent with CJD. An electroencephalogram showed diffuse cerebral disturbances with periodic discharges, and a spinal fluid analysis revealed an elevated 14-3-3 protein level, both also consistent with a clinicoradiographic diagnosis of CJD. The patient progressed rapidly while an inpatient, was discharged to home hospice care, and died just 1 month after his dominantly vestibular presentation to the emergency department.

DISCUSSION

This case expands the known spectrum of CJD presentations, broadens the differential diagnosis of acute vestibular syndrome, and highlights the importance of bedside oculomotor examinations in discriminating central from peripheral causes of acute vertigo.

Sporadic CJD is a rare, untreatable, transmissible spongiform neurodegenerative disorder caused by infectious protein particles known as prions.¹² Classic CJD is a rapidly progressive dementia with ataxia and myoclonus, although the spectrum of presenting symptoms is wide¹³ and focal variants can mimic stroke. Diagnostic delay for weeks or months is common with CJD, leading to confusion and frustration for patients, increasing risks of further disease transmission, and impeding scientific progress in studying early treatments.¹⁴ Vertigo and dizziness presentations are infrequent in CJD,¹³

and, to our knowledge, this is the first report of an initial presentation closely mimicking vestibular neuritis.

Perhaps more importantly, this case highlights the relevance of bedside vestibular physiology to clinical diagnosis in patients with acute vestibular syndrome. The central lesion location here was readily differentiated from a benign peripheral vestibulopathy at the first visit using simple bedside vestibular tests (normal vestibular reflexes in a patient with acute, continuous vertigo/dizziness, and nystagmus). Unfortunately, these well-established bedside techniques remain

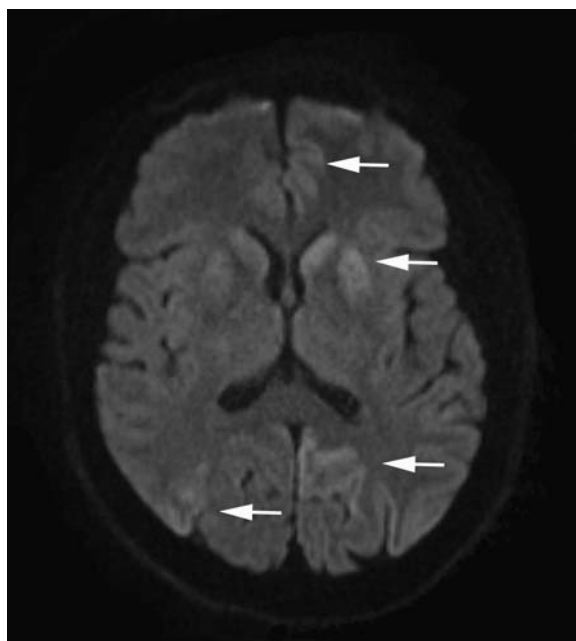


FIGURE 2. Diffusion-weighted magnetic resonance imaging. Shown is a single, representative axial image with areas of restricted diffusion (white arrows), consistent with Creutzfeldt-Jacob disease.

unfamiliar to most frontline clinicians and many neurologists. Dissemination using focused clinical skills training¹⁵ or device-based approaches¹¹ may prove beneficial.

REFERENCES

1. Sloane PD. Dizziness in primary care. Results from the National Ambulatory Medical Care Survey. *J Fam Pract.* 1989;29:33–38.
2. Newman-Toker DE, Hsieh YH, Camargo CA Jr, et al. Spectrum of dizziness visits to US emergency departments: cross-sectional analysis from a nationally representative sample. *Mayo Clin Proc.* 2008;83:765–775.
3. Tarnutzer AA, Berkowitz AL, Robinson KA, et al. Does my dizzy patient have a stroke? A systematic review of bedside diagnosis in acute vestibular syndrome. *CMAJ.* 2011;183:E571–E592.
4. Pula JH, Newman-Toker DE, Kattah JC. Multiple sclerosis as a cause of the acute vestibular syndrome. *J Neurol.* 2013;260:1649–1654.
5. Kattah JC, Dhanani SD, Pula JH, et al. Vestibular signs of thiamine deficiency during the early phase of suspected Wernicke's encephalopathy. *Neurol Clin Pract.* 2013;3:460–468.
6. Smiatacz T, Kowalik MM, Hlebowicz M. Prolonged dysphagia due to *Listeria-rhombencephalitis* with brainstem abscess and acute polyradiculoneuritis. *J Infect.* 2006;52:e165–e167.
7. Kattah JC, Talkad AV, Wang DZ, et al. HINTS to diagnose stroke in the acute vestibular syndrome: three-step bedside oculomotor examination more sensitive than early MRI diffusion-weighted imaging. *Stroke.* 2009;40:3504–3510.
8. Newman-Toker DE, Kerber KA, Hsieh YH, et al. HINTS outperforms ABCD2 to screen for stroke in acute continuous vertigo and dizziness. *Acad Emerg Med.* 2013;20:986–996.
9. Newman-Toker DE, Kattah JC, Alvernia JE, et al. Normal head impulse test differentiates acute cerebellar strokes from vestibular neuritis. *Neurology.* 2008;70(24 pt 2):2378–2385.
10. Halmagyi GM, Curthoys IS. A clinical sign of canal paresis. *Arch Neurol.* 1988;45:737–739.
11. Newman-Toker DE, Saber Tehrani AS, Mantokoudis G, et al. Quantitative video-oculography to help diagnose stroke in acute vertigo and dizziness: toward an ECG for the eyes. *Stroke.* 2013;44:1158–1161.
12. Collins SJ, Lawson VA, Masters CL. Transmissible spongiform encephalopathies. *Lancet.* 2004;363:51–61.
13. Appleby BS, Appleby KK, Rabins PV. Does the presentation of Creutzfeldt-Jakob disease vary by age or presumed etiology? A meta-analysis of the past 10 years. *J Neuropsychiatry Clin Neurosci.* 2007;19:428–435.
14. Paterson RW, Torres-Chae CC, Kuo AL, et al. Differential diagnosis of jakob-creutzfeldt disease. *Arch Neurol.* 2012;69:1578–1582.
15. Omron R, Saber Tehrani AS, Duval-Arnold J, et al. The participation in a vertigo day resulted in better resident comfort with discharging patients without receiving a CT scan in patients with vestibular neuritis. Paper presented at: Society for Academic Emergency Medicine Annual Meeting.; May 9-12, 2012; Chicago, IL.