

# Swiss Medical Weekly

Formerly: Schweizerische Medizinische Wochenschrift

An open access, online journal • [www.smw.ch](http://www.smw.ch)

Original article | Published 31 January 2016, doi:10.4414/smw.2016.14269

Cite this as: Swiss Med Wkly. 2016;146:w14269

## Tuberculosis in early medieval Switzerland – osteological and molecular evidence

Christine Cooper<sup>a</sup>, Robert Fellner<sup>b</sup>, Olivier Heubi<sup>b</sup>, Frank Maixner<sup>c</sup>, Albert Zink<sup>c</sup>, Sandra Löscher<sup>a</sup><sup>a</sup> Department of Physical Anthropology, Institute of Forensic Medicine, Bern University, Switzerland<sup>b</sup> Office de la Culture, Section d'archéologie et paléontologie, Porrentruy, Switzerland<sup>c</sup> Institute for Mummies and the Iceman, EURAC Research, Bolzano, Italy

### Summary

Lesions consistent with skeletal tuberculosis were found in 13 individuals from an early medieval skeletal sample from Courroux (Switzerland). One case of Pott's disease as well as lytic lesions in vertebrae and joints, rib lesions and endocranial new bone formation were identified. Three individuals with lesions and one without were tested for the presence of *Mycobacterium tuberculosis* complex (MTBC) ancient DNA (aDNA), and in two cases, evidence for MTBC aDNA was detected. Our results suggest the presence of tuberculosis in the analysed material, which is in accordance with other osteological and biomolecular research that reported a high prevalence of tuberculosis in medieval skeletons.

**Key words:** *Mycobacterium tuberculosis*; MTBC; infectious diseases; ancient DNA; bone lesions; Pott's disease; IS6110; vertebrae; ribs; early medieval

### Introduction

Human tuberculosis is the result of an infection by members of the *Mycobacterium tuberculosis* complex (MTBC) including *M. tuberculosis* and *M. bovis*. Because infection with *M. tuberculosis* is usually acquired by inhaling droplets coughed into the air by a lung-infected person, the disease commonly begins as respiratory infection. Human infection with *M. bovis*, the reservoir of which is in animals, can occur through the consumption of food, especially milk, from infected animals [1]. Tuberculosis is mostly associated with the lungs, but it can affect any part of the body. Mycobacteria can spread to the skeletal system via the bloodstream and lymphatic system where they gravitate to the red bone marrow, particularly in metaphyses and epiphyses. The high haematopoietic bone marrow content in vertebrae, ribs and sternum at all ages makes these elements more prone to tuberculosis infection. The spine is affected most frequently, followed by the hip and knee [2]. Once established in the skeleton, the formation of sharply demarcated tubercles is observed, followed by the gradual destruction and eventually collapse of skeletal elements [2,

3]. About 1–5% of tuberculosis patients in modern times have been reported to develop bone changes [3, 4].

Palaeopathological studies of tuberculosis in ancient populations mostly rely on the presence of spinal tuberculosis [2]. Several recent studies have focused on establishing diagnostic criteria for early stage or atypical tuberculosis lesions and their confirmation by biomolecular methods based on mycobacterial ancient DNA (aDNA) and lipid biomarker analyses. Rib lesions, superficial vertebral changes and endocranial lesions are now thought to be suggestive of tuberculosis as well, even though they cannot be considered to be pathognomic [2, 5–9].

In the spine, the anterior portion of the vertebral body is almost exclusively affected [3]. When para-discal lesions occur, the cartilage surface is eroded, followed by a narrowing of the intervertebral space, and adjacent vertebrae become affected [1]. Usually vertebrae of the lower thoracic and upper lumbar spine are involved, with the cortical destruction of the anterior region leading to collapse of vertebrae and, as a result, angular kyphosis and fusion of vertebrae. These alterations are known as Pott's disease. Vertebral tuberculosis is the most common and most characteristic skeletal lesion [10].

Inflammatory lesions in ribs have been attributed to tuberculous spread directly from the lungs or pleura [11]. Studies of skeletons with documented causes of death revealed that rib lesions are more frequent in individuals who died of pulmonary tuberculosis [11–13]. Periosteal reaction in ribs was significantly more common among individuals with tuberculosis than those with nontubercular pulmonary disease [14]. The percentages of individuals with rib lesions were found to be very variable though. New bone formation was found in 8.8% of pulmonary tuberculosis cases in the Hamann-Todd Collection [11], whereas rib lesions were identified in 61.6% of the individuals with pulmonary tuberculosis as cause of death in the Terry Collection [13]. In the Coimbra Identified Skeletal Collection 90.9% of the juveniles who died from pulmonary tuberculosis exhibited rib lesions [15]. Tuberculosis is undoubtedly the most common cause of rib lesions where it is endemic [10]. Rib lesions can therefore be useful in diagnosing past cases of tuberculosis, especially since it is the most common form

of tuberculosis (pulmonary tuberculosis) that may induce rib changes. In these cases, new bone formation was most frequently observed on the vertebral end of ribs from the middle of the rib cage [8].

The skull is rarely involved, the exception to this being young children. Infection occurs mostly haematogenously and most frequently in the frontal and parietal bones. Lesions include round lytic defects as well as vascular lesions and new bone formation on the endocranial aspect of the skull [2, 10, 16].

Even though many skeletal samples from different epochs have been studied in Switzerland and cases of skeletal tuberculosis have been identified (table 1), there is so far hardly any clear evidence from the Early Middle Ages.

Lesions that could be indicative of tuberculosis but were not discussed in that context have been described in other archaeological samples as well [23–25]. In addition to the cases from archaeological excavations, the Galler Collection of mostly dry-bone specimens from the late 19th and early 20th century contains numerous cases of skeletal tuberculosis [26, 27].

Many probable cases are known to exist in skeletal samples that have either not undergone a systematic palaeopathological investigation [28–30] or remain unpublished. Thus the published cases probably represent only a small fraction of the cases that exist in Swiss skeletal samples, and their distribution reflects the current state of research rather than the actual spatial or temporal distribution of cases.

The aim of this study was an assessment of the presence of tuberculosis in a rural early medieval population by means of a systematic investigation of bone lesions and molecular analyses of MTBC aDNA. Comparable investigations of other samples are planned in order to assess epidemiological aspects of tuberculosis during different times and in different regions of Switzerland as well as in rural and urban populations.

## The site


A construction project in the village centre of Courroux in the canton Jura led to the excavation of a 1400 m<sup>2</sup> surface to the east of the parish church. Discoveries reported during the 19th and 20th centuries indicated that a Gallo-Roman villa once covered central Courroux. We therefore expected to encounter finds and features belonging to this establishment, which proved to be the case: a series of post-holes outlining two timber buildings, two wells, and two stone-lined cellars from the Roman period were probably part of the *pars rustica*, i.e., the section of the villa containing the living quarters of the agricultural workers as well as stables, sheds and workspaces.

The discovery of an early medieval cemetery was unexpected. Located to the north of the modern church, the cemetery contained 54 inhumations (fig. 1a). Its organisation in parallel rows is typical for the early medieval period. Two stone-lined Roman cellars in the centre of the cemetery were reused as burial chambers for children (fig. 1b). The graves were all oriented along an east-west axis and were often lined with stones. Twelve tombs contained grave goods such as belt buckles, rings, fibulae and beads. These finds could be dated to the period between 610 and 670 AD. The comparatively small size and simple organisation of the cemetery are consistent with the relatively short occupation period indicated by the grave goods. Little is known about the contemporary settlement that must have been situated outside of the excavated area.

## Methods

### Osteological methods

The sex of adults was assessed using morphological criteria [31]. The age of subadults was estimated on the basis of



**Figure 1**

a: Plan of the early medieval cemetery in Courroux, Place des Mouleurs; b: several children were buried in the remains of two stone-lined Roman cellars in the middle of the cemetery.

**Table 1:** Possible cases of bone tuberculosis in archaeological skeletons from Switzerland.

Site (canton)	Date	Lesions
Saint-Prex (VD)	5th–7th c. AD	Healed Pott's disease [17], diagnosis later revised by authors [18].
Oberwil bei Büren (BE)	7th/8th to 9th c. AD	Spondylitis tuberculosa [19].
Walkringen (BE)	7th/8th to 10th/11th c. AD	Vertebral and tibial extrapulmonary tuberculosis [20].
Worb (BE)	16th–18th c. AD	Fusion of thoracic vertebrae in a female. Pott's disease and endocranial lesions in a subadult [21].
Leontica (TI)	12th/13th c. AD	Possible tuberculous arthritis of the knee joint [22].

BE = Bern; TI = Ticino; VD = Vaud

dental and skeletal development [32–34]. For adults, the “combined method” was applied [35], but only the pubic symphysis and the endocranial sutures were assessed in order to avoid destruction of joints. Additionally, age-related changes of the dentition, spine and joints were taken into consideration.

For the palaeopathological examination, the number of individuals with preserved ribs and vertebrae was determined as a first step. The number of ribs was estimated by counting the vertebral rib ends. For reasons of preservation, side and number of ribs were not recorded systematically. Vertebral bodies were considered present when they were at least approximately 30% preserved. All bones were examined for the presence of lytic lesions as well as new bone formation. Prevalence of rib and vertebral lesions was calculated for affected individuals and affected bones. Pathological changes were documented in all other preserved bones as well.

Individuals under one year of age were excluded from the study for two reasons. Firstly, it was assumed that they could have hardly developed skeletal tuberculosis. Secondly, the percentage of neonates and infants in cemeteries varies greatly. Although they are often absent or underrepresented in early medieval cemeteries, this is not the case in later periods in Switzerland [36]. Including them in a study of bone tuberculosis could, therefore, lead to a bias and make the data less comparable.

### Molecular analysis

Samples for molecular analyses were taken from four individuals, three of whom exhibited bone lesions (graves 10, 94, 127). The fourth, without lesions (grave 84), was selected as a negative control. Vertebrae (graves 10, 84, 94) and ribs (graves 10, 127) were used.

Molecular analyses were conducted at the ancient DNA laboratory of the European Academy of Bozen/Bolzano (EURAC) Institute for Mummies and the Iceman, Bolzano, Italy. Sample preparation and DNA extraction was performed in a dedicated pre-polymerase chain-reaction (PCR) area following the strict procedures required for studies of ancient DNA: use of protective clothing, ultraviolet light exposure of the equipment and bleach sterilisation of surfaces, use of PCR workstations and filtered pipette tips. Within a designated sample preparation room the outer surface of the bone samples was mechanically removed by using a Dremel® speed rotary tool. The surfaces of hard tissue material were subsequently subjected to a 15 min ultraviolet treatment. Finally, the cleaned samples were pulverised using a Retsch® mixer mill (25 Hz, 15 sec). DNA extraction was performed with approximately 250 mg of tissue powder using a silica-based DNA extraction described by Rohland, Siedel and Hofreiter [37]. The presence of tubercle bacillus DNA was assessed by applying a PCR-based assay targeting the MTBC multicopy IS6110 region [38]. To increase the sensitivity of the assay, a nested PCR strategy was applied [39]. Initially, conventional PCR was performed using primer IS6110F and the IS6110R primer to generate a 123 base-pair product. Two microlitres of the initial PCR reaction was used as the template for the nested PCR. For both the external and internal

PCR we included as controls the extraction blanks and two negative PCR controls.

For the IS6110 PCR assay resulting in a 123 base-pair fragment [38] the AmpliTaq Gold Mastermix 360 (Applied Biosystems, Foster City, CA, USA) was used according to the manufacturer’s instructions and 2 µl of GC enhancer and 5 µl of DNA (approximately 3 ng DNA) were added to a final volume of 25 µl. The PCR reaction mix for the IS6110 internal nested PCR [39] contained 10 mM tris-HCl (pH 8.3), 50 mM KCl, 1.875 mM MgCl<sub>2</sub>, 200 µM of each deoxynucleotide triphosphate, 0.5 µM of each primer, 0.1 mg/ml bovine serum albumin, 0.05 U/µl AmpliTaq Gold (Applied Biosystems, Foster City, CA, USA) 2 µl of PCR product of the IS6110 external PCR for the internal nested PCR to a final volume of 50 µl.

The obtained PCR products were separated by electrophoresis on a 2.85% agarose gel and visualised on a UV screen after staining with ethidium bromide. The nucleotide sequences of the PCR products were determined by direct sequencing. The PCR products of amplification were checked and purified (EXO-SAP treatments) and 4 µl of the PCR amplification cleaned product were sequenced on an ABI Prism 310 DNA automated sequencer, using the BigDye® Terminator Cycle Sequencing Ready Reaction Kit version 3.1 (Applied Biosystems, Foster City, CA, USA). Primers used for the sequencing were the same as those used for the PCRs. Results were subjected to sequence analysis via the National Center for Biotechnology Information (NCBI) blastN [40].

## Results

### Demographic composition of the sample

Of the 54 individuals, 27.8% (15/54) were subadults, four of whom were under one year of age and were excluded from further study. The 39 adults comprised 17 females and 22 males.

### Lesions indicative of tuberculosis

#### Vertebral lesions

Thirty-six individuals exhibited at least one observable vertebral body, and a total of 598 vertebral bodies were preserved. Lytic lesions were identified in 9 individuals (25.0%) and 32 vertebral bodies (5.4%, fig. 2). Lumbar vertebrae (10/108, 9.3%) were affected more frequently than thoracic (20/305, 6.6%) and cervical vertebrae (2/185, 1.1%).

In one 40–55-year-old female (grave 94), destruction of the vertebral bodies of the fourth to eighth thoracic vertebrae and an angular kyphosis with fusion of the facet joints was found (fig. 3a). There was an additional lytic lesion in the endplate of the third thoracic vertebra. As a result of the compression of the ribcage, at least two ribs on the right side were fused.

In the other affected spines the alterations consisted of small lytic lesions in the endplates, often with an underlying rounded cavity extending into the cancellous bone (fig. 3b). Irregular erosion and pitting of vertebral endplates with less clearly demarcated cavities were observed as well, often in combination with the former. These lesions

were found in single or multiple vertebral bodies of the affected individuals. Their diameters ranged from 2 to 11 mm.

#### Rib lesions

Thirty-three individuals had a total of 557 preserved ribs that were examined for visceral new bone formation and lytic lesions. Three individuals (3/33, 9.1%) and 15 ribs (15/557, 2.7%) were affected.

New woven bone formation was observed on several vertebral rib ends of a child (grave 82, fig. 3c), indicating an active infection at the time of death [41]. A combination of lytic lesions and new bone formation was found on the vertebral ends of ribs of a male (grave 10). The lesions appeared to be destructive and accompanied by sclerosis, but woven bone was also present at the margins. Lytic lesions were seen in several ribs of another male (grave 127, fig. 3d). They exhibited multiple crater-like lesions as well as patches of new bone formation in or around the lytic lesions and on other parts of the ribs. Ribs without lytic lesions also exhibited new bone formation.

#### Other lesions

The male from grave 127 exhibited lytic lesions around the posterior edge of the glenoid cavity of the right scapula. No reactive bone formation surrounding the lesions was observed (fig. 3e).

Sharply demarcated cavities without reactive bone formation were recorded in the anterior calcaneal articular surface of the talus of a male (grave 106).

A small patch of endocranial new bone formation was found in the parietal bone of a child (grave 128).

#### Molecular analysis

Of the analysed specimens, two tested positive for the repetitive element IS6110. A 92 base-pair nested IS6110 product from the thoracic vertebra (grave 84) and rib fragment (grave 127) were obtained and confirmed by sequencing.

In summary, bone lesions were found in 13 individuals. One of these, as well as an individual without osseous lesions, tested positive for MTBC aDNA. Two of the affected individuals exhibited lesions in more than one part of the skeleton (table 2).

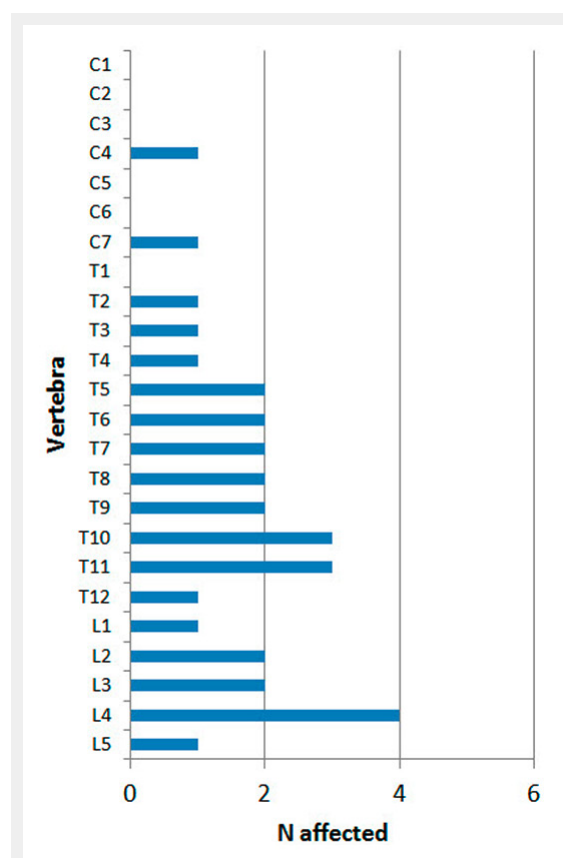
#### Discussion

The pathological changes in the spine of the individual from grave 94 are indicative of Pott's disease [1, 10]. As differential diagnoses, osteomyelitis and compression fractures must be considered, among others [2, 42]. Massive destruction of vertebral bodies and a gibbus are uncommon in osteomyelitis and compression fractures, and compression fractures mostly affect only one vertebra [10]. We therefore conclude that Pott's disease is the most likely diagnosis. This is the only "classical" case of skeletal tuberculosis in the sample. The aetiology of the small lytic lesions in the endplates of vertebrae is difficult to narrow down. Cavitation and abscessing of vertebral bodies is known to

**Table 2:** Overview of all individuals with lytic lesions and new bone formation, and the results of the molecular analyses.

Grave ID	Sex	Age at death (years)	Lesions	aDNA result
10	Male	50–70	Ribs: erosion and slight new bone formation at the vertebral end of several ribs. Spine: T11 – cavity in endplate (3 mm); L2 – cavity in endplate (7 mm).	Negative EURAC ID 1502, 1629
16	Male	60–80	Spine: T12 – four cavities in endplate (2 mm, 2 mm, 2 mm, 6 mm).	Not tested
82	Undetermined	5–6	Ribs: new bone formation at the vertebral end of several ribs	Not tested
84	Male	35–45	–	Positive EURAC ID 1501
94	Female	40–55	Spine: T3 – cavity in endplate (11 mm); T4–T8 – destruction of vertebral bodies, neural arches fused, Pott's disease.	Negative EURAC ID 1503
106	Male	40–55	Joints: lytic lesions in talus	Not tested
116	Male	40–60	Spine: L2 – cavity in endplate (7 mm); L3 – two cavities in endplate (2 mm, 2 mm); L4 – cavity in endplate (5 mm).	Not tested
127	Male	40–55	Ribs: large lytic lesions as well as new bone formation on all parts of the visceral surface of ribs. Joints: lytic lesions around the right glenoid fossa.	Positive EURAC ID 1630
128	Undetermined	5–7	Skull: endocranial new bone formation.	Not tested
129	Female	60–80	Spine: L4 – irregular and extensive erosion of the endplate without clearly demarcated cavities.	Not tested
132	Male	50–65	Spine: T2 – cavity in endplate (4 mm); L1 – cavity in endplate (4 mm); L3 – cavity in endplate (3 mm).	Not tested
133	Female	50–70	Spine: C4 – cavity in endplate (3 mm); both endplates are also irregular and pitted/eroded; T10 – three cavities in endplate (2 mm, 2 mm, 3 mm).	Not tested
164	Female	40–50	Spine: C7 – cavity in endplate (3 mm), endplate also eroded; T5–T11, L4–L5 – endplates are all irregularly pitted and partly eroded, mostly with several tiny cavities that are not clearly demarcated.	Not tested
166	Male	20–25	Spine: T9 – cavity in endplate (6 mm); T10 – cavity in endplate (9 mm); T11 – cavity in endplate (4 mm); L4 – cavity in endplate (4 mm).	Not tested

be an inflammatory response to invading tubercle bacilli and the formation of tubercles, but in tuberculosis, the destruction of vertebrae usually begins in the anterior, inferior portion of the vertebral body [1, 43] which was not the case here as lesions were found only in vertebral endplates. The neural arches were not affected though, which is typical for vertebral tuberculosis [10, 41]. The distribution of the lesions throughout the spine resembles that found in 62 autopsied cases of vertebral tuberculosis [10]. Differential diagnoses of these lesions include several conditions [2, 42, 44]. The lesions do not resemble smooth-walled Schmorl's nodes. In cancer and fungal infections, involvement of the neural arches is common, and a small number of lesions limited to few vertebral bodies would not be expected [2, 10, 44]. Some authors have hypothesised that similar le-



**Figure 2**

Distribution of lytic lesions throughout the spine.

sions could represent early-stage tuberculous spondylodiscitis [6]. However, the early stages of bone tuberculosis have not been identified with any reasonable certainty [2], and infectious spondylodiscitis can be caused by various other pathogens such as *Staphylococcus aureus* [45, 46]. We conclude that the lesions are consistent with possible early-stage spinal tuberculosis, but other aetiologies cannot be excluded.

The rib lesions in our sample (with the exception of lytic lesions in the individual from grave 127) were all located at the vertebral ends. This is more common in rib lesions associated with tuberculosis, whereas lesions associated with other pulmonary diseases are often found along the rib shaft [8]. It has been suggested that a high number of individuals with rib lesions in a population points at a broader presence of tuberculosis in that population if there is clear evidence that the disease was actually present in that group [47]. In Courroux, the presence of tuberculosis was confirmed by means of molecular analysis. For this reason we assume that tuberculosis is the most likely cause of the rib lesions.

The percentage of individuals with rib lesions lies within the values reported from other European sites from different epochs (table 3). Even though these vary, rib lesions are generally a common finding in past human groups, with males being affected more commonly than females [7]. In



**Figure 3**

a: Angular kyphosis of the spine due to destruction of the vertebral bodies of the fourth to eighth thoracic vertebrae as found *in situ* (grave 94), the thoracic region of this skeleton was recovered in a cast due to the pathological alterations; b: lytic lesions in the endplate of a lumbar vertebra (grave 116); c: new bone formation on the vertebral end of a rib (grave 82); d: lytic lesions and new bone formation on the visceral rib surfaces (grave 127); e: lytic lesions in the scapula (grave 127).

**Table 3:** Number and percentage of individuals affected by rib lesions in different European sites.

Sample	Dating	Individuals			Reference
		Total	With rib lesions		
		n	n	%	
Germany, three sites	Early Neolithic	88	14	15.9	[48]
England, Kempston	4th c. AD	87	4	4.6	[7]
UK, Kingsholm	4th c. AD	36	7	19.4	[7]
<b>Switzerland, Courroux*</b>	<b>7th c. AD</b>	<b>33</b>	<b>3</b>	<b>9.1</b>	<b>This study</b>
England, Addingham	8th–10th c. AD	24	2	8.3	[7]
England, Barton-upon-Humber	8th–10th c. AD	209	3	1.4	[7]
Poland, various sites	Medieval	81	1	1.2	[49]
England, Chichester	12th–16th c. AD	306	54	17.7	[7]
England, Brough	12th–16th c. AD	35	8	22.9	[7]
England, Newcastle-upon-Tyne	18th–19th c. AD	210	9	4.3	[7]
Portugal, Coimbra (individuals died from pulmonary tuberculosis)	20th c. AD	63	54	85.7	[8]

accordance with this, the affected individuals in our sample were two males and one child.

The lesion in a scapula (grave 127) is consistent with an osseous focus, even though in tuberculosis such foci are more common in the head or proximal metaphysis of the humerus [10]. The lytic lesions in a talus (grave 106) could represent a primary haematogenous bony focus which is most commonly observed in the talus when the ankle and tarsal bones are affected by tuberculosis [10]. While endocranial granular impressions and new bone formation as found in a child (grave 128) have been associated with tuberculous meningitis [50–52], the classic tuberculous lesions in the skull are lytic and perforate both tables of the skull [53]. Especially in the younger age groups, endocranial new bone formation may be the result of growth processes, trauma and inflammatory processes rather than tuberculosis and cannot be considered pathognomic for tuberculosis [54].

We obtained positive results for MTBC aDNA from two out of four tested individuals, one of which was an individual without skeletal lesions (grave 84). The other positive result came from an individual with lytic lesions in the ribs and the scapula (grave 127). The presence of MTBC aDNA could not be ascertained in the case of Pott's disease and a case of new bone formation in ribs.

Several factors can influence the PCR-based diagnosis of ancient pathogens and have to be considered when interpreting these TB DNA negative results. Ancient DNA becomes highly fragmented and partly degraded or entirely absent over time [55]. Furthermore, the applied PCR diagnostics, often adapted from the scientific studies on recent material, target large DNA fragments hardly occurring in the field of aDNA [56]. Future DNA-based analysis should include next-generation sequencing (NGS) approaches, and TB screening in alternative sampling sites such as the dental pulp [57]. Thereby the amplification bias of the PCR-based approaches can be reduced, and NGS facilitates pathogen diagnostics and provides additional data on preservation such as DNA damage patterns and DNA fragment size distribution. Moreover, by use of NGS the presence of TB DNA will not only be confirmed but it will also be possible to further characterise the ancient strain, thus providing insights into the evolution of this devastating disease [58, 59].

In a recent study [60] that applied a rigorous analytical regimen to the detection of MTBC aDNA, 12 samples gave definite evidence of its presence. None of these came from vertebrae displaying lesions associated with tuberculosis, but eight were from ribs with visceral new bone formation and the rest from other lesions. While vertebrae are not an ideal source for MTBC aDNA, the importance of rib lesions in the study of MTBC aDNA is increasingly recognised [48, 60]. Our study seems to confirm this.

Many factors complicate the study of the palaeopathology of tuberculosis, including factors related to data collection and reporting [2]. We are able to detect only a fraction of the people affected in the past through the skeletal record, because only a small percentage of sufferers develop bone tuberculosis in the first place while the overwhelming majority of infected people had no osseous lesions [2]. Furthermore, the absence of skeletal manifestations can mean

that an individual was not affected or died before skeletal lesions could develop, the latter leading to an underestimation of the disease prevalence through the use of osseous changes [61]. This is the case in our sample, since one individual without skeletal lesions tested positive for MTBC aDNA. Provided that the individual with Pott's disease represents a case of tuberculosis in spite of the negative result from the molecular analysis, there are at least three confirmed cases (6.0%) in our sample. An increasing body of osteological and biomolecular studies reveals high frequencies of tuberculosis in all time periods [9, 62–67]. Our results suggest that this is probably also true for early medieval Switzerland. However, much work remains to be done in order to assess any trends in the spatial and temporal spread of tuberculosis in this area.

### Limitations of the study

Differential diagnosis of bone lesions was a limitation. Radiological examinations could have been helpful but were not attempted yet. Molecular analyses were conducted for only four individuals. The reason for this was that molecular analyses were initially performed to ascertain the diagnosis of tuberculosis in cases with typical bone lesions. This did, however, not allow us to assess a possible correlation between the presence of other lesions possibly indicative of tuberculosis and positive results for the presence of MTBC aDNA.

**Acknowledgements:** We wish to express our gratitude to the excavation team and Domenic Rüttimann for their meticulous work on-site, and Simon Kramis for photographing the lesions. We thank Fabian Mitterer for his initial help in the molecular analysis of the sample material.

**Disclosure statement:** No financial support and no other potential conflict of interest relevant to this article was reported.

**Correspondence:** Sandra Lösch, Ph D, Department of Physical Anthropology, Institute of Forensic Medicine, Bern University, Sulgenauweg 40, CH-3007 Bern, [Sandra.Loesch\[at\]irm.unibe.ch](mailto:Sandra.Loesch[at]irm.unibe.ch)

### References


- 1 Auferderheide AC, Rodríguez-Martín C. The Cambridge Encyclopedia of Human Paleopathology. Cambridge: Cambridge University Press; 1998.
- 2 Roberts CA, Buikstra JE. The Bioarchaeology of Tuberculosis. A Global View on a Reemerging Disease. Gainesville: University Press of Florida; 2003.
- 3 Resnick D, Niwayama G. Osteomyelitis, septic arthritis, and soft tissue infection: Organisms. In: Resnick D, editor. Diagnosis of bone and joint disorders. Edinburgh: W.B. Saunders; 1995. p. 2448–558.
- 4 Davidson PT, Horowitz I. Skeletal tuberculosis. A review with patient presentations and discussion. Am J Med. 1970;48(1):77–84. doi: 10.1016/0002-9343(70)90101-4. PubMed PMID: 4906108.
- 5 Haas CJ, Zink A, Molnar E, Szeimies U, Reischl U, Marcsik A, et al. Molecular evidence for different stages of tuberculosis in ancient bone samples from Hungary. Am J Phys Anthropol. 2000;113(3):293–304. doi: 10.1002/1096-8644(200011)113:3<293::Aid-Ajpa2>3.0.Co;2-6. PubMed PMID: WOS:000090113400002.
- 6 Posa A, Maixner F, Lovasz G, Molnar E, Bereczki Z, Perrin P, et al. Revision of tuberculous lesions in the Bacsalmás-Oalmás series – preliminary morphological and biomolecular studies. Anthropol Anz.

- 2013;70(1):83–100. doi: Doi 10.1127/0003-5548/2012/0260. PubMed PMID: 23590114.
- 7 Roberts CA, Boylston A, Buckley L, Chamberlain AC, Murphy EM. Rib lesions and tuberculosis: the palaeopathological evidence. *Tubercle and lung disease: the official journal of the International Union against Tuberculosis and Lung Disease*. 1998;79(1):55–60. doi: 10.1054/tuld.1998.0005. PubMed PMID: 10645442.
- 8 Santos AL, Roberts CA. Anatomy of a serial killer: Differential diagnosis of tuberculosis based on rib lesions of adult individuals from the Coimbra Identified Skeletal Collection, Portugal. *Am J Phys Anthropol*. 2006;130(1):38–49. doi: Doi 10.1002/Ajpa.20160. PubMed PMID: WOS:000237018100004.
- 9 Zink AR, Molnar E, Motamedi N, Palfy G, Marsik A, Nerlich AG. Molecular history of tuberculosis from ancient mummies and skeletons. *Int J Osteoarchaeol*. 2007;17(4):380–91. doi: Doi 10.1002/Oa.909. PubMed PMID: WOS:000249132000006.
- 10 Ortner DJ. Identification of pathological conditions in human skeletal remains. Ortner DJ, editor. London: Routledge; 2003.
- 11 Kelley MA, Micozzi MS. Rib Lesions in Chronic Pulmonary Tuberculosis. *Am J Phys Anthropol*. 1984;65(4):381–6. doi: DOI 10.1002/ajpa.1330650407. PubMed PMID: WOS:A1984TX99300006.
- 12 Kelley MA, El-Najjar MY. Natural Variation and Differential-Diagnosis of Skeletal Changes in Tuberculosis. *Am J Phys Anthropol*. 1980;52(2):153–67. doi: DOI 10.1002/ajpa.1330520202. PubMed PMID: WOS:A1980JN51700001.
- 13 Roberts C, Lucy D, Manchester K. Inflammatory Lesions of Ribs – an Analysis of the Terry Collection. *Am J Phys Anthropol*. 1994;95(2):169–82. doi: DOI 10.1002/ajpa.1330950205. PubMed PMID: WOS:A1994PJ94000004.
- 14 Anson C, Rothschild B, Naples V. Soft Tissue Contributions to Pseudo-pathology of Ribs. *Advances in Anthropology*. 2012;2(2):57–63.
- 15 Santos AL, Roberts CA. A picture of tuberculosis in young Portuguese people in the early 20th century: A multidisciplinary study of the skeletal and historical evidence. *Am J Phys Anthropol*. 2001;115(1):38–49. doi: Doi 10.1002/Ajpa.1054. PubMed PMID: WOS:000168337500004.
- 16 Hershkovitz I, Greenwald CM, Latimer B, Jellema LM, Wish-Baratz S, Eshed V, et al. *Serpens endocrania symmetrica* (SES): A new term and a possible clue for identifying intrathoracic disease in skeletal populations. *Am J Phys Anthropol*. 2002;118(3):201–16. doi: Doi 10.1002/Ajpa.10077. PubMed PMID: WOS:000176476000001.
- 17 Morel P, J.-L. D, M.-R. S. Un mal de Pott du cimetière burgonde de Saint-Prex, canton de Vaud (Suisse). (5me, 6me, 7me siècles). *Lyon Médical* 1961;40:643–59. French.
- 18 Ulrich-Bochsler S, Schäublin E, Zeltner TB, Glowatzki G. Invalisierende Wirbelsäulenverkrümmung an einem Skelettfund aus dem Frühmittelalter (7/8. Bis Anfang 9. Jh.). Ein Fall einer wahrscheinlichen Spondylitis tuberculosa. *Schweizerische Medizinische Wochenschrift* 1982;112:1318–23. German.
- 19 Ulrich-Bochsler S, Menk R, Schäublin E. Die Bevölkerung von Oberwil bei Büren. In: Eggenberger P, Kellenberger H, editors. Oberwil bei Büren an der Aare, Reformierte Pfarrkirche Archäologische Grabung 1979. Bern1985. p. 79–108. German.
- 20 Ulrich-Bochsler S, Meyer L. Die anthropologischen Forschungen. Die Skelettfunde aus der Kirchgrabung von Walkringen. In: Eggenberger P, Bossert M, Ulrich-Bochsler S, editors. Walkringen, Reformierte Pfarrkirche. Bern1992. p. 89–144. German.
- 21 Ulrich-Bochsler S. Die anthropologischen Forschungen. In: Eggenberger P, Kehrl M, Schlup M, Ulrich-Bochsler S, editors. Worb, Pfarrkirche Die Ergebnisse der Bauforschungen von 1983. Bern 2012. p. 129–220. German.
- 22 Andreetta A, Lösch S, editors. Lesions of skeletal tuberculosis on young woman's knee, buried in S. Giovanni Battista church in Leontica (Ticino, Switzerland). The 19th european meeting of the paleopathology association; 2012; Lille.
- 23 Rüttimann B, Gugg HR. Pathologische Befunde. In: Schneider J, Gutscher D, Etter H, Hanser J, editors. Der Münsterhof in Zürich Bericht über die Stadtkernforschungen 1977/78. Olten/Freiburg i. Br.1982. p. 213–27. German.
- 24 Ulrich-Bochsler S. Die Bestattungen in der ehemaligen St. Nikolauskapelle im Lichte anthropologischer Untersuchungen. In: Eggenberger P, Ulrich-Bochsler S, Keck G, editors. Nidau – Ehemalige Frühmesskapelle St Nikolaus1996. p. 97–119. German.
- 25 Brunner S. Eine spätrömische Nekropole westlich des Castrum Rauracense: das Gräberfeld Kaiseraugst-Höll. *Jahresberichte aus Augst und Kaiseraugst* 2014. p. 241–331. German.
- 26 Holloway KL, Link K, Ruhli F, Henneberg M. Skeletal lesions in human tuberculosis may sometimes heal: an aid to palaeopathological diagnoses. *Plos One*. 2013;8(4):e62798. doi: 10.1371/journal.pone.0062798. PubMed PMID: 23638146; PubMed Central PMCID: PMC3634763.
- 27 Rühli FJ, Hotz G, Böni T. Brief communication: the Galler Collection: a little-known historic Swiss bone pathology reference series. *Am J Phys Anthropol*. 2003;121(1):15–8. doi: 10.1002/ajpa.10219. PubMed PMID: 12687579.
- 28 Etter HF. Anthropologische Funde und Befunde. *Jahresbericht der Archäologischen Bodenforschung des Kantons Basel-Stadt* 1989. Basel1989. p. 232–49. German.
- 29 Etter HF, Bockmühl P, Heinrichs C, Hitz I, Hotz G, Lörcher M, et al. Der Spitalfriedhof St. Johann in Basel. Funde und Befunde aus einer anthropologischen Ausgrabung. *Armut, Krankheit, Tod im frühindustriellen Basel*. Basel 1993. German.
- 30 Hotz G, Cueni A. Ein Überblick zum Forschungsstand der neuzeitlichen Skelettserie aus dem Spitalfriedhof St. Johann in Basel. *Bulletin der Schweizerischen Gesellschaft für Anthropologie*. 2003;9(1):1–6. German.
- 31 Ferembach D, Schwidetzky I, Stloukal M. Recommendations for Age and Sex Diagnoses of Skeletons. *Bulletins et Memoires de la Société d'Anthropologie de Paris* 1979;6(1):7–45. PubMed PMID: WOS:A1979HS95500001.
- 32 Schour I, Massler M. The development of the human dentition. *J Am Dent Assoc*. 1941;28:1153–60.
- 33 Scheuer L, Black S. *Developmental Juvenile Osteology*. London: Academic Press; 2000.
- 34 Schour I, Massler M. *Development of the human dentition*. 2nd ed. Chicago: American Dental Association; 1944.
- 35 Acsádi G, Nemeskéri J. *History of Human Lifespan and Mortality*. Budapest, Hungary: Akadémiai Kiadó; 1970.
- 36 Ulrich-Bochsler S. Anthropologische Befunde zur Stellung von Frau und Kind in Mittelalter und Neuzeit. *Soziobiologische und soziokulturelle Aspekte im Lichte von Archäologie, Geschichte, Volkskunde und Medizingeschichte*. Bern1997. German.
- 37 Rohland N, Siedel H, Hofreiter M. A rapid column-based ancient DNA extraction method for increased sample throughput. *Mol Ecol Resour*. 2010;10(4):677–83. doi: 10.1111/j.1755-0998.2009.02824.x. PubMed PMID: 21565072.
- 38 Eisenach KD, Cave MD, Bates JH, Crawford JT. Polymerase chain reaction amplification of a repetitive DNA sequence specific for *Mycobacterium tuberculosis*. *J Infect Dis*. 1990;161(5):977–81. PubMed PMID: 2109022.
- 39 Taylor GM, Crossey M, Saldanha J, Waldron T. DNA from *Mycobacterium tuberculosis* identified in Mediaeval human skeletal remains using polymerase chain reaction. *J Archaeol Sci*. 1996;23(5):789–98. PubMed PMID: WOS:A1996VH58800014.
- 40 Altschul SF, Gish W, Miller W, Myers EW, Lipman DJ. Basic Local Alignment Search Tool. *J Mol Biol*. 1990;215(3):403–10. doi: DOI 10.1006/jmbi.1990.9999. PubMed PMID: WOS:A1990ED16700008.
- 41 Ortner DJ. Differential Diagnosis of Skeletal Lesions in Infectious Disease. In: Pinhasi R, Mays S, editors. *Advances in Human Palaeopathology*. Chichester: John Wiley & Sons Ltd.; 2008. p. 191–214.
- 42 Matos V, Marques C, Lopes C. Severe Vertebral Collapse in a Juvenile from the Graveyard (13th/14th-19th Centuries) of the Sao Miguel Church (Castelo Branco, Portugal): Differential Palaeopathological Diagnosis. *Int J Osteoarchaeol*. 2011;21(2):208–17. doi: Doi 10.1002/Oa.1125. PubMed PMID: WOS:000288872100008.
- 43 Mann RW, Hunt DR. *Photographic Regional Atlas of Bone Disease: A Guide to Pathologic and Normal Variation in the Human Skeleton*. Springfield, Illinois: Charles C Thomas; 2005.
- 44 Hershkovitz I, Rothschild BM, Dutour O, Greenwald C. Clues to recognition of fungal origin of lytic skeletal lesions. *Am J Phys An-*

- thropol. 1998;106(1):47–60. doi: Doi 10.1002/(Sici)1096-8644(199805)106:1<47::Aid-Ajpa4>3.0.Co;2-A. PubMed PMID: WOS:000073288200004.
- 45 Cottle L, Riordan T. Infectious spondylodiscitis. *J Infection*. 2008;56(6):401–12. doi: DOI 10.1016/j.jinf.2008.02.005. PubMed PMID: WOS:000257459200001.
- 46 Garkowski A, Zajkowska A, Czupryna P, Lebkowski W, Letmanowski M, Golebicki P, et al. Infectious spondylodiscitis – A case series analysis. *Adv Med Sci-Poland*. 2014;59(1):57–60. doi: DOI 10.1016/j.advms.2014.02.001. PubMed PMID: WOS:000345341600012.
- 47 Larsen CS. *Bioarchaeology. Interpreting behavior from the human skeleton*. Cambridge: Cambridge University Press; 1997.
- 48 Nicklisch N, Maixner F, Ganslmeier R, Friederich S, Dresely V, Meller H, et al. Rib lesions in skeletons from early neolithic sites in Central Germany: On the trail of tuberculosis at the onset of agriculture. *Am J Phys Anthropol*. 2012;149(3):391–404. doi: Doi 10.1002/Ajpa.22137. PubMed PMID: WOS:000309922100010.
- 49 Betsinger TK. *The Biological Consequences of Urbanization in Medieval Poland*: Ohio State University; 2007.
- 50 Schultz M. The role of tuberculosis in infancy and childhood in prehistoric and historic populations. In: Pálfi G, Dutour O, Deak J, Hutas I, editors. *Tuberculosis past and present*. Budapest: Golden Book Publisher; 1999. p. 503–7.
- 51 Schultz M. Paleohistopathology of bone: A new approach to the study of ancient diseases. *Yearbook of Physical Anthropology*. 2001;44:106–47. doi: Doi 10.1002/Ajpa.10024. PubMed PMID: WOS:000174091100005.
- 52 Schultz M, Schmidt-Schultz TH. Is it possible to diagnose TB in ancient bone using microscopy? *Tuberculosis*. 2015;95:S80–S6. doi: 10.1016/j.tube.2015.02.035. PubMed PMID: WOS:000357931300014.
- 53 Hackett CJ. *Diagnostic Criteria of Syphilis, Yaws and Treponarid (Treponematoses) and of Some Other Diseases in Dry Bones*. Berlin Heidelberg New York: Springer 1976.
- 54 Lewis ME. Endocranial lesions in non-adult skeletons: Understanding their aetiology. *Int J Osteoarchaeol*. 2004;14(2):82–97. doi: Doi 10.1002/Oa.713. PubMed PMID: WOS:000221162900002.
- 55 Paabo S, Poinar H, Serre D, Jaenicke-Despres V, Hebler J, Rohland N, et al. Genetic analyses from ancient DNA. *Annu Rev Genet*. 2004;38:645–79. doi: DOI 10.1146/annurev.genet.37.110801.143214. PubMed PMID: WOS:000226244600020.
- 56 Kirsanow K, Burger J. Ancient human DNA. *Ann Anat*. 2012;194(1):121–32. doi: 10.1016/j.aanat.2011.11.002. PubMed PMID: WOS:000303142100015.
- 57 Matheson CD, Vernon KK, Lahti A, Fratpietro R, Spigelman M, Gibson S, et al. Molecular exploration of the first-century Tomb of the Shroud in Akeldama, Jerusalem. *Plos One*. 2009;4(12):e8319. doi: 10.1371/journal.pone.0008319. PubMed PMID: 20016819; PubMed Central PMCID: PMC2789407.
- 58 Bos KI, Harkins KM, Herbig A, Coscolla M, Weber N, Comas I, et al. Pre-Columbian mycobacterial genomes reveal seals as a source of New World human tuberculosis. *Nature*. 2014;514(7523):494–7. doi: 10.1038/nature13591. PubMed PMID: 25141181; PubMed Central PMCID: PMC4550673.
- 59 Kay GL, Sergeant MJ, Zhou ZM, Chan JZM, Millard A, Quick J, et al. Eighteenth-century genomes show that mixed infections were common at time of peak tuberculosis in Europe. *Nature Communications*. 2015;6. doi: Artn 671710.1038/Ncomms7717. PubMed PMID: WOS:000353701300002.
- 60 Müller R, Roberts CA, Brown TA. Biomolecular identification of ancient *Mycobacterium tuberculosis* complex DNA in human remains from Britain and continental Europe. *Am J Phys Anthropol*. 2014;153(2):178–89. doi: 10.1002/ajpa.22417. PubMed PMID: 24226751.
- 61 Wood JW, Milner GR, Harpending HC, Weiss KM. The Osteological Paradox - Problems of Inferring Prehistoric Health from Skeletal Samples. *Current anthropology*. 1992;33(4):343–70. doi: Doi 10.1086/204084. PubMed PMID: WOS:A1992JN18700001.
- 62 Lösch S, Kim MR, Dutour O, Courtaud P, Maixner F, Romon T, et al. Evidence for tuberculosis in 18th/19th century slaves in Anse Sainte-Marguerite (Guadeloupe - French Western Indies). *Tuberculosis (Edinb)*. 2015;95(Suppl 1):S65–8. doi: 10.1016/j.tube.2015.02.006. PubMed PMID: 25754341.
- 63 Molnar E, Donoghue HD, Lee OY, Wu HH, Besra GS, Minnikin DE, et al. Morphological and biomolecular evidence for tuberculosis in 8th century AD skeletons from Belmegyer-Csomoki domb, Hungary. *Tuberculosis (Edinb)*. 2015;95 (Suppl 1):S35–41. doi: 10.1016/j.tube.2015.02.032. PubMed PMID: 25771204.
- 64 Posa A, Maixner F, Mende BG, Kohler K, Osztas A, Sola C, et al. Tuberculosis in Late Neolithic-Early Copper Age human skeletal remains from Hungary. *Tuberculosis (Edinb)*. 2015;95(Suppl 1):S18–22. doi: 10.1016/j.tube.2015.02.011. PubMed PMID: 25857937.
- 65 Posa A, Maixner F, Sola C, Bereczki Z, Molnar E, Masson M, et al. Tuberculosis infection in a late-medieval Hungarian population. *Tuberculosis (Edinb)*. 2015;95(Suppl 1):S60–4. doi: 10.1016/j.tube.2015.02.010. PubMed PMID: 25794469.
- 66 Roberts CA. Old World tuberculosis: Evidence from human remains with a review of current research and future prospects. *Tuberculosis (Edinb)*. 2015;95(Suppl 1):S117–21. doi: 10.1016/j.tube.2015.02.018. PubMed PMID: 25802030.
- 67 Teschler-Nicola M, Novotny F, Spannagl-Steiner M, Stadler P, Prohaska T, Irrgeher J, et al. The Early Mediaeval manorial estate of Gars/Thunau, Lower Austria: An enclave of endemic tuberculosis? *Tuberculosis (Edinb)*. 2015;95(Suppl 1):S51–9. doi: 10.1016/j.tube.2015.02.017. PubMed PMID: 25857936.

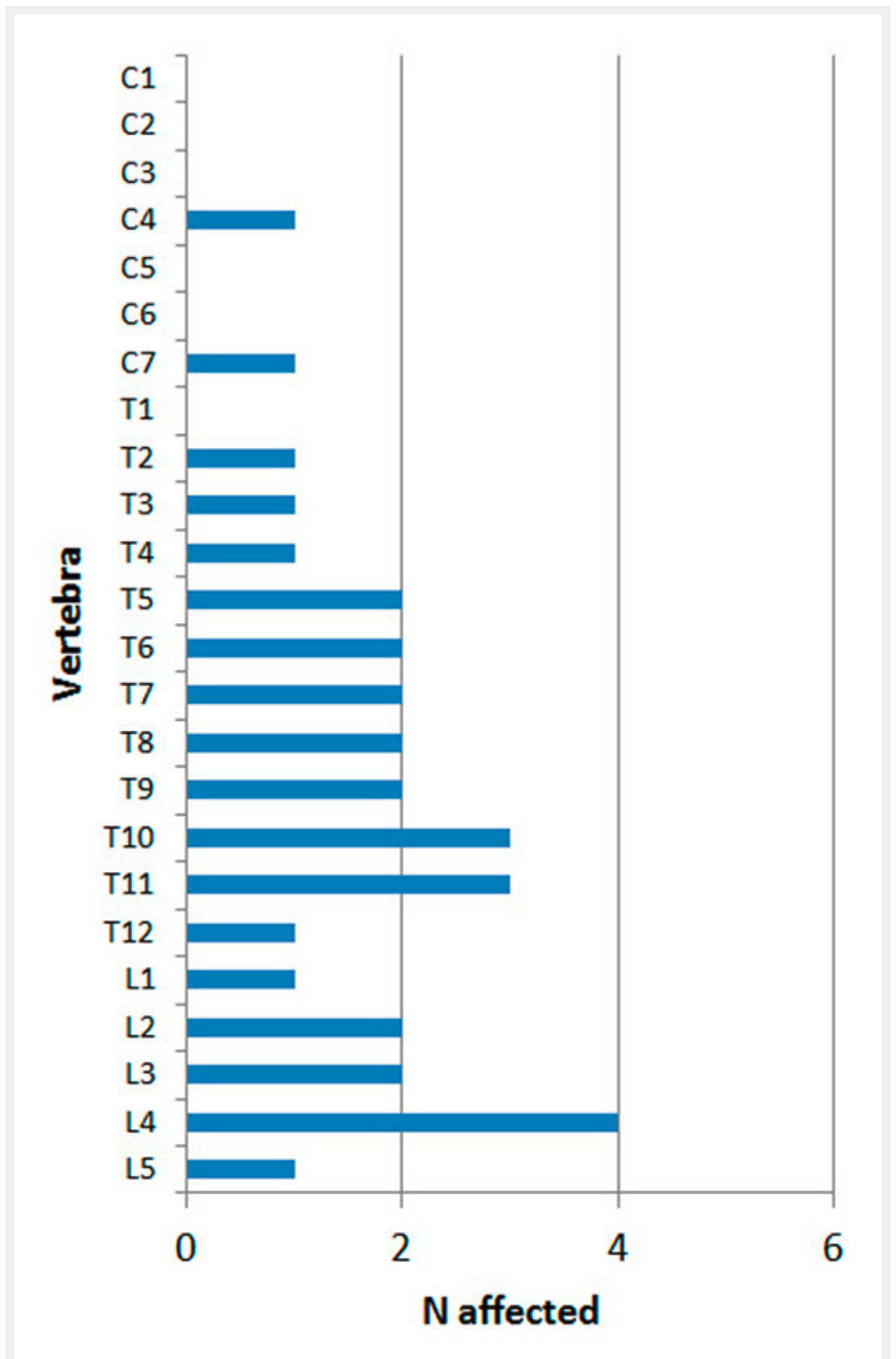


Figures (large format)



**Figure 1**

a: Plan of the early medieval cemetery in Courroux, Place des Mouleurs; b: several children were buried in the remains of two stone-lined Roman cellars in the middle of the cemetery.



**Figure 2**  
Distribution of lytic lesions throughout the spine.



**Figure 3**

a: Angular kyphosis of the spine due to destruction of the vertebral bodies of the fourth to eighth thoracic vertebrae as found *in situ* (grave 94), the thoracic region of this skeleton was recovered in a cast due to the pathological alterations; b: lytic lesions in the endplate of a lumbar vertebra (grave 116); c: new bone formation on the vertebral end of a rib (grave 82); d: lytic lesions and new bone formation on the visceral rib surfaces (grave 127), e: lytic lesions in the scapula (grave 127).