

Diagnosis of cardiac metastasis from cervical cancer in a 33-year-old patient using multimodal imaging studies: a case report and literature review

Khoschy Schawkat¹, Beatrix Hokschi², Markus Schwerzmann², Stefan Puig¹ and Thorsten Klink¹

Acta Radiologica Short Reports
3(8) 1–5

© The Foundation Acta Radiologica
2014

Reprints and permissions:
sagepub.co.uk/journalsPermissions.nav
DOI: 10.1177/2047981614530287
arr.sagepub.com



Abstract

We report a case of a 33-year-old woman with emergency admission due to dyspnoea and fever. History included squamous cell carcinoma of the cervix in complete remission. Contrast-enhanced computed tomography (CT) scanning of the chest, which was indicated to rule out pneumonia, revealed an infiltrative cardiac mass. Further assessment of the tumour by echocardiography and cardiac magnetic resonance imaging (MRI) showed transmural infiltration of the apical interventricular septum with a mass extending into the left and right ventricle cavities. The mass was highly suspicious for a cardiac metastasis. Cardiac metastases from cervical cancer are extremely rare. Recurrence of cervical carcinoma involving the heart should be considered even after a curative therapy approach. Non-invasive imaging plays a paramount role in investigating cardiac masses. Echocardiography, CT and MRI are complementary imaging modalities for complete work-up of intracardiac lesions.

Keywords

Cardiac, computed tomography (CT), magnetic resonance imaging (MRI), cervix, heard, metastases

Date received: 10 October 2013; accepted: 12 March 2014

Introduction

Cardiac masses are uncommon findings. They are subdivided into non-neoplastic (e.g. intracardiac thrombus) and neoplastic lesions. Most frequent neoplastic lesions are metastases from extra-cardiac tumors. Metastases are approximately 40 times more common than primary tumors, more than 70% of the latter are benign (1,2). Myocardial metastases are suggestive of hematogenous invasion (3). Simultaneous hematogenous dissemination of cancer cells into other organs is often found (3).

Early detection of cardiac metastasis is key in improving the prognosis. Non-invasive imaging plays a paramount role in investigating cardiac masses and establishing a diagnosis. Most cardiac masses are initially detected by echocardiography. If present, echocardiography can also be used to assess the hemodynamic relevance of accompanying pericardial effusion. Computed tomography (CT) and magnetic

resonance imaging (MRI) are valuable tools for the visualization of inaccessible cardiac and thoracic structures and for the evaluation of extra-cardiac lesions. MRI assesses myocardial function comparably to echocardiography, and renders excellent contrast resolution allowing for the differentiation of tumor, myocardium, and pericardium (3).

We report a case of a cardiac mass in a patient with fairly unspecific symptoms. The mass was finally diagnosed as a metastasis from known cervical cancer 2 years after radical Wertheim's hysterectomy and

¹INSELSPITAL – Bern University Hospital, Bern, Switzerland

²University of Bern, Bern, Switzerland

Corresponding author:

Khoschy Schawkat, INSELSPITAL – Bern University Hospital, Freiburgstrasse 10, Bern, 3010 Switzerland.
Email: khoschy.schawkat@insel.ch



complete remission. The clinical and multimodal imaging assessment is described.

Case report

A 33-year-old woman with fever and mild left thoracic pain presented to our hospital emergency room.

She had been diagnosed with squamous cell carcinoma of the cervix (stage IIB) at the age of 31 years, and had undergone a multimodal therapy including radical Wertheim's hysterectomy and adjuvant radio-/chemotherapy.

Pulmonary and lymphatic recurrence had been diagnosed by a follow-up CT scan 1 year later. The metastasis in the right lower lobe and mediastinal lymph node metastases had been resected. Atypical thoracoscopic wedge resection of the left lower lobe had been performed 2 months later for resecting another pulmonary metastasis. No complications had occurred and the patient had been discharged.

In this admission the patient's respiratory sounds were decreased in the left lower lung field. The body temperature was 38°C. Heart sounds were normal without murmurs. The C-reactive protein was elevated to 70 mg/L.

A contrast-enhanced CT scan of the chest was performed to rule out infectious disease or pleuritis/pericarditis. CT images showed mediastinal and hilar lymphadenopathy, pericardial effusion, and mild left-sided pleural effusion. Furthermore, a mass within the left ventricle, a thickening of the apical myocardium, and enhancement of the adjacent pericardium were noted (Fig. 1a and b). Metastatic mass was detected on the previous metastasectomy site of posterior basal segment of left lower lobe (Fig. 2a and b).

MRI of the heart performed that same day showed an extensive cardiac mass. The mass infiltrated the ventricular septum and the adjacent walls of the left and right ventricle between mid-level and the apex. Short-axis cine images demonstrated hypo- and akinetic

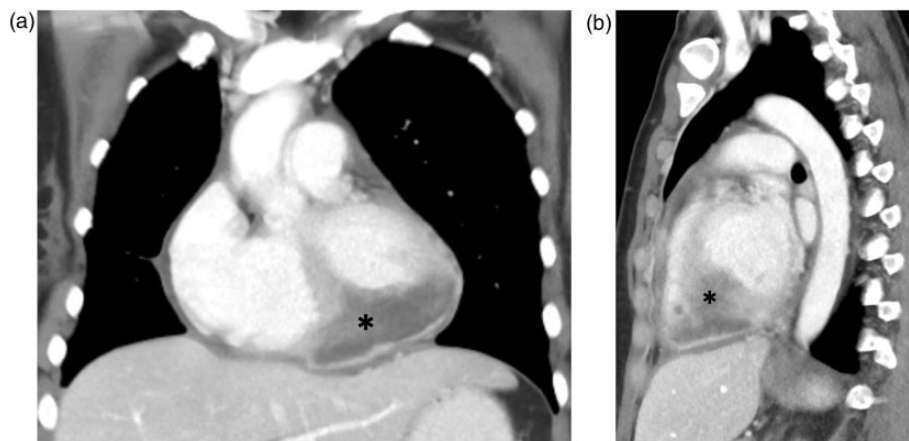


Fig. 1. Coronal (a) and sagittal (b) reconstructions of contrast-enhanced CT scan. Cardiac mass involves the inferior and septal part of the biventricular myocardium (black asterisks).

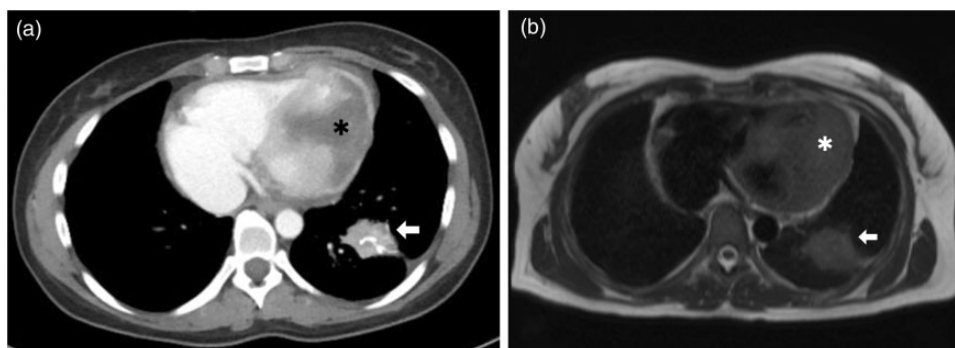


Fig. 2. Pulmonary metastasis within the left lower lobe (white arrows): (a) axial contrast-enhanced CT scan, and (b) axial T1-weighted MR image. The black asterisk in (a) and white asterisk in (b) point to the cardiac metastasis.

movement of the involved myocardium, while basal myocardium showed normal wall movement and normal systolic wall thickening (not shown here). Overall LV and RV function was not decreased. The mass remained hypointense during first-pass perfusion and demonstrated late gadolinium enhancement (Fig. 3a and b). No intraventricular thrombus was detected. Small amount of pericardial effusion, pericardial thickening, and contrast enhancement led to the suspicion of carcinomatous pericarditis.

Echocardiography showed the presence of an intracardiac mass in both ventricles and suspected also a mass at the left atrial level, close to the mitral valve. Valvular function was normal and transesophageal echocardiography was not suggestive of infective endocarditis of the mitral valve. There were no signs of hemodynamic significant pericardial effusion (Fig. 4a and b). Blood cultures that were taken 3 days in a

row after admission were negative. Electrocardiogram (ECG) showed ST-segment elevation in V3–V6.

Final diagnostic and therapeutic decision was made in a multidisciplinary setting: treatment for cardiac and pulmonary metastases from cervical cancer was limited to palliative chemotherapy since the lesion was unresectable, and for the high risk of myocardial rupture, palliative radiotherapy was precluded.

Discussion

The severity of clinical symptoms in patients with cardiac metastasis is variable and differs depending on the extent and the localization within the heart. Cardiac metastasis may cause medical emergencies or – more often – remain unrecognized until finally found during postmortem autopsy. In patients with history of malignancy, a late disease recurrence with cardiac

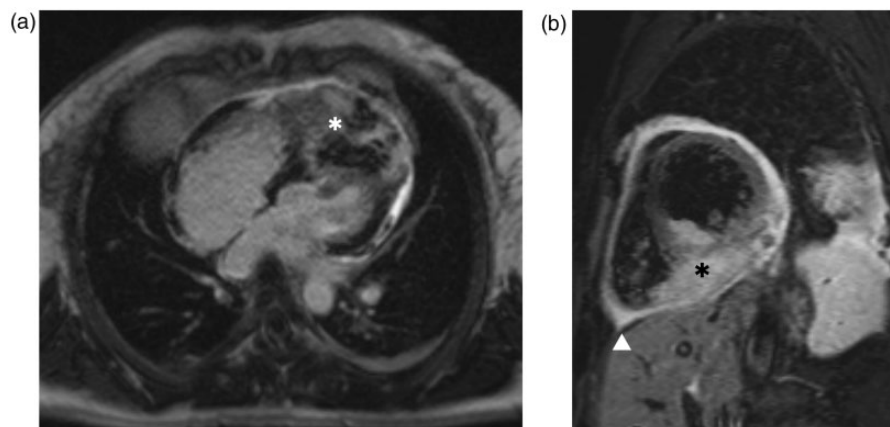


Fig. 3. Cardiac MRI: four-chamber view of delayed enhancement image (a) and short axis view of delayed enhancement image with black-blood technique (b). The cardiac mass infiltrated the right and left ventricular myocardium and cavities (asterisks). Images also show pericardial effusion and thickening (arrow head).

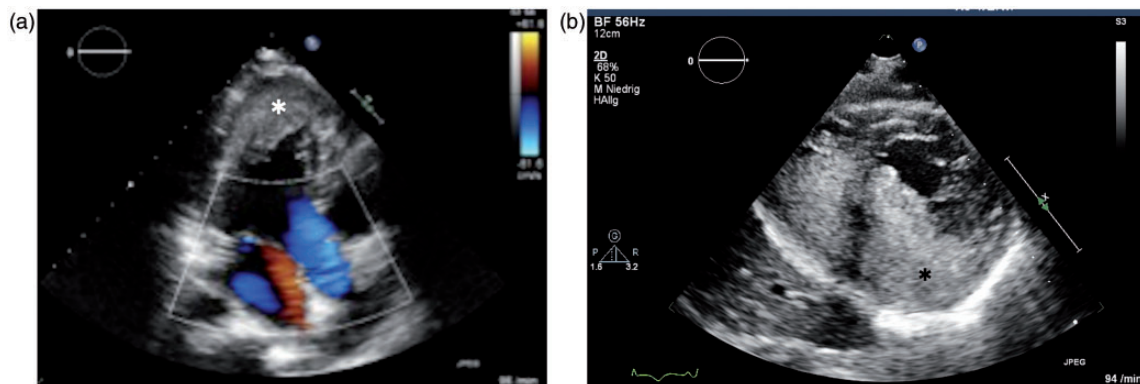


Fig. 4. Transthoracic echocardiography four chamber view (a) and subcostal view (b) shows cardiac mass infiltrating cardiac apex, septum, and biventricular cavities (asterisks).

Table 1. Literature review of case reports.

Authors	Year	Age	Stage	Chief complaint	Site of involvement	Interval to cardiac metastasis (years)	Primary treatment
Togo et al. (13)	2013	39	Ila	Nausea and vomiting	IVC-RA	1	C + OP
Nakao et al. (15)	2006	57	IIIb	Chest pain	IVC-RA	0.8	C + R
Ferraz et al. (8)	2005	63	•	Fatigue and dyspnea	RV-PA	33	C + R + OP
Iwaki et al. (12)	2001	49	•	Cough and low-grade fever	RV	0	C + R
Sergi et al. (14)	1999	50	Ila	Oliguria/anuria and shortness of breath	RA, LA, RV, LV	0.7	C + R + OP
Ando et al. (11)	1996	41	IIb	Slight dyspnea and abdominal pain	RV	0.8	R + OP

C, chemotherapy; IVC-RV, inferior vena cava into the right atrium; LA, left atrium; LV, left ventricle; OP, operation; R, radiotherapy; RA, right atrium; RV, right ventricle; •, not stated.

metastasis should be taken into account, even if clinical symptoms are mild and unspecific (4).

Extrapelvic metastases from recurrent cervical cancer typically occur in the lungs, liver, bones, and lymph nodes (5). The heart is rarely affected. Rare cardiac metastases most commonly originate from lung or breast cancer presumably due to their proximity to the heart (6,7). The incidence of cardiac metastasis of uterine cervix tumors has been shown in autopsy studies to be between 3–4% (8).

Most frequently, metastasis arise from retrograde regional lymphatic invasion through lymphatic channels in the mediastinum into the pericardium and epicardium (9). The small metastatic implants obstruct the lymphatic drainage of the visceral pericardium which contains most of the lymphatic channels resulting in pericardial effusion (3). Implantation of cancer fragments in the myocardium is less frequent. It is suggestive of hematogenous spread via the coronary arteries and is frequently accompanied by pulmonary metastasis.

Only a few reports exist about cardiac metastasis in recurring cervical cancer with an antemortem diagnosis. Inamura et al. reported a case of cardiac metastasis of recurrent cervical carcinoma after more than 3 years of complete remission (4). The patient presented with multiple pulmonary emboli, disseminated intravascular coagulation and right heart failure. Recently, Saitoh et al. presented a case of an isolated right ventricular metastasis of uterine cervical carcinoma after radiotherapy treatment (10). They suggest that patients with an intracardiac mass and history of uterine cervical cancer should be suspected of having a myocardial metastasis until proven otherwise. Ando et al., like us, incidentally found a suspect intracardial tumor in a patient with a history of carcinoma of the uterine cervix using imaging modalities (CT and MRI) (11).

We searched PubMed for similar cases of patients presenting with unspecific symptoms and incidental findings of cardiac metastasis from cervical cancer. Table 1 shows six comparable articles, in which all patients were aged 7–32 years older than our patient (8,12–15).

Recent publications recommend aggressive local and systemic treatment for palliation of associated symptoms in patients with cardiac metastasis from any primary tumor (3,4,16,17). In the present case, the patient was administered to palliative chemotherapy. The tumor is surgically not resectable. Palliative radiotherapy was not an option due to the high risk of transmyocardial rupture.

Multimodal imaging studies are key for early detection of cardiac metastasis.

Echocardiography is valuable and convenient for initial imaging in patients with potential risk of cancer recurrence and thoracic symptoms. In some patients, poor image quality limits its diagnostic value. MRI remains the modality of choice in the non-invasive evaluation of intrinsic myocardial abnormalities (18). CT provides superior spatial resolution and renders the assessment of extracardiac structures.

In conclusion, the diagnosis of cardiac metastasis may be missed due to only mild or non-specific symptoms and incomplete diagnostic work-up. A multimodal imaging approach including echocardiography, MRI, and CT may be favorable for early detection of cardiac metastasis in patients presenting with mild symptoms and a history of cervical cancer.

Conflict of interest

None declared.

References

1. Lam KY, Dickens P, Chan AC. Tumors of the heart. A 20-year experience with a review of 12,485 consecutive autopsies. *Arch Pathol Lab Med* 1993;117:1027–1031.
2. Roberts WC. Primary and secondary neoplasms of the heart. *Am J Cardiol* 1997;80:671–682.
3. Chiles C, Woodard PK, Gutierrez FR, et al. Metastatic involvement of the heart and pericardium: CT and MR imaging. *Radiographics* 2001;21:439–449.
4. Inamura K, Hayashida A, Kaji Y, et al. Recurrence of cervical carcinoma manifesting as cardiac metastasis three years after curative resection. *Am J Med Sci* 2004;328:167–169.
5. Kim HS, Park NH, Kang SB. Rare metastases of recurrent cervical cancer to the pericardium and abdominal muscle. *Arch Gynecol Obstet* 2008;278:479–482.
6. Burke A, Jeudy J Jr, Virmani R. Cardiac tumours: an update: Cardiac tumours. *Heart* 2008;94:117–123.
7. Glockner JF. Imaging of pericardial disease. *Magn Reson Imaging Clin N Am* 2003;11:149–162, vii.
8. Ferraz JG, Martins AL, de Souza JF, et al. Metastatic tumor of squamous cell carcinoma from uterine cervix to heart: ante-mortem diagnosis. *Arq Bras Cardiol* 2006;87:104–107.
9. Hancock EW. Neoplastic pericardial disease. *Cardiol Clin* 1990;8:673–682.
10. Saitoh Y, Aota M, Koike H, et al. Isolated right ventricular metastasis of uterine cervical carcinoma. *Jpn J Thorac Cardiovasc Surg* 2005;53:645–648.
11. Ando K, Kashihara K, Harada M, et al. Carcinoma of the uterine cervix with myocardial metastasis. *Gynecol Oncol* 1997;65:169–172.
12. Iwaki T, Kanaya H, Namura M, et al. Right ventricular metastasis from a primary cervical carcinoma. *Jpn Circ J* 2001;65:761–763.
13. Togo A, Muramatsu T, Tsukada H, et al. A case of metastatic uterine cervical squamous cell carcinoma in the right atrium. *Tokai J Exp Clin Med* 2013;38:42–45.
14. Sergi C, Magener A, Ehemann V, et al. Stage IIa cervix carcinoma with metastasis to the heart: report of a case with immunohistochemistry, flow cytometry, and virology findings. *Gynecol Oncol* 2000;76:133–138.
15. Nakao Y, Yokoyama M, Yasunaga M, et al. Metastatic tumor extending through the inferior vena cava into the right atrium: a case report of carcinoma of the uterine cervix with para-aortic lymph node metastases. *Int J Gynecol Cancer* 2006;16:914–916.
16. Lemus JF, Abdulhay G, Sobolewski C, et al. Cardiac metastasis from carcinoma of the cervix: report of two cases. *Gynecol Oncol* 1998;69:264–268.
17. Jamshed A, Khafaga Y, El-Husseiny G, et al. Pericardial metastasis in carcinoma of the uterine cervix. *Gynecol Oncol* 1996;61:451–453.
18. Restrepo CS, Largoza A, Lemos DF, et al. CT and MR imaging findings of malignant cardiac tumors. *Curr Probl Diagn Radiol* 2005;34:1–11.