

Brain-Derived Neurotrophic Factor Protects against Multiple Forms of Brain Injury in Bacterial Meningitis

Yoeng-Delphine Bifrare, Jürg Kummer, Philipp Joss, Martin G. Täuber, and Stephen L. Leib

Institute for Infectious Diseases, University of Bern, Bern, Switzerland

Background. Brain-derived neurotrophic factor (BDNF) blocks activation of caspase-3, reduces translocation of apoptosis-inducing factor (AIF), attenuates excitotoxicity of glutamate, and increases antioxidant enzyme activities. The mechanisms of neuroprotection suggest that BDNF may be beneficial in bacterial meningitis.

Methods. To assess a potentially beneficial effect of adjuvant treatment with BDNF in bacterial meningitis, 11-day-old infant rats with experimental meningitis due to *Streptococcus pneumoniae* or group B streptococci (GBS) were randomly assigned to receive intracisternal injections with either BDNF (3 mg/kg) or equal volumes (10 μ L) of saline. Twenty-two hours after infection, brains were analyzed, by histomorphometrical examination, for the extent of cortical and hippocampal neuronal injury.

Results. Compared with treatment with saline, treatment with BDNF significantly reduced the extent of 3 distinct forms of brain cell injury in this disease model: cortical necrosis in meningitis due to GBS (median, 0.0% [range, 0.0%–33.7%] vs. 21.3% [range, 0.0%–55.3%]; $P < .03$), caspase-3-dependent cell death in meningitis due to *S. pneumoniae* (median score, 0.33 [range, 0.0–1.0] vs. 1.10 [0.10–1.56]; $P < .05$), and caspase-3-independent hippocampal cell death in meningitis due to GBS (median score, 0 [range, 0–2] vs. 0.88 [range, 0–3.25]; $P < .02$). The last form of injury was associated with nuclear translocation of AIF.

Conclusion. BDNF efficiently reduces multiple forms of neuronal injury in bacterial meningitis and may hold promise as adjunctive therapy for this disease.

Despite improved antibiotic treatment, bacterial meningitis remains a devastating disease, with mortality of up to 30% [1, 2]. The long-term sequelae of bacterial meningitis are common and include hearing loss, seizures, sensory-motor deficits, and impairment of learning and memory [3, 4]. A follow-up study of children revealed that, as late as 12 years after recovery from bacterial meningitis, significant neurological and intellectual impairments persisted [5]. Streptococcal pneumonia is consistently associated with a particularly high

incidence of neurological sequelae, with up to half of the survivors presenting some form of neurological sequelae [6, 7].

In humans and in experimental animal models, bacterial meningitis causes neuronal injury to the cortical and subcortical regions [8–11]. Three distinct forms of neuronal cell death have been documented. In the cortex, neurons undergo ischemic damage, leading to cellular necrosis in the ischemic core and to caspase-3-dependent cell death in the penumbra [12–15]. Two different forms of cell death have been identified in the dentate gyrus of the hippocampus, a region important for learning and memory: classic caspase-3-dependent cell death (i.e., apoptosis) primarily affects the subgranular zone containing recently divided immature neurons, whereas caspase-3-independent cell death (i.e., pyknosis) occurs throughout the dentate granular cell layer, affecting both mature and immature neurons [16].

Neurotrophins, a family of the neurotrophic factors, control neuronal cell death in development and play an important role in neuronal differentiation and sur-

Received 3 May 2004; accepted 13 July 2004; electronically published 1 December 2004.

Presented in part: annual meeting of the Swiss Society for Infectious Diseases, Basel, Switzerland, 6–7 March 2003 (abstract P52).

Financial support: Swiss National Science Foundation (grants 632-66057.01 and 3235-66256.01); National Institutes of Health (grant NS-35902).

Reprints or correspondence: Dr. Stephen L. Leib, Institute for Infectious Diseases, University of Bern, Friedbühlstr. 51, PO Box 61, 3010 Bern, Switzerland (stephen.leib@ifik.unibe.ch).

The Journal of Infectious Diseases 2005;191:40–5

© 2004 by the Infectious Diseases Society of America. All rights reserved. 0022-1899/2005/19101-0007\$15.00

vival [12–15]. Brain-derived neurotrophic factor (BDNF) is of particular interest, since its receptor (trkB) is found in a broad range of neuronal cell types and is highly expressed in the hippocampus. Because of its neuroprotective effects, BDNF holds promise as a treatment for diseases of the central nervous system (CNS). In several studies of ischemic-hypoxic injury, BDNF exhibited marked antiapoptotic effects by blocking activation of caspase-3 [17, 18]. Furthermore, BDNF attenuated the nuclear translocation of apoptosis-inducing factor (AIF) [19], which can be a mediator of caspase-3-independent cell death.

Given the neuroprotective effect of administration of BDNF in various models of neuronal injury, we decided to evaluate the neuroprotective effect of BDNF in experimental meningitis, using a well-characterized infant rat model that mimics important features of the human disease and exhibits all 3 forms of neuronal injury associated with bacterial meningitis [15, 16, 20–23]. We took advantage of the fact that the extent of the various forms of injury depends on the infecting pathogen. Bacterial meningitis due to *Streptococcus pneumoniae* primarily induces apoptosis and, to a much lesser extent, pyknosis, whereas the reverse is true for meningitis due to group B streptococci (GBS) [16]. Thus, depending on the form of injury investigated, we used one or the other infecting pathogen to examine the effect of adjuvant administration of BDNF. The effect of BDNF on apoptotic cell death in the dentate gyrus of the hippocampus was analyzed by use of *S. pneumoniae* as the infecting pathogen, whereas its effect on caspase-3-independent cell death and cortical necrosis was analyzed by use of GBS as the infecting pathogens.

MATERIALS AND METHODS

Infecting pathogens. To maximize the extent of the various forms of neuronal injury, we used a type III GBS isolate to examine cortical necrosis and caspase-3-independent cell death in the dentate gyrus and a serotype 3 *S. pneumoniae* isolate to examine hippocampal apoptotic cell death. Both organisms were initially isolated from patients with bacterial meningitis and had been passaged repeatedly through animals. The organisms were grown on blood-agar plates, cultured overnight in 10 mL of brain-heart infusion medium, diluted in fresh medium, and grown for 6 h to logarithmic phase. The culture broth was centrifuged for 10 min at 5000 g, pelleted, resuspended in sterile saline to the desired density, and used for intracisternal injection. The accuracy of the inoculum size was confirmed by quantitative cultures.

Model of meningitis. The animal studies were approved by the Animal Care and Experimentation Committee of the Canton of Bern, Switzerland, and followed National Institutes of Health guidelines for the performance of animal experiments. Nursing Sprague-Dawley rat pups ($n = 60$) were infected on

postnatal day 11 by intracisternal injection of 10 μ L of saline containing either *S. pneumoniae* (\log_{10} 7.5 ± 0.4 cfu/mL; $n = 20$) or GBS (\log_{10} 7.6 ± 0.9 cfu/mL; $n = 40$). Infected rats were randomized for repeated intracisternal injections of either 3 mg/kg BDNF per dose (provided by Regeneron Pharmaceuticals) or equal volumes (10 μ L) of saline at 0, 6, 12, 15, 18, and 21 h after infection. Eighteen hours after intracisternal injection, rats were weighed and assessed clinically, as described elsewhere [24]. To document meningitis, 10 μ L of cerebrospinal fluid (CSF) was obtained by puncture of the cisterna magna and was cultured quantitatively by serial dilutions. Infected rats then received 1 subcutaneous injection of 100 mg/kg ceftriaxone (Roche Pharma).

Histopathological examination. For histopathological examination, rats were killed 22 ± 0.5 h (mean \pm SD) after infection. Rats that died spontaneously or that had to be killed for ethical reasons before 21 h after infection were not included ($n = 19$). After perfusion with 4% paraformaldehyde in PBS, 12 coronal sections from the frontal, middle, and dorsal brain region were mounted on polylysine-coated slides and Nissl stained with cresyl blue. Forty-one rats were evaluated for cortical and hippocampal injury: 9 were infected with *S. pneumoniae* and treated with saline, 7 were infected with *S. pneumoniae* and treated with BDNF, 14 were infected with GBS and treated with saline, and 11 were infected with GBS and treated with BDNF.

Cortical necrosis, defined as areas of reduced neuronal density with neurons displaying morphological features of necrosis, including cell swelling and loss of cytoarchitecture (figure 1A), was assessed as a percentage of total cortex, and a mean percentage per rat was calculated from all evaluated sections [25]. In the dentate gyrus of the hippocampus, the extent of neuronal injury was scored by use of bright-field microscopy. Pyknosis, which is characterized morphologically by uniformly shrunken nuclei, forming clusters of damaged cells predominantly in the lower blade of the dentate granule cell layer (figure 1B), was assessed in the 4 blades of the structure and, if present, was scored as 1 point for each blade (maximum, 4 points/section) [16]. The median score for each rat was calculated from all sections evaluated. For apoptosis, cells with morphological features of apoptosis (condensed, fragmented nuclei and apoptotic bodies) (figure 1C) were counted in 3 visual fields (magnification, $\times 400$) in each of the 4 blades of the dentate gyrus, and the following scoring system was applied for the count in each blade: 0–5 cells, 0; 6–20 cells, 1; and >20 cells, 2 [15]. The median score per rat was calculated from all sections evaluated. All histopathological examinations were performed by an investigator who was unaware of the clinical, microbiological, and treatment data for the respective rat.

Immunohistochemical analysis. For immunohistochemical analysis, rats were killed and perfused with PBS, and their brains

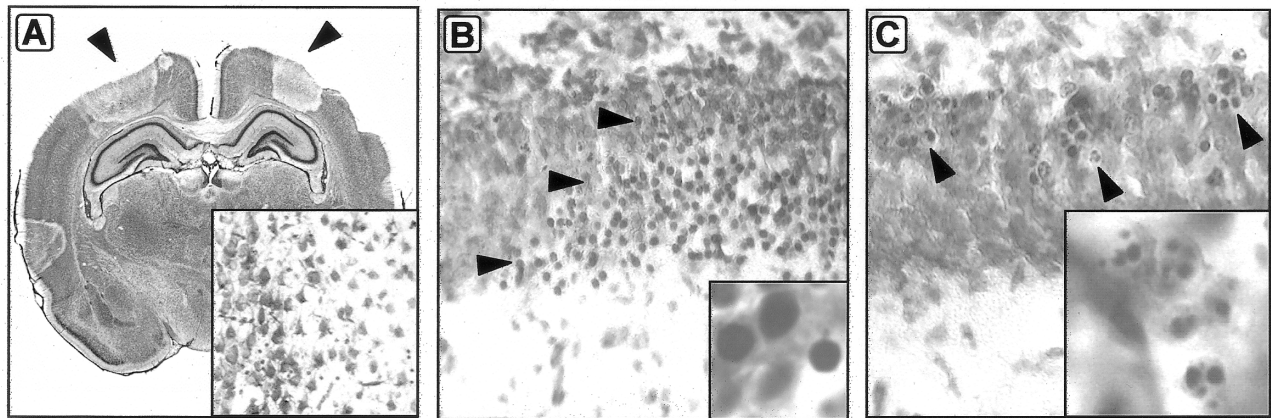


Figure 1. Brain histological examination of the cortex (A) and the dentate gyrus (B and C) in infant rats with bacterial meningitis. A, In the cerebral cortex, necrotic neuronal loss is present in a wedge-shaped pattern (arrowheads). Insert, Areas of cortical necrosis (right side) are sharply demarcated from unaffected areas (left side) and show reduced neuronal density and neurons with morphological features of necrosis, including cell swelling, loss of cellular demarcation, and fading of cytoarchitecture (original magnification, $\times 400$; cresyl violet staining). B, Pyknosis in the dentate gyrus of the hippocampus, containing clustered cells with dense and shrunken nuclei (see insert for magnification $\times 1200$), spanning the entire blade of the dentate gyrus (arrowheads). The lower blade was consistently more severely affected than the upper blade (original magnification, $\times 400$; cresyl violet staining). C, Apoptosis in the subgranular zone. Neurons with condensed and fragmented nuclei (see insert for magnification $\times 1200$) are scattered along the subgranular zone (arrowheads) (original magnification, $\times 400$; cresyl violet staining).

were embedded in paraffin. Two-micrometer sections were cut, mounted, deparaffinized, and hydrated. The sections were rinsed with PBS, incubated overnight at 4°C with the primary antibody for AIF (provided by G. Kroemer, Institut Gustave Roussy, France), and diluted 1:200 in antibody buffer (1/1 [vol/vol] 0.5% bovine serum albumin in PBS and 0.5 mol/L Tris buffer [pH 7.6] in 0.88% NaCl). Sections were then washed in PBS and incubated for 1 h at room temperature with the secondary antibody (Alexa Fluor 488; Molecular Probe), diluted 1:1000 in antibody buffer. Nuclei were counterstained with 4'-6-diamidino-2-phenylindole (DAPI).

Statistical methods. The clinical parameters were compared by use of the unpaired Student's *t* test. Neuronal injury was analyzed by use of the Mann-Whitney *U* test. $P < .05$ was considered to be significant.

RESULTS

Characteristics of disease. Eighteen hours after infection, all rats had documented meningitis, with lethargy and positive bacterial cultures in CSF. Compared with treatment with saline, treatment with BDNF had no effect on CSF bacterial titers, clinical score, or survival (table 1). However, rats treated with BDNF lost significantly more weight than did rats treated with saline (table 1). This increased weight loss was presumably due to the appetite suppression known to be associated with central application of BDNF [26].

Effect of treatment with BDNF on cortical necrosis. The effect of treatment with BDNF on ischemic cortical necrosis was evaluated in rats infected with GBS. Among infected, saline-treated rats, 11 of 14 showed necrosis (median, 21.3%; range,

Table 1. Effect of treatment with brain-derived neurotrophic factor (BDNF) on cerebrospinal fluid (CSF) bacterial titers, weight loss, activity score, and mortality in rats with meningitis due to group B streptococci (GBS) or *Streptococcus pneumoniae*.

Pathogen, treatment	CSF bacterial titer, \log_{10} cfu/mL	Weight loss, g	Activity score	Mortality, %
GBS				
Saline ($n = 22$)	7.8 ± 0.9	0.4 ± 0.5	3.9 ± 0.5	36
BDNF ($n = 18$)	7.3 ± 0.7	1.6 ± 1.0^a	3.8 ± 0.5	50
<i>S. pneumoniae</i>				
Saline ($n = 10$)	7.6 ± 0.2	0.5 ± 0.5	3.9 ± 0.2	10
BDNF ($n = 10$)	7.5 ± 0.5	1.7 ± 0.3^a	3.8 ± 0.3	30

NOTE. Data are mean \pm SD, except where noted. CSF titers, weight loss, and activity score were evaluated 18 h after infection. Mortality was evaluated within 22 h after infection.

^a $P < .05$.

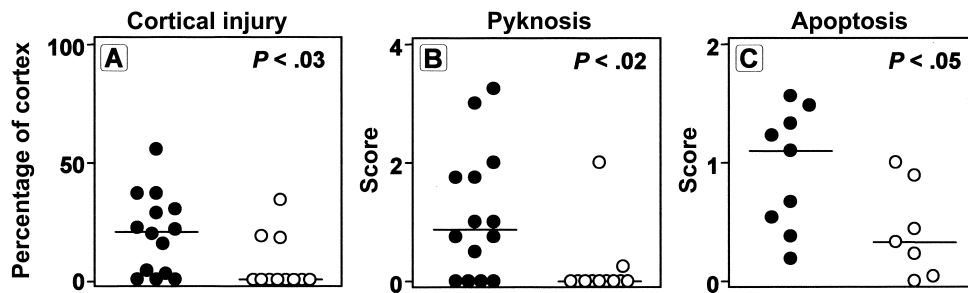


Figure 2. Histomorphometrical analysis of neuronal injury in rats with experimental meningitis treated with saline (●) or brain-derived neurotrophic factor (BDNF; ○). The bar represents the median value in each group (A–C). BDNF significantly attenuated cortical necrosis (A) and caspase-3-independent hippocampal cell death (B) in meningitis due to group B streptococci and caspase-3-dependent apoptosis (C) in meningitis due to *Streptococcus pneumoniae*.

0.0%–55.3%). The appearance of cortical injury was characteristic of the patterns described previously in this model [21–23], with focal, often wedge-shaped areas of neuronal loss (figure 1A). Treatment with BDNF significantly ($P < .03$) reduced the incidence and extent of cortical injury (figure 2A). Only 3 of 11 infected, BDNF-treated rats had cortical injury (median 0.0%; range, 0.0%–33.7%).

Effect of treatment with BDNF on caspase-3-independent cell death in the hippocampus. Caspase-3-independent cell death in the hippocampus has previously been reported to be associated primarily with GBS infection [16]. Accordingly, the effect of BDNF on this form of injury was assessed in the rats infected with GBS. Among infected, saline-treated rats, 10 (71%) of 14 showed evidence of this form of neuronal injury, with a median score of 0.88 (range, 0–3.25). Treatment with BDNF significantly reduced this form of hippocampal cell death, with only 2 (19%) of 11 infected, BDNF-treated rats showing neuronal damage, with a median score of 0 (range, 0–2) ($P < .02$) (figure 2B).

Nuclear translocation of AIF in caspase-3-independent cell

death. The nature of the caspase-3-independent cell death in this model of meningitis due to GBS has not been clarified [16]. Previous studies have suggested that, in bacterial meningitis, some forms of neuronal injury in the hippocampus may be associated with nuclear translocation of AIF [27]. Since BDNF can block nuclear translocation of AIF [19] and since it was effective in reducing caspase-3-independent cell death in the present study, we reasoned that this form of injury may be associated with nuclear translocation of AIF. Staining for AIF by use of fluorescent immunohistochemical analysis documented the presence of AIF in the cytoplasm of normally appearing cells in the dentate gyrus. In contrast, in cells that, by DAPI staining, showed evidence of injury (i.e., condensed, shrunken, and rounded nuclei), AIF was consistently localized to the nucleus (figure 3). Thus, the pyknotic form of hippocampal neuronal injury in bacterial meningitis is associated with nuclear translocation of AIF, and BDNF prevents this form of injury, presumably by inhibiting nuclear translocation of AIF.

Effect of therapy with BDNF on hippocampal apoptosis. Caspase-3-dependent apoptosis was evaluated in the model of

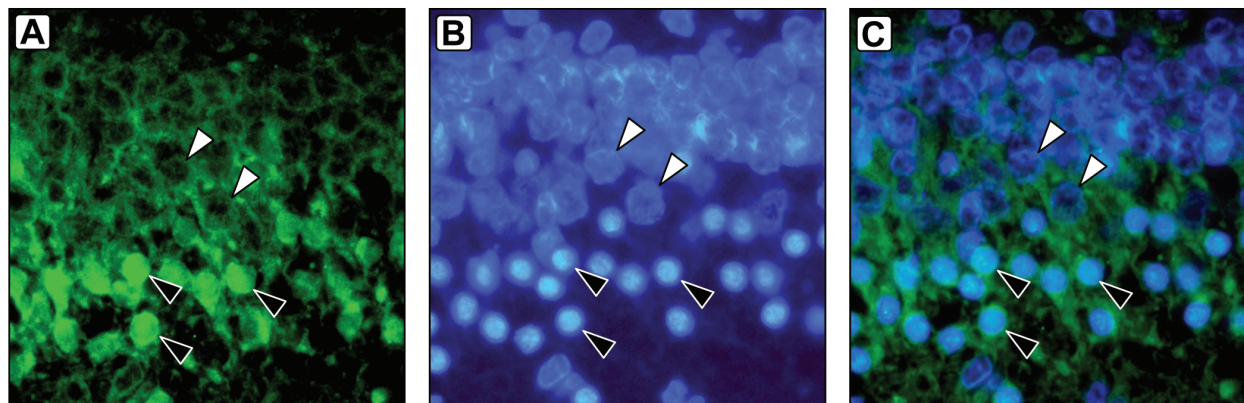


Figure 3. Immunohistochemical analysis of apoptosis-inducing factor (AIF) in meningitis due to group B streptococci in the hippocampal dentate gyrus (A). B, Counterstaining with 4'-6-diamidino-2-phenylindole; C, merged picture. In healthy neurons, AIF is located in the cytoplasm (white arrowheads), whereas, in pyknotic cells, AIF is clearly translocated into the nucleus (black arrowheads) (fluorescence imaging, magnification $\times 600$).

meningitis due to *S. pneumoniae*. As reported elsewhere [16], infection with *S. pneumoniae* consistently led to cells showing apoptotic morphological features in the subgranular zone of the dentate gyrus. In rats infected with *S. pneumoniae* and treated with saline, the median score of apoptotic neurons was 1.10 (range, 0.08–1.56). Treatment with BDNF significantly reduced the extent of this form of injury (median score, 0.33; range, 0.0–1.0; $P < .05$) (figure 2C).

DISCUSSION

Since the discovery of the potent survival-promoting effects of neurotrophic factors, there has been the hope that they can be used successfully in treating diseases of the CNS. BDNF is of particular interest in this regard, since its receptor (trkB) is expressed in a broad range of neurons throughout the brain [28], which is a prerequisite for a beneficial effect in diseases affecting multiple regions of the brain, as is the case in bacterial meningitis. Several studies have demonstrated the beneficial effect of BDNF in treating ischemia, trauma, and excitotoxicity [17, 18, 29, 30]. In the present study, we have demonstrated that adjuvant therapy with BDNF in experimental bacterial meningitis protects the brain from 3 distinct forms of injury: necrosis affecting the cortex and caspase-3–dependent and –independent cell death in the hippocampal dentate gyrus.

Bacterial meningitis causes wedge-shaped lesions in the cortex, defined by neuronal loss and morphological features of cellular necrosis (cell swelling and fading of cytoarchitecture) [25]. The results of several experimental studies have supported the importance of ischemia as a central mechanism in cortical necrosis. For example, inhibition of the endogenous vasoconstrictors endothelins with a nonselective receptor antagonist (bosentan) protected infant rats with pneumococcal meningitis from a reduction in cerebral blood flow and simultaneously reduced cortical injury [25]. Along the same line, inhibition of the production of the vasodilative nitric oxide with an inhibitor of inducible nitric oxide synthase (aminoguanidine) reduced cerebral blood flow and increased cortical necrotic damage [31].

The mechanisms by which BDNF protects from ischemic injury in bacterial meningitis are not clear. Cellular calcium overload plays a role in a variety of CNS insults, particularly in conjunction with excitatory amino acids (EAAs) [32]. BDNF can enhance the binding capacity of intracellular calcium and thereby increase cell survival [33]. In bacterial meningitis, levels of EAAs are increased in interstitial brain fluid [34], and an antagonist of neuronal EAA receptors (kynurenic acid) attenuates cortical injury [22]. Thus, by neutralizing the potentially detrimental effects of increased intracellular calcium, BDNF may preserve neurons from necrosis.

A further possible explanation for the beneficial effect of BDNF in experimental meningitis may be related to its ability to increase

antioxidant enzyme activities and thus attenuate the harmful effects of reactive oxygen species [30]. Adjuvant antioxidants reduce cortical injury in models of bacterial meningitis, possibly through preservation of cerebral blood flow [21, 35].

In the hippocampus, bacterial meningitis causes caspase-3–dependent apoptosis of neurons, including recently divided immature neurons located in the subgranular zone of the dentate gyrus [15, 16]. In a neonatal hypoxia-ischemia model, BDNF has been shown to be protective against caspase-3–dependent cell death by blocking activation of caspase-3 through the trkB receptor [18]. Interestingly, this receptor, which mediates progenitor cell survival and neurogenesis, is expressed in the same region where caspase-3–dependent cell death affects progenitor cells in meningitis [16]. The inhibitory activity of BDNF on caspase-3–mediated proapoptotic pathways is likely responsible for its beneficial effect on caspase-3–dependent cell death in the present study.

Pyknosis (i.e., caspase-3–independent cell death) is distinct from apoptosis (i.e., caspase-3–dependent cell death) and is characterized by cell clusters with dense and shrunken nuclei that are TUNEL negative and fail to express activated caspase-3 [16]. In the present study, we found that BDNF also protected against this form of injury. The beneficial effect of BDNF on caspase-3–independent cell death has been documented in a model of retinal detachment in rats, in which cell death was shown to be induced by the translocation of AIF into the nucleus [19]. Furthermore, a recent study analyzing caspase-3–independent cell death documented that nuclear translocation of AIF was triggered by glucose deprivation and ischemia, conditions that frequently affect the brain during meningitis [36]. We therefore explored whether nuclear translocation of AIF occurred in our model of meningitis due to GBS [16, 27]. Indeed, pyknotic cells in the dentate gyrus consistently showed immunocytochemical evidence of AIF in the nucleus. This result suggests that the protective effect of BDNF against pyknosis seen in the present model of bacterial meningitis is related to its capacity to interfere with nuclear translocation of AIF.

In conclusion, BDNF is neuroprotective against 3 distinct forms of neuronal cell injury in bacterial meningitis. These findings are of particular interest in light of recent findings that production of BDNF increases during meningitis at both the transcriptional and translational level, whereas treatment with antibiotics reduces production of BDNF [37]. It thus appears that BDNF is part of an endogenous protective pathway during meningitis and that external administration in parallel to antibiotic treatment of bacterial meningitis has the potential to reduce neuronal cell injury and, possibly, long-term neurological sequelae.

References

- Schuchat A, Robinson K, Wenger JD, et al. Bacterial meningitis in the United States in 1995. Active Surveillance Team. *N Engl J Med* **1997**; 337:970–6.
- Harvey D, Holt DE, Bedford H. Bacterial meningitis in the newborn: a prospective study of mortality and morbidity. *Semin Perinatol* **1999**; 23:218–25.
- Bedford H, de Louvois J, Halket S, Peckham C, Hurley R, Harvey D. Meningitis in infancy in England and Wales: follow up at age 5 years. *BMJ* **2001**; 323:533–6.
- Grimwood K, Anderson VA, Bond L, et al. Adverse outcomes of bacterial meningitis in school-age survivors. *Pediatrics* **1995**; 95:646–56.
- Grimwood K, Anderson P, Anderson V, Tan L, Nolan T. Twelve year outcomes following bacterial meningitis: further evidence for persisting effects. *Arch Dis Child* **2000**; 83:111–6.
- van de Beek D, Schmand B, de Gans J, et al. Cognitive impairment in adults with good recovery after bacterial meningitis. *J Infect Dis* **2002**; 186:1047–52.
- Merkelbach S, Sittinger H, Schweizer I, Muller M. Cognitive outcome after bacterial meningitis. *Acta Neurol Scand* **2000**; 102:118–23.
- Free SL, Li LM, Fish DR, Shorvon SD, Stevens JM. Bilateral hippocampal volume loss in patients with a history of encephalitis or meningitis. *Epilepsia* **1996**; 37:400–5.
- Nau R, Soto A, Bruck W. Apoptosis of neurons in the dentate gyrus in humans suffering from bacterial meningitis. *J Neuropathol Exp Neurol* **1999**; 58:265–74.
- Leib SL, Kim YS, Chow LL, Sheldon RA, Täuber MG. Reactive oxygen intermediates contribute to necrotic and apoptotic neuronal injury in an infant rat model of bacterial meningitis due to group B streptococci. *J Clin Invest* **1996**; 98:2632–9.
- Zysk G, Bruck W, Gerber J, Bruck Y, Prange HW, Nau R. Anti-inflammatory treatment influences neuronal apoptotic cell death in the dentate gyrus in experimental pneumococcal meningitis. *J Neuropathol Exp Neurol* **1996**; 55:722–8.
- Horch HW, Kruttgen A, Portbury SD, Katz LC. Destabilization of cortical dendrites and spines by BDNF. *Neuron* **1999**; 23:353–64.
- Huang EJ, Reichardt LF. Neurotrophins: roles in neuronal development and function. *Annu Rev Neurosci* **2001**; 24:677–736.
- Bibel M, Barde YA. Neurotrophins: key regulators of cell fate and cell shape in the vertebrate nervous system. *Genes Dev* **2000**; 14:2919–37.
- Gianinazzi C, Grandgirard D, Imboden H, et al. Caspase-3 mediates hippocampal apoptosis in pneumococcal meningitis. *Acta Neuropathol (Berl)* **2003**; 105:499–507.
- Bifrare YD, Gianinazzi C, Imboden H, Leib SL, Täuber MG. Bacterial meningitis causes two distinct forms of cellular damage in the hippocampal dentate gyrus in infant rats. *Hippocampus* **2003**; 13:481–8.
- Han BH, D'Costa A, Back SA, et al. BDNF blocks caspase-3 activation in neonatal hypoxia-ischemia. *Neurobiol Dis* **2000**; 7:38–53.
- Han BH, Holtzman DM. BDNF protects the neonatal brain from hypoxic-ischemic injury in vivo via the ERK pathway. *J Neurosci* **2000**; 20:5775–81.
- Hisatomi T, Sakamoto T, Murata T, et al. Relocalization of apoptosis-inducing factor in photoreceptor apoptosis induced by retinal detachment in vivo. *Am J Pathol* **2001**; 158:1271–8.
- Leib SL, Heimgartner C, Bifrare YD, Loeffler JM, Täuber MG. Dexamethasone aggravates hippocampal apoptosis and learning deficiency in pneumococcal meningitis in infant rats. *Pediatr Res* **2003**; 54:353–7.
- Leib SL, Kim YS, Chow LL, Sheldon RA, Täuber MG. Reactive oxygen intermediates contribute to necrotic and apoptotic neuronal injury in an infant rat model of bacterial meningitis due to group B streptococci. *J Clin Invest* **1996**; 98:2632–9.
- Leib SL, Kim YS, Ferriero DM, Täuber MG. Neuroprotective effect of excitatory amino acid antagonist kynurenic acid in experimental bacterial meningitis. *J Infect Dis* **1996**; 173:166–71.
- Leib SL, Kim YS, Black SM, Tureen JH, Täuber MG. Inducible nitric oxide synthase and the effect of aminoguanidine in experimental neonatal meningitis. *J Infect Dis* **1998**; 177:692–700.
- Leib SL, Clements JM, Lindberg RL, et al. Inhibition of matrix metalloproteinases and tumour necrosis factor α converting enzyme as adjuvant therapy in pneumococcal meningitis. *Brain* **2001**; 124:1734–42.
- Pfister L-A, Tureen JH, Shaw S, et al. Endothelin inhibition improves cerebral blood flow and is neuroprotective in pneumococcal meningitis. *Ann Neurol* **2000**; 47:329–35.
- Pelleymounter MA, Cullen MJ, Wellman CL. Characteristics of BDNF-induced weight loss. *Exp Neurol* **1995**; 131:229–38.
- Braun JS, Novak R, Murray PJ, et al. Apoptosis-inducing factor mediates microglial and neuronal apoptosis caused by pneumococcus. *J Infect Dis* **2001**; 184:1300–9.
- Yan Q, Rosenfeld RD, Matheson CR, et al. Expression of brain-derived neurotrophic factor protein in the adult rat central nervous system. *Neuroscience* **1997**; 78:431–48.
- Zou J, Bretlau P, Pyrkko I, et al. Comparison of the protective efficacy of neurotrophins and antioxidants for vibration-induced trauma. *ORL J Otorhinolaryngol Relat Spec* **2003**; 65:155–61.
- Galvin KA, Oorschot DE. Continuous low-dose treatment with brain-derived neurotrophic factor or neurotrophin-3 protects striatal medium spiny neurons from mild neonatal hypoxia/ischemia: a stereological study. *Neuroscience* **2003**; 118:1023–32.
- Leib SL, Kim YS, Black SM, Tureen JH, Täuber MG. Inducible nitric oxide synthase and the effect of aminoguanidine in experimental neonatal meningitis. *J Infect Dis* **1998**; 177:692–700.
- Leib SL, Kim YS, Ferriero DM, Täuber MG. Neuroprotective effect of excitatory amino acid antagonist kynurenic acid in experimental bacterial meningitis. *J Infect Dis* **1996**; 173:166–71.
- Ventimiglia R, Mather PE, Jones BE, Lindsay RM. The neurotrophins BDNF, NT-3 and NT-4/5 promote survival and morphological and biochemical differentiation of striatal neurons in vitro. *Eur J Neurosci* **1995**; 7:213–22.
- Guerra-Romero L, Tureen JH, Fournier MA, Makrides V, Täuber MG. Amino acids in cerebrospinal and brain interstitial fluid in experimental pneumococcal meningitis. *Pediatr Res* **1993**; 33:510–3.
- Auer M, Pfister LA, Leppert D, Täuber MG, Leib SL. Effects of clinically used antioxidants in experimental pneumococcal meningitis. *J Infect Dis* **2000**; 182:347–50.
- Cao G, Clark RS, Pei W, et al. Translocation of apoptosis-inducing factor in vulnerable neurons after transient cerebral ischemia and in neuronal cultures after oxygen-glucose deprivation. *J Cereb Blood Flow Metab* **2003**; 23:1137–50.
- Li L, Shui QX, Zhao ZY. Regulation of brain-derived neurotrophic factor (BDNF) expression following antibiotic treatment of experimental bacterial meningitis. *J Child Neurol* **2003**; 18:828–34.