

Transesophageal Echocardiography in Cryptogenic Stroke and Patent Foramen Ovale

Analysis of Putative High-Risk Features From the Risk of Paradoxical Embolism Database

Benjamin S. Wessler, MD; David E. Thaler, MD, PhD; Robin Ruthazer, MPH;
Christian Weimar, MD; Marco R. Di Tullio, MD; Mitchell S.V. Elkind, MD, MS;
Shunichi Homma, MD; Jennifer S. Lutz, MS; Jean-Louis Mas, MD; Heinrich P. Mattle, MD;
Bernhard Meier, MD; Krassen Nedelchev, MD; Federica Papetti, MD;
Emanuele Di Angelantonio, MD, MSc, PhD; Mark Reisman, MD; Joaquín Serena, MD, PhD;
David M. Kent, MD, CM, MSc

Background—Patent foramen ovale (PFO) is associated with cryptogenic stroke (CS), although the pathogenicity of a discovered PFO in the setting of CS is typically unclear. Transesophageal echocardiography features such as PFO size, associated hypermobile septum, and presence of a right-to-left shunt at rest have all been proposed as markers of risk. The association of these transesophageal echocardiography features with other markers of pathogenicity has not been examined.

Methods and Results—We used a recently derived score based on clinical and neuroimaging features to stratify patients with PFO and CS by the probability that their stroke is PFO-attributable. We examined whether high-risk transesophageal echocardiography features are seen more frequently in patients more likely to have had a PFO-attributable stroke ($n=637$) compared with those less likely to have a PFO-attributable stroke ($n=657$). Large physiologic shunt size was not more frequently seen among those with probable PFO-attributable strokes (odds ratio [OR], 0.92; $P=0.53$). The presence of neither a hypermobile septum nor a right-to-left shunt at rest was detected more often in those with a probable PFO-attributable stroke (OR, 0.80; $P=0.45$; OR, 1.15; $P=0.11$, respectively).

Conclusions—We found no evidence that the proposed transesophageal echocardiography risk markers of large PFO size, hypermobile septum, and presence of right-to-left shunt at rest are associated with clinical features suggesting that a CS is PFO-attributable. Additional tools to describe PFOs may be useful in helping to determine whether an observed PFO is incidental or pathogenically related to CS. (*Circ Cardiovasc Imaging*. 2014;7:125-131.)

Key Words: cardiovascular imaging ■ cerebrovascular disease/stroke ■ congenital heart disease ■ echocardiography ■ foramen ovale, patent ■ risk factor

Patent foramen ovale (PFO) is associated with cryptogenic stroke (CS).¹ Despite this association, there is continued debate about the causal relationship of discovered PFOs in patients with CS.^{2,3} Numerous candidate

echocardiographic features have been proposed as high-risk features that make a PFO more likely to be causally linked to CS, including presence of a hypermobile atrial septum (or atrial septal aneurysm [ASA]),⁴ physiologic shunt size as measured by right-to-left microbubble count,⁵ and presence of a right-to-left shunt at rest (ie, without a Valsalva maneuver).⁶ Investigators have incorporated these potential

Editorial see p 5
Clinical Perspective on p 131

Received June 17, 2013; accepted October 22, 2013.

From the Division of Cardiology, Tufts Medical Center, Boston, MA (B.S.W.); Department of Neurology (D.E.T., D.M.K.), and Institute for Clinical Research and Health Policy Studies Predictive Analytics and Comparative Effectiveness Center, (R.R., J.S.L., D.M.K.), Tufts Medical Center/Tufts University School of Medicine, Boston, MA; Department of Neurology, University of Duisburg-Essen, Duisburg-Essen Germany (C.W.); Division of Cardiology (M.R.D.T., S.H.), and Departments of Neurology and Epidemiology (M.S.V.E.), Columbia University, New York, NY; Department of Neurology, Hôpital Sainte-Anne, Paris-Descartes University, Paris, France (J.-L.M.); Department of Neurology (H.P.M.), and Department of Cardiology, Swiss Cardiovascular Center (B.M.), Inselspital, University of Bern, Bern, Switzerland; Department of Neurology, Triemli Municipal Hospital, Zurich, Switzerland (K.N.); Department of Cardiology, “Sapienza” University of Rome, Rome, Italy (F.P.); Department of Public Health and Primary Care, University of Cambridge, Cambridge, United Kingdom (E.D.A.); Swedish Medical Center, Seattle, WA (M.R.); and Department of Neurology, Hospital Universitari Doctor Josep Trueta, Institut d’Investigació Biomèdica de Girona, Girona, Spain (J.S.).

The Data Supplement is available at <http://circimaging.ahajournals.org/lookup/suppl/doi:10.1161/CIRCIMAGING.113.000807/-/DC1>.

Correspondence to David M Kent, MD, CM, MSc, Institute for Clinical Research and Health Policy Studies, Tufts Medical Center, 800 Washington St, Box 63, Boston, MA 02111. E-mail Dkent1@tuftsmedicalcenter.org

© 2013 American Heart Association, Inc.

Circ Cardiovasc Imaging is available at <http://circimaging.ahajournals.org>

DOI: 10.1161/CIRCIMAGING.113.000807

high-risk parameters into routine echocardiographic analysis in an attempt to identify high-risk PFOs from incidentally discovered ones. Nevertheless, reports raise the possibility that these echocardiographic features are not clearly related to either CS or the risk of recurrence.^{3,7,8} This uncertainty adds to the debate about causality and raises questions about appropriate therapeutic approaches.⁹

We report an analysis from the Risk of Paradoxical Embolism (RoPE) database,¹⁰ a large observational database formed by combining 12 component databases of patients with CS and known PFO status. The rationale for the RoPE study has been previously described and builds on previous work demonstrating that overall summary trial results may not represent benefits for individual patients and that risk modeling may improve result interpretation.^{11,12} These issues are important for trial design and for treating patients because the likelihood that a CS event is attributable to an identified PFO is related to patient-specific factors, and PFO closure may not be beneficial for all patients with CS and PFO.^{13,14}

The RoPE score is a way to stratify patients with CS with respect to the (1) likelihood that a PFO would be present (before transesophageal echocardiography [TEE] evaluation), and (2) (related) probability that CS is attributable to an observed PFO.¹⁵ In brief, among patients with PFO and CS, younger patients, without conventional stroke risk factors or previous stroke and with a visible superficial lesion seen on neuroimaging, seem to be more likely to have a PFO-attributable CS. Using the RoPE score, we attempted to clarify the clinical significance of the major high-risk PFO echocardiographic features. Our hypothesis is that high-risk

echocardiographic features will be more prevalent in patients with probable PFO-associated CS and less prevalent in those with probable incidental PFOs.

Methods

The RoPE database has been described previously.^{10,16} Briefly, we combined 12 databases containing clinical, neuroimaging, and echocardiographic data of patients with CS who were investigated for PFO. The RoPE study includes patients with (n=1925) and without (n=1749) PFO (see Figure).¹⁷⁻²² CS was defined by the Trial of Org 10172 in Acute Stroke Treatment (TOAST) classification and was diagnosed within component databases.²³ As previously described,¹⁶ CS definition for this study specifically excluded patients with known stroke mechanisms, such as large artery atherosclerosis, cardioembolism, small vessel disease, or strokes of other causes, including arterial dissection or hypercoagulable states. Stroke was defined as the sudden onset of neurological deficit in a vascular territory, presumed to be due to focal ischemia after a comprehensive workup. If a deficit was present for <24 hours, it was considered a transient ischemic attack if there were no acute magnetic resonance imaging or computed tomography changes in appropriate locations. Patients underwent either TEE or transcranial Doppler for PFO detection. For this analysis, only patients evaluated with TEE (n=1324) were included. Component database variables were harmonized, and new data were collected when necessary and feasible. This study was approved by the Tufts Medical Center Internal Review Board.

The RoPE score is a prediction tool for determining the probability that an index CS is attributable to PFO (Table 1). For an individual, it may not be possible to identify with certainty whether a PFO is incidental or pathogenic. The 10-point RoPE score allows estimation of the attributable fraction for a PFO in the setting of CS. Attributable fraction is determined by the prevalence of PFO in patients with CS compared with that found in an otherwise similar group of patients without CS. Because PFO prevalence in CS patients is dependent on other patient characteristics,²⁴ a more patient-specific attributable

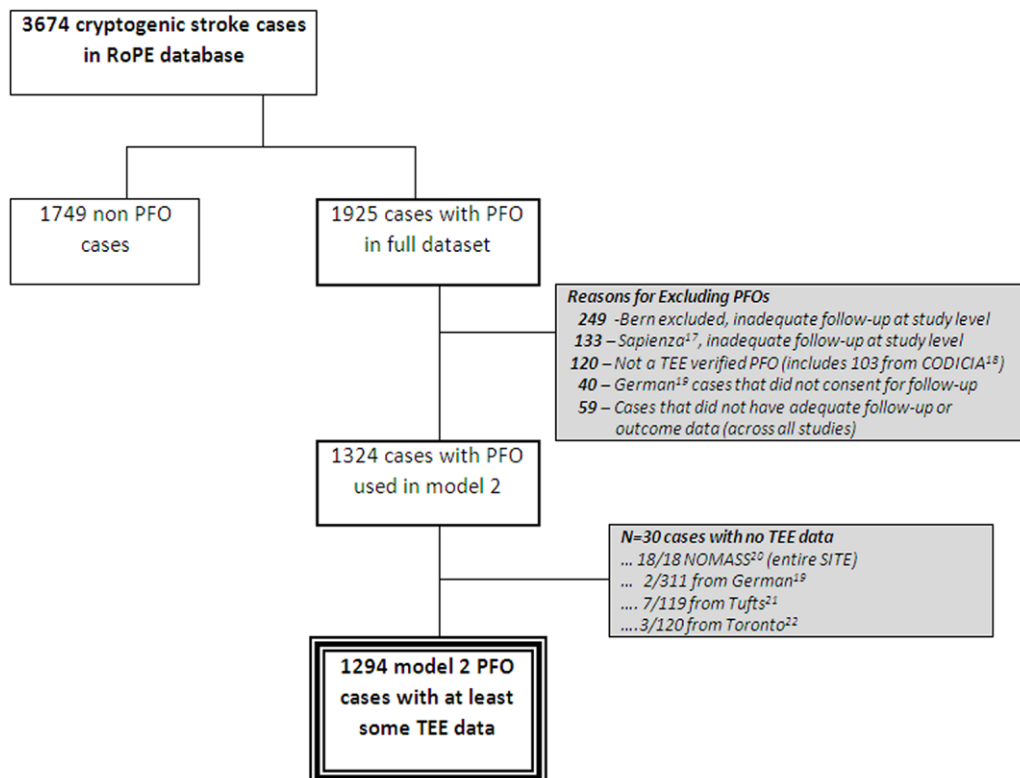


Figure. Cases included in transesophageal echocardiography analysis.

Table 1. RoPE Score Calculator

Characteristic Points	RoPE Score
No history of hypertension	1
No history of diabetes mellitus	1
No history of stroke or TIA	1
Nonsmoker	1
Cortical infarct on imaging	1
Age, y	
18–29	5
30–39	4
40–49	3
50–59	2
60–69	1
≥70	0
Total score (sum of individual points)	
Maximum score (a patient <30 y with no hypertension, no diabetes mellitus, no history of stroke or TIA, nonsmoker, and cortical infarct)	10
Minimum score (a patient ≥70 y with hypertension, diabetes mellitus, previous stroke, current smoker, and no cortical infarct)	0

RoPE indicates Risk of Paradoxical Embolism; and TIA, transient ischemic attack.

fraction can be considered by applying a patient-specific PFO prevalence rate.¹⁵ Generally, with a decreasing number of conventional stroke risk factors and younger age (resulting in a higher RoPE score and an increasing PFO prevalence), the PFO-attributable fraction (which, assuming causality, can be thought of as the proportion of strokes that would not have occurred if PFO had been previously eliminated) increases.

For this analysis, individual RoPE scores were calculated for each of the 1324 cases with PFO investigated by TEE. Echocardiographic variables were harmonized values based on clinical rationale and primary data from the component databases (published or unpublished). RoPE study investigators, through e-mail, telephone, teleconference, and face-to-face meetings, came to consensus regarding how to harmonize the echocardiographic parameters.¹⁶ Hypermobility of the interatrial septum (yes/no) was defined as maximum septal excursion from the midline into the right or left atrium (Bern published,²⁵ Patent Foramen Ovale in Cryptogenic Stroke Study [PICSS] Study,⁸ German,¹⁹ Lausanne, Tufts,²¹ Aortic Plaque and Risk of Ischemic Stroke [APRIS] Study,²⁶ French PFO/ASA²⁷) and total excursion between right and left atria (Recurrent Stroke and Massive Right-to-Left Shunt [CODICIA] Study).¹⁸ The consensus definition of hypermobility in our database refers to ≥10 mm of excursion from midline and is approximately equivalent to ASA used in the literature. Shunting across the PFO at rest (yes/no) was considered present if right-to-left shunting of bubbles was observed even in the absence of a Valsalva maneuver. All centers were likely to inject microbubbles from the upper extremity. Physiologic shunt size (large/small) was based on counting bubbles in the left atrium ≤3 cardiac cycles after right atrial opacification. Microbubbles observed after 3 cardiac cycles were not used to assess shunt severity. Large shunt size was defined differently in component databases: >10 bubbles (APRIS,²⁶ Bern published,²⁵ CODICIA,¹⁸ Lausanne, and PICSS⁸), ≥10 bubbles (French PFO/ASA,²⁷ German¹⁹), and >15 bubbles (Tufts²¹). The consensus definition of large shunt size was defined in our database as >10 bubbles in the left atrium ≤3 cardiac cycles after right atrial opacification.¹⁶ Our hypothesis is that these echocardiographic features will be more frequently observed in RoPE score strata with a higher probability of PFO-attributable stroke.

Statistical Analysis

For our primary analysis, we divided the population into those with a RoPE score that was above or below the median, that is, those with

scores >6 (higher probability of PFO-attributable stroke) and <6 (lower probability of PFO-attributable stroke). Significance was determined using *t*-test and χ^2 analyses with significance set at $P=0.05$. We used a generalized linear mixed model that included a random-effect term representing each component database when determining the significance of the various echocardiographic findings across RoPE score categories. For these analyses, the independent variable was the RoPE score; the dependent variable was presence or absence of putative high-risk TEE features. Our secondary analysis consisted of a test of linear trend with >7 ordered RoPE score categories, again using generalized mixed models where the study site was included as a random effect. We also performed extensive sensitivity analyses that evaluated association between RoPE score categories and composite PFO risk profiles: (1) large size and hypermobile septum, (2) not large and not hypermobile, and (3) large size or hypermobile. We evaluated the inter-reader reliability (κ) for the proposed high-risk TEE features by having 3 blinded readers reread a sampling of studies from the French PFO/ASA and PICSS studies. In addition, we explored for association by redefining large shunt size using a higher uncountable number of bubbles.

Results

The characteristics of subjects included in this analysis are shown in Table 2. There were 1294 subjects with CS and PFO and TEE data (see Figure). The mean age was 50 years; 59% of patients were white. There were 637 subjects with RoPE score >6 and 657 with RoPE score ≤6. This stratification produced subgroups with different characteristics: those in the low RoPE score group were 10-fold more likely to have diabetes mellitus, 5-fold more likely to have coronary artery disease, and ≈8-fold more likely to have hypertension ($P<0.0001$ for age, presence of diabetes mellitus, coronary artery disease, hypertension, hypercholesterolemia, and history of stroke or transient ischemic attack; $P=0.03$ for current smoking).

The proposed high-risk PFO characteristics seen on TEE were commonly seen in the RoPE database (Table 3). A sampling of TEE studies was reread by 3 readers to establish inter-reader reliability within the RoPE database. For 29 TEE studies from the French PFO/ASA study, $\kappa=0.57$ for hypermobile septum, 0.42 for large PFO, and 0.75 for shunt at rest, and for 31 TEE studies from the PICSS study, $\kappa=0.33$ for hypermobile septum, 0.14 for large PFO, and 0.33 for shunt at rest. Inter-reader agreement for these variables was consistent with previously published standards.²⁸ Overall, 25.3% had a hypermobile septum, 64.4% had a large shunt, and 69.6% had a shunt at rest. However, there was no difference in the frequency of these echocardiographic PFO features between the high RoPE score (higher probability of PFO-related index stroke) and low RoPE score (lower probability of PFO-related index stroke) cohorts (odds ratio [OR], 0.92; $P=0.53$ for large number of bubbles; OR, 1.15; $P=0.45$ for right-to-left shunt at rest; OR, 0.80; $P=0.11$ for presence of a hypermobile septum). Extensive exploratory analyses of echocardiographic features across RoPE score strata demonstrated no trend toward increased frequency as RoPE score increased after correcting for site effect. The prevalence of these TEE features varied across different centers for any given RoPE score stratum (see the Data Supplement I). Furthermore, we saw no trends after exploring different definitions of large shunt size and no association between RoPE score category and composite PFO risk profiles (see the Data Supplement II).

Table 2. Patient Characteristics Across RoPE Score Strata

	All PFO Patients With At Least Some TEE Data (n=1294)	RoPE Score >6 (n=637)	RoPE Score ≤6 (n=657)	P Value*
Patient characteristics				
Age, y, mean±SD	49.6±14.6 (1294)	38.9±9.2 (637)	60.0±10.8 (657)	
Age >65 y	17.9% (232/1294)	0.0% (0/637)	35.3% (232/657)	
Men	59.4% (768/1294)	54.6% (348/637)	63.9% (420/657)	0.0007
White race	86.6% (453/523)	93.4% (283/303)	77.3% (170/220)	<0.0001
Incident event was TIA	14.0% (181/1294)	9.7% (62/637)	18.1% (119/657)	<0.0001
Medical history, % yes				
Diabetes mellitus	8.7% (112/1289)	1.3% (8/636)	15.9% (104/653)	
Coronary artery disease	7.1% (63/885)	2.0% (7/343)	10.3% (56/542)	<0.0001
Hypertension	29.2% (377/1290)	6.0% (38/637)	51.9% (339/653)	
Hypercholesterolemia	24.2% (242/998)	12.1% (62/512)	37.0% (180/486)	<0.0001
Current smoker	29.6% (380/1282)	26.9% (171/636)	32.4% (209/646)	
History of stroke or TIA	11.9% (154/1290)	5.0% (32/635)	18.6% (122/655)	

Patient-level data were extracted from individual databases. Age represents the age at the time of index event. PFO indicates patent foramen ovale; RoPE, Risk of Paradoxical Embolism; TIA, transient ischemic attack; and TEE, transesophageal echocardiography.

*P-values from t-test (age), or χ^2 test.

Discussion

Because treatment decisions may rely on whether a discovered PFO is pathogenically related to the index stroke, it is critically important to identify reliable ways to stratify the likelihood that an identified PFO is associated with stroke. Although some proposed high-risk TEE features have been reported to be associated with CS in previous case-control studies, these previous studies report on a small number of patients and are often not statistically significant.^{8,29–37} Moreover, recognized potential high-risk features, including a persistent Eustachian valve, are not consistently reported in the literature.³⁸ This analysis from the RoPE study demonstrates that previously proposed high-risk TEE findings of septal hypermobility, shunt at rest, and physiologically large shunt do not seem to be more frequently found in patients whose clinical and neuroimaging features (ie, superficially located lesions) are highly suggestive of a PFO-attributable index stroke.

The null results from our study can be interpreted in several ways. First, the so-called high-risk PFO features may play no etiologic role in stroke; although the association between PFO and CS is presumed to be due to paradoxical embolism, there may be other important mechanisms unrelated to shunting or septal hypermobility. Second, although the features may, in fact, lead to higher risk of stroke (through paradoxical

embolism or other mechanisms), their ascertainment by TEE is imperfect and highly variable. Even when examining the same studies, inter-reader agreement would be surprisingly low, and (as discussed below) the studies are highly dependent on techniques and on patient factors that vary over time. Extensive exploratory analyses failed to identify trends when evaluating data from individual sites with uniform protocols (see the Data Supplement I). Third, in this study, TEE variables were collected at multiple sites under independent research protocols. These pragmatic conditions may have further increased measurement error. Fourth, although the relationship between the RoPE score and the presence of PFO was robust in this database, it is not possible to segregate patients for whom PFO is and is not causally related to their stroke. Finally, it is possible that the PFO association is mediated by different mechanisms, of which some depend on a large shunt, for example, paradoxical embolism, whereas others depend on a small shunt, for example, in situ thrombus formation. As previously reported, assuming a control PFO prevalence rate of 25%, the PFO-attributable fraction for patients with CS ranged from 0% (95% confidence interval [CI], 0%–4%) for patients with RoPE score 0 to 3, to 88% (95% CI, 83%–91%) for patients with RoPE score 9 to 10.¹⁵ Because patients with and without a true association between CS and PFO were

Table 3. Putative High-Risk TEE Features Across High and Low RoPE Score Strata

TEE Findings	All PFO Patients With At Least Some TEE Data (n=1294)	RoPE Score >6 (n=637)	RoPE Score ≤6 (n=657)	P Value*
Large no. of bubbles vs not large	64.4% (695/1079)	67.4% (347/515)	61.7% (348/564)	0.5286
Shunt at rest vs no shunt	69.6% (484/695)	67.6% (238/352)	71.7% (246/343)	0.4474
Hypermobile septum vs not	25.3% (320/1265)	23.0% (144/626)	27.5% (176/639)	0.1063

PFO indicates patent foramen ovale; RoPE, Risk of Paradoxical Embolism; and TEE, transesophageal echocardiography.

*P-values from generalized mixed models (TEE variables only) after adjusting for random site effect.

included in both comparison groups, the potential effect of the high-risk features may have been underestimated.

Although it is likely that each of these sources contributed to our null findings, the inability of TEE to robustly identify high-risk PFOs is a concern because TEE remains the gold standard by which anatomic characteristics of PFOs are characterized. Specific TEE protocols are not standardized across institutions, instantaneous loading conditions may fluctuate, and anatomic and functional features are variably reported in the literature.³⁹

ASA is characterized by a saccular formation of the interatrial septum that may protrude into either atrium. The term itself represents a spectrum of atrial septal morphological changes.⁴⁰ It is variably defined in the literature as septal movement of >10 or >15 mm.^{8,41} The causal relationship between ASA and CS has not been firmly established, although hypotheses include embolization of thrombi formed within the ASA, thrombus formation secondary to subclinical atrial arrhythmias, and alterations of septal movement that promote right-left shunting.²⁷ Recently reported exploratory analyses suggest that those with ASA present benefit from device closure compared with those without this septal anatomy, although this was not seen consistently.^{14,42} Interestingly, as reported in the literature, there is significant inter- and intraobserver variability in detecting this abnormality (even in research settings), likely limiting the discriminatory ability of this finding.²⁸ Morphological heterogeneity, varying definitions, and inconsistent detection may all contribute to the explanation as to why our analysis showed no clear relationship with RoPE strata in the RoPE database.

Our analysis evaluated microbubble count, 1 of the most commonly used tools for semiquantitative characterization of shunt size. Inconsistency of fine gradations of microbubble count is likely because these counts are made based on a single frame in a single imaging plane and, thus, may not represent the actual amount of shunting.⁴³ Moreover, the number of microbubbles does not correlate well with the anatomic size of a PFO.⁴⁴ Quantification of PFO size can be determined by the separation between septum primum and septum secundum in the bicaval view both at rest and during Valsalva maneuver.⁴⁵ This view, which is possible for most medium- and large-sized PFOs, was not consistently performed across the component RoPE databases. A further limitation of microbubble count, as determined in this study, is that important variation in shunt size may occur well beyond our cut-off value of 10. Although we also saw no effect using higher cut-offs, technical limitations of TEE may prevent measuring shunt size when the bubbles are uncountable, although variation in this range may be clinically significant. Newer methods of shunt detection may offer an increased ability to quantify the shunt objectively and over a wider range.⁴⁶ The measured shunt size may also differ depending on whether microbubbles are injected from the upper (as is standard) or the lower extremities (perhaps better reflecting the presumed mechanism due to lower extremity or pelvic vein thrombi). In part because shunting from the lower extremity may depend on the presence and characteristics of a Eustachian valve (unmeasured across most RoPE component studies), measures of shunting from these 2 sources may be poorly correlated.^{45,47} A minority of included databases (Bern and PICSS) systematically ascertained information on the Eustachian valve.⁴⁷ As a result, this

feature was not included in our analysis. These limitations, in association with significant inter-reader variability in bubble count, create noise that may contribute to the null result for this variable.^{27,28}

Similarly, the presence of a right-to-left shunt at rest is highly variable and dependent on technique and loading conditions. Physiological pressure differences between the right and left atria usually push the septum primum against the septum secundum. Momentary changes in pressures can result in a transient elevation of right atrial pressure so that it is greater than left atrial pressure. The free edge of the septum primum may move, resulting in enlargement of the PFO orifice.⁹ Transient shunting and directional shift can be seen in the setting of changes in volume status or body positioning. An effective Valsalva maneuver, defined by complete bowing of the interatrial septum toward the left atrium, may be difficult when sedation is too heavy.³⁹ Moreover, this hemodynamic state represents 1 of many circumstances where right atrial pressure may rise above that seen in the left atrium. Because the presence of right-to-left shunting is critically dependent on instantaneous interatrial pressure differences, it is not surprising that this short-term observation as documented in the component RoPE database studies is an unreliable marker of long-term paradoxical embolism risk.

In summary, we found no evidence that subjects with CS and clinical features suggestive of PFO-attributable stroke are more likely to have putative high-risk TEE features than those whose clinical features suggest CS unrelated to their PFO. Because of numerous technical limitations, TEE may be unreliable in risk-stratifying PFO on the basis of physiological and anatomic features. Although some of the limitations discussed here relate to limitations in how TEE was applied in the component RoPE studies and may be partially addressable through more rigorous standardization of imaging procedures, our results can also be seen as reflecting the limitations of TEE measurements as they are usually performed in routine clinical practice. Further development of technologies that might better and more consistently characterize PFO features is needed.

Sources of Funding

This study was partially funded by grants UL1 RR025752, R01 NS062153, and R21 NS079826 from the National Institutes of Health.

Disclosures

Both D.M.K. and D.E.T. have consulted for WL Gore Associates. D.E.T. is a consultant to AGA Medical Corporation. The other authors report no conflicts.

References

1. Lechat P, Mas JL, Lascault G, Loron P, Theard M, Klimczac M, Drobinski G, Thomas D, Grosgeat Y. Prevalence of patent foramen ovale in patients with stroke. *N Engl J Med*. 1988;318:1148–1152.
2. Homma S, Sacco RL. Patent foramen ovale and stroke. *Circulation*. 2005;112:1063–1072.
3. Kent DM, Thaler DE. Is patent foramen ovale a modifiable risk factor for stroke recurrence? *Stroke*. 2010;41(10 suppl):S26–S30.
4. Agmon Y, Khandheria BK, Meissner I, Gentile F, Whisnant JP, Sicks JD, O'Fallon WM, Covalt JL, Wiebers DO, Seward JB. Frequency of atrial

- septal aneurysms in patients with cerebral ischemic events. *Circulation*. 1999;99:1942–1944.
5. Lee JY, Song JK, Song JM, Kang DH, Yun SC, Kang DW, Kwon SU, Kim JS. Association between anatomic features of atrial septal abnormalities obtained by omni-plane transesophageal echocardiography and stroke recurrence in cryptogenic stroke patients with patent foramen ovale. *Am J Cardiol*. 2010;106:129–134.
 6. Rigatelli G, Dell'Avvocata F, Cardaioli P, Giordan M, Braggion G, Aggio S, Chinaglia M, Mandapaka S, Kuruvilla J, Chen JP, Nanjundappa A. Permanent right-to-left shunt is the key factor in managing patent foramen ovale. *J Am Coll Cardiol*. 2011;58:2257–2261.
 7. Di Tullio MR, Sacco RL, Sciacca RR, Jin Z, Homma S. Patent foramen ovale and the risk of ischemic stroke in a multiethnic population. *J Am Coll Cardiol*. 2007;49:797–802.
 8. Homma S, Sacco RL, Di Tullio MR, Sciacca RR, Mohr JP; PFO in Cryptogenic Stroke Study (PICSS) Investigators. Effect of medical treatment in stroke patients with patent foramen ovale: patent foramen ovale in Cryptogenic Stroke Study. *Circulation*. 2002;105:2625–2631.
 9. Kuttly S, Sengupta PP, Khandheria BK. Patent foramen ovale: the known and the to be known. *J Am Coll Cardiol*. 2012;59:1665–1671.
 10. Kent DM, Thaler DE; RoPE Study Investigators. The Risk of Paradoxical Embolism (RoPE) Study: developing risk models for application to ongoing randomized trials of percutaneous patent foramen ovale closure for cryptogenic stroke. *Trials*. 2011;12:185.
 11. Kent DM, Hayward RA. Limitations of applying summary results of clinical trials to individual patients: the need for risk stratification. *JAMA*. 2007;298:1209–1212.
 12. Kent DM, Rothwell PM, Ioannidis JP, Altman DG, Hayward RA. Assessing and reporting heterogeneity in treatment effects in clinical trials: a proposal. *Trials*. 2010;11:85.
 13. Alsheikh-Ali AA, Thaler DE, Kent DM. Patent foramen ovale in cryptogenic stroke: incidental or pathogenic? *Stroke*. 2009;40:2349–2355.
 14. Furlan AJ, Reisman M, Massaro J, Mauri L, Adams H, Albers GW, Felberg R, Herrmann H, Kar S, Landzberg M, Raizner A, Wechsler L; CLOSURE I Investigators. Closure or medical therapy for cryptogenic stroke with patent foramen ovale. *N Engl J Med*. 2012;366:991–999.
 15. Kent DM, Ruthazer R, Weimar C, Mas JL, Serena J, Homma S, Di Angelantonio E, Di Tullio MR, Lutz JS, Elkind MS, Griffith J, Jaigobin C, Mattle HP, Michel P, Mono ML, Nedeltchev K, Papetti F, Thaler DE. An index to identify stroke-related vs incidental patent foramen ovale in cryptogenic stroke. *Neurology*. 2013;81:619–625.
 16. Thaler DE, Di Angelantonio E, Di Tullio MR, Donovan JS, Griffith J, Jaigobin C, Mattle HP, Michel P, Mono ML, Nedeltchev K, Papetti F, Ruthazer R, Serena J, Weimar C, Elkind MS, Kent DM. The Risk of Paradoxical Embolism (RoPE) Study: initial description of the completed database. *Int J Stroke*. 2012 Aug 9 [Epub ahead of print].
 17. De Castro S, Papetti F, Di Angelantonio E, Razmovska B, Trusculli G, Tuderti U, Puca E, Correnti A, Fiorelli M, Principe M, Toni D. Feasibility and clinical utility of transesophageal echocardiography in the acute phase of cerebral ischemia. *Am J Cardiol*. 2010;106:1339–1344.
 18. Serena J, Marti-Fàbregas J, Santamarina E, Rodríguez JJ, Perez-Ayuso MJ, Masjuan J, Segura T, Gállego J, Dávalos A; CODICIA, Right-to-Left Shunt in Cryptogenic Stroke Study; Stroke Project of the Cerebrovascular Diseases Study Group, Spanish Society of Neurology. Recurrent stroke and massive right-to-left shunt: results from the prospective Spanish multicenter (CODICIA) study. *Stroke*. 2008;39:3131–3136.
 19. Weimar C, Holle DN, Benemann J, Schmid E, Schminke U, Haberl RL, Diener HC, Goertler M; German Stroke Study Collaboration. Current management and risk of recurrent stroke in cerebrovascular patients with right-to-left cardiac shunt. *Cerebrovasc Dis*. 2009;28:349–356.
 20. Steiner MM, Di Tullio MR, Rundek T, Gan R, Chen X, Liguori C, Brainin M, Homma S, Sacco RL. Patent foramen ovale size and embolic brain imaging findings among patients with ischemic stroke. *Stroke*. 1998;29:944–948.
 21. Kitsios GD, Lasker A, Singh J, Thaler DE. Recurrent stroke on imaging and presumed paradoxical embolism: a cross-sectional analysis. *Neurology*. 2012;78:993–997.
 22. Casaubon L, McLaughlin P, Webb G, Yeo E, Merker D, Jaigobin C. Recurrent stroke/TIA in cryptogenic stroke patients with patent foramen ovale. *Can J Neurol Sci*. 2007;34:74–80.
 23. Adams HP Jr, Bendixen BH, Kappelle LJ, Biller J, Love BB, Gordon DL, Marsh EE III. Classification of subtype of acute ischemic stroke. Definitions for use in a multicenter clinical trial. Trial of Org 10172 in Acute Stroke Treatment. *Stroke*. 1993;24:35–41.
 24. Kitsios GD, Dahabreh IJ, Abu Dabrh AM, Thaler DE, Kent DM. Patent foramen ovale closure and medical treatments for secondary stroke prevention: a systematic review of observational and randomized evidence. *Stroke*. 2012;43:422–431.
 25. Nedeltchev K, Arnold M, Wahl A, Sturzenegger M, Vella EE, Windecker S, Meier B, Mattle HP. Outcome of patients with cryptogenic stroke and patent foramen ovale. *J Neurol Neurosurg Psychiatry*. 2002;72:347–350.
 26. Di Tullio MR, Homma S, Jin Z, Sacco RL. Aortic atherosclerosis, hypercoagulability, and stroke: the APRIS (Aortic Plaque and Risk of Ischemic Stroke) study. *J Am Coll Cardiol*. 2008;52:855–861.
 27. Mas JL, Arquizan C, Lamy C, Zuber M, Cabanes L, Derumeaux G, Coste J; Patent Foramen Ovale and Atrial Septal Aneurysm Study Group. Recurrent cerebrovascular events associated with patent foramen ovale, atrial septal aneurysm, or both. *N Engl J Med*. 2001;345:1740–1746.
 28. Cabanes L, Coste J, Derumeaux G, Jeanrenaud X, Lamy C, Zuber M, Mas JL; Patent Foramen Ovale and Atrial Septal Aneurysm Study Group. Interobserver and intraobserver variability in detection of patent foramen ovale and atrial septal aneurysm with transesophageal echocardiography. *J Am Soc Echocardiogr*. 2002;15:441–446.
 29. Hanna JP, Sun JP, Furlan AJ, Stewart WJ, Sila CA, Tan M. Patent foramen ovale and brain infarct: echocardiographic predictors, recurrence, and prevention. *Stroke*. 1994;25:782–786.
 30. Natanzon A, Goldman ME. Patent foramen ovale: anatomy versus pathophysiology—which determines stroke risk? *J Am Soc Echocardiogr*. 2003;16:71–76.
 31. Force M, Massabau P, Larue V. Prevalence of atrial septal abnormalities in older patients with cryptogenic ischemic stroke or transient ischemic attack. *Clin Neurol Neurosurg*. 2008;110:779–783.
 32. Goel SS, Tuzcu EM, Shishehbor MH, de Oliveira EI, Borek PP, Krasuski RA, Rodríguez LL, Kapadia SR. Morphology of the patent foramen ovale in asymptomatic versus symptomatic (stroke or transient ischemic attack) patients. *Am J Cardiol*. 2009;103:124–129.
 33. Mesa D, Ruiz M, Delgado M, Suárez de Lezo J, Pan M, Tejero I, García D, Crespín M, León C, Toledano F, Mazuelos F, Ochoa JJ, Bescansa E. Prevalence of patent foramen ovale determined by transesophageal echocardiography in patients with cryptogenic stroke aged 55 years or older: same as younger patients? *Rev Esp Cardiol*. 2010;63:315–322.
 34. Cabanes L, Mas JL, Cohen A, Amarenco P, Cabanes PA, Oubary P, Chedru F, Guérin F, Bousser MG, de Recondo J. Atrial septal aneurysm and patent foramen ovale as risk factors for cryptogenic stroke in patients less than 55 years of age: a study using transesophageal echocardiography. *Stroke*. 1993;24:1865–1873.
 35. Handke M, Harloff A, Olschewski M, Hetzel A, Geibel A. Patent foramen ovale and cryptogenic stroke in older patients. *N Engl J Med*. 2007;357:2262–2268.
 36. Job FP, Ringelstein EB, Grafen Y, Flachskampf FA, Doherty C, Stockmanns A, Hanrath P. Comparison of transcranial contrast Doppler sonography and transesophageal contrast echocardiography for the detection of patent foramen ovale in young stroke patients. *Am J Cardiol*. 1994;74:381–384.
 37. Petty GW, Khandheria BK, Chu CP, Sicks JD, Whisnant JP. Patent foramen ovale in patients with cerebral infarction. A transesophageal echocardiographic study. *Arch Neurol*. 1997;54:819–822.
 38. Schuchlenz HW, Saurer G, Weihs W, Rehak P. Persisting eustachian valve in adults: relation to patent foramen ovale and cerebrovascular events. *J Am Soc Echocardiogr*. 2004;17:231–233.
 39. Di Tullio MR. Patent foramen ovale: echocardiographic detection and clinical relevance in stroke. *J Am Soc Echocardiogr*. 2010;23:144–155; quiz 220.
 40. Olivares-Reyes A, Chan S, Lazar EJ, Bandlamudi K, Narla V, Ong K. Atrial septal aneurysm: a new classification in two hundred five adults. *J Am Soc Echocardiogr*. 1997;10:644–656.
 41. Hara H, Virmani R, Ladich E, Mackey-Bojack S, Titus J, Reisman M, Gray W, Nakamura M, Mooney M, Poulouse A, Schwartz RS. Patent foramen ovale: current pathology, pathophysiology, and clinical status. *J Am Coll Cardiol*. 2005;46:1768–1776.
 42. Meier B, Kalesan B, Mattle HP, Khattab AA, Hildick-Smith D, Dudek D, Andersen G, Ibrahim R, Schuler G, Walton AS, Wahl A, Windecker S, Juni P; PC Trial Investigators. Percutaneous closure of patent foramen ovale in cryptogenic embolism. *N Engl J Med*. 2013;368:1083–1091.
 43. De Castro S, Cartoni D, Fiorelli M, Rasura M, Anzini A, Zanette EM, Beccia M, Colonnese C, Fedele F, Fieschi C, Pandian NG. Morphological and functional characteristics of patent foramen ovale and their embolic implications. *Stroke*. 2000;31:2407–2413.

44. Schuchlenz HW, Weihs W, Horner S, Quehenberger F. The association between the diameter of a patent foramen ovale and the risk of embolic cerebrovascular events. *Am J Med.* 2000;109:456–462.
45. Homma S, Di Tullio MR, Sacco RL, Mihalatos D, Li Mandri G, Mohr JP. Characteristics of patent foramen ovale associated with cryptogenic stroke. A biplane transesophageal echocardiographic study. *Stroke.* 1994;25:582–586.
46. Sommer R, Brandwein R, Dobson D, Eggers E, Eggers A. Novel system for detection of cardiac right to left shunts. *J Am Coll Cardiol.* 2012;60(suppl):B225–B226.
47. Homma S, Sacco RL, Di Tullio MR, Sciacca RR, Mohr JP. Atrial anatomy in non-cardioembolic stroke patients: effect of medical therapy. *J Am Coll Cardiol.* 2003;42:1066–1072.

CLINICAL PERSPECTIVE

Patent foramen ovale (PFO) is associated with cryptogenic stroke (CS), although the pathogenicity of an observed PFO for an individual is unknown. Transesophageal echocardiography (TEE) features such as PFO size, hypermobile septum (atrial septal aneurysm), and presence of a right-to-left shunt at rest are proposed high-risk features. The Risk of Paradoxical Embolism (RoPE) database, evaluated here, is a large observational database formed by combining 12 component databases of patients with CS and known PFO status. We used the RoPE score, a recently developed score based on clinical data and neuroimaging, to stratify patients with PFO and CS by the probability that CS is attributable to an observed PFO. We evaluated whether high-risk TEE features were seen more frequently in patients more likely to have a PFO-associated stroke. This analysis shows no association between purported high-risk TEE features and the likelihood that an observed PFO is pathogenically related to CS. Additional tools to describe PFOs may be helpful in determining whether an observed PFO is incidental or likely pathogenically related to CS.