

27. Robbers LF, Eerenberg ES, Teunissen PF, Jansen MF, Hollander MR, Horrevoets AJ, Knaepen P, Nijveldt R, Heymans MW, Levi MM, van Rossum AC, Niessen HW, Marcu CB, Beek AM, van Royen N. Magnetic resonance imaging-defined areas of microvascular obstruction after acute myocardial infarction represent microvascular destruction and haemorrhage. *Eur Heart J* 2013;**34**:2346–2353.
28. Sezer M, Cimen A, Aslanger E, Elitok A, Umman B, Bugra Z, Yormaz E, Turkmen C, Adalet IS, Nisanci Y, Umman S. Effect of intracoronary streptokinase administered immediately after primary percutaneous coronary intervention on long-term left ventricular infarct size, volumes, and function. *J Am Coll Cardiol* 2009;**54**:1065–1071.
29. McGeoch R, Watkins S, Berry C, Steedman T, Davie A, Byrne J, Hillis S, Lindsay M, Robb S, Dargie H, Oldroyd K. The index of microcirculatory resistance measured acutely predicts the extent and severity of myocardial infarction in patients with ST-segment elevation myocardial infarction. *JACC Cardiovasc Interv* 2010;**3**:715–722.
30. Eitel I, Desch S, Fuernau G, Hildebrand L, Gutberlet M, Schuler G, Thiele H. Prognostic significance and determinants of myocardial salvage assessed by cardiovascular magnetic resonance in acute reperfused myocardial infarction. *J Am Coll Cardiol* 2010;**55**:2470–2479.
31. Neumann FJ, Kosa I, Dickfeld T, Blasini R, Gawaz M, Hausleiter J, Schwaiger M, Schomig A. Recovery of myocardial perfusion in acute myocardial infarction after successful balloon angioplasty and stent placement in the infarct-related coronary artery. *J Am Coll Cardiol* 1997;**30**:1270–1276.
32. Schwartz BG, Kloner RA. Coronary no reflow. *J Mol Cell Cardiol* 2012;**52**:873–882.
33. Pitarys CJ II, Virmani R, Vildibill HD Jr, Jackson EK, Forman MB. Reduction of myocardial reperfusion injury by intravenous adenosine administered during the early reperfusion period. *Circulation* 1991;**83**:237–247.
34. Reffelmann T, Kloner RA. Microvascular reperfusion injury: rapid expansion of anatomic no reflow during reperfusion in the rabbit. *Am J Physiol Heart Circ Physiol* 2002;**283**:H1099–H1107.
35. Niccoli G, Lanza GA, Shaw S, Romagnoli E, Gioia D, Burzotta F, Trani C, Mazzari MA, Mongiardo R, De Vita M, Rebuffi AG, Luscher TF, Crea F. Endothelin-1 and acute myocardial infarction: a no-reflow mediator after successful percutaneous myocardial revascularization. *Eur Heart J* 2006;**27**:1793–1798.
36. Eitel I, Nowak M, Stehl C, Adams V, Fuernau G, Hildebrand L, Desch S, Schuler G, Thiele H. Endothelin-1 release in acute myocardial infarction as a predictor of long-term prognosis and no-reflow assessed by contrast-enhanced magnetic resonance imaging. *Am Heart J* 2010;**159**:882–890.
37. Watanabe T, Suzuki N, Shimamoto N, Fujino M, Imada A. Contribution of endogenous endothelin to the extension of myocardial infarct size in rats. *Circ Res* 1991;**69**:370–377.
38. Adlbrecht C, Andreas M, Redwan B, Distelmaier K, Mascherbauer J, Kaider A, Wolz M, Tilea IA, Neunteufl T, Delle-Karth G, Maurer G, Lang IM. Systemic endothelin receptor blockade in ST-segment elevation acute coronary syndrome protects the microvasculature: a randomised pilot study. *EuroIntervention* 2012;**7**:1386–1395.

CARDIOVASCULAR FLASHLIGHT

doi:10.1093/eurheartj/ehu023

Online publish-ahead-of-print 3 February 2014

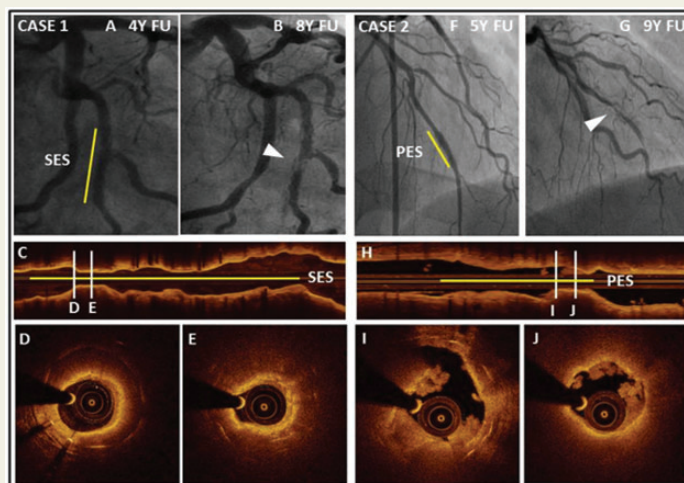
Neoatherosclerosis as reason for stent failures beyond 5 years after drug-eluting stent implantation

Masanori Taniwaki, Stephan Windecker, and Lorenz Räber*

Department of Cardiology, Swiss Cardiovascular Center, Bern University Hospital, Bern 3010, Switzerland

* Corresponding author. Tel: +41 316320929, Fax: +41 316324770, Email: lorenz.raeber@insel.ch

A 69-year-old male (case 1) was admitted due to acute non-ST-segment elevation myocardial infarction (NSTEMI). Eight years earlier, he had previously undergone treatment with a sirolimus-eluting stent (SES). Four years after stent implantation, a follow-up angiography was obtained showing a patent stent without obstructive in-stent restenosis (Panel A). Angiograms obtained at the time of NSTEMI (Panel B) disclosed subtotal occlusion in the middle of the SES (arrowheads). Optical coherence tomography revealed a signal intense luminal layer with an underlying, highly attenuating, diffusely demarcated area, suggestive for an in-stent fibroatheroma (Panel D) with a minimal cap thickness of 80 μm . Accordingly, ischaemia was caused by the high degree of stenosis (Panel E). Similarly, a 59-year-old male (case 2) was admitted due to STEMI. Nine years before, he had received a paclitaxel-eluting stent (PES). Five years after stent implantation, a follow-up angiography revealed a patent stent (Panel F). Angiograms obtained at the time of STEMI (Panel G) disclosed total occlusion in the proximal of PES (arrowheads). Optical coherence tomography showed a rupture of thin cap fibroatheroma within the stented segment (Panel I). The thin cap fibroatheroma caused a severe stenosis with superimposed thrombus (Panel J).



Neoatherosclerosis has been recently described as particular disease entity being responsible for very late stent failures. These two cases illustrate that the presence of a favourable long-term angiographic result years after DES implantation does not exclude a future neoatherosclerosis-related event (restenosis or stent thrombosis). Large observational and long-term intracoronary imaging studies are required to fully elucidate the dynamics and clinical relevance of neoatherosclerosis.

This paper was guest edited by **Brahmajee Nallamothu** (bnallamo@umich.edu, University of Michigan).